

Left Ventricular Pseudoaneurysm - A rare condition and its Imaging

Farooq Ahmad Ganie, Ghulam Nabi Lone, Syeed Wahid, Mohd Iqbal

Farooq Ahmad Ganie, Ghulam Nabi Lone, Syeed Wahid, Mohd Iqbal Dar, Department of Cardiovascular and thoracic Surgery¹ and Department of cardiology², Sher-i-Kashmir Institute of Medical Sciences (SKIMS), Soura Srinagar (Jammu and Kashmir), India

Conflict-of-interest statement: The author(s) declare(s) that there is no conflict of interest regarding the publication of this paper.

Open-Access: This article is an open-access article which was selected by an in-house editor and fully peer-reviewed by external reviewers. It is distributed in accordance with the Creative Commons Attribution Non Commercial (CC BY-NC 4.0) license, which permits others to distribute, remix, adapt, build upon this work non-commercially, and license their derivative works on different terms, provided the original work is properly cited and the use is non-commercial. See: <http://creativecommons.org/licenses/by-nc/4.0/>

Correspondence to: Farooq Ahmad Ganie, Department of Cardiovascular and thoracic Surgery¹ and Department of cardiology², Sher-i-Kashmir Institute of Medical Sciences (SKIMS), Soura Srinagar (Jammu and Kashmir), India.

Email: farooq.ganie@ymail.com

Telephone: +946064259

Received: October 13, 2016

Revised: December 25, 2016

Accepted: January 2, 2017

Published online: February 24, 2017

ABSTRACT

Left ventricular pseudoaneurysm is a well-recognized and rare complication of myocardial infarction and frequent cause of death. A 48-year-old man with old myocardial infarction was diagnosed to have a left ventricular pseudoaneurysm on echocardiography. In addition, he had a unique, echocardiographic finding. He was successfully treated by Dor procedure and myocardial revascularization.

Key words: Left ventricular rupture; Pseudoaneurysm; Myocardial infarction; CABG

© 2017 The Author(s). Published by ACT Publishing Group Ltd. All rights reserved.

Ganie FA, Lone GN, Wahid S, Iqbal M. Left Ventricular Pseudoaneurysm - A rare condition and its Imaging. *Journal of Cardiology and Therapy* 2017; 4(1): 608-610 Available from: URL: <http://www.ghrnet.org/index.php/jct/article/view/1894>

INTRODUCTION

Pseudoaneurysm of the left ventricle (LV) usually develops following ventricular rupture due to transmural myocardial infarction (MI)^[1]. The incidence of LV free wall rupture following MI is 2%^[2]. Free wall rupture causes fatal pericardial tamponade in most cases, but in some, the thrombus becomes organized within the limitation of the surrounding tissues and pericardium, and becomes a cavity that results in pseudoaneurysm formation^[3].

CLINICAL REPORT

A 48 years old man, a chronic smoker presented with progressively worsening dyspnoea on exertion NYHA class II since the last one week and left hypochondrial pain and palpitations for the last 3 to 4 days. the patient had history of a anterior and inferior wall myocardial infarction two years back. Transthoracic echocardiography was done which revealed a moderately enlarged left ventricle with a large pseudoaneurysm involving distal septum and apex and a large apical thrombus.

A thin fluttering membrane was seen covering the thrombus. In the short axis of the Left Ventricle distal to the papillary muscle, this membrane appeared to be detached from other layers except from 1 to 5 O' clock position (Figure 1). A layer of blood with spontaneous echo contrast was seen between this fluttering endocardium and the LV clot. No communication of this blood cavity with the LV cavity was demonstrable. The LV ejection fraction was about 40%. There was a small collection of pericardial fluid near RV apex close to the aneurysm. A cardiac (magnetic resonance imaging) MRI with contrast confirmed the echocardiographic findings (Figure 2). In addition, transmural infarcts were noticed in territories of the left anterior descending branch and the right coronary artery branch. A preoperative coronary angiogram showed single vessel disease with

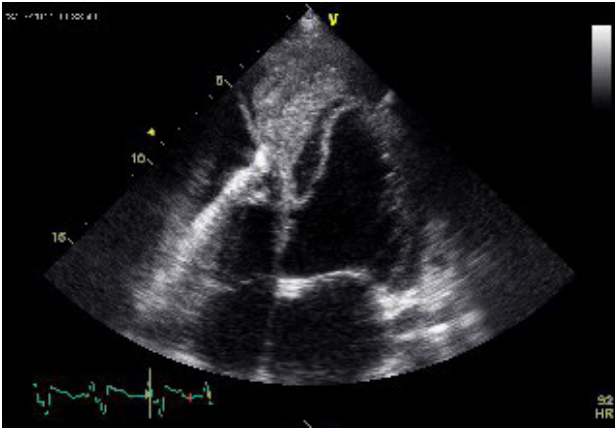


Figure 1 Echocardiography depicts the Left Ventricular Pseudoaneurysm.

occlusion of the distal left anterior descending artery (LAD). The patient was taken for an urgent pseudoaneurysm repair.

The approach was through a standard median sternotomy with exposure and cannulation of the femoral vessels prior to sternotomy. Manipulation of the heart was avoided prior to cardiopulmonary bypass to prevent rupture or embolization. The pericardium was found to contain about 50 ml of serosanguinous fluid. A large, organized clot was found in the dilated portion of the left ventricle close to the apex. The epicardium was intact. The aneurysmal portion of the LV was excised till healthy tissue. Left ventricular reconstruction was done by Dor procedure using a 4 cm size goretex patch and 2-0 prolene continuous sutures. LAD endarterectomy was done and a vein graft was used for revascularization of left anterior descending and diagonal branches. Postoperatively, the patient was electively ventilated for twenty four hours, intra aortic

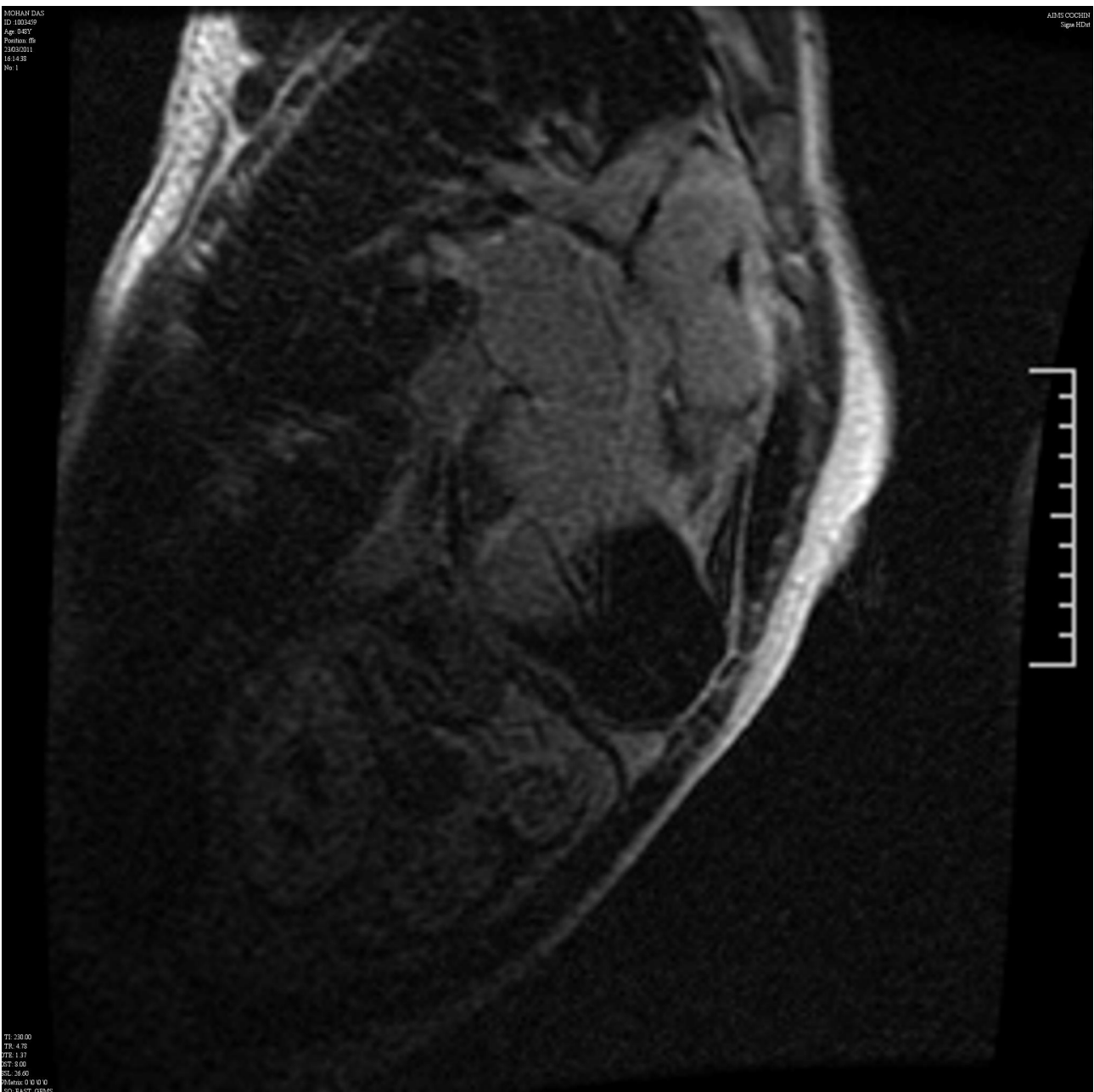


Figure 2 Cardiac(magnetic resonance imaging) MRI showing the Left Ventricular Pseudoaneurysm.

balloon pump (IABP) Was put to ensure adequate hemodynamic was discontinued after 72 hours. The patient remained in the intensive care unit for four days and was discharged on the tenth postoperative day. echocardiography done postoperatively showed moderate LV dysfunction with an ejection fraction of 35- 40%. At 3 months post surgery the patient is in NYHA class II.

DISCUSSION

Left ventricular pseudoaneurysm is a serious complication of transmural myocardial infarction. Being a rare condition, the natural history of LV pseudoaneurysm is unknown. They are usually localized to the inferobasal and posterobasal segments of the LV. In our case, the pseudoaneurysm was located on the apical and posterobasal portion. Pseudoaneurysms do not have a definite symptomatology. They most commonly present with heart failure symptoms, chest pain and dyspnoea, but they are asymptomatic in 10% of the cases. Currently, echocardiography (transthoracic or transesophageal) is the diagnostic standard^[4] for diagnosis of pseudoaneurysms as it has the ability to visualize the heart in different planes and distinguish the myocardium from other structures. Characteristic echocardiographic findings suggestive of a false aneurysm include a sharp discontinuity of endocardial image at the site of pseudoaneurysm communication with the left ventricular cavity, a saccular or globular contour of the false aneurysmal chamber and the presence of a relatively narrow orifice compared with the diameter of the aneurysm fundus^[5]. Two other characteristics of pseudoaneurysm include systolic expansion of the aneurysmal cavity and displacement of other cardiac chambers. At times, visualization of the myocardial wall at the pseudoaneurysm site is difficult and one cannot distinguish a pseudoaneurysm from a localized pericardial effusion, hematoma, pericardial cyst or diverticulum. In these cases, colour flow imaging facilitates diagnosis by demonstrating shunting of blood from the left ventricular cavity into the aneurysm and back. Pulsed doppler demonstrating turbulent flow at the neck of a cavity or the cavity itself also suggests a pseudoaneurysm^[6]. In our case, preoperative diagnosis was established by echocardiography. Although, it did not fit into the classic definition of a pseudoaneurysm according to the echocardiographic criteria, the fact that it was a pseudoaneurysm was based on its location and the absence of myocardium in the aneurysmal cavity. No communication between the aneurysmal cavity and the left ventricle was demonstrable on

echocardiography, but the presence of an endocardium which was detached from all the other layers and was seen fluttering depending upon the dynamic left ventricular pressure changes. A diagnosis of intramural hematoma or myocardial dissection was not ruled out. However, in those cases, the position of the endocardial membrane would have been the same regardless of the left ventricular pressure changes. This fluttering endocardium is a unique finding and has not been reported in literature. On echocardiography the presence of free space behind the left atrium communicating with the left ventricular cavity reported in literature, in left ventricle pseudoaneurysm^[7].

Intraoperatively, there was no evidence of either a hematoma or a dissection. Surgery is indicated for all patients as soon as the diagnosis is established, unless the surgical risk is prohibitive^[7], especially for large or expanding pseudoaneurysms, regardless of symptoms. This approach is justified by uncertain natural history in regard to rupture and risk of embolizing thrombotic material.

REFERENCES

1. Eren E, Bozbuga N, Toker ME, Keles C, Rabus MB, Yildirim O, et al. Surgical treatment of post-infarction left ventricular pseudoaneurysm: a two-decade experience. *Tex Heart Inst J* 2007; **34**: 47–51.
2. Moreno R, Lopez de Sa E, Lopez-Sendon JL, Garcia E, Soriano J, Abeytua M, et al. Frequency of left ventricular free-wall rupture in patients with acute myocardial infarction treated with primary angioplasty. *Am J Cardiol* 2000; **85**: 757–60, A8.
3. Malcolm ID, Fitchett DH, Stewart D, Marpole D, Symes J. Ventricular aneurysm: false or true? An important distinction. *Ann Thorac Surg* 1980; **29**: 474–7.
4. Sutherland GR, Smyllie JH, Roelandt JR. Advantages of colour flow imaging in the diagnosis of left ventricular pseudoaneurysm. *Br Heart J* 1989; **61**: 59–64.
5. Catherwood E, Mintz GS, Kotler MN, Parry WR, Segal BL. Two-dimensional echocardiographic recognition of left ventricular pseudoaneurysm. *Circulation* 1980; **62**: 294-303.
6. Loperfido F, Pennestri F, Mazzari M, Biasucci LM, Vigna C, Laurenzi F. Diagnosis of left ventricular pseudoaneurysm by pulsed Doppler echocardiography. *Am Heart J* 1985; **110**: 1291-3.
7. Sidebotham D, Lai J. An abnormal echo free space behind the left atrium. *Journal of Cardiothoracic and vascular anaesthesia* 2004; **18**: 671-72.

Peer reviewer: Jin Bo Su