

## Precise Medicine of Restrictive Cardiomyopathy

QianYun Wu, Iokfai Cheang, XinLi Li

QianYun Wu, Iokfai Cheang, XinLi Li, Department of Cardiology, the First Affiliated Hospital with Nanjing Medical University, Nanjing, China

**Conflict-of-interest statement:** The author(s) declare(s) that there is no conflict of interest regarding the publication of this paper.

**Open-Access:** This article is an open-access article which was selected by an in-house editor and fully peer-reviewed by external reviewers. It is distributed in accordance with the Creative Commons Attribution Non Commercial (CC BY-NC 4.0) license, which permits others to distribute, remix, adapt, build upon this work non-commercially, and license their derivative works on different terms, provided the original work is properly cited and the use is non-commercial. See: <http://creativecommons.org/licenses/by-nc/4.0/>

**Correspondence to:** Prof. XinLi LI, Department of Cardiology, First Affiliated Hospital with Nanjing Medical University, Guangzhou Road 300, Nanjing 210029, China.

Email: [xinli3267@yeah.net](mailto:xinli3267@yeah.net)

Telephone: +86-13611573111

Fax: +86-25 68303754

Received: January 2, 2018

Revised: April 6, 2018

Accepted: April 8, 2018

Published online: May 2, 2018

### ABSTRACT

Restrictive Cardiomyopathy (RCM) is a form of cardiomyopathy, which having improper blood filling by different restricted etiologies. RCM can be clinically challenging and often result of a poor prognosis. With the early and precise intervention, expectancy outcomes are better. In this article, we reviewed an updated of restrictive cardiomyopathy which are published and provide an overview diagnosis and treatment advancement of the disease.

**Key words:** Restrictive cardiomyopathy (RCM); Precise Medicine; Diagnosis; Treatment

© 2018 The Author(s). Published by ACT Publishing Group Ltd. All rights reserved.

Wu QY, Cheang I, Li XL. Precise Medicine of Restrictive Cardiomyopathy. *Journal of Cardiology and Therapy* 2018; 5(1): 723-728 Available from: URL: <http://www.ghrnet.org/index.php/jct/article/view/2239>

### INTRODUCTION

According to the different physiology change, cardiomyopathy can be divided into different forms. Hypertrophic cardiomyopathy (HCM) is defined by the presence of increased left ventricular (LV) wall thickness that is not solely explained by abnormal loading conditions. Dilated cardiomyopathy (DCM) is a progressive ventricular wall thinning and dilatation accompanied with gradual functional impairment. Restrictive cardiomyopathy (RCM) is a heterogenous group of myocardial diseases which usually result from increased myocardial stiffness leads to impaired ventricular filling by variety of causes.

Restrictive physiology could also occur in HCM and DCM, correct differentiate the disease are needed. Among 1,226 patients with familial HCM (688 families), 1.5% had phenotypes diagnostic of RCM<sup>[1]</sup>. Consequently, the variety of etiopathogenesis and the difficulty of diagnosis lead to poor prognosis of patients with RCM<sup>[2-4]</sup>.

Studies showed up to 10%-15% of patients in heart failure preserved ejection fraction (HFpEF) were caused by RCM<sup>[4]</sup>. In a pediatric single center study, the morbidity of RCM in children accounted for 4.8% of all cardiomyopathy. High incidence of sudden death was observed: 2-year survival rate was 50%, and the 5-year survival rate dropped to only 25%<sup>[5]</sup>. Therefore, to investigate the causes of restricted cardiomyopathy and establish the precise diagnosis and treatment are crucial for improving the prognosis.

### CLASSIFICATION

RCM is divided into primary and secondary, in which genetic inheritance could exist in both types.

Primary RCM is usually inherited and a number of mutations have been identified. Most of which are autosomal dominant (AD)<sup>[6]</sup>.

According to the location of the lesion, secondary RCM is divided into myocardial diseases and endocardial diseases.

Myocardial diseases are subclassified as infiltrative, noninfiltrative, and storage disorders. In infiltrative disorders, abnormal deposits occur in the interstitial space, among cardiac amyloidosis (CA) is the most common type of infiltrative disorder. Whereas in storage disorder, deposits accumulated within the cell, such as glycogen storage disorder, hemochromatosis, etc.

Endocardial diseases include drug-induced restrictive cardiomyopathy, hematologic diseases (eq. Sickle cell anemia.), carcinoid, medication-induced (serotonin, ergotamine), and chemotherapy-induced (anthracyclines).

Other rare causes, such as post viral myocarditis<sup>[7]</sup>, diabetic cardiomyopathy mainly describe a restrictive phenotype with concentric LV remodeling and diastolic LV dysfunction<sup>[8]</sup>. Types of muscular dystrophies with cardiac involvement comprises can also behaved as RCM<sup>[7]</sup>.

## PATHOPHYSIOLOGY

### 1. Primary RCM

The pathogenesis of primary RCM is mainly due to the increased sensitivity of muscle filament to calcium and the accumulation of desmin and type III collagen<sup>[9-11]</sup>. Familial cases are commonly manifested AD inheritance with incomplete penetrance.

There are over 20 reported genes were shown to be associated with RCM, but familial RCM caused by single gene defect is the least common. Genes have been discovered to be associated with the primary RCM including troponin (cTnI and cTnT), myosin binding protein C (MyBP-C), myosin light chain 3 (MYL2, MYL3), desmin (DES), myopalladin (MYPN), etc<sup>[12]</sup>.

For the mutation of the genes which encoding sarcomeric proteins and cytoskeletal protein gene led to RCM, it could also cause hypertrophic cardiomyopathy (HCM) or dilated cardiomyopathy (DCM). RCM was often considered as an extreme form of HCM<sup>[13]</sup>. Previous studies have found that confirmed gene mutation rate was only 30% in RCM. In two other smaller scale studies showed the incidence of familial inheritance idiopathic RCM was up to 75%<sup>[14]</sup>, confirmed gene rate was about 54% ~ 60%<sup>[15]</sup>. Specific pathogenic genes are shown in table 1.

### 2. Secondary RCM

#### 2.1. Cardiac amyloidosis (CA)

Cardiac amyloidosis is often caused by a group of diseases resulting by the misfolded protein. The misfolded soluble extracellular proteins and insoluble fibrils deposited in the myocardial tissues, leading to both structural and functional disruptions. Based on the nature of the fibril precursor protein and associated clinical features, CA is divided into 5 different types (Table 2)<sup>[16]</sup>, in which AL and ATTR are closely related to cardiac disorders.

#### 2.1.1 Amyloid light-chain (AL) amyloidosis

AL amyloidosis, also named as primary amyloidosis, is associated with monoclonal gammopathy of undetermined significance or plasma cell dyscrasias, most common in multiple myeloma. Cardiac involvement usually indicated poor prognosis, over half of the

patients developed heart failure in early stage. Even with early chemotherapy, the median survival time of AL amyloidosis patients with HF was less than 6 months<sup>[17]</sup>.

#### 2.1.2 Cardiac Transthyretin Amyloidosis (ATTR)

ATTR is caused by extracellular deposition of amyloid fibrils from liver-derived transthyretin (TTR), including mutant (m-TTR) and wild type (wt-TTR).

**Table 1** Possible pathogenic gene of RCM.

Abbr.	Name	Gene ID
TNNI3	Troponin I3	7137
TNNT2	Troponin T2	7139
TNNC1	Troponin C1	7134
TPM1	Tropomyosin 1	7168
MYL2	Myosin Light Chain 2	4633
MYL3	Myosin Light Chain3	4634
ACTC1	Alpha-cardiac Actin	70
MYBPC3	Myosin Binding Protein C, cardiac	4607
TTN	Titin	7273
DES	Desmin	1674
MYPN	Myopalladin	84665
CryAB	Crystallin Alpha B	1410
BAG3	Bcl-2-Associated Athanogene3	9531
FLNC	Filamin-C	2318
TNN	Tenascin N	63923
SMAD	SMAD Family Member 4	4089
MYH7	Myosin Heavy Chain 7	4625
SYNE2	Spectrin Repeat Containing Nuclear Envelope Protein 2	23224
JUP	Junction Plakoglobin	3728
ACTN2	Actinin Alpha 2	88

**Table 2** Types of Cardiac Amyloidosis.

Type	Precursor Protein	Producing Area	Involved tissue
AL Amyloidosis	Light Chain Fragments	Bone Marrow	Liver, Kidney, Heart, Nervous System, Soft Tissue
M-TTR Amyloidosis	Mutated Transthyretin	Liver	Heart, Nervous System,
Wt-ATTR Amyloidosis (Senile CA)	Wild-type Transthyretin	Liver	Heart
AA Amyloidosis	Serum Amyloid Protein A (SAA)	Stress Reactants	Heart, Kidney, Liver
Isolated Atrial Amyloidosis (IAA)	Atrial Natriuretic Peptide (ANP)	Atrium	Atrium

**Table 3** Other Common Associated Diseases and Genes of Secondary RCM.

Diseases	Mode of Inheritance	Genes
Systemic sclerosis	Multifactorial	PTPN22, MCP-1, IL-1a, IL-10, IL-13, FAS, AIF1, IL13RA2, SPARC, FBN1, TOPOI
Pseudoxanthoma Elasticum	AR	ABCC6
Sarcoidosis	Multifactorial	BTNL2, ANXA11
Gaucher disease	AR	GBA
Hurler disease	AR	IDUA
Glycogen storage disease	Usually AR	G6PC, SLC37A4, NPT4, GAA, AGL, GBE, PYGM, PYGL, PFKM, PBK, PBKPHKA2, PBKPHKB, PHKG2, PBK, PBKPHKA1, PHKA1, PHKG1, GYS2, GYS1
Fabry disease	XR	GLA
Hemochromatosis	AD / AR	HFE, HFE2, HAMP, TFR2 SCL40A1
Hereditary amyloidosis	AD	TTR, CST3, GSN, LYZ, APOA1, APOA2, FGA

(1) Mutant TTR Amyloidosis (m-TTR): m-TTR is a systemic autosomal dominant disorder due to tissue deposition of various proteins, including apolipoproteins A-I and A-II, and TTR. It is often associated with peripheral or autonomic neuropathy. Cardiac involvements are often less aggressive than AL amyloidosis<sup>[18]</sup>.

(2) Wild Type TTR Amyloidosis (wt-TTR). Wild Type TTR Amyloidosis was previously known as senile amyloidosis. Study showed at the autopsy of individuals over 80 years old, about 8% to 16% had cardiac amyloid deposition. Compared with primary amyloidosis, the prognosis of wt-TTR is better, with a median survival time of 6 years<sup>[2]</sup>.

(3) Including AA amyloidosis, atrial associated amyloidosis and apolipoproteins A-I/ A-II associated amyloidosis are less common types of CA. Cardiac amyloid deposition also can occur in isolated atrial and dialysis-related (b2 microglobulin) amyloidosis. Although isolated atrial amyloidosis is associated with development of atrial fibrillation and/or other localized lesions presentation, HF is less common in these types<sup>[19]</sup>.

### 2.1.3 Other types of secondary RCM

Most are gene related. The mode of inheritance depends on the disease and mutant genes<sup>[20]</sup>. The discovered associated genes are shown below on Table 3<sup>[21]</sup>.

## DIAGNOSIS

For patients whose clinical history and physical examination indicating a suspected RCM, ECG and echocardiogram are routine for the evaluation and differential diagnosis. The suspicion of RCM could be supported by various tests of the usual causes; such as the free light chain in serum and urine indicating the diagnosis of CA, hemochromatosis, hypereosinophilia syndrome, etc. Also Cardiac MRI (CMR), biopsy, and genetic screening contribute to the precision diagnosis of RCM, which are particularly important to exclude the secondary causes and establish to optimal regimen. At present stage, genetic diagnosis and treatment of RCM are continuously expanding according to novel mutations. Following paragraphs focused on the preliminary diagnosis and precise diagnosis of RCM. The flow chart is illustrated in figure 1.

### 1. Preliminary Diagnosis

#### 1.1. ECG & UCG

Electrocardiogram (ECG) of RCM patients commonly present with low voltage of limb and left chest leads (V5, V6), pseudo infarction, and poor R wave progression in chest leads.

Echocardiography (UCG) as a routine examination has a great significance, when any of the following manifestations occurred in the absence of other plausible causes, the diagnosis of RCM a highly possible. (1) End-diastolic LV wall thickness greater than 12 mm; (2) Granular sparkling appearance of the myocardium; (3) Increased thickness of atrioventricular valves, right ventricular free wall, or interatrial septum; (4) Pericardial effusion.

In addition, there are different characteristic could be observed in corresponding etiology. Constrictive pericarditis can be seen an atrioventricular septal incisure and a reduce coordination of ventricular movement. In hypertrophic cardiomyopathy, ventricular diastolic compliance decreased and the lesions mainly involving the interventricular septum. Mural thrombi often observe in hypereosinophilia syndrome. However, for patients with ultrasound features suggesting a constricted cardiac disease, results should be combined with other test to investigate etiology and diagnosis.

### 1.2. Cardiac magnetic resonance (CMR)

CMR, with late gadolinium enhancement (LGE) and T1 mapping, is emerging as a reference standard for diagnosis and characterization of cardiac amyloidosis<sup>[22]</sup>, and providing transparent view of disease evaluation and morphological characteristics.

The cardiac structure of RCM is characterized by normal or reduced ventricular volume, normal or slight thickening of ventricular wall thickness, enlarged double chamber and normal pericardium in T1W1 and T2W1 sequences. In sub-endocardial and mid-myocardial, LGE as a characteristic manifestation are indicated the existence of myocardial fibrosis. In typical CA, CMR can show diffuse endocardial LGE, simultaneously involving the all four chambers but the mid-layer does not involve, and intuitively display the CA infiltration area. Study by Ana Martinez-Naharro, *et al*<sup>[23]</sup> support the view that using CMR as typical LGE imaging for cardiac ATTR. Moreover, CMR with extracellular volume fraction (ECV) correlated with amyloid burden was found to be an independent prognostic factor for survival in patients with ATTR.

### 1.3. Others

Radionuclide myocardial imaging (ECT) contributes to diagnose RCM. It has been suggested that the preferential binding to ATTR might be a result of higher calcium content and could be considered a diagnostic standard for ATTR<sup>[22]</sup>.

Cardiac catheterization is not only for the differential and functional diagnosis; the value of evaluating both pre-operative indications and post-operative condition for heart transplantation is major either. By measuring LVEDP as well as other parameters in assessing pulmonary vascular resistance is considered the gold standard for determination of diastolic parameters<sup>[24]</sup>.

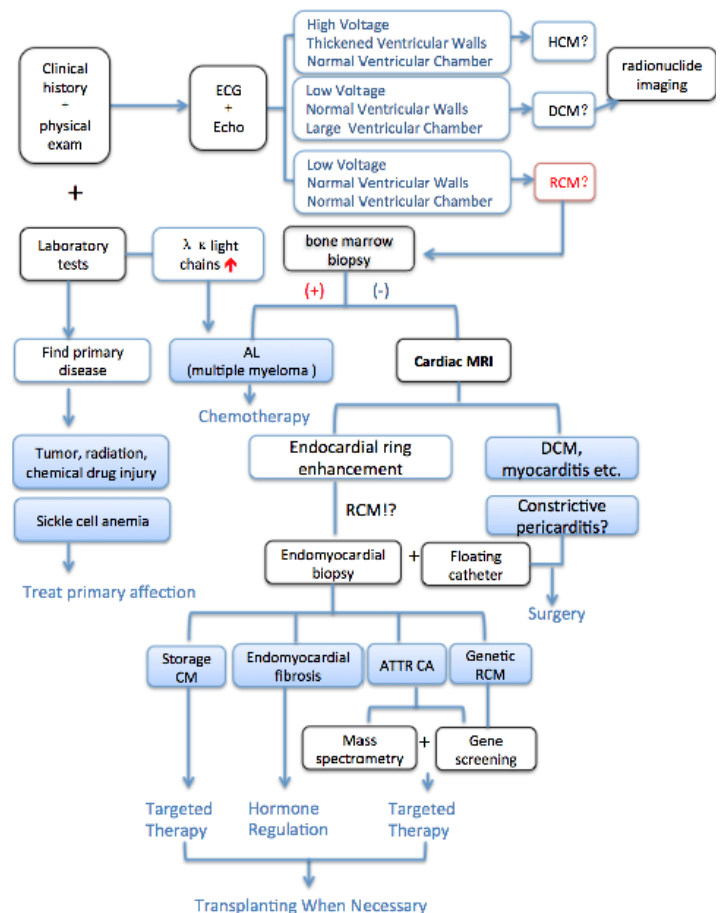


Figure 1 Flow Chart for Diagnosis of RCM.

**Table 4** Differential Diagnosis of Constrictive pericarditis *vs* restrictive cardiomyopathy

Diagnostic evaluation	Constrictive Pericarditis	Restrictive Cardiomyopathy
Physical Findings	Kussmaul sign, pericardial knock	Regurgitant murmur, Kussmaul sign may be present, S3 (advanced).
ECG	Low voltages, non-specific ST/T changes, atrial fibrillation.	Low voltages, pseudoinfarction, possible widening of QRS, left-axis deviation, atrial fibrillation.
Chest X-ray	Pericardial calcifications(1/3 of cases)	No pericardial calcifications.
Echocardiography	Septal bounce.	Small left ventricle with large atria, possible increased wall thickness.
	Pericardial thickening and calcifications.	E/A ratio >2, short DT.
	Respiratory variation of the mitral peak E velocity of >25% and variation in the pulmonary venous peak D flow velocity of >20%	Significant respiratory variations of mitral inflow are absent.
	Colour M-mode flow propagation velocity (Vp)>45 cm/sec.	Colour M-mode flow propagation velocity (Vp) > 45 cm/sec.
	Tissue Doppler: peak e' > 8.0 cm/s.	Tissue Doppler: peak e' < 8.0 cm/s.
Cardiac Catheterization	"Dip and plateau" or "square root" sign, right ventricular diastolic, and left ventricular diastolic pressures usually equal, ventricular interdependence (i.e. assessed by the systolic area index >1.1).	Marked right ventricular systolic hypertension (> 50 mmHg) and left ventricular diastolic pressure exceeds right ventricular diastolic pressure (LVEDP > RVEDP) at rest or during exercise by 5 mmHg or more (RVEDP < 1/3 RVSP).
CT/CMR	pericardial thickness >3-4mm, pericardial calcifications(CT),ventricular interdependence (real-time cine CMR).	Normal pericardial thickness (< 3.0 mm), myocardial involvement by morphology and functional study (CMR).

CMR - cardiac magnetic resonance; CT - computed tomography; DT - deceleration time; ECG - electrocardiogram; LVEDP - left ventricular end-diastolic pressure; RVEDP - right ventricular end-diastolic pressure; RVSP - right ventricular systolic pressure; Systolic Area Index - the ratio of the RV area (mmHg x s) to the LV area (mmHg x s) in inspiration versus expiration.

## 2. Precise Diagnosis

### 2.1. Pathological Diagnosis

Including bone marrow biopsy and endomyocardial biopsy (EMB), pathology evidences are considered the golden standard for the diagnosis of RCM.

Endomyocardial biopsy can achieve nearly 100% sensitivity if minimum of 4 or more samples are obtained during the biopsy procedure<sup>[25]</sup>. It could provide a transparent view of the etiology, therefore EMB should be considered when the pathogenesis of heart failure cannot be determined by noninvasive testing. Especially, when suspecting of infiltrative disease and rare cardiomyopathy, such as suspected hypersensitivity myocarditis, anthracycline cardiomyopathy, cardiac tumors, and arrhythmogenic right ventricular cardiomyopathy (ARVC), etc.<sup>[26]</sup>

However, not all hospitals are eligible for myocardial biopsy. Bone marrow biopsy could use to confirm the diagnosis of amyloidosis; mass spectrometry analysis is further used to identify amyloid type. Rectal, gastrocnemius, labial gland, and fat aspiration biopsy should be used as the secondary choice when myocardial biopsy is not available<sup>[27]</sup>.

### 2.2. Genetic diagnosis

The genetic diagnosis of RCM is recommended in European guidelines (IIB)<sup>[16]</sup>, with the rising consciousness of precise medicine. In the clinical application, it recommends that the etiopathogenesis and diagnosis depend on detected pathogenic mutations in the proband; and for the proband that could not locate the pathogenic mutations but cannot exclude the possibility of genetic disease, the incidence of autosomal dominant pathogenicity was significantly lower than those found in pathogenic mutations. Detection of these 8 target genes: JUP, DES, BAG3, ACTN2, MYH7, TNNT2, TNNI3 and MYBPC3 are recommended<sup>[28]</sup>.

## 3 Antidiastole of Constrictive Pericarditis

Due to the similar clinical features of constrictive pericarditis (CP) and RCM, there is high rate of clinical misdiagnosis and it is important to differentiate them carefully. In developed countries, the most common reported causes of CP respectively were idiopathic or viral, post-radiation therapy, connective tissue disorder, and

post-cardiac surgery<sup>[40]</sup>. On the other hand in developing countries, tuberculosis infection is a major cause besides the above. In addition to the different etiology, other diagnostic evaluation including ECG, echocardiography, cardiac imaging characteristics, and cardiac catheterization could have different presentation which listed below (Table 4, Modified from Imazio *et al*<sup>[41]</sup>).

## TREATMENT

### 1. Primary RCM:

Up to now, heart transplantation is as the one and only effective treatment for RCM. With the improvement of gene engineering technology, the mutation of RCM would provide the basis for precise treatment which needs further clinical trials.

Gene therapy improve the heart function of heart failure by inhibiting the expression of G protein-coupled kinas2 (GRK2) has been succeed<sup>[29]</sup>; which provides new perspectives of the cardiomyopathy treatments. By inhibiting the overexpression of SERCA2a gene to regulate the calcium reserving of the heart, it regulated and controlled the development of heart failure which also might delay the progress of RCM<sup>[30]</sup>.

Gene repairmen or deletion to mutation of primary RCM with viral vector are the future target of therapy, which need further clinical trials to demonstrate it. The gene therapy using adeno-associated virus (AAV) to transform through virus engineering as a carrier has been recognized<sup>[31]</sup>. Further exploration of the usage and mechanisms are needed.

### 2. Secondary RCM:

The treatments of primary disease combine with the basis of the clinical characteristics to build up the optimum therapy for different types are considered in secondary RCM.

For endometrial fibrosis, the treatment is mainly to improve the symptoms of heart failure. Spironolactone is the first choice of diuretic, which can prevent further progression of fibrosis and improve outcomes in addition to the pathophysiological role<sup>[32]</sup>. Surgical resection and atrioventricular valve repair are feasible and could increase survival rate<sup>[33]</sup>.

Bortezomib-based regimens for light chain cardiac amyloidosis



(AL-CA) are now considered to be the preferred treatment option for its near complete remission of plasma cell dyscrasias<sup>[34]</sup>. With early recognition and treatment with targeted plasma cell therapy, AL-CA can be managed effectively. Gene-silencing therapy for amyloidosis has also evolved, such as anti-serum amyloid P (SAP) component, which has experienced preclinical and early clinical success in amyloid deposits scavenging from affected organs<sup>[35]</sup>. For end stage patient, cardiac transplantation combined with chemotherapy or targeted drug therapy could reduce the recurrence.

Clinical trials from the various pathological pathways of reducing amyloid protein production in m-TTR are currently in progress<sup>[36]</sup>, including stabilizing four TTR dimer to interfere protein decomposition to degrade amyloid fiber<sup>[37]</sup>; doxycycline and tauroursodeoxycholic acid; small interfering RNA (siRNA) and monoclonal antibody therapy, etc. Among the above siRNA and ASOS gene suppressor therapy in amyloidosis disease model has one of the most promising aspects. Liver involvement suggests early orthotopic liver transplantation; combined heart-liver transplantation if available, which could reduce cardiac sudden death<sup>[38]</sup>.

Such as eosinophilia, etiological treatment includes corticosteroids and (or) with imatinib, anticoagulant therapy, the treatment of heart failure and end-stage heart transplantation<sup>[39]</sup>.

## PROGNOSIS

The complexity and diversity of RCM etiology make it has worst prognosis of cardiomyopathy. Current staging systems for AL-CA are based on serum levels of NT-pro-BNP, cardiac troponin T, and the concentration of circulating free light chains. The combination of the 3 biomarkers constitutes the most powerful prognostic tool available in AL-CA and is the basis for the staging systems elaborated by the Mayo Clinic. The scoring system assigns 1 point for each of the following: NT-pro-BNP  $\geq 1800$  pg/mL, troponin T  $\geq 0.025$  ng/mL, and difference between the  $\kappa$  and  $\lambda$  free light chains  $\geq 18$  mg/dL. Median survival of stage III patients was only 3.5 to 4.1 months. Patients with pronounced elevations of both NT-pro-BNP and troponin have a particularly poor prognosis<sup>[22]</sup>.

## CONCLUSION

For patients with RCM, the early and accurate diagnosis reflexes a great clinical outcome. Preliminary diagnosis once confirmed cardiomyopathy; for any suspicion of primary RCM patient, known mutation carriers and their family members, genetic screening is necessary. Genetic diagnosis and treatment technique of heart disease are emerging and rising. The genetic diagnosis has a high clinical value for early diagnosis, risk stratification, and prognostic evaluation of RCM patients; while genetic treatment provides a new promising way for RCM patients. Overall, both could provide a significant improvement the prognosis of patients with RCM and needed a further exploration in clinical practices.

## REFERENCE

1. Kubo T, Gimeno JR, Bahl A, Steffensen U, Steffensen M, Osman E, Thaman R, Mogensen J, Elliott PM, [DOI Y, McKenna WJ. Prevalence, clinical significance, and genetic basis of hypertrophic cardiomyopathy with restrictive phenotype. *Journal of the American College of Cardiology* 2007; **49(25)**: 2419-2426. [DOI: 10.1016/j.jacc.2007.02.061]; [PMID: 17599605]
2. Muchtar E, Blauwet LA, Gertz MA. Restrictive cardiomyopathy: genetics, pathogenesis, clinical manifestations, diagnosis, and therapy. *Circ Res* 2017; **121(7)**: 819-837. [DOI: 10.1161/CIRCRESAHA.117.310982]; [PMID: 28912185]
3. Garcia MJ. Constrictive pericarditis versus restrictive cardiomyopathy? *J Am Coll Cardiol* 2016; **67(17)**: 2061-2076. [DOI: 10.1016/j.jacc.2016.01.076]; [PMID: 27126534]
4. Geske JB, Anavekar NS, Nishimura RA, Oh JK, Gersh BJ. Differentiation of constriction and restriction: complex cardiovascular hemodynamics. *J Am Coll Cardiol* 2016; **68(21)**: 2329-2347. [DOI: 10.1016/j.jacc.2016.08.050]; [PMID: 27884252]
5. Malčić I, Jelusić M, Kniewald H, Barišić N, Jelasić D, Bozikov J. Epidemiology of cardiomyopathies in children and adolescents: a retrospective study over the last 10 years. *Cardiol Young*. 2002; **12(3)**: 253-259; [PMID: 12365172]
6. Edwards CQ, Griffen LM, Goldgar D, Drummond C, Skolnick MH, Kushner JP. Prevalence of hemochromatosis among 11,065 presumably healthy blood donors. *N Engl J Med*. 1988; **318**: 1355-1362. [DOI: 10.1056/NEJM198805263182103]; [PMID: 3367936]
7. Jurcuț RO, Bastian A E, Militaru S, Popa A, Manole E, Popescu BA, Tallila J, Popescu BO, Ginghină CD. Discovery of a new mutation in the desmin gene in a young patient with cardiomyopathy and muscular weakness. *Rom J Morphol Embryol*. 2017; **58(1)**: 225-230. [PMID: 28523323]
8. Seferovi PM, Paulus WJ. Clinical diabetic cardiomyopathy: a two-faced disease with restrictive and dilated phenotypes. *European Heart Journal*. 2015; **36(27)**: 1718. [DOI: 10.1093/eurheartj/ehv134]; [PMID: 25888006]
9. Zhang J, Kumar A, Stalker HJ, Viridi G, Ferrans VJ, Horiba K, Fricker FJ, Wallace MR. Clinical and molecular studies of a large family with desmin-associated restrictive cardiomyopathy *Clin Genet*. 2001; **59**: 248-256. [DOI: 10.1034/j.1399-0004.2001.590406.x PMID: 11298680]
10. Davis J, Wen H, Edwards T, Metzger JM. Allele and species dependent contractile defects by restrictive and hypertrophic cardiomyopathy-linked troponin I mutants *J Mol Cell Cardiol*. 2008; **44(5)**: 891-904. [DOI: 10.1016/j.yjmcc.2008.02.274]; [PMID: 18423659]
11. Yumoto F, Lu QW, Morimoto S, Tanaka H, Kono N, Nagata K, Ojima T, Takahashi-Yanaga F, Miwa Y, Sasaguri T, Nishita K, Tanokura M, Ohtsuki I. Drastic Ca<sup>2+</sup> sensitization of myofilament associated with a small structural change in troponin I in inherited restrictive cardiomyopathy. *Biochem Biophys Res Commun*. 2005; **338(3)**: 1519-26. [DOI: 10.1016/j.bbrc.2005.10.116]; [PMID: 16288990]
12. Gu Q, Mendsaikhan U, Khuchua Z, Jones BC, Lu L, Towbin JA, Xu B, Purevjav E. Dissection of Z-disc myopalladin gene network involved in the development of restrictive cardiomyopathy using system genetics approach. *World J Cardiol* 2017; **9(4)**: 320-331. [DOI: 10.4330/wjc.v9.i4.320]; [PMID: 28515850]
13. Hinton RB, Michelfelder EC, Marino BS, Bove KE, Ware SM. A fetus with hypertrophic cardiomyopathy, restrictive, and single-ventricle physiology, and a beta-myosin heavy chain mutation. *Journal of Pediatrics*. 2010; **157(1)**: 164-166. [DOI: 10.1016/j.jpeds.2010.02.044]; [PMID: 20394946]
14. Gallego-Delgado M, Delgado JF, Brossa-Loidi V, Palomo J, Marzoa-Rivas R, Perez-Villa F, Salazar-Mendiguchía J, Ruiz-Cano MJ, Gonzalez-Lopez E, Padron-Barthe L, Bornstein B, Alonso-Pulpon L, Garcia-Pavia P. Idiopathic restrictive cardiomyopathy is primarily a genetic disease. *J Am Coll Cardiol*. 2016; **67(25)**: 3021-3023. [DOI: 10.1016/j.jacc.2016.04.024]; [PMID: 27339502]
15. Kostareva A, Kiselev A, Gudkova A, Frishman G, Ruepp A, Frishman D, Smolina N, Tarnovskaya S, Nilsson D, Zlotina A, Khodyuchenko T, Verzhinina T, Pervunina T, Klyushina A, Kozlenok A, Sjoberg G, Golovljova I, Sejersen T, Shlyakhto E. Genetic spectrum of Idiopathic restrictive cardiomyopathy uncovered by next-generation sequencing. *PLoS One*. 2016;

- 11(9)**: e0163362. [DOI: 10.1371/journal.pone.0163362]; [PMID: 27662471]
16. Ackerman MJ, Priori SG, Willems S, Berul C, Brugada R, Calkins H, Camm AJ, Ellinor PT, Gollob M, Hamilton R, Hershberger RE, Judge DP, Le Marec H, McKenna WJ, Schulze-Bahr E, Semsarian C, Towbin JA, Watkins H, Wilde A, Wolpert C, Zipes DP; Heart Rhythm Society (HRS); European Heart Rhythm Association (EHRA). HRS/EHRA expert consensus statement on the state of genetic testing for the channelopathies and cardiomyopathies: this document was developed as a partnership between the Heart Rhythm Society (HRS) and the European Heart Rhythm Association (EHRA). *Europace*. 2011; **13(8)**: 1077-1109. [DOI: 10.1093/europace/eur245]; [PMID: 21810866]
  17. Sperry BW, Tang WHW. Amyloid heart disease: genetics translated into disease-modifying therapy. *Heart*. 2017; **103(11)**: 812-817. [DOI: 10.1136/heartjnl-2016-309914]; [PMID: 28255101]
  18. Tuzovic M, Yang EH, Baas AS, Depasquale EC, Deng MC, Cruz D, Vorobiof G. Cardiac amyloidosis: diagnosis and treatment strategies. *Curr Oncol Rep*. 2017; **19(7)**: 46. [DOI: 10.1007/s11912-017-0607-4]; [PMID: 28528458]
  19. Röcken C, Peters B, Juenemann G, Saeger W, Klein HU, Huth C, Roessner A, Goette A. Atrial amyloidosis: an arrhythmogenic substrate for persistent atrial fibrillation. *Circulation* 2002; **106**: 2091-7. [DOI: 10.1161/01.CIR.0000034511.06350]; [PMID: 12379579]
  20. Ishibashi-Ueda H, Matsuyama TA, Ohta-Ogo K, Matsuyama TA, Ohta-Ogo K, Ikeda Y. Significance and value of endomyocardial biopsy based on our own experience. *Circ J*. 2017 Mar 24; **81(4)**: 417-426. [DOI: 10.1253/circj. CJ-16-0927]; [PMID: 28331134]
  21. Sen-Chowdhry S, Syrris P, McKenna WJ. Genetics of restrictive cardiomyopathy. *Heart Fail Clin*. 2010 Apr; **6(2)**: 179-86. [DOI: 10.1016/j.hfc.2009.11.005]; [PMID: 20347786]
  22. Elliott P, Comenzo R, Semigran M, Rapezzi C. Addressing common questions encountered in the diagnosis and management of cardiac amyloidosis *Circulation* 2017; **135(14)**: 1357-1377. [DOI: 10.1161/CIRCULATIONAHA.116.024438]; [PMID: 28373528]
  23. Brodehl A, Ferrier RA, Hamilton SJ, Greenway SC, Brundler MA, Yu W, Gibson WT, McKinnon ML, McGillivray B, Alvarez N, Giuffre M, Schwartzentruber; FORGE Canada Consortium, Gerull B. Mutations in FLNC are Associated with Familial Restrictive Cardiomyopathy. *Hum Mutat*. 2016; **37(3)**: 269-279. [DOI: 10.1002/humu.22942]; [PMID: 26666891]
  24. Ryan TD, Madueme PC, Jefferies JL, Michelfelder EC, Towbin JA, Woo JG, Sahay RD, King EC, Brown R, Moore RA, Grenier MA, Goldstein BH. Utility of Echocardiography in the Assessment of Left Ventricular Diastolic Function and Restrictive Physiology in Children and Young Adults with Restrictive Cardiomyopathy: A Comparative Echocardiography-Catheterization Study. *Pediatric Cardiology* 2016; **38(2)**: 1-9. [DOI: 10.1007/s00246-016-1526-0]; [PMID: 27878632]
  25. Pellikka PA, Holmes DR Jr, Edwards WD, Nishimura RA, Tajik AJ, Kyle RA. Endomyocardial biopsy in 30 patients with primary amyloidosis and suspected cardiac involvement. *Arch Intern Med*. 1988; **148(3)**: 662-666; [PMID: 3341867]
  26. Bennett MK, Gilotra NA, Harrington C, Rao S, Dunn JM, Freitag TB, Halushka MK, Russell SD. Evaluation of the role of endomyocardial biopsy in 851 patients with unexplained heart failure from 2000-2009. *Circ Heart Fail*. 2013; **6(4)**: 676-684. [DOI: 10.1161/CIRCHEARTFAILURE.112.000087]; [PMID: 23733916]
  27. Siddiqi OK, Ruberg FL. Challenging the myths of cardiac amyloidosis. *Eur Heart J*. 2017; **38(24)**: 1909-1912. [DOI: 10.1093/eurheartj/ehx210]; [PMID: 28444296]
  28. Sturm AC. Genetic testing in the contemporary diagnosis of cardiomyopathy. *Curr Heart Fail Rep*. 2013; **10(1)**: 63-72. [DOI: 10.1007/s11897-012-0124-6]; [PMID: 23135967]
  29. Cannavo A, Komici K, Bencivenga L, D'Amico ML, Gambino G, Liccardo D, Ferrara N, Rengo G. GRK2 as a therapeutic target for heart failure. *Expert Opin Ther Targets*. 2018 Jan; **22(1)**: 75-83. [DOI: 10.1080/14728222.2018.1406925]; [PMID: 29166798]
  30. del Monte F, Harding SE, Schmidt U, Matsui T, Kang ZB, Dec GW, Gwathmey JK, Rosenzweig A, Hajjar RJ. Restoration of Contractile Function in Isolated Cardiomyocytes From Failing Human Hearts by Gene Transfer of SERCA2a. *Circulation*. 1999; **100(23)**: 2308-2311; [PMID: 10587333]
  31. Mingozzi F, High K A. Therapeutic in vivo gene transfer for genetic disease using AAV: progress and challenges. *Nature Reviews Genetics*. 2011; **12(5)**: 341. [DOI: 10.1038/nrg2988]; [PMID: 21499295]
  32. Beaton A, Mocumbi AO. Diagnosis and management of endomyocardial fibrosis. *Cardiol Clin*. 2017; **35(1)**: 87-98. [DOI: 10.1016/j.ccl.2016.08.005]; [PMID: 27886792]
  33. MacGowan GA. The challenge of radiation-induced restrictive cardiomyopathy and outcomes after heart transplantation. *J Card Fail*. 2016; **22(6)**: 479-480. [DOI: 10.1016/j.cardfail.2016.04.006]; [PMID: 27084525]
  34. Mikhael JR, Schuster SR, Jimenez-Zepeda VH, Bello N, Spong J, Reeder CB, Stewart AK, Bergsagel PL, Fonseca R. Cyclophosphamide-bortezomib-dexamethasone (CyBORd) produces rapid and complete hematologic response in patients with AL amyloidosis *Blood*. 2012; **119**: 4391-4394. [DOI: 10.1182/blood-2011-11-390930]; [PMID: 22331188]
  35. Gertz MA. Immunoglobulin light chain amyloidosis: 2016 update on diagnosis, prognosis, and treatment. *Am J Hematol*. 2016 Sep; **91(9)**: 947-56. [DOI: 10.1002/ajh.24433]; [PMID: 27527836]
  36. Ackermann EJ, Guo S, Booten S, Alvarado L, Benson M, Hughes S, Monia BP. Clinical development of an antisense therapy for the treatment of transthyretin-associated polyneuropathy. *Amyloid*. 2012; **19(Suppl 1)**: 43-44. [DOI: 10.3109/13506129.2012.673140]; [PMID: 22494066]
  37. Sperry BW, Tang WHW. Amyloid heart disease: genetics translated into disease-modifying therapy. *Heart*. 2017; **103(11)**: 812-817. [DOI: 10.1136/heartjnl-2016-309914]; [PMID: 28255101]
  38. Ericzon BG, Wilczek HE, Larsson M, Wijayatunga P, Stangou A, Pena JR, Furtado E, Barroso E, Daniel J, Samuel D, Adam R, Karam V, Poterucha J, Lewis D, Ferraz-Neto BH, Cruz MW, Munar-Ques M, Fabregat J, Ikeda S, Ando Y, Heaton N, Otto G, Suhr O. Liver transplantation for hereditary transthyretin amyloidosis: after 20 years still the best therapeutic alternative? *Transplantation*. 2015; **99(9)**: 1847-1854. [DOI: 10.1097/TP.0000000000000574]; [PMID: 26308415]
  39. Mankad R, Bonnichsen C, Mankad S. Hypereosinophilic syndrome: cardiac diagnosis and management. *Heart*. 2016; **102(2)**: 100-106. [DOI: 10.1136/heartjnl-2015-307959]; [PMID: 26567231]
  40. Adler Y, Charron P, Imazio M, Badano L, Barón-Esquivias G, Bogaert J, Brucato A, Gueret P, Klingel K, Lionis C, Maisch B, Mayosi B, Pavie A, Ristić AD, Sabaté Tenas M, Seferovic P, Swedberg K, Tomkowski W. 2015 ESC Guidelines for the diagnosis and management of pericardial diseases: The Task Force for the Diagnosis and Management of Pericardial Diseases of the European Society of Cardiology (ESC) Endorsed by: The European Association for Cardio-Thoracic Surgery (EACTS). *European Heart Journal*. 2015; **36(42)**: 2921-2964. [DOI: 10.1093/eurheartj/ehv318]
  41. Imazio M, Brucato A, Mayosi BM, Derosa FG, Lestuzzi C, Macor A, Trincheri R, Spodick DH, Adler Y. Medical therapy of pericardial diseases: part II: noninfectious pericarditis, pericardial effusion and constrictive pericarditis. *J Cardiovasc Med (Hagerstown)*. 2010; **11**: 785-794; [PMID: 20925146]