

Aortic-Right Atrial Fistula Diagnosed at Cardiac Rehabilitation Center Early after Ascending Aorta and Aortic Valve Replacement Surgery

Franco Tarro Genta, Francesco Giallauria

Franco Tarro Genta, Fondazione Salvatore Maugeri, IRCCS, Division of Cardiac Rehabilitation, Presidio Major, Turin, Italy

Francesco Giallauria, Department of Translational Medical Sciences, Cardiac Rehabilitation Unit, "Federico II" University of Naples, Naples, Italy

Francesco Giallauria, School of Science and Technology, University of New England, Armidale, NSW 2351, Australia

Correspondence to: Franco Tarro Genta, MD, Presidio Major Via Santa Giulia 60, 10124 Torino, Italy.

Email: franco.tarrogenta@fsm.it

Telephone: +39-0118151611

Fax: +39-01181516308

Received: January 17, 2013

Revised: February 14, 2014

Accepted: February 21, 2014

Published online: March 10, 2014

Tarro Genta F, Giallauria F. Aortic-Right Atrial Fistula Diagnosed at Cardiac Rehabilitation Center Early after Ascending Aorta and Aortic Valve Replacement Surgery. *Journal of Cardiology and Therapy* 2014; 1(2): 37-40 Available from: URL: <http://www.ghrnet.org/index.php/jct/article/view/618>

INTRODUCTION

Aorto-right atrial fistula is a rare complication after aortic valve replacement usually following an early or late aortic prosthetic valve endocarditis^[1-5]. Cardiac rehabilitation (CR) programs has several beneficial effects reducing mortality^[6], preventing cardiac remodelling^[7,8], and improving cardiovascular functional capacity and myocardial perfusion^[9-12]. The improvement of endothelial function^[13], the anti-inflammatory properties^[14,15], and the improvement of neurohormonal and autonomic balance^[16-20] might be some of the putative mechanisms by which exercise training exerts its beneficial effects. A meticulous echocardiography examination is always mandatory^[7,8], even in the absence of surgical complications, when patients are admitted to cardiac rehabilitation after cardiac surgery undergoing supervised training to gain recovery for a safe hospital discharge. We reported a case of aortic-right atrial fistula diagnosed at cardiac rehabilitation center early after ascending aorta and aortic valve replacement surgery where echocardiography was determinant in modifying patient's outcome despite nearly silent clinical and functional findings.

CASE REPORT

A 59-years old asymptomatic physically active man with no cardiovascular risk factors and with history of previous multiple trauma (left foot and left tibia and fibula fracture in 2003) during sports activities (ski), was referred to cardiac surgery after diagnosis of aortic disease characterized by aortic root dilation (50 mm) and ascending aortic aneurysm (52 mm) and moderate aortic regurgitation at echocardiography performed for a routine check-up. Coronary angiography (February 2011) did not show coronary artery disease. On February 15, 2011, the patient underwent cardiac surgery for replacement of the ascending aorta above the sino-tubular junction with woven Dacron vascular prosthesis Intervascular 26, re-implantation of the right coronary artery and aortic valve replacement

ABSTRACT

We reported a case of 59-years old man referred to residential cardiac rehabilitation after complex cardiac surgery (replacement of the ascending aorta above the sino-tubular junction with woven Dacron vascular prosthesis Intervascular 26, re-implantation of the right coronary artery and aortic valve replacement with stented biological prosthesis after diagnosis of aortic disease characterized by aortic root dilation, ascending aortic aneurysm and moderate aortic regurgitation) where echocardiography performed on admission at the rehabilitation setting diagnosed an aorto-right atrial fistula despite a nearly normal clinical and functional assessment. The patient, consequently, underwent a new cardiac surgery with complete recovery. Both echocardiography and a functional assessment was performed at the admission and after one-year follow-up. This case report emphasizes the importance of echocardiography examination after cardiac surgery in cardiac rehabilitation setting, even with the lack of clear clinical, functional or laboratory suspects of infection or in absence of known surgical complications.

© 2014 ACT. All rights reserved.

Key words: Aortic-Right Atrial Fistula; Cardiac Surgery; Echocardiography; Cardiac Rehabilitation

with stented biological prosthesis Carpentier- Edwards Perimount n.25 (Edwards Lifesciences™) (biological valve required by the patient's desire to continue hard mountain sport activity); no adverse outcome after surgery was reported except for the need of 1 unit blood transfusion for mild anemia. Intra-operatively transesophageal echocardiography at the end of surgery did not report anomalies.

Six days after surgery, the patient was admitted to our residential cardiac rehabilitation center. On admission, patient was asymptomatic and only a grade 1/6 systolic continuous murmur over the right sternal border was detected. The day after admission, patient performed a satisfactory submaximal exercise capacity 6 minute walking test (461 m) although fatigue was reported at the end. Biochemistry was good. Transthoracic echocardiography (TTE) (February 22, 2011) showed increased (75mL/m²) left ventricular end diastolic indexed volume (LEDVi), a left ventricle with normal ejection fraction (EF) (59% Simpson biplane mode), normal aortic biological prosthesis function (mean gradient=12 mmHg with minimum intra-prosthesis regurgitation) and normal aortic vascular prosthesis profile. Apical 4 and 5 chambers views showed an abnormal systolic jet, with possible origin from aorta upon bio-prosthesis plane and directed towards the right atrium (Figure 1 Panel B arrow). Such flow, yet not easily quantifiable for its eccentricity, did not seem to determine a significant right atrium and ventricular overload (estimated pulmonary to systemic cardiac output ratio=1.3:1) despite a borderline tricuspid annular plane systolic excursion (TAPSE) (16 mm), elevated pulmonary systolic artery pressure (PAPs) estimation (50 mmHg) and an enlarged right atrium volume (37mL/m²). Transesophageal echocardiography (February 23, 2011) confirmed the presence of shunt between the right sinus of Valsalva and the right atrium (Figure 2 Panel B arrow) with no evidence of endocarditic vegetations.

Aortic angiography (February 28, 2011) showed a fistula between the right sinus of Valsalva and right atrium (Figure 3 arrow). Therefore, the patient underwent the same day a new cardiac surgery; intra-operatively surgeon detected no signs of endocarditis but confirmed a fistula originating in the right sinus of Valsalva below the site of the right coronary artery implantation; patient was then treated with aortic root and biological prosthesis replacement with St. Jude Medical Valved Graft (with mechanical valve component) with reattachment of coronaries (Bentall procedure).

Patient was re-admitted to residential cardiac rehabilitation and completed a 2 weeks training program (daily session of up to 35 W for 30 minutes cycling and 4,5 Km/h for 30 minutes at treadmill) without clinical complication. On admission, 6 minute walking test distance was low (200 m) but it significantly improved at discharge (720 m). TTE (March 8, 2011) showed a non dilated left ventricle (LEDVi=64mL/m²), with normal EF (62%), normal operating parameters of mechanical aortic prosthesis (mean gradient of 18 mmHg with no pathological regurgitation) and normal aortic vascular prosthesis profile. Right ventricular function was preserved and right atrial volume was only slightly improved (TAPSE=17 mm and Right Atrial Volume=30mL/m²). Patient was discharged on March 16, 2011.

At scheduled clinical and echocardiographic evaluation at our cardiac rehabilitation center on January 2012, the patient was in good health status, had re-started sport sessions weekly without reporting any symptoms; 6 minute walking test distance was good (760 m). TTE confirmed non dilated left ventricle (LEDVi=62mL/m²) with normal EF (62% Simpson biplane mode), normal operating parameters of mechanical aortic prosthesis (mean gradient of 15 mmHg with no pathological regurgitation) and normal aortic vascular prosthesis profile. There was a net improvement in right ventricular function (TAPSE=23mm) and right atrial volume (14mL/m²).

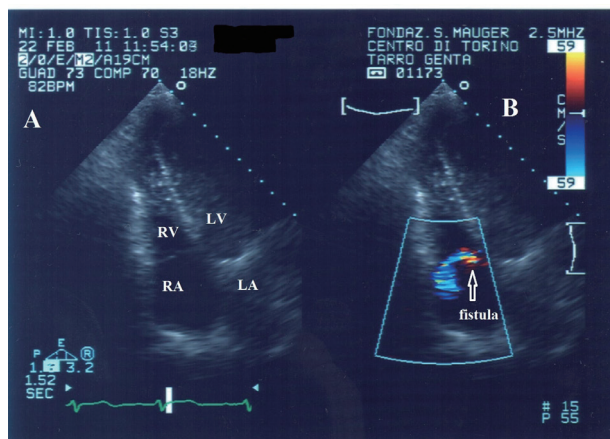


Figure 1 Transthoracic bidimensional (2D-Echo) (panel A) and Color-flow Doppler (panel B) 4 chamber view.

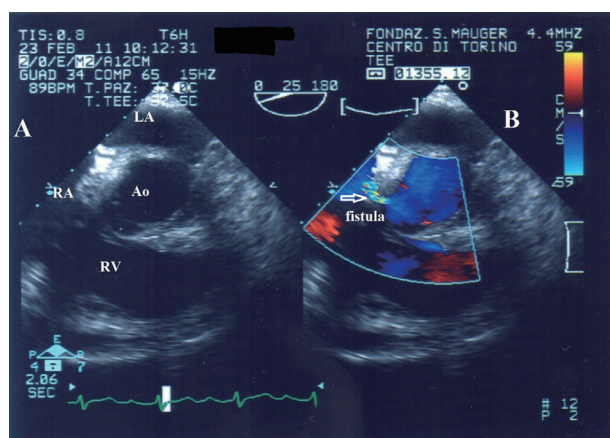


Figure 2 Transesophageal echocardiography mild-oesophageal bidimensional (2D-Echo) (panel A) and Color-flow Doppler (Color 2D-Echo) (panel B) short axis view of aorta upon valve prosthesis.

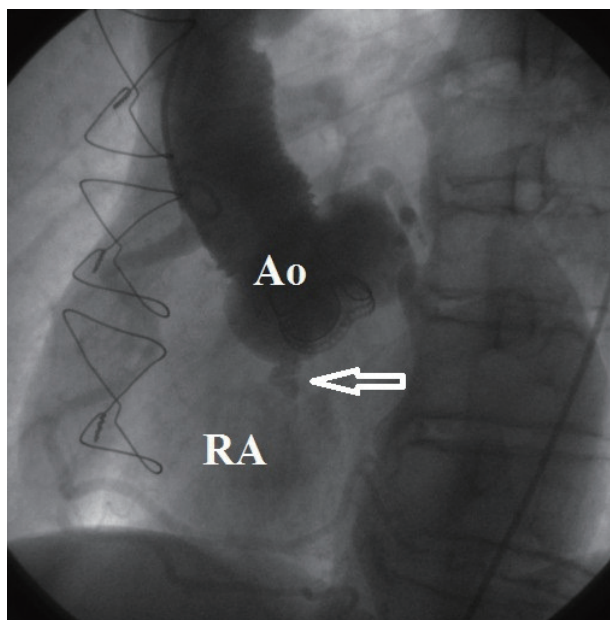


Figure 3 Aortogram in left anterior oblique projection.

DISCUSSION

Aorto-right atrial fistula is a rare condition described in literature occurring after aortic valve replacement^[21,22]. It may usually follow an early or late aortic prosthetic valve endocarditis^[11-5]. Aorto-

right atrial fistula may also be congenital^[23,24], complication of aortic dissection^[25,26], occurring after trans-septal catheterization and catheter ablation for atrial fibrillation^[27,28], or at aortotomy site following surgical myectomy^[29]. Interestingly, it has been recently reported a case of aorto-right atrial fistula secondary to rupture of an occluded old saphenous venous graft to right coronary artery^[30]. In only one case, aorto-right atrial fistula in the post-operative period was not consequence of the above mentioned mechanisms and a traumatic tear or damage due to aggressive decalcification near the suture was speculated^[31]. In the present case, none of the above reported mechanisms were confirmed; the young age of the patient and the absence of aortic stenosis were consistent with the absence of significant aortic annular calcifications. Despite a clear pathophysiological mechanism for the reported fistula has not been clarified in the operative record, we speculated that a minimal tear at the first operation occurred for the need of re-implantation of the right coronary artery. This could be trivial at the hemodynamic test performed at the end of first operation and not clearly detectable or detected by an intra-operatively transesophageal echocardiography. Intra-aortic high pressure may then have promoted the progression of tear toward the right atrium anatomically strictly close to this aortic region. The small size probably accounted for the mild symptoms and clinical signs recorded of the aorto-right atrial fistula at the admission to residential cardiac rehabilitation.

The present case emphasizes the importance of echocardiographic screening in patients with cardiac disease referred to rehabilitation setting; it should be performed before discharge by the cardiac centre in case of referral to non-cardiac rehabilitation programs (as could happen with very old patients or patient with neurological disease complicating cardiac surgery and referred to geriatric or neurological rehabilitation) because difficulty in availability of diagnostic methods in such setting could let these patients be involved in the rehabilitation program with potential life-threatening consequences.

In conclusion, echocardiographic assessment at admission to cardiac rehabilitation setting after surgical valve intervention is strongly recommended even if clear clinical, functional or laboratory suspect of infection or known surgical complications are lacking. The role of transesophageal echocardiography and Doppler color-flow imaging is paramount for the definitive diagnosis and detection of the fistula. Three-dimensional transthoracic echocardiography is emerging as new technique for the detection of the fistula^[32]. Correction of aorto-right atrial fistula may be performed by traditional surgery although percutaneous repair could represent an optional technique^[33].

CONFLICT OF INTERESTS

There are no conflicts of interest with regard to the present study.

REFERENCES

- 1 Gunarathne A, Hunt J, Gershlick A. Aorto-right atrial and right ventricular fistulae: a very rare complication of native bicuspid aortic valve endocarditis. *Heart* 2013; **99**(22): 1708
- 2 Candan O, Gecmen C, Guler A, Karabay CY, Aung SM, Agus HZ, Sonmez K. Aorto-right atrial fistula secondary to infective endocarditis presenting with cardiogenic shock. *J Cardiovasc Med (Hagerstown)* 2012; **13**(1): 65-67
- 3 Rohnera A, Bernheimb A, Busera P, Kaufmanna B, Kessel-Schaefera A. Aorto-right atrial fistula due to complicated prosthetic valve endocarditis. *Cardiovascular Medicine* 2010; **13**(11): 350-351
- 4 Ozer N, Deniz A, Atalar E, Aksoyek S, Ovunc K, Kes SS. Aorta-Right Atrial Fistula: A Rare Complication of Prosthetic Aortic Valvular Endocarditis. *J Am Soc Echocardiogr* 2007; **20**: 538.e5-e6
- 5 Ten Morro F, Miró Palau V, Osa Sáez AM, Osa Asensi J, Quesada Carmona A, Morillas Blasco P. A right aorto-atrial fistula as a complication of early prosthetic endocarditis. *Rev Esp Cardiol* 1999; **52**: 1022-1024
- 6 Rauch B, Riemer T, Schwaab B, Schneider S, Diller F, Gohlke H, Schiele R, Katus H, Gitt A, Seneges J; for the OMEGA study group. Short-term comprehensive cardiac rehabilitation after AMI is associated with reduced 1-year mortality: results from the OMEGA study. *Eur J Prev Cardiol* 2013 Apr 4. [Epub ahead of print]
- 7 Giallauria F, Cirillo P, Lucci R, Pacileo M, De Lorenzo A, D'Agostino M, et al. Left ventricular remodeling in patients with moderate systolic dysfunction after myocardial infarction: favorable effects of exercise training and predictive role of N-terminal pro-brain natriuretic peptide. *Eur J Cardiovasc Prev Rehabil* 2008; **15**: 113-118
- 8 Giallauria F, Galizia G, Lucci R, D'Agostino M, Vitelli A, Maresca L, et al. Favorable effects of exercise-based cardiac rehabilitation after acute myocardial infarction on left atrial remodeling. *Int J Cardiol* 2009; **136**: 300-306
- 9 Giallauria F, Lucci R, D'Agostino M, Vitelli A, Maresca L, Mancini M, et al. Two year multi-comprehensive secondary prevention program: favourable effects on cardiovascular functional capacity and coronary risk profile after acute myocardial infarction. *J Cardiovasc Med (Hagerstown)* 2009; **10**: 772-780.
- 10 Giannuzzi P, Temporelli PL, Marchioli R, Maggioni AP, Bal-estroni G, Ceci V, Chieffo C, Gattone M, Griffo R, Sweiger C, Tavazzi L, Urbinati S, Valagussa F, Vanuzzo D, for the GOSPEL Investigators. Global Secondary Prevention Strategies to Limit Event Recurrence after Myocardial Infarction. *Arch Intern Med* 2008; **168**(20): 2194-2204
- 11 Giallauria F, Acampa W, Ricci F, Vitelli A, Maresca L, Mancini M, Grieco A, Gallicchio R, Xhoxhi E, Spinelli L, Cuocolo A, Vigorito C. Effects of exercise training started within 2 weeks after acute myocardial infarction on myocardial perfusion and left ventricular function: a gated SPECT imaging study. *Eur J Prev Cardiol* 2012; **19**: 1410-1419
- 12 Giallauria F, Acampa W, Ricci F, Vitelli A, Torella G, Lucci R, Del Prete G, Zampella E, Assante R, Rengo G, Leosco D, Cuocolo A, Vigorito C. Exercise training early after acute myocardial infarction reduces stress-induced hypoperfusion and improves left ventricular function. *Eur J Nucl Med Mol Imaging* 2013; **40**: 315-24
- 13 Tarro Genta F, Eleuteri E, Temporelli PL, Comazzi F, Tidu M, Bouslenko Z, Bertolin F, Vigorito C, Giannuzzi P, Giallauria F. Flow-mediated dilation normalization predicts outcome in chronic heart failure patients. *J Cardiac Fail* 2013; **19**: 260-267
- 14 Giallauria F, Cirillo P, D'agostino M, Petrillo G, Vitelli A, Pacileo M, et al. Effects of exercise training on high-mobility group box-1 levels after acute myocardial infarction. *J Card Fail* 2011; **17**: 108-14
- 15 Cirillo P, Giallauria F, Pacileo M, Petrillo G, D'Agostino M, Vigorito C, Chiariello M. Increased High Mobility Group Box-1 Protein levels are associated with impaired cardiopulmonary and echocardiographic findings after acute myocardial infarction. *J Card Fail* 2009; **15**(4): 362-367
- 16 Giallauria F, De Lorenzo A, Pilerici F, Manakos A, Lucci R, Psaroudaki M, et al. Long-Term Effects of Cardiac Rehabilitation on End-Exercise Heart Rate Recovery after Myocardial Infarction. *Eur J Cardiovasc Prev Rehabil* 2006; **13**: 544-550
- 17 Giallauria F, Lucci R, Pietrosante M, De Lorenzo A, Gargiulo G, D'Agostino M, Gerundo G, Abete P, Rengo F, Vigorito C. Exercise-based Cardiac Rehabilitation improves Heart

- Rate Recovery in Elderly Patients after Acute Myocardial Infarction. *J Gerontol Ser A-Biol Sci Med Sci.* 2006;61:713-7.
- 18 Giallauria F, De Lorenzo A, Pileri F, Manakos A, Lucci R, Psaroudaki M, et al. Reduction of NT-pro-BNP levels with exercise-based cardiac rehabilitation in patients with left ventricular dysfunction after myocardial infarction. *Eur J Cardiovasc Prev Rehabil* 2006; **13**: 625-632
 - 19 Giallauria F, Lucci R, De Lorenzo A, D'Agostino M, Del Forno D, Vigorito C. Favourable effects of exercise training on N-terminal pro-brain natriuretic peptide plasma levels in elderly patients after acute myocardial infarction. *Age Ageing* 2006; **35**: 601-607
 - 20 Smart N, Meyer T, Butterfield J, Faddy S, Passino C, Malfatto G, et al. Individual patient meta-analysis of exercise training effects on systemic brain natriuretic peptide expression in heart failure. *Eur J Prev Cardiol* 2012; **19**: 428-435
 - 21 Najib MQ, Ng D, Vinales KL, Chaliki HP. Aorto-right ventricular fistula: a complication of aortic valve replacement. *Ann Thorac Cardiovasc Surg* 2012; **18**(1): 64-67
 - 22 Menon PR, Doenst T, Ender J, Mohr FW, Mathioudakis D. Surgical treatment of an aorto-right atrial fistula as a complication of tricuspid valve repair. *Thorac Cardiovasc Surg* 2011; **59**(4): 250-252
 - 23 Alozie A, Kische S, Kaminski A, Ince H. Aorto-right atrial shunt due to perforated sinus of valsalva aneurysm in a young athlete: a rare congenital defect confirmed by various non-invasive imaging modalities. *Eur Heart J* 2012; **33**(1): 138
 - 24 Akar R, Sirlak M, Eyileten Z, Tas_oz R, Ozyurda U. Aortico-cameral communication from right sinus of valsalva to right atrium. *J Ank Univ Fac Med* 2006; **59**: 73-76
 - 25 Frank MW, Stout MJ. Acute aortic dissection with an aorta-right atrium fistula. *Tex Heart Inst J* 2003; **30**: 335-336
 - 26 Nakano H, Takahara Y, Sudou Y, Shioiri M, Nakajima N. Aortic dissection complicated with aorto-right atrium fistula. *Jpn J Thorac Cardiovasc Surg* 2000; **48**(8): 531-533
 - 27 Tsang MY, Hagler DJ, Dearani JA, Rihal CS, Anavekar NS. Aorto-right atrial fistula: a rare complication of trans-septal puncture and catheter ablation for atrial fibrillation. *Eur Heart J Cardiovasc Imaging* 2014; **15**(1): 115
 - 28 Aligeti VR, South HL, Hirsh JB, Wortham DC. Aorto-right atrial fistula following transseptal catheterization and catheter ablation for atrial fibrillation. *J Cardiovasc Electrophysiol* 2012; **23**(6): 659-661
 - 29 Kalra A, Kohl LP, Asinger RW, Bachour FA, Van Camp JR, Ayenew W, Bart BA. Aorto-right atrial fistula at aortotomy site following surgical myectomy. *Echocardiography* 2013; **30**(9): E300-1
 - 30 Balestrini CS, Saaibi JF, Ortiz SN. Aorto - right atrial fistula secondary to rupture of an occluded old saphenous venous graft to right coronary artery. *Catheter Cardiovasc Interv* 2013 Feb **13**. doi: 10.1002/ccd.24859. [Epub ahead of print]
 - 31 Badak O, Akdeniz B, Aslan O, Kirimli O, Göldeli O, Güneri S. Rare complication of aortic valve replacement: aorto-right atrial fistula. *Anadolu Kardiyol Derg* 2003; **3**(4): 373
 - 32 Patel V, Fountain A, Guglin M, Nanda NC. Three-dimensional Transthoracic echocardiography in identification of aorto-right atrial fistula and aorto-right ventricular fistulas. *Echocardiography* 2010; **27**(9): E105-8.
 - 33 Eng MH, Garcia JA, Hansgen A, Chan KC, Carroll JD. Percutaneous closure of a para-prosthetic aorto-right ventricular fistula. *Int J Cardiol* 2007; **118**(2): e31-4.

Peer reviewer: Thomas Strecker, Herzchirurgische Klinik, Universitätsklinikum Erlangen, Krankenhausstraße 12, 91054 Erlangen, Germany.