

## Diastolic Handgrip Stress Test Using an External Pressure Transducer: on the road for a New Initial Screening Test for Preclinical Coronary Artery Disease?

Jan Manolas

Jan Manolas, Department of Check Up, Diagnostic and Therapeutic Center of Athens, HYGEIA hospital, Erythrou Stavrou 4 and Kifissias Ave., Maroussi, Athens 151 23, Greece

Correspondence to: Jan Manolas, MD, PhD, Department of Check Up, Diagnostic and Therapeutic Center of Athens, HYGEIA hospital, Erythrou Stavrou 4 and Kifissias Ave., Maroussi, Athens 151 23, Greece.

Email: [diastolicstresstest@gmail.com](mailto:diastolicstresstest@gmail.com)

Telephone: +30-6936 718444

Received: February 2, 2014

Revised: April 19, 2014

Accepted: April 26, 2014

Published online: June 10, 2014

for Preclinical Coronary Artery Disease? *Journal of Cardiology and Therapy* 2014; 1(5): 102-107 Available from: URL: <http://www.ghrnet.org/index.php/jct/article/view/713>

### INTRODUCTION

Although numerous sophisticated techniques are now available and are widely applied for diagnosing and following up patients with coronary artery disease (CAD), the initial screening for asymptomatic/subclinical CAD represents still today one of the greatest diagnostic problems worldwide. Despite our numerous highly developed diagnostic tools, more than 60% of those hospitalized with acute coronary syndrome or dying suddenly have not been identified before these tragic events<sup>[1]</sup>. There are many factors contributing to this obviously existing screening failure in identifying patients with “silent CAD”.

First, “healthy feeling-and-looking” persons are not usually coming to us in tertiary Hospitals for being examined by our experts using sophisticated diagnostic techniques. Second, most of our modern noninvasive methods are often neither sufficiently cost-effective nor appropriate for applying them for screening asymptomatic intermediate or low risk persons representing the greatest part of CAD patients. Third, all combinations of our current expertize needing tools have been proved in some more recent extensive and thorough studies to have a too low average sensitivity (<70%) and an unacceptable low average specificity (<50%)<sup>[2-4]</sup>. For all these reasons, the identification of most persons with potential subclinical CAD is still today failing both in our hospitals and in private practice in the early asymptomatic stage.

We should, therefore, realize that by developing further only our sophisticated noninvasive techniques being useful for evaluating patients with known CAD, we cannot improve our initial screening ability. What is still needed for improving our screening for “silent CAD” and prevent early enough its progression, is to develop simple, fast, not expertize needing and widely applicable techniques that might be applied widely as screening tools. In general, a suitable screening test should have a proved firm pathophysiologic basis and also be safe and convenient for any patient and, therefore, widely applicable above out-of-hospitals. Specifically in CAD, we know now that physiologically as well as for the management of CAD patients, the degree of flow-limitation and inducible ischemia are of

### ABSTRACT

The initial screening of asymptomatic coronary artery disease (CAD) can be done mainly out of hospitals, where sophisticated techniques cannot and should not be applied widely. This great diagnostic problem could be potentially solved by applying widely a diastolic handgrip stress test by placing an external pressure transducer over the left ventricular (LV) impulse transthoracically and recording a pressocardiogram (Presso Test). Pressocardiogram reflects in time, slope and pulse amplitude LV pressure curve at rest and exercise and some diastolic indexes correlate significantly with corresponding standard diastolic measures of LV pressure. During handgrip, above the pressocardiographic A wave shows in CAD a dramatic increase that corresponds the dramatic rise in LV end-diastolic and atrial pressures in presence of induced ischemia. A high prevalence of these typical and exactly definable “ischemic diastolic changes” have been found in patients with or without symptoms who subsequently showed in angiography significant or non-obstructive CAD. Thus, Presso Test could become a useful diagnostic tool for indentifying even asymptomatic patients in daily practice.

© 2014 ACT. All rights reserved.

**Key words:** Coronary Artery Diseases; Diastolic function; Diastolic Stress Test; Isometric Handgrip Exercise; Left ventricular Function

Manolas J. Diastolic Handgrip Stress Test Using an External Pressure Transducer: On the road for a New Initial Screening Test

greater clinical importance than the degree of anatomic stenosis per se. Consequently, an ideal screening tool for CAD should be a safe, fast and low level exercise modality for detecting latent exercise-inducible ischemia before applying more sophisticated diagnostic “anatomic” techniques – like coronary artery calcification or computer tomographic angiography.

### ISOMETRIC HANDGRIP EXERCISE AND LV PRESSURE DIASTOLIC CHANGES

The most widely applied exercise modality is dynamic exercise using bicycle or treadmill, which cannot be performed by every subject due to obesity or physical disability or even lack of desire. A low level handgrip exercise testing could represent an almost ideal exercise mode, especially in the out-of-hospital setting. Above, a low level (40% of maximal voluntary contraction) and short (2 min) isometric handgrip exercise represents a fast, safe and most convenient for everyone exercise testing<sup>[5-8]</sup>.

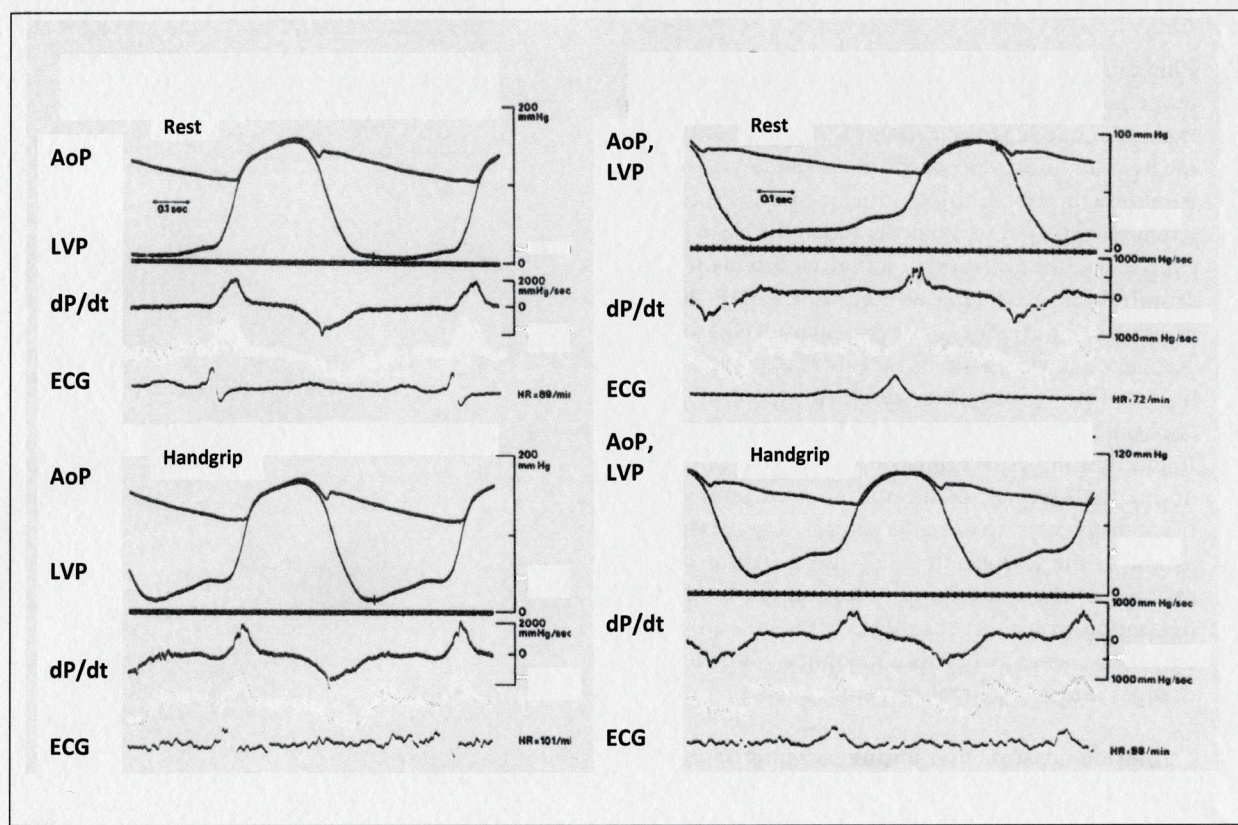
However, this short and safe exercise mode has hitherto neither further explored nor widely applied in clinical practice. The most probable cause is that it represents a too short and low level exercise with significantly less heart rate and blood pressure increase, which is obviously not sufficient for producing detectable ischemic ECG changes or specific echocardiographic abnormalities. On the other hand, it has been shown that low level handgrip exercise is associated with significant and early occurring LV pressure (LVP) curve diastolic changes – above a dramatic LV end-diastolic pressure (LVEDP) rise in CAD as well as in several other cardiovascular

disease states<sup>[5-8]</sup>. Interestingly, this slight handgrip test has been shown to induce in CAD patients significant endothelial dysfunction and great vasospasm diagnosed angiographically in significantly stenosed coronary arteries<sup>[8]</sup> as well as ischemia even in non-significant CAD<sup>[9,10]</sup>.

However, Krayenbuehl<sup>[6]</sup> has found a great handgrip-induced LVEDP rise also in patients with severe aortic stenosis or non-obstructive hypertrophic cardiomyopathy at 36% and 60% from baseline value, respectively. In CAD patients without associated valvular disease, LVEDP increased at 38% over the baseline value<sup>[6]</sup>. Interestingly, this characteristic LVEDP rise was not associated with any ECG changes or symptoms, which all occurred in later phases.

### ISCHEMIC DIASTOLIC CHANGES OF LVP CURVE

In absence of structural cardiac disease, Krayenbuehl<sup>[6]</sup> found a dramatic average LVEDP rise from 16mmHg to 22 mmHg (38% of rest value) and Brown *et al*<sup>[8]</sup> from 15mmHg to 24 mmHg (60% increase from baseline). Interestingly, Flessas *et al*<sup>[7]</sup> found that an increase of LVEDP from 14 to 23 mmHg (64% of rest value) was associated with new wall motion abnormalities in those patients without collateral vessels. Similar significant LVP abnormalities in end and also in early (relaxation) diastole have also been found in presence of angina pectoris with dynamic exercise<sup>[11]</sup>. We termed these characteristic for the presence of CAD high-magnitude diastolic LVP abnormalities in absence of ECG or systolic or volumetric changes an “ischemic diastolic response”<sup>[12]</sup>. Figure 1 left panel,



**Figure 1** Left ventricular (LVP) and aortic (AoP) pressures at Rest and during 2 min of 40% isometric handgrip exercise in a patient with CAD showing an “ischemic diastolic response” (left panel) and a patient with non-obstructive hypertrophic cardiomyopathy showing a “non-ischemic diastolic response” (right panel). Left Ventricular end-diastolic pressure (LVEDP) increases in the former from 14 to 38 Hg (171%) and in the latter from 27 to 43mmHg (59%); dP/dt: first time derivative of LVP; ECG: electrocardiogram (modified from Manolas J, *Hel J Cardiol* 1994).

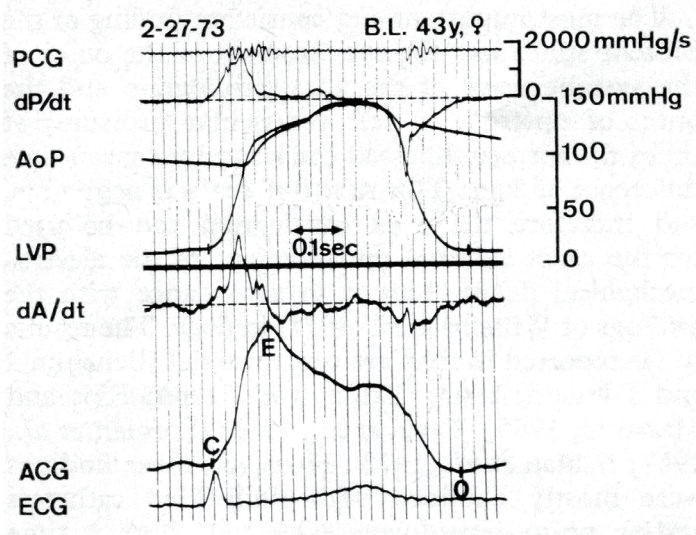
shows the diastolic LVP curve changes in a patient with significant 1 vessel CAD with a dramatic handgrip-induced increase of LVEDP from 14 to 38mmHg (171% rise from baseline value) without ECG changes. In contrast, figure 1 right panel shows that in a patient with non-obstructive hypertrophic cardiomyopathy and dyspnea on effort, the LVEDP was already at rest increased and raised further from 27 to 43 mmHg (59% of rest value); whereas this significant end-diastolic change could also be partly induced by structural changes within the LV wall –like myocardial disarray and fibrosis, in presence of normal coronary arteries.

We have postulated that a noninvasive technique that could accurately detect these dramatic and characteristic handgrip-induced ischemic LVP changes in diastole, might be helpful for improving the initial screening patients without or with only atypical symptoms with inducible ischemia, especially those without any structural cardiac disease<sup>[12]</sup>.

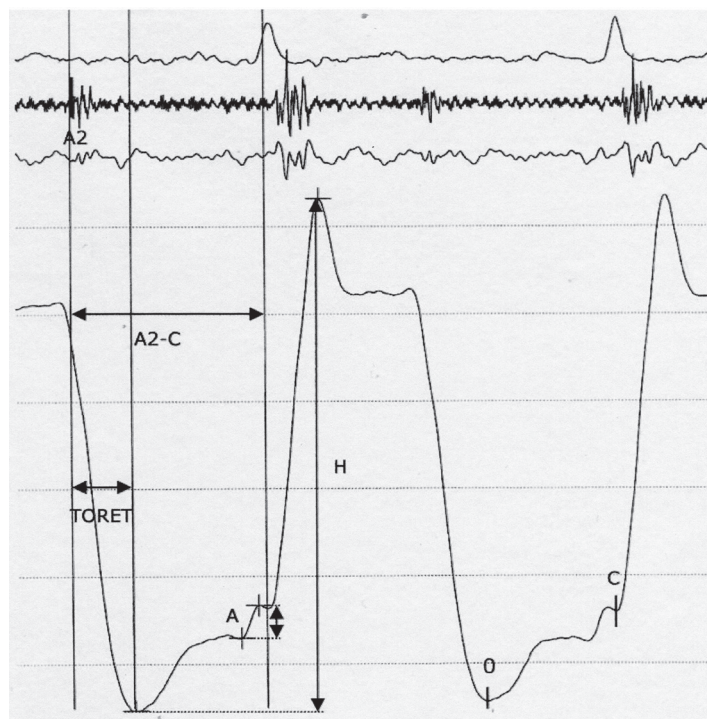
### USE OF PRESSOCARDIOGRAPHY FOR ESTIMATING LVP DIASTOLIC CHANGES

It has been proved that recordings obtained by an optimal external “pulse”-pressure transducer placed on the thorax over the maximal left ventricular (LV) pulse reflects in time and slope and “pulse” amplitude at rest<sup>[13-18]</sup> (Figure 2) and with exercise<sup>[19-21]</sup> to corresponding LV pressure curve diastolic changes. Figure 2 shows the similarity in slopes and coincidence of onset of systolic rise (C point) with the corresponding onset of LVP rise and pressocardiogram as well as mostly also of lowest point of pressure decay of the LV curve in early diastole. Further, the 1st time derivatives of both curves are very similar.

Alternatively, the relative A wave to total pressocardiographic height (A/H) (Figure 3) has been found to correlate with LVEDP and left atrial pressure as well as specific LV stiffness measures at rest<sup>[15-18]</sup> as well as with exercise<sup>[19-21]</sup>. Moreover, the total relaxation time (TORET) measured from the aortic valve closure to lowest point



**Figure 2** Simultaneous high-fidelity recordings of LV and aortic Pressures as well as of pressocardiogram and their 1st time derivatives from a healthy subject. The onset of rising of both curves are identical, whereas the lowest point (O) of pressocardiogram precedes slightly the corresponding point of LVP curve. The derivatives are formally very similar, but the curves differ significantly during the ejection phase. the ACG = (Apex) pressocardiogram; dA/dt = 1st time derivative of pressocardiogram; PCG = phonocardiogram (modified from Manolas et al, Br Heart J 1975).



**Figure 3** Definition of pressocardiographic diastolic indexes in a healthy subject. A = Atrial wave of pressocardiogram; A2-C = diastolic length; H= total pressocardiographic height; TORET = total relaxation time measured from the onset of 2nd heart sound in the PCG to the lowest diastolic nadir of pressocardiogram. Other abbreviations as in figure 2.

of these pressure transducer-derived recordings as well as TORET corrected for diastolic length-termed TORET index (TORETI)- have been shown to correlate significantly with invasive LV relaxation measures<sup>[14,18]</sup>. Thus, the term “pressocardiogram” reflects better than the older term “apex- or vibro-cardiogram” the true genesis of these tracings, which do not represent just some “precordial vibrations” or are obtained from the apical part of the LV pulse of the heart -but from the middle part of the left ventricle<sup>[22]</sup>.

### PRESSOCARDIOGRAPHY DURING HANDGRIP EXERCISE

Figure 4 demonstrates the first recordings of Presso test in 1985 in an office in Athens, Greece; whereas the A/H shows a more than double increase from baseline with 2 min handgrip exercise in a patient with atypical symptoms, who has subsequently shown in angiography a significant stenosis in left coronary artery.

In a group of healthy subjects, we could define for the 1st time the normal limits of pressocardiographic diastolic changes and the “positivity criteria” of this “handgrip pressocardiographic stress test” - now termed Presso Tes<sup>[23]</sup>. These positivity criteria show a high sensitivity and normalcy in patients with myocardial disease. Subjects without evidence of cardiovascular diseases showed no or only slight changes in diastole within these normal limits (Figure 5) and patients with significant CAD with or without symptoms showed a typical dramatic increase in the A/H ratio (Figure 6) or an absolute (TORET) and relative prolonged relaxation time (TORETI) (Figure 7) or both<sup>[23-27]</sup>. The Presso Test’s definitions and criteria have been included in the guidelines of European Society of Cardiology<sup>[28]</sup>.

Most importantly, by comparing the LV diastolic behaviour as assessed by Presso Test in patients with CAD without prior myocardial infarction with those with hypertrophic cardiomyopathy,

we could for the 1st time define exact differentiation criteria separating an “ischemic” from a “non-ischemic” diastolic pattern with isometric exercise<sup>[26]</sup>.

The high-magnitude of the handgrip-induced pressocardiographic diastolic changes-above of at end-diastole were very similar-if not identical-with those found in cath lab using micromanometer in left ventricle in CAD patients with inducible ischemia. Specifically, in outpatients without myocardial infarction and without drugs, a high-magnitude increase of A/H has been found at 67-100% over the baseline value within just 1 to 2 minutes of a 2 min low level isometric handgrip exercise<sup>[23-26]</sup>. It should also be emphasized that when compared with the A wave changes<sup>[19-21,23-27]</sup>, an impaired relaxation - defined by TORET prolongation and/or TORETI decrease - was less pronounced than the A/H increase, ranging from 16 to 22% of baseline value<sup>[23-27]</sup>.

The prevalence of an “ischemic pattern” has been shown to be higher in outpatients<sup>[26]</sup> than in hospitalized patients with CAD without prior infarction<sup>[27]</sup>. This could be caused by a decrease in adrenalin secretion with handgrip due to bed rest as well as medical treatment in the latter<sup>[27]</sup>. Further, hospitalized patients with prior myocardial infarction showed less frequently an ischemic diastolic response than those without (52% vs 61%, respectively)<sup>[27]</sup>; this could be explained by the fact that necrotic and scared “non-viable” myocardial tissue is not producing a significantly increase of exercise-induced “ischemic LV stiffness”.

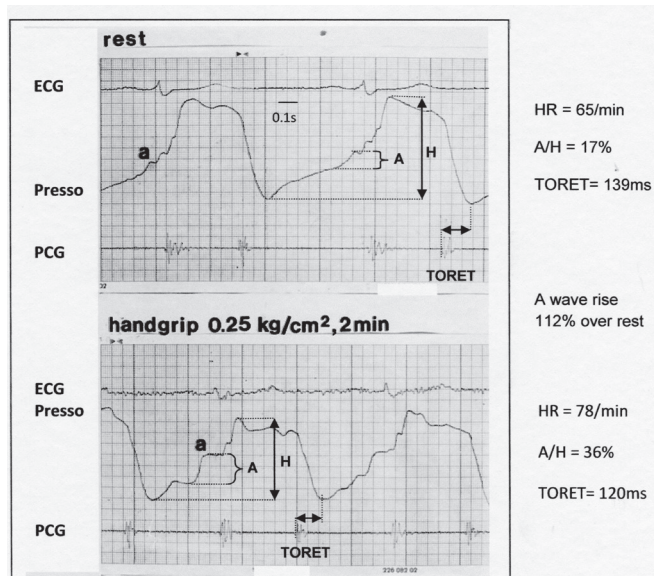
An handgrip-induced ischemic diastolic response, as assessed by Presso Test, has been found to occur less often in hypertension or cardiomyopathies<sup>[29,30]</sup>. In these patients, an ischemia can be the result of structural changes within the LV wall associated with fibrosis or myocardial disarray as well as endothelial dysfunction or microvascular disease.

## CONCLUSIONS

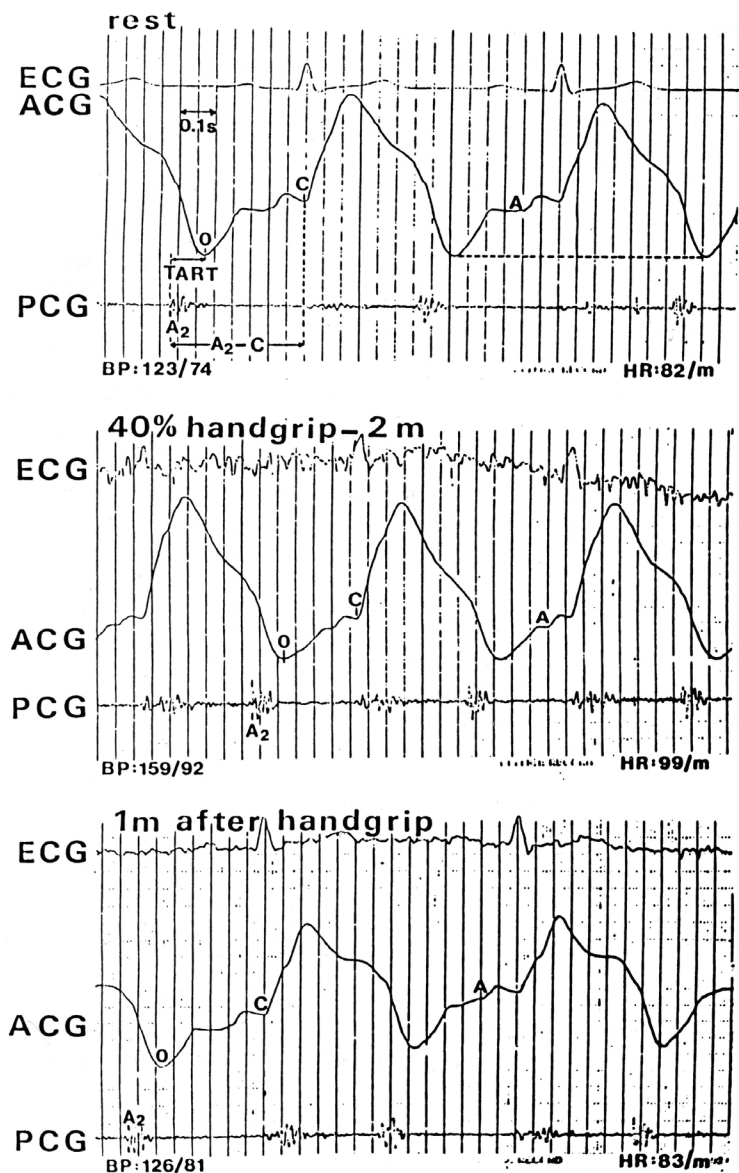
According to findings in catheterization studies using identical micromanometers in and over the left ventricle for obtaining high-

fidelity pressure and pulse-pressure recordings, respectively, it has been shown that the latter - termed pressocardiograms- reflect diastolic changes of the LVP curve in time and amplitude, both at rest and exercise.

The dramatic diastolic LVP changes –above in end-diastole- that have been found in presence of induced ischemia in CAD patients correspond to those high-magnitude diastolic changes –above of A wave- of pressocardiogram found with short/low level isometric handgrip exercise in CAD patients. Thus, in absence of other non-CAD structural diseases-like cardiomyopathies or aortic valvular diseases, handgrip-pressocardiographic stress test might become useful as a complementary diagnostic modality -above in out-of-hospital setting- for identifying those patients, who potentially suffer from subclinical/silent CAD. This simple and safe stress test might serve somehow as a “Pre-test” for separating those patients who might need more sophisticated and expertize diagnostic techniques.



**Figure 4** The 1<sup>st</sup> recordings of presso- and phonocardiogram during low level isometric handgrip exercise –termed Presso Test- in a patient with atypical angina, who subsequently has been catheterized and showed CAD. The A/H index shows during handgrip an increase of 112% over the rest value associated with a shortening of TORET corresponding the heart rate increase and no ECG changes.



**Figure 5** Presso Test in a healthy volunteer. The relative A wave amplitude and the relaxation time from the onset of aortic component of the 2nd heart sound (A2) remain within normal range in all phases. Other abbreviations as in figure 2 (from Manolas, Z Kardiol 1990).

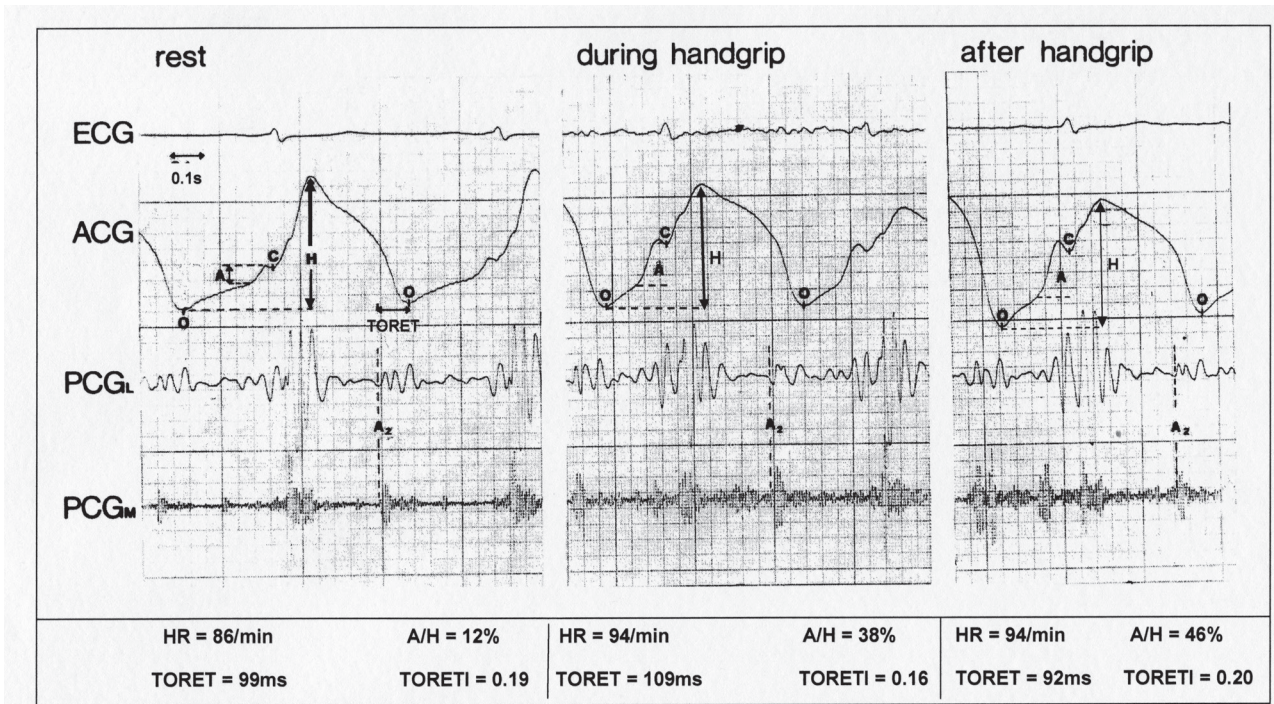


Figure 6 Presso Test with an “ischemic pattern” due to A wave increase in a patient with 3 vessels CAD. The HR increases from 86/min to 94/min during and after handgrip. The A/H increases from 12% at rest up to 38% during and 46% after handgrip; thus, showing a maximal increase of 283% over the rest value. The relaxation time shows a slight decrease. Abbreviations as in figure 2. (modified from Manolas, Cardiology 1995).

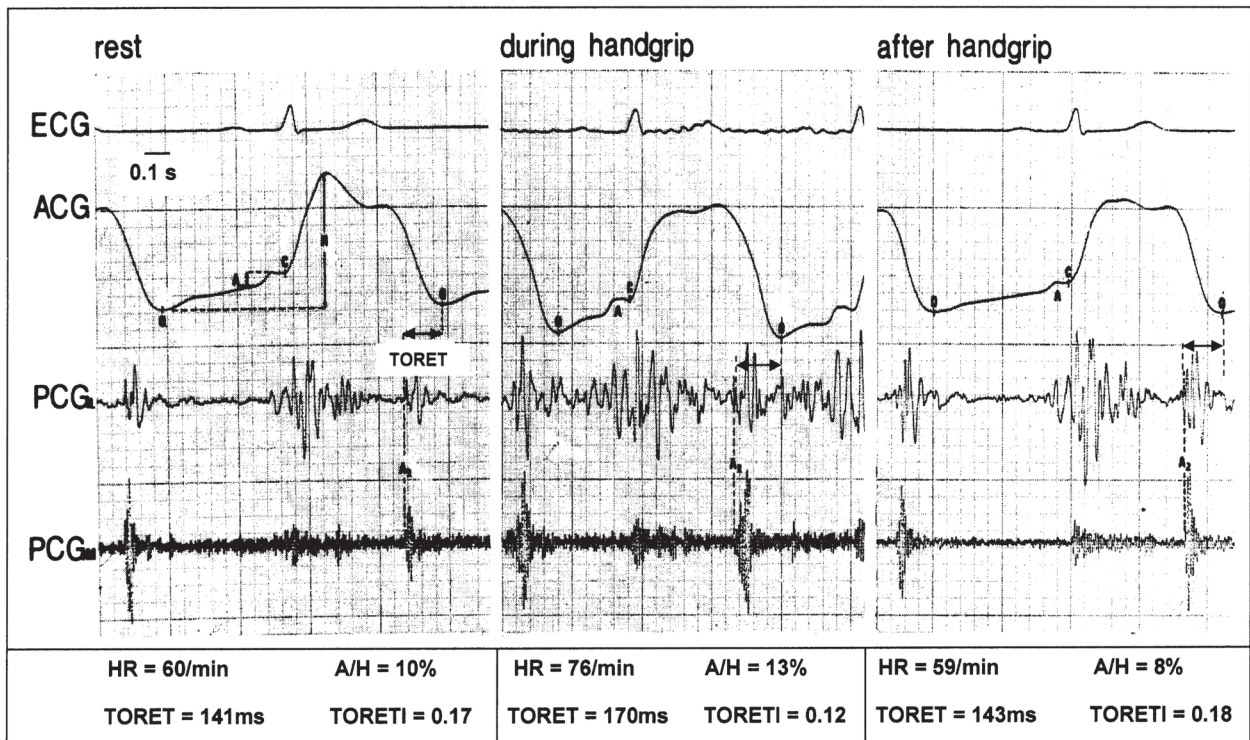


Figure 7 Presso Test with an “ischemic pattern” due to relaxation prolongation in an asymptomatic patient with 2 vessels CAD. The A wave amplitude does not change significantly. Whereas HR increases from 60/min to 76/min, TORET prolongs from 141ms to 170ms during handgrip (19% over rest value) and TORETI ( $= \sqrt{A_2-C}/\text{TORET}$ ) decreases from 0.17 to 0.12. In contrast, the A wave amplitude shows only insignificant changes with handgrip (modified from Manolas, Cardiology 1995).

## CONFLICT OF INTERESTS

There are no conflicts of interest with regard to the present study.

## REFERENCES

- 1 Gradus-Pizlo I, Segar DS, Feigenbaum H. Detection of subclinical coronary atherosclerosis using noninvasive imaging methods. *ACC Current J Review* 1999; 47-50
- 2 Patel MR1, Peterson ED, Dai D, Brennan JM, Redberg RF, Anderson HV, Brindis RG, Douglas PS. Low diagnostic yield of elective coronary angiography. *N Engl J Med* 2010; **362**: 886-895
- 3 Douglas PS, Patel MR, Bailey SR, Dai D, Kaltenbach L, Brindis RG, Messenger J, Peterson ED. Hospital variability in the rate of finding obstructive coronary artery disease at elective, diagnostic coronary arteriography. *J Am Coll Cardiol* 2011; **58**: 801-809
- 4 Levitt K1, Guo H, Wijesundera HC, Ko DT, Natarajan MK, Feindel CM, Kingsbury K, Cohen EA, Tu JV. Predictors of normal coronary arteries at coronary angiography. *Am Heart J* 2013; **166**(4): 694-700
- 5 Helfant RH, Banka VS, DeVilla MA, Pine R, Kabde V, Meister SG. Use of Bicycle ergometry and sustained handgrip exercise in the diagnosis of presence and extent of coronary heart disease. *Br Heart J* 1973; **35**: 1321-1325
- 6 Krayenbuehl HP. Evaluation of left ventricular function by handgrip. *Eur J Cardiology* 1974; **1**: 283-291
- 7 Flessas AP, Connelly GP, Handa S, Tilney CR, Kloster CK, Rimmer RH Jr, Keefe JF, Klein MD, Ryan TJ. Effects of isometric exercise on the end-diastolic pressure, volumes and function of the left ventricle in man. *Circulation* 1976; **53**: 839-846
- 8 Brown BG, Lee AB, Bolson EL, Dodge HT. Reflex constriction of significant coronary stenosis as a mechanism contributing to ischemia during isometric exercise. *Circulation* 1984; **70**: 18-24
- 9 Buchthal SD, Den Hollander JA, Merz CN, et al. Abnormal myocardial phosphorus-31 nuclear magnetic resonance spectroscopy in women with chest pain but normal coronary arteriograms. *N Engl J Med* 2000; **342**: 829-835
- 10 Johnson BD, Shaw LJ, Buchthal SD, Bairey Merz CN, Kim HW, Scott KN, Doyle M, Olson MB, Pepine CJ, den Hollander J, Sharaf B, Rogers WJ, Mankad S, Forder JR, Kelsey SF, Pohost GM; National Institutes of Health-National Heart, Lung, and Blood Institute. Prognosis in women with myocardial ischemia in the absence of obstructive coronary disease. *Circulation* 2004; **109**: 2993-2999
- 11 Mann T, Goldberg S, Mudge GH Jr, Grossman W. Factors contributing to altered left ventricular diastolic properties during angina pectoris. *Circulation* 1979; **59**: 14-20
- 12 Manolas J. The ischemic diastolic response. Described, unknown, clinically useful? *Helv J Cardiol* 1994; **35**: 597-605
- 13 Manolas J, Rutishauser W, Wirz P, Arbenz U. Time relation between apexcardiogram and left ventricular events using simultaneous high-fidelity tracings in man. *Br Heart J* 1975; **37**: 1263-1267
- 14 Manolas J, Rutishauser W. Relation between apex cardiographic and internal indices of left ventricular relaxation in man. *Br Heart J* 1977; **39**: 1324-1332
- 15 Gibson TC, Madry R, Grossman W, et al. The A wave of the apexcardiogram and left ventricular diastolic stiffness. *Circulation* 1977; **49**: 441-446
- 16 Manolas J, Krayenbuehl HP. Comparison between apexcardiographic and angiographic indexes of left ventricular performance in patients with aortic incompetence. *Circulation* 1978; **57**: 692-698
- 17 Manolas J, Krayenbuehl HP, Rutishauser W. Use of apexcardiography to evaluate left ventricular diastolic compliance in human beings. *Am J Cardiol* 1979; **43**: 939-945
- 18 Manolas J, Rutishauser W. Diastolic amplitude time index: a new apexcardiographic index of left ventricular diastolic function in human beings. *Am J Cardiol* 1981; **48**: 736-745
- 19 Benchimol A and Dimond EG. The apex cardiogram in ischaemic heart disease. *Br Heart J* 1962; **24**: 581-594
- 20 Dimond EG and Benchimol A. Correlation of intracardiac pressure and precordial movement in ischaemic heart disease. *Br Heart J* 1963; **25**: 369-392
- 21 Manolas J, Kaparis GT, Rutishauser W. Noninvasive detection of an abnormal left ventricular end-diastolic pressure elevation during handgrip in coronary patients. *Am J Cardiac Imaging* 1994; **8**: 277 (abstract)
- 22 Gleichmann U, Vlachakis N, Tsilos T. Zur Entstehung des Herzspitzenstosses und Deutung systolischer Formveraenderungen des Apexkardiogramms. *Z Kreislaufforschung* 1970; **60**: 789-807
- 23 Manolas J. Value of handgrip-apexcardiographic test for the detection of early left ventricular dysfunction in patients with angina pectoris. *Z Kardiol* 1990; **79**: 825-830
- 24 Manolas J. Noninvasive detection of coronary artery disease by assessing diastolic abnormalities during low isometric exercise. *Clin Cardiology* 1993; **16**: 205-212
- 25 Manolas J. Comparison of the handgrip apexcardiography test and stress ECG for detection of patients with coronary heart disease. *Herz* 1993; **4**: 256-266
- 26 Manolas J. Ischemic and nonischemic patterns of diastolic abnormalities during isometric handgrip exercise. *Cardiology* 1995; **86**: 179-188
- 27 Manolas J1, Chrysochoou C, Kastelanos S, Aggeli KN, Panagiota-kos DB, Stefanadis C, Toutouzas P. Identification of patients with coronary artery disease by assessing diastolic abnormalities during isometric exercise. *Clin Cardiol* 2001; **24**: 735-743
- 28 Paulus WJ, the participants of the European Study Group on Diastolic Heart Failure, Working Group on Myocardial Function of European Society of Cardiology. How to diagnose diastolic heart failure? *Eur Heart J* 1998; **19**: 990-1000
- 29 Manolas J. Patterns of diastolic abnormalities during isometric stress in patients with systemic hypertension. *Cardiology* 1997; **88**: 36-47
- 30 Manolas J1, Kyriakidis M, Anastasakis A, Pegas P, Rigopoulos A, Theopistou A, Toutouzas P. Usefulness of noninvasive detection of left ventricular diastolic abnormalities during isometric stress in hypertrophic cardiomyopathy and in athletes. *Am J Cardiol* 1998; **81**: 306-313

**Peer reviewers:** Jose Antonio F. Ramires, MD, PhD, FACC, FESC, Rua Almirante Soares Dutra, 521, Cardiology Department, INCOR, 05654-000 São Paulo, SP, Brasil; Varounis Christos, MD, Msc (Biostatistics), PhD, Cardiologist, 2nd Cardiology Department, Attikon University Hospital, Athens University Medical School, Rimini 1, Haidari, 12462, Greece.