

Cellulite Treatment Using Endoscopic Scissors

Nour Alharthi, Mohammed A. Alsufyani

Nour Alharthi, Department of Dermatology and Dermatologic Surgery, Prince Sultan Military Medical City, Riyadh, 11159, Saudi Arabia
Mohammed A. Alsufyani, Department of Dermatology and Dermatologic Surgery, Prince Sultan Military Medical City, Riyadh, 11159, Saudi Arabia

Conflict-of-interest statement: The author(s) declare(s) that there is no conflict of interest regarding the publication of this paper.

Correspondence to: Mohammed A. Alsufyani, Department of Dermatology and Dermatologic Surgery, Prince Sultan Military Medical City, Riyadh, 11159, Saudi Arabia.
Email: malsufyani@psmmc.med.
Telephone: +966114777714

Received: July 25, 2016

Revised: October 15, 2016

Accepted: October 18, 2016

Published online: December 26, 2016

ABSTRACT

The aim of this paper is to report a new surgical technique for cellulite treatment, using autoclavable endoscopic scissors to release the fibrous band under tumescent anesthesia with the least number of access wounds targeting the entire affected area. Twelve female patients, all who suffered from stage III on the Numberger-Muller cellulite classification, underwent the procedure. Satisfaction rate was measured by the Global Aesthetic Improvement Scale (GAIS). Ten patients scored 4 on the GAIS, and two patients scored 3. This technique had minimal side effects and was cost effective.

Key words: Cellulite; Treatment; Endoscopic scissors

© 2016 The Author(s). Published by ACT Publishing Group Ltd. This is an open access article under the CC BY-NC-ND license (<http://creativecommons.org/licenses/by-nc-nd/4.0/>).

Alharthi N, Alsufyani MA. Cellulite Treatment Using Endoscopic Scissors. *Journal of Dermatological Research* 2016; 1(4): 69-71
Available from: URL: <http://www.ghrnet.org/index.php/jdr/article/view/1803>

INTRODUCTION

Cellulite is a common problem affecting 85% of all women over the age of 20 years from all races. Cellulite is defined as a localized metabolic disorder that causes herniation of the subcutaneous fat within the fibrous septa, leading to dimpling and nodularity of the skin. It is usually found in the hips, thighs, and abdomen. The etiology is not well understood. Several predisposing factors are well known to worsen the condition, such as hereditary, sedentary life style, pregnancy, hormonal influence, and ethnicity, more often in white women. Cellulite is classified to four grades according to Numberger-Muller cellulite classification, as shown in Table 1. Stage zero has no dimpling when the subject stands and lies down, and the pinch test reveals folds and furrows but no mattress-like appearance. Stage 1 has no dimpling, but the pinch test reveals the mattress-like appearance. Dimpling that appears spontaneously when standing is seen only in stage 2. Stage 3 dimpling is spontaneous and seen when both standing and lying down. The treatments for cellulite include noninvasive and invasive therapies. We report a new surgical technique that we found to be effective in treating cellulite.

DESCRIPTION OF THE TECHNIQUE

The patient is positioned in a standing posture with overhead lighting to exaggerate the cellulite and locate it better. It is marked with any color the surgeon feels comfortable with; we prefer red for its convenience (Figure 1). The patient is brought into the operating room and prepped, and the areas to be treated are sterilized in the usual manner. A standard Klein's tumescent anesthesia is infiltrated into the region, ensuring adequate infusion of both superficial and deep fat layers. If the patient was scheduled for liposuction in the same area, cellulite treatment is undertaken first to ensure that the

Table 1 Nurnberger-Muller cellulite classification scale.

Stage 0	No dimpling when the subject is standing or lying down. The pinch test reveals folds and furrows but no mattress-like appearance.
Stage 1	No dimpling while the subject is standing or lying down, but the pinch test reveals a mattress-like appearance.
Stage 2	Dimpling appears spontaneously when standing but not while lying down.
Stage 3	Dimpling appears spontaneously when standing and lying down.

cellulitic bands are still under tension; this helps capture and release the bands, analogous to someone holding a string tight while you cut it with scissors. Given the length of the endoscopic scissors, the entry wound may be placed in a concealed region, even if some distance from the cellulite. The choice of using straight versus curved-tip scissors is entirely up to the surgeon; they both work. We opted to use curved ones simply because we feel they offer more control over the orientation of the tip direction in relation to the location of the cellulitic band (Figure 2). The endoscopic scissors are introduced with the tips closed and oriented superiorly. When the surgeon reaches the cellulitic band, the scissors are opened to hook the band and secure it between the blades of the scissors. The band is released with the scissors; this may require one to three snips. The procedure is demonstrated in the video link. (<https://youtu.be/x96GuqcTrW>).

DISCUSSION

The tremendous demand by woman of all ages for cellulite therapy has resulted in several studies to find the best cellulite treatment.

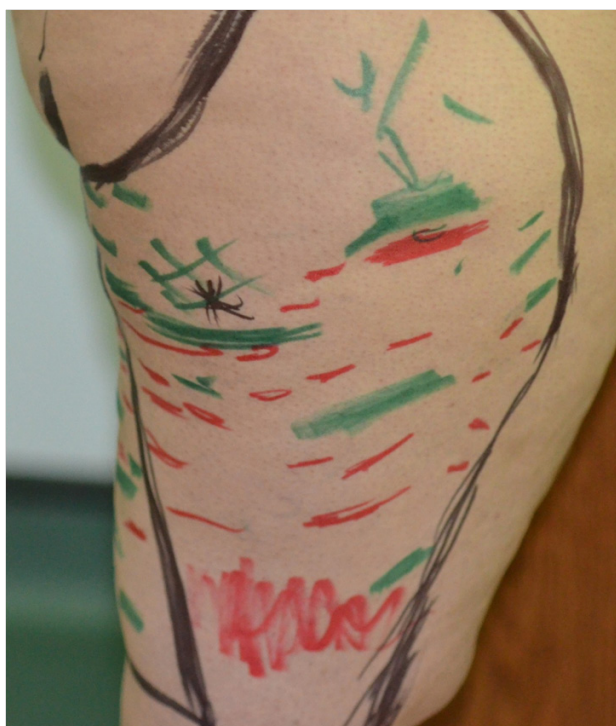

Figure 1 Marking of cellulite.

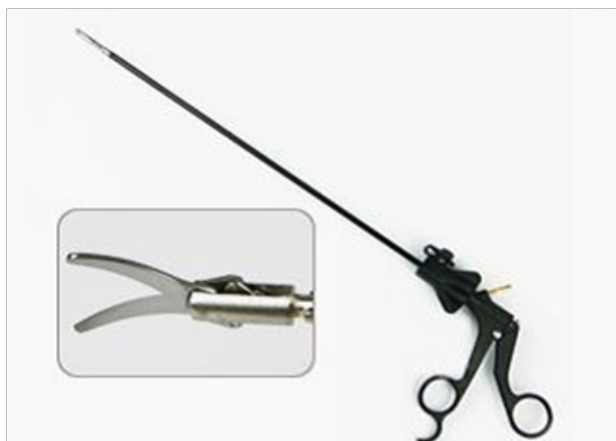

Figure 2 Endoscopic scissors with a curved tip.

Both noninvasive and invasive techniques have been described in literature. However, the treatments in these studies lacked long-term efficacy and longevity^[1]. In fact, no one treatment is completely successful^[1].

Noninvasive therapies, such as endermologie, phosphatidylcholine, mesotherapy, radiofrequency devices, extracorporeal shock wave therapy, and several topical therapies may show some improvement, but all these therapies need multiple sessions, have questionable long-term sustainability, and are not cost effective^[1].

Invasive therapies for cellulite have been shown to be more efficacious when compared to noninvasive therapy. Liposuction is considered outdated according to recent reports indicating that manual liposuction results in poor cosmetic outcome^[2] and actually might cause exaggeration of cellulite. Another modality of treatment, ultrasound-assisted liposuction, was found to be safe and less destructive to the connective tissue than the conventional liposuction technique^[3]. To date, it is unknown whether to consider the preservation of such connective tissue in ultrasound-assisted liposuction superior. Laser-assisted liposuction was suggested as superior to manual liposuction in treating small surface areas of cellulite, but supporting evidence is absent in the literature^[4].

Currently, cellulite treatment is performed to destroy fat selectively with skin tightening. ND-YAG (1064 nm) laser treatment in combination with fat transplant has been found effective with additional skin tightening, with a more than 80% patient satisfaction rate^[4]. Minimally invasive pulsed 1440 nm Nd: YAG works by heating the dermis from the inside out to increase dermal thickness and skin elasticity by stimulating neocollagenesis and collagen remodeling^[5]. This indicated significant improvement; however, more randomized, controlled studies are required to assess the degree of improvement.

Radiofrequency has achieved tissue tightening by heating the skin to mediate a reaction in dermis and collagen denaturation thermally. High- and low-radiofrequency devices have been used. Combining radiofrequency with suction (750 mmHg negative pressure) in published randomized controlled trials (RCTs) showed no statistically significant improvement compared to monotherapy^[6,7].

Hessel *et al*^[8] showed up to 78% patient satisfaction by using subcision, which improved skin dimpling by severing the septae that hold fat lobules resulting in skin dimpling. Subcision was found to be effective in treating cellulite but with controversial long-term results. The technique to achieve the result used a 16- or 18-gauge needle inserted in subcutaneous fat in a direction parallel to the epidermis, shearing the septae.

Cellfina, an FDA-approved for cellulite treatment, targets the fibrous bands under the dimpled skin. By using the Cellfina suction device on the skin, locally infiltrated with anesthetic agent, a sharp instrument releases the band. It is considered the most effective for the dimple type of cellulite^[9]. Cellfina has shown high patient satisfaction rate, almost no downtime, and long-lasting results^[10].

In recent updates, a dramatic improvement was achieved by combining therapies. Brandi *et al.* reported a significant improvement in skin irregularity by using carbon dioxide therapy 3 weeks after liposuction, administered two times a week for the treatment period. Transcutaneous carbon dioxide also can be used as a monotherapy and has been associated with improvement in skin elasticity by disrupting adipocyte tissue and altering microcirculation^[11,12].

In our technique, we report a new cellulite treatment technique by using surgical endoscopic scissors to release cellulitic bands. We included 12 healthy females with no known comorbidity, ages 29 to 36 years old, who had cellulite grade III and higher on the

Numberger-Muller cellulite classification. The Global Aesthetic Improvement Scale (GAIS) was used as well to measure the patient satisfaction rate (Table 2). Ten of the patients achieved a score of 4 by GAIS, and two patients achieved a score of 3 (Table 3). The side effects observed in the trial were limited to bruises, paresthesia, and swelling all resolving within three weeks. The mean follow-up period was four months. The advantage of this procedure is that only one concealed access wound is made in the skin rather than multiple access wounds, which can increase the risk of scars and post-inflammatory hyperpigmentation, which are very common in our region (the Middle East) due to our skin type, which ranges from 3 to 5 Fitzpatrick's skin type. In addition, the endoscopic scissors are autoclavable, so there are no consumables with frequent usage, and this is very cost effective in both the short and long term. The final results are usually appreciated after 3 to 4 months after one session (Figures 3 and 4).

CONCLUSION

Cellulite is common, affecting most females; much effort has been expended to find the best treatment. Reported noninvasive and invasive measures have varied in efficacy and longevity. Compared to those, our technique has the advantage of the possibility of performing the procedure under tumescent anesthesia while the patient is conscious, and requiring only one or two access wounds, with fewer side effects and high satisfaction rates. Despite these findings, more randomized controlled studies are advised to evaluate the efficacy of our technique objectively.

REFERENCES

- 1 Luebberding S, Krueger N, Sadick N. Cellulite: An Evidence – based Review. *Am J Clin Dermatol* 2015; **16**: 243-256
- 2 Coleman WP, Hanke CW, Alt TH, editors. *Cosmetic surgery of the skin: principle and practice*. Philadelphia: BC Decker; 1991. pp. 231-38
- 3 ademo C, Mazzocchi M, Rossi A, Scuderi N. Ultrasonic liposculpting: extrapolations from the analysis of in vivo sonicated adipose tissue. *Plast Reconstr Surg* 1997; **100**: 220-6
- 4 Goldman A, Gotkin RH, Sarnoff DS et al. Cellulite: a new treatment approach combining subdermalNd: YAG laser lipolysis and autologous fat transplantation. *Aesthet Surg J* 2008; **28**: 656-62
- 5 Di Bernardo BE. Treatment of cellulite using a 1440-nm pulsed laser with one –year follow-up. *Aesthetic Surg J*. 2011; **31(3)**: 34-44
- 6 Romero C, Caballero N, Herrero M, Ruiz R et al. Effect of cellulite treatment with RF, IR light, mechanical massage and suction treating one buttock with the contralateral as control. *J Cosmet Laser Ther*. 2008; **10(4)**: 193-201
- 7 Nootheti PK, Magpantay A, Yosowitz G, Calderon S et al. A single center, randomized, comparative, prospective clinical study to determine the efficacy of VelaSmooth system versus the triactive system for treatment of cellulite. *Laser Surg Med*. 2006; **38(10)**: 908-12
- 8 Hessel DM, Mazzucco R. subcision: a treatment for cellulite. *Int J Dermatol* 2000; **39**: 539-44
- 9 Green JB, Cohen JL. Cellfina observations: pearls and pitfalls. *Semin Cutan Med Surg*. 2015 Sep; **34(3)**: 144-6
- 10 Green JB, Cohen JL, Kaufman J, Metelitsa AI, Kaminer MS. Therapeutic approaches to cellulite. *Semin Cutan Med Surg*. 2015 Sep; **34(3)**: 140-3
- 11 Brandi C, D'Aniello C, Grimaldi L, Caiazzo E et al. Carbon Diox-

Very Much Improved	Optimal cosmetic result for the implant in patient
Much Improved	Marked improvement in appearance but not completely optimal for this patient. A touch-up would slightly improve the result.
Improved	Obvious improvement in appearance from the initial condition, but a touch-up or re-treatment is indicated.
No Change	The appearance is essentially the same as the original condition.

Variable character	Number (%)
Gender	
Female	12 (100)
Male	0
Age	Range (29–36)
Nurnberger-Muller cellulite	
Stage 3	12 (100)
Global aesthetic improvement scale	
4	10
3	2

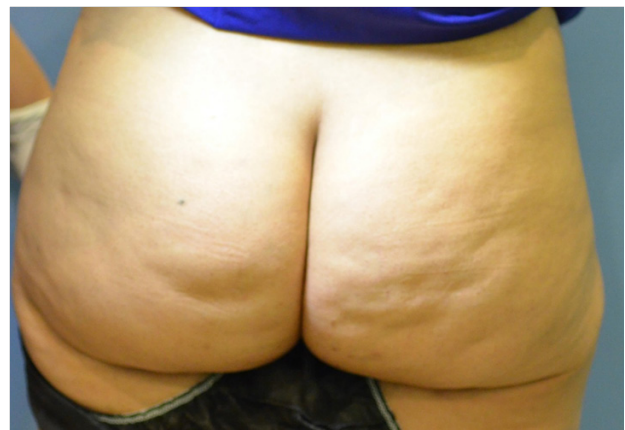

Figure 3 Before treatment.

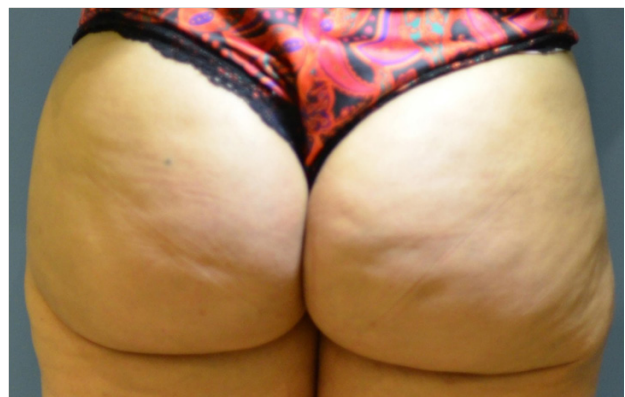


Figure 4 After treatment.

- 12 Lee GSK. Carbon dioxide therapy in the treatment of cellulite: an audit of clinical practice. *Aesth. Plast. Surg* 2010; **34(2)**: 239-43