

## Nodular-Cystic Fat Necrosis -A Review of 147 Japanese Patients

Masanori Ban

Masanori Ban, Ban skin clinic, Private practice, Hashima, Japan

**Conflict-of-interest statement:** The author(s) declare(s) that there is no conflict of interest regarding the publication of this paper.

**Correspondence to:** Ban Hifuka, Masakicho Magari 1050-1, Hashima City, 501-6227, Japan.

**Email:** banhifuka@major.ocn.ne.jp

**Telephone:** +81-58-391-0056

**Received:** August 2, 2016

**Revised:** August 20, 2016

**Accepted:** August 22, 2016

**Published online:** December 26, 2016

### ABSTRACT

Nodular-cystic fat necrosis, which is also called encapsulated fat necrosis, is a mobile subcutaneous nodule and histologically reveals fat necrosis encapsulated by fibrous connective tissue. In Japan, many cases have been reported, and there are some opinions that diabetes mellitus and systemic corticosteroid therapy cause this condition. The author found that out of 147 Japanese patients reported from 1982 up to 2015, 9 had the former and 23 received the latter. Systemic corticosteroid therapy may be responsible for nodular-cystic fat necrosis.

**Key words:** Nodular-cystic fat necrosis; Japanese patients; Systemic corticosteroid therapy

© 2016 The Author(s). Published by ACT Publishing Group Ltd. This is an open access article under the CC BY-NC-ND license (<http://creativecommons.org/licenses/by-nc-nd/4.0/>).

Ban M. Nodular-Cystic Fat Necrosis - A Review of 147 Japanese Patients. *Journal of Dermatological Research* 2016; 1(4): 65-68 Available from: URL: <http://www.ghrnet.org/index.php/jdr/article/view/1807>

### EDITORIAL

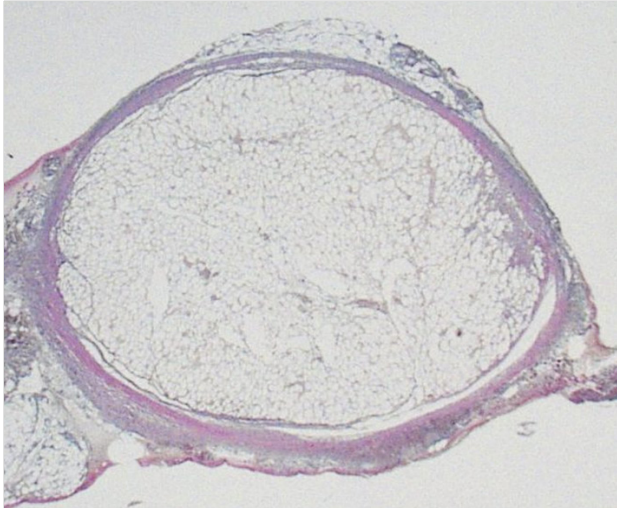
Many cases of nodular-cystic fat necrosis have been reported by Japanese. It is a subcutaneous nodule and histologically reveals fat necrosis encapsulated by fibrous connective tissue (Figure 1). Most lesions have mobility<sup>[1]</sup>. This condition has several names. The term “nodular-cystic fat necrosis” was proposed by Przyjemski & Schuster in 1977<sup>[2]</sup>. Sahl<sup>[3]</sup> reported two cases as “mobile encapsulated lipoma” the next year. He mentioned encapsulated adipocytes and thrombi, but did not do the presence of fatty degeneration. In 1984 Kikuchi et al<sup>[4]</sup> thought Sahl’s cases identical to nodular-cystic fat necrosis and emphasized that “mobile encapsulated lipoma” was a more suitable term. At the same time Kikuchi<sup>[5]</sup> reported two cases showing advanced necrosis, membranocystic change and no mobility. He concluded them to be different from mobile encapsulated lipoma. In 1989 Hurt & Santa Cruz<sup>[1]</sup> stated that the above cases belong to a spectrum consisting of the different fatty degeneration and the mobility depends on the quantity of surrounding soft tissue. They preferred the term “nodular-cystic fat necrosis.” Now membranocystic change is considered a nonspecific pattern of fat necrosis<sup>[6]</sup>.

In Japan, a mother country of Kikuchi, the concept of this condition was confused. At first, three terms mainly were used: “nodular-cystic fat necrosis”, “mobile encapsulated lipoma” and the Japanese name proposed by Ichiki et al<sup>[7]</sup> in 1987, which could be translated to “encapsulated fat necrotic small nodule (Kikuchi)”. This Japanese name was succinctly translated to “encapsulated fat necrosis (Kikuchi)” by Ezo et al<sup>[8]</sup>. Two English papers using “encapsulated fat necrosis” in the titles were written by Japanese dermatologists in 1997 and 2000<sup>[9,10]</sup>. This term became popular not only in Japan but around the world. “Mobile encapsulated lipoma” is rarely used now.

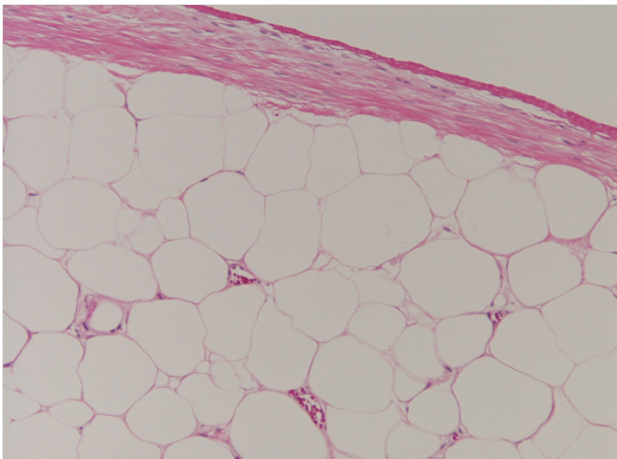
Hurt & Santa Cruz<sup>[1]</sup> described that fat degeneration progresses with time. In the early stage the construction of the adipose tissue is kept, but most areas show no nuclei. Vascular structure and blood cells are found (Figure 2). The middle stage lesions show degenerated honeycomb patterns of anucleated adipocytes, focal or massive hemorrhage, vascular thrombosis and lipomembranous change (Figure 3). The late stage lesions reveal fibrosis, hyalinization and calcification. The construction of the adipose

Ban M. Nodular-cystic fat necrosis


tissue mostly are not found (Figure 4)<sup>[1,11,12]</sup>. A very few lesions disappear spontaneously<sup>[13,14]</sup>. The pathogenesis is thought to be rapidly compromised blood supply, presumably from trauma, in the adipose tissue<sup>[1]</sup>. Some cases have been reported, which were associated with complications: erythema nodosum<sup>[15]</sup>, Ehlers-Danlos syndrome<sup>[8]</sup>, Heerfordt's syndrome<sup>[16]</sup>, splinter granuloma<sup>[17]</sup>, systemic



**Figure 1** A subcutaneous nodule composed of fat necrosis and surrounded by fibrous tissue (× 10).



**Figure 2** Anucleated fat cells and veins including red cells in the early stage (× 100).



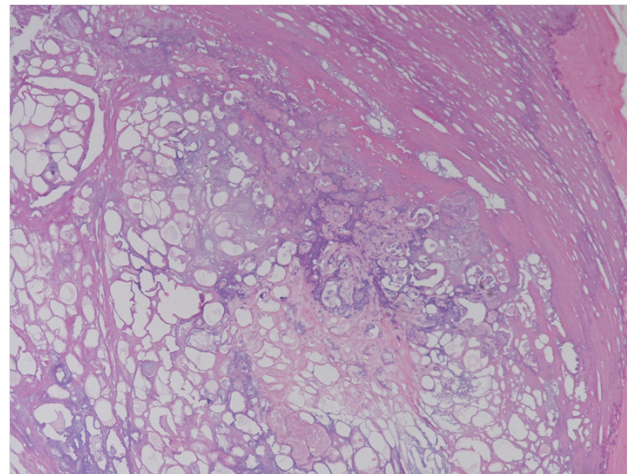
**Figure 3** Degenerate veins and membranocystic change in the middle stage (× 100).

sclerosis<sup>[14]</sup>, lupus erythematosus<sup>[18]</sup>, and juvenile dermatomyositis<sup>[19]</sup>. Local ischemia in skin may be induced by them. In Japan several authors suspect diabetes mellitus<sup>[20-23]</sup> and systemic corticosteroid therapy<sup>[13,14,24,25]</sup> as etiologies of nodular-cystic fat necrosis. It is speculated that diabetic microangiopathy causes local ischemia in the patients with the former and that skin atrophy, subcutaneous hemorrhage and panniculitis do it in ones who received the latter. Shibata et al<sup>[24]</sup> suggested that it is a dermatome of Cushing syndrome which reveals high levels of cortisol.

Searching Pub Med, Ichushi service (Japanese online medical service by NPO Japan Medical Abstracts Society) and previous views<sup>[10,23]</sup>, the author found 147 Japanese patients with this condition reported from 1982 up to 2015 in English and Japanese literature, and analyzed their complications.

The number of lesions was multiple in 79 patients, single in 52 and unknown in 16 patients. The youngest was a one-year old female. Female patients between the ages of 40 and 69 predominated (Table 1). About 60% lesions occurred in the lower extremities which are easy to receive trauma (Table 2). The history of trauma was evident in only 26 patients, and frequent in the young (Table 1). The reason may be because they have many opportunities playing sports. The present analysis did not indicate the participation of diabetes mellitus. Only 9 patients (6%) had it (Table 3). Prevalence of diabetes in Japanese adults (20-79 years) is 7.6% (International Diabetes Federation 2015). However, it is important that 8 out of 9 patients had multiple lesions. Twenty-three patients (15.6%) had taken systemic corticosteroid therapy (Table 3). Twenty out of them had multiple lesions. These numbers make us suspect possibility that it causes nodular-cystic fat necrosis. Enough information was not obtained about the doses and the dosing period.

The author hopes more reports about complications from the world.



**Figure 4** Fibrosis and calcification in the late stage (× 100).

Table 1 Distribution of age, sex and trauma history.				
Age	Number of male	Number of male with the history of trauma	Number of female	Number of female with the history of trauma
0~9	0	0	1	1
10~19	7	4	6	2
20~29	5	4	6	3
30~39	2	2	11	3
40~49	2	0	21	0
50~59	9	1	24	3
60~69	4	0	32	1
70~79	2	1	9	1
80~89	2	0	4	0

**Table 2** Site of the lesions.

Site	Number of patients
Lower leg	65
Knee	15
Thigh	20
Pedis	5
Hand	10
Elbow	5
Forearm	9
Upper arm	4
Inguinal	3
Buttock	11
Abdomen	1
Chest	1
Back	6
Lumbus	8
Neck	1
Unknown	5

**Table 3** Complications and systemic corticosteroid therapy.

Underlying disease	Number of patients	Number of patients receiving systemic corticosteroid therapy
Systemic lupus erythematosus	7	6
Dermatomyositis	1	1
Rheumatoid arthritis	3	2
Systemic lupus erythematosus + rheumatoid arthritis	1	1
Systemic scleroderma + Sjogren's syndrome + Basedow's disease	1	1
Sjogren's syndrome + anti-phospholipid antibody syndrome + systemic lupus erythematosus	1	1
Autoimmune hepatitis	1	1
Pemphigus vulgaris	1	1
Hypereosinophilic syndrome	1	1
Granulomatosis with polyangiitis	1	1
Sheehan's syndrome	1	1
Chronic inflammatory demyelinating polyneuropathy	1	1
Polyneuritis	1	1
Cushing's syndrome	2	0
Ehlers-Danlos syndrome	1	0
Polyarthritis	1	0
Polymyositis	1	0
Multiple sclerosis	1	0
Sarcoidosis ( including Heerfordt's syndrome)	2	0
Behcet's disease	1	0
Diabetes melitus	7	0
Daibetis melitus + rheumatoid arthritis	1	0
Daibetis melitus + polyneuritis	1	1
Unknown		4

## ACKNOWLEDGMENTS

I wish to thank Prof. Mariko Seishima (Gifu University) for her help.

## REFERENCES

- Hurt MA, Santa Cruz DJ. Nodular-cystic fat necrosis. A reevaluation of the so-called mobile encapsulated lipoma. *J Am Acad Dermatol* 1989; **21**: 493-498. [PMID: 2674212]
- Przyjemski CJ, Schuster SR. Nodular-cystic fat necrosis. *J Pediatr* 1977; **91**: 605-607. [PMID: 908980]
- Sahl WJ Jr. Mobile encapsulated lipomas. Formerly called en-

- capsulated angioliipomas. *Arch Dermatol* 1978; **114**: 1684-1686. [PMID: 718219]
- Kikuchi I, Okazaki M, Narahara S. The so-called mobile encapsulated lipoma. *J Dermatol* 1984; **11**: 410-412. [PMID: 6392389]
- Kikuchi I. Encapsulated necrosis on the legs showing a changing number of nodules. A special type of encapsulated adiponecrosis? *J Dermatol* 1984; **11**: 413-416. [PMID: 6392390]
- Pujol RM, Wang CY, Gibson LE, Su WP. Lipomembranous changes in nodular-cystic fat necrosis. *J Cutan Pathol* 1995; **22**: 551-555. [PMID: 8835174]
- Ichiki Y, Umemura A, Yamamoto A, Yanagihara M, Mori S. Encapsulated fat necrotic small nodule (Kikuchi). *Jpn J Dermatol* 1987; **97**: 74. (in Japanese)
- Ezoe K, Shono M, Yoshimoto S. A case of encapsulated fat necrosis (Kikuchi). *J J Clin Dermatol* 1988; **42**: 1139-1143. (in Japanese)
- Ohtake N, Gushi A, Matsushita S, Kanzaki T. Encapsulated fat necrosis in a patient with Ehlers-Danlos syndrome. *J Cutan Pathol* 1997; **24**: 189-192. [PMID: 9085156]
- Kiryu H, Rikihisa W, Furue M. Encapsulated fat necrosis—a clinicopathological study of 8 cases and a literature review. *J Cutan Pathol* 2000; **27**: 19-23. [PMID: 10660127]
- Ban M, Ichiki Y, Yamada T, Kitajima Y. Three cases of nodular cystic fat necrosis. *Rinsho derma* (Tokyo) 1996; **38**: 1729-1732. (in Japanese)
- Hisa T, Taniguchi S, Nishimura T, Nakanishi T, Wakasa K, Kakudo K, Hirachi Y, Takigawa M. Mobile fat; three stages? *Australas J Dermatol* 1996; **37**: 223-224. [PMID: 8961596]
- Hokoishi M, Maruyama M, Murakami S, Hashimoto K. A case of encapsulated fat necrosis. *Nishinohon J Dermatol* 2004; **66**: 451-453
- Demitsu T, Yoneda K, Iida E, Takada M, Hiratsuka Y, Azuma R, Kakurai M. A case of nodular cystic fat necrosis with systemic lupus erythematosus presenting the multiple subcutaneous nodules on the extremities. *J Eur Acad Dermatol Venereol* 2008; **22**: 885-886. [PMID: 18577023]; [DOI: 10.1111/j.1468-3083.2007.02482.x]
- Ahn SK, Lee BJ, Lee SH, Lee WS. Nodular cystic fat necrosis in a patient with erythema nodosum. *Clin Exp Dermatol* 1995; **20**: 263-265. [PMID: 7671430]
- Ueda N, Satoh T, Yamamoto T, Yokozeki H. Nodular cystic fat necrosis in Heerfordt's syndrome. *Eur Acad Dermatol Venereol* 2007; **21**: 708-709. [PMID: 17448005]; [DOI: 10.1111/j.1468-3083.2006.02005.x]
- Lee HJ, Ahn SK, Hong SP, Bak H. Nodular cystic fat necrosis with lipomembranous change observed in splinter granuloma. *Int J Dermatol* 2014; **53**: 135-137. [PMID: 23231473]; [DOI: 10.1111/j.1365-4632.2012.05575.x]
- Toritsugi M, Yamamoto T, Nishioka K. Nodular cystic fat necrosis with systemic sclerosis. *Eur J Dermatol* 2004; **14**: 353-355. [PMID: 15358578]
- Ferenzi K, Berke A, Makkar HS. Nodular cystic fat necrosis with calcification in a patient with juvenile dermatomyositis. *Pediatr Dermatol* 2014; **31**: 588-590. [PMID: 24930439]; [DOI: 10.1111/pde.12363]
- Umemoto K, Kurimoto T, Yoshida M, Tezuka T. Encapsulated necrosis: A case report. *Skin research* 1989; **31**: 817-819. (in Japanese)
- Irie H, Ohnishi Y, Yanagihara Y, Osamura Y. Encapsulated fat necrosis (Kikuchi). *Rinsho derma* (Tokyo) 1991; **33**: 1585-1588. (in Japanese)
- Iwashige K, Hasama Y, Kuroki T, Sekiguchi N, Ono Y, Hashimoto T, Umeda F, Nawada H. A case of Diabetes mellitus with encapsulated fat necrosis. *Jpn J Clin Exp Med* 1995; **72**: 2783-2786. (in Japanese)
- Kubota Y, Nakai K, Moriue T, Yokoi I, Fujita N, Miyamoto I, Yoneda K. Nodular cystic fat necrosis in a patient with diabetes

Ban M. Nodular-cystic fat necrosis

- mellitus. *J Dermatol* 2009; **36**: 353-354. [PMID: 19500184]; [DOI: 10.1111/j.1346-8138.2009.00651.x]
24. Yamada S, Sasaki Y, Hata Y, Kawahara Y, Tanaka M. Mobile encapsulated lipoma—Report of two cases and consideration to 28 cases in Japan. *J J Clin Dermatol* 1998; **52**: 303-308. (in Japanese)
25. Shibata M, Ochiai T, Saito Y, Nakaya T, Morishima T, Fukuda N, Soma M, Ishida H, Hachiya T. Multiple mobile encapsulated lipoma –Dermadrome of Cushing syndrome –. *Rinsho derma* (Tokyo) 1997; **39**: 931-935. (in Japanese)

**Peer reviewer:** Mohammed Alsufyani