

Basal Cell Nevus Syndrome: A Tale of Ancient Mummies and Cyclopic Sheep

Solomon Geizhals, Eve Lowenstein

Solomon Geizhals, BA, MD Candidate Class of 2019, SUNY Downstate Medical School, 1206 Virginia Street, Far Rockaway NY 11691, the United States

Eve Lowenstein, MD, PhD, Department of Dermatology, SUNY Downstate Medical School, Box 46, 450 Clarkson Avenue, Brooklyn NY 11203, the United States

Conflict-of-interest statement: The author(s) declare(s) that there is no conflict of interest regarding the publication of this paper.

Open-Access: This article is an open-access article which was selected by an in-house editor and fully peer-reviewed by external reviewers. It is distributed in accordance with the Creative Commons Attribution Non Commercial (CC BY-NC 4.0) license, which permits others to distribute, remix, adapt, build upon this work non-commercially, and license their derivative works on different terms, provided the original work is properly cited and the use is non-commercial. See: <http://creativecommons.org/licenses/by-nc/4.0/>

Correspondence to: Solomon Geizhals, BA, MD Candidate Class of 2019, SUNY Downstate Medical School, 1206 Virginia Street, Far Rockaway NY 11691, the United States.

Email: ygeizhals@yahoo.com

Telephone: +1-917-444-0678

Received: April 10, 2017

Revised: May 24, 2017

Accepted: August 2, 2017

Published online: December 26, 2017

ABSTRACT

Disease has left its record upon this earth from before a written or historic record is available. The study of mummies and human remains in the last 100 years has shed light on numerous diseases. Diseases previously prominent in society such as tuberculosis and leprosy, are well represented in the paleorecord. Even rare diseases whose identities were unknown until recent times have been evidenced in the paleorecord. Basal cell nevus syndrome, also known as Gorlin-Goltz syndrome, is a rare, heritable, autosomal-dominant condition with complete penetrance and variable expressivity. Although this disease was first recognized by Jarisch and White in 1894 and its spectrum elaborated by Gorlin and Goltz in 1960, the archeological

finding of Egyptian Dynastic brothers exhibits proof of this disease in the paleorecord antedates these descriptions by over 3000 years. A look at the original finding and how far our knowledge has come in understanding this disease is the focus of this review.

Key words: Basal cell nevus syndrome; Gorlin- Goltz syndrome; mummies; Paleopathology; cyclopia

© 2017 The Author(s). Published by ACT Publishing Group Ltd. All rights reserved.

Geizhals S, Lowenstein E. Basal Cell Nevus Syndrome: A Tale of Ancient Mummies and Cyclopic Sheep. *Journal of Dermatological Research* 2017; 2(4): 116-119 Available from: URL: <http://www.ghrnet.org/index.php/jdr/article/view/2041>

BACKGROUND

Basal cell nevus syndrome, or BCNS, is a rare genetic disorder with mutation of the human homolog of *Drosophila* PTCH1 gene on chromosome 9q22.3-q31^[1]. Its protein product, Patched, is a transmembrane receptor that binds to Sonic Hedgehog receptor (SHH). When Patched is not bound to SHH, it is free to inhibit Smoothed (SMO) downstream. SMO is a transmembrane G-protein which is constitutively active unless inhibited by Patched^[2]. When uninhibited, SMO activates its downstream target Gli for cell growth, but this signal can be blocked by the recently described Suppressor of Fused gene (SUFU), which binds to and inhibits Gli transcription (Diagram 1).

BCNS is rare with estimated prevalence ranging from 1 in 57,000^[1] to 1 in 256,000^[3]. The signs and symptoms of BCNS appear gradually, hence, diagnosis is typically delayed till from late teens to as late as mid-thirties. This autosomal dominant disorder, while having no ethnic or sexual predilection, tends to have less severe and later onset of skin cancer in darker-skinned patients, due to the skin pigment protection of DNA in basal nuclei from ultraviolet radiation^[4].

Although the symptoms and manifestations of BCNS was first examined and elaborated by Gorlin and Goltz in their seminal piece in 1960^[5], the diagnosis has evolved from the simple triad of bifid ribs, jaw cysts and basal cell carcinoma. Diagnosis is now based on the presence of either one major criterion and genetic confirmation, or two major criteria, or one major and two minor criteria. (Table 1)

Some of the major criteria include: a BCC prior to 20 years of age or excessive numbers of BCCs out of proportion to prior sun exposure and skin type, odontogenic keratocyst of the jaw prior to 20 years of age, the existence of palmar or plantar pitting, medulloblastoma, lamellar calcification of the falx cerebri, or a first degree relative with BCNS. Minor criteria include rib anomalies (ie; bifid ribs), other specific skeletal malformations and radiologic changes (i.e., vertebral anomalies, kyphoscoliosis, brachymetacarpalia, postaxial polydactyly), macrocephaly, cleft/lip palate, ovarian/cardiac fibroma, lymphomesenteric cysts and ocular abnormalities, such as strabismus, hypertelorism, congenital cataracts, glaucoma^[6]. It should be noted, that patients with a SUFU mutation present clinically with greater risk of medulloblastomas, but lack of odontogenic keratocysts^[7].

THE OLDEST DOCUMENTED CASE OF BCNS

Paleodermatology is the study of the integument and associated diseases as demonstrated in the remains of former times^[8]. The skeletal remains of two excavated Egyptian brothers of the Dynastic period present with findings consistent with BCNS^[9]. The younger male's (20-25 years old) remains demonstrate findings consistent with an odontogenic cyst, a bifid rib (Figure 1), incompletely fused sacral laminae and brachymetacarpalia (shortened 4th finger) (Figure 2). The older male (60+/- 10 years) presented with multiple probable odontogenic cysts (Figure 3), multiple bifid ribs, incomplete fusion of the sacrum, disturbed vertebra from osteoarthritis and extensive ventral lipping, and enlarged sella turcica with an asymmetrical occiput (Figure 4), and brachymetacarpalia of the 4th digit. The paleo-evidence clearly supports the diagnosis of BCNS under the current criteria. Both brothers exhibited the major criteria of

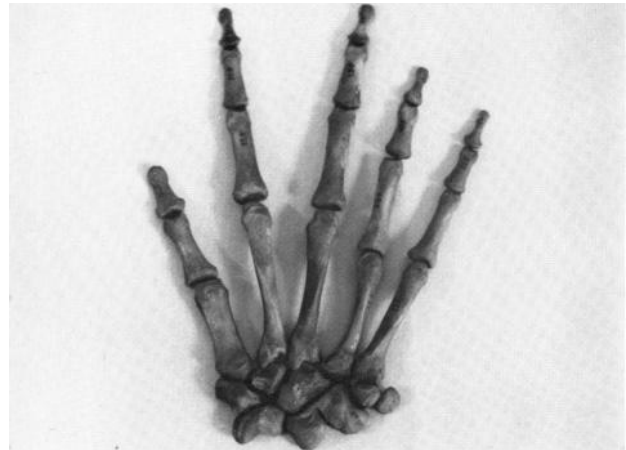

Figure 2 Brachymetacarpalia (shortened 4th finger)- Reprinted with permission from the Cambridge Journal of Medical History.



Figure 3 Multiple odontogenic cysts- Reprinted with permission from the Cambridge Journal of Medical History.

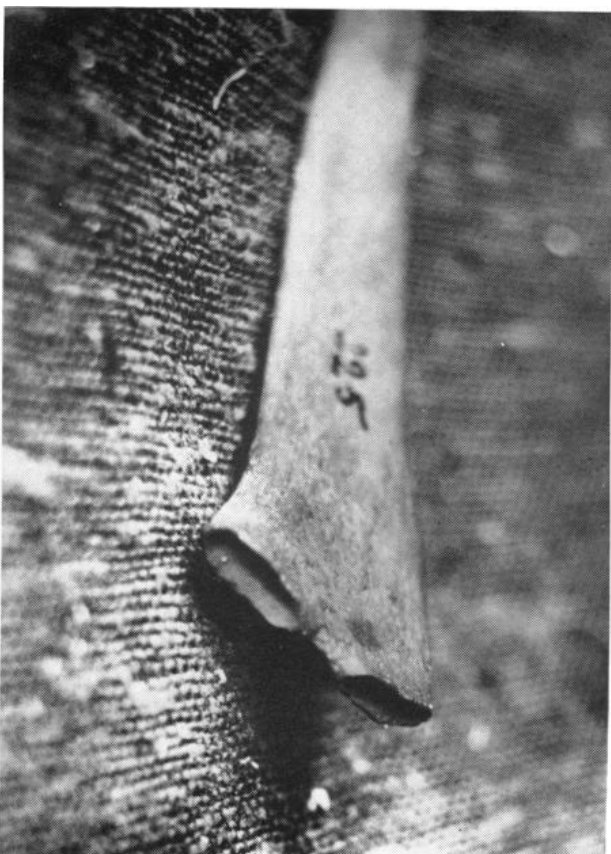

Figure 1 A bifid rib- Reprinted with permission from the Cambridge Journal of Medical History.

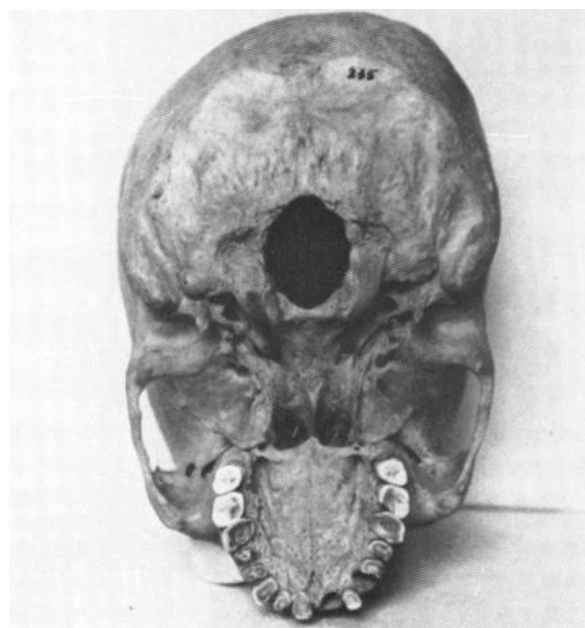


Figure 4 An enlarged sella turcica with an asymmetrical occiput- Reprinted with permission from the Cambridge Journal of Medical History.

Table 1 Diagnostic Criteria for Gorlin- Goltz Syndrome[4].

Major Criteria	Minor Criteria
Odontogenic keratocytes of jaw prior to 20 years of age	Macrocephaly
Palmar/plantar pits	Rib abnormalities (fused, splayed, bifid)
Lamellar calcifications of falx cerebri	Skeletal abnormalities (Sprengel deformity, pectus deformity, syndactyly of digits, kyphoscoliosis)
First-degree relative with Gorlin-Goltz Syndrome	Congenital anomalies (cleft lip or palate, frontal bossing, coarse facies)
Multiple BCCs, out of proportion to those expected from sun damage, or one in a patient < 20 years old	Radiological anomalies (bridging of sella turcica, vertebral abnormalities, flame-shaped lucencies of hands and feet)
Medulloblastoma (desmoplastic) in early childhood	Ovarian fibroma, cardiac fibroma
	Lymphomesenteric cysts
	Ocular abnormalities (cataracts, developmental defects, retinal epithelium pigmentary changes, glaucoma, colobma)

odontogenic cysts and an affected first degree relative, as well as multiple minor criteria including skeletal and rib abnormalities. The paleodermatological findings of the Egyptian brothers exhibits the symptoms of BCNS that predates Gorlin and Goltz’s analysis by over 3000 years^[10].

Although one of the Egyptian brothers lived until 60+/- 10 years old, Gorlin Syndrome, while associated with an increased morbidity, has not been linked to a decreased mortality. Life expectancy for Gorlin Syndrome was recently determined to be over 73 years, which is slightly lower than the current mean of general population of 80 years, but not by a tremendous effect^[11].

The care and treatment of Gorlin Syndrome is multifaceted. Counseling for sun avoidance and protection is advisable for BCC prophylaxis. Appropriate surveillance includes annual MRIs for medulloblastomas until the age of 8 (incidence thereafter is uncommon) and regular skin exams for BCCs. Dental screening for dental cysts, EKGs for cardiac fibromas, visual and auditory screening should also be utilized. Additionally, patients should be offered psychological assessments and counseling for comorbid depression^[4]. Primary prevention of skin cancer with sun avoidance and protective measures is recommended. Surgical excision of BCCs, ablative laser therapies and phototherapy are all treatment options, although they all treat the sequelae and don’t target the underlying cause: the mutated PTCH1 gene. Moreover, radiologic treatment is contraindicated because individuals with BCNS are very sensitive to ionizing radiation and can develop hundreds of tumors following radiotherapy for medulloblastomas ^[2]. Recently, the scientific world has focused on targeting the underlying genetic mutations and biochemical pathways via the utilization of cyclopamine and vismodegib.

Cyclopamine was discovered after an 11-year investigation in the 1950s of several cyclopic lambs that were born to sheep that grazed on wild corn lily, or *Veratrum californicu*, at a farm in Idaho ^[12]. In 2000, the mechanism where sonic hedgehog pathway and SMO function in embryogenesis causing cyclopia was proposed. SHH protein from the prechordal plate suppresses Pax6 expression, crucial in localization of eye development in the embryo, causes lateralization of the orbital fields during embryogenesis^[13]. Cyclopamine inhibits both cell proliferation, making it both a teratogen and a tumor suppressor^[14]. However, given cyclopamines has poor oral bioavailability, low receptor affinity and inadequate pharmacokinetics, a more potent, acid stable and soluble cyclopamine derivative, IPI-926 has been developed and has entered Phase I trials^[15].

Vismodegib, earlier named GDC-0449, also inhibits SMO, but with greater potency and more favorable pharmaceutical properties than cyclopamine^[16]. Vismodegib is the first-in-class, orally bioavailable SHH signaling pathway inhibitor to reach the market^[17]. However,

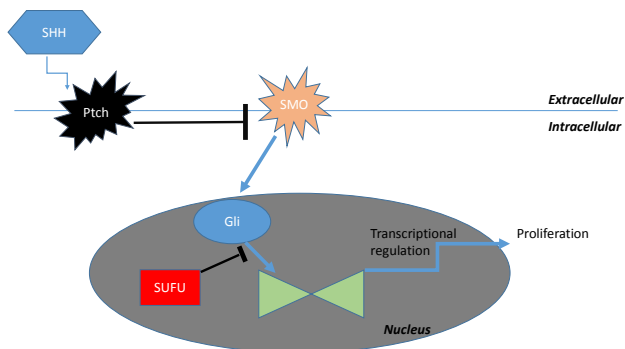


Figure 5 The Sonic Hedgehog Signal Transduction Pathway. SHH: Sonic Hedgehog; Ptc1: Patched transmembrane protein; SMO: Smoothened receptor; Gli: Gli family of transcription factors; SUFU: Suppressor of Fused gene.

this greater potency and its teratogenic effects leads to a multitude of side-effects. In one study, 54% of patients receiving treatment discontinued the medication owing to side effects, and only 1 of 5 eligible patients were able to continue Vismodegib for 18 months. The grade 1 and 2 adverse events included loss of taste, muscle cramps, hair loss, and weight loss. Patients receiving Vismodegib had more grade 3 or 4 adverse events as compared with patients receiving placebo^[18] (Figure 5).

CONCLUSION

The mummified remains of 3000-year old Egyptian brothers clearly bear witness to and evidence the existence of this rare syndrome BCNS that is a focus of great scientific inquiry today. Fifty years since the discovery of the wild lily grazed upon by sheep that developed cyclopia, this pathway and syndrome continue to fascinate us and teach us a great deal about embryogenesis and tumor biology.

REFERENCES

1. Farndon PA, Del Mastro RG, Kilpatrick MW, Evans, DRG. Location of gene for Gorlin syndrome. *The Lancet* 1992; **339(8793)**: 581-582. [PMID: 1347096]; [DOI: 10.1016/0140-6736(92)90868-4]
2. Bologna J, Jorizzo JL, Schaffer, JV. *Dermatology*. 3rd edition. Elsevier Saunders. 2012. 1767-1768, 1778-1779.
3. Muzio LL. Nevoid basal cell carcinoma syndrome (Gorlin syndrome). *Orphanet journal of rare diseases* 2008; **3(1)**: 32. [PMID: 19032739]; [DOI: 10.1186/1750-1172-3-32]
4. John AM, Schwartz RA. Basal cell naevus syndrome: an update on genetics and treatment. *British Journal of Dermatology*. 2016; **174(1)**: 68-76. [PMID: 26409035]; [DOI: 10.1111/bjd.14206]
5. Gorlin RJ, Goltz RW. Multiple nevoid basal-cell epithelioma, jaw

- cysts and bifid rib. A syndrome. *N Engl J Med* 1960; **262**: 908-912. [PMID: 13851319]; [DOI: 10.1056/NEJM196005052621803]
6. Bree AF, Maulik RS. Consensus statement from the first international colloquium on basal cell nevus syndrome (BCNS). *American Journal of Medical Genetics* 2011 Sep; **155A(9)**: 2091-2097. [PMID: 21834049]; [DOI: 10.1002/ajmg.a.34128]
 7. Smith MJ, Beetz C, Williams SG, Bhaskar SS, O'Sullivan J, Anderson B, Daly SB, Urquhart JE, Bholah Z, Oudit D, Cheesman E. Germline mutations in SUFU cause Gorlin syndrome-associated childhood medulloblastoma and redefine the risk associated with PTCH1 mutations. *Journal of Clinical Oncology* 2014; **32(36)**: 4155-4161. [PMID: 25403219]; [DOI: 10.1200/JCO.2014.58.2569]
 8. Lowenstein EJ. Paleodermatoses: lessons learned from mummies. *J Am Acad Dermatol.* 2004 Jun; **50(6)**: 919-936. [PMID: 15153895]; [DOI: 10.1016/S0190-9622(03)00914-9]
 9. \Satinoff MI, Wells C. Multiple basal cell naevus syndrome in ancient Egypt. *Med Hist* 1969; **13(3)**: 294-297. [PMID: 4893629]; [DOI: 10.1017/S0025727300014563]
 10. Lowenstein EJ. Genodermatoses among the ancients: basal cell nevus syndrome in Egyptian dynastic brothers. *Skinmed* 2011; **9(2)**: 117-118. [PMID: 21548519]
 11. Wilding A, Ingham SL, Laloo F, Clancy T, Huson SM, Moran A, Evans DG. Life expectancy in hereditary cancer predisposing diseases: an observational study. *Journal of medical genetics* 2012; **49(4)**: 264-269. [PMID: 22362873]; [DOI: 10.1136/jmedgenet-2011-100562]
 12. Binns W, Thacker EJ, James LF, Huffman WT. A congenital cyclopiantype malformation in lambs. *Journal of the American Veterinary Medical Association* 1959; **134(4)**: 180-183. [PMID: 13630801]
 13. Gilbert SF. *Developmental biology: the anatomical tradition.* 2000. Available from: URL: <https://www.ncbi.nlm.nih.gov/books/NBK10024/>
 14. Chen JK, Taipale J, Cooper MK, Beachy PA. Inhibition of Hedgehog signaling by direct binding of cyclopamine to Smoothened. 2002. *Genes & development* 2002 Nov 1; **16(21)**: 2743-2748. [PMID: 12414725]; [DOI: 10.1101/gad.1025302]
 15. Abidi A. Hedgehog signaling pathway: A novel target for cancer therapy: Vismodegib, a promising therapeutic option in treatment of basal cell carcinomas. *Indian Journal of Pharmacology* 2014; **46(1)**: 3-12. [PMID: 24550577]; [DOI: 10.4103/0253-7613.124884]
 16. LoRusso PM, Rudin CM, Reddy JC, Tibes R, Weiss GJ, Borad MJ, Hann CL, Brahmer JR, Chang I, Darbonne WC, Graham RA, Zerivitz KL, Low JA, Von Hoff DD. Phase I trial of hedgehog pathway inhibitor vismodegib (GDC-0449) in patients with refractory, locally advanced or metastatic solid tumors. *Clinical Cancer Research.* 2011; **17(8)**: 2502-2511. [PMID: 21300762]; [DOI: 10.1158/1078-0432.CCR-10-2745]
 17. Cowey CL. Targeted Therapy for Advanced Basal-Cell Carcinoma: Vismodegib and Beyond. *Dermatology and Therapy.* 2013; **3(1)**: 17-31. [PMID: 23888252]; [DOI: 10.1007/s13555-013-0019-9]
 18. Tang JY, Mackay-Wiggan JM, Aszterbaum M, Yauch RL, Lindgren J, Chang K, Coppola C, Chanana AM, Marji J, Bickers DR, Epstein EH Jr. Inhibiting the hedgehog pathway in patients with the basal-cell nevus syndrome. *New England Journal of Medicine.* 2012; **366(23)**: 2180-2188. [PMID: 22670904]; [DOI: 10.1056/NEJMoa1113538]

Peer reviewer: Orit Markowitz