

## Definitive Radiotherapy for Basal Cell Carcinoma and Cutaneous Squamous Cell Carcinoma of the Nose

David Gregory Tighe<sup>1</sup>, Bianca Karle<sup>2</sup>, Amelia Hollands<sup>2</sup>, Gavin Gottschalk<sup>3</sup>, Christina Saywell<sup>4</sup>, Terence Poon<sup>5</sup>, Tanya Gilmour<sup>6</sup>, Jillian Wells<sup>7,8</sup>, Jonathan Stretch<sup>9,10,11</sup>, Anne O'Neill<sup>7,8</sup>, Nina Wines<sup>12</sup>, Michael Li<sup>3</sup>, Andrea Jopp-McKay<sup>9</sup>, Gerald Blaise Fogarty<sup>2,13,14,15</sup>

1. Faculty of Medicine, University of New South Wales, Kensington, NSW, 2033, Australia

2. Genesis Care, Mater Hospital, 25 Rocklands Rd, Crows Nest, NSW, 2065, Australia

3. Chatswood Dermatology Centre, Suite 3, 6 McIntosh Street, Chatswood, NSW, 2067, Australia

4. Mosman Dermatology, Shop 34 Level 1, 1-3 Brady St, Mosman, NSW, 2088, Australia

5. Neutral Bay Laser & Dermatology Clinic, Suite 202, 156 Military Rd, Neutral Bay, NSW, 2088, Australia

6. North Shore Dermatology, Suite 502 Level 5/39, Esplanade, Manly, NSW, 2095, Australia

7. Department of Dermatology, Westmead Hospital, Hawkesbury Rd, Westmead, NSW, 2145, Australia

8. Harbourside Dermatology, Master Gunners Cottage, 1100 Middle Head Road, Mosman, NSW, 2088, Australia

9. Melanoma Institute Australia, The University of Sydney, North Sydney, NSW, Australia

10. Sydney Medical School, The University of Sydney, NSW, Australia

11. Royal Prince Alfred Hospital, Camperdown, NSW, Australia

12. Northern Sydney Dermatology, Suite 2D Level 2, 115 Sailors Bay Rd, Northbridge, NSW, 2063, Australia

13. Genesis Care, St Vincent's Hospital, Victoria St, Darlinghurst, NSW, 2010, Australia

14. Faculty of Engineering, University of Technology Sydney, 15 Broadway, Ultimo, NSW, 2007 Australia

15. School of Medicine, The University of Notre Dame Australia, 160 Oxford St, Darlinghurst NSW 2010 Australia

**Conflict-of-interest statement:** The author(s) declare(s) that there is no conflict of interest regarding the publication of this paper.

**Open-Access:** This article is an open-access article which was selected by an in-house editor and fully peer-reviewed by external reviewers. It is distributed in accordance with the Creative Commons Attribution Non Commercial (CC BY-NC 4.0) license, which permits others to distribute, remix, adapt, build upon this work non-commercially, and license their derivative works on different terms, provided the original work is properly cited and the use is non-commercial. See: <http://creativecommons.org/licenses/by-nc/4.0/>

Correspondence to: Professor Gerald Fogarty, Genesis Care, St Vincent's Hospital, Victoria St, Darlinghurst, NSW, 2010, Australia.

Email: [Gerald.fogarty@genesiscare.com](mailto:Gerald.fogarty@genesiscare.com)

Telephone: +612 8302 5400

Fax: +612 8302 5410

Received: February 23, 2019

Revised: April 7, 2019

Accepted: April 10, 2019

Published online: May 13, 2019

### ABSTRACT

**AIM:** This study is a retrospective audit of a single clinician's treatment of basal cell carcinoma (BCC) and cutaneous squamous cell carcinoma (cSCC) of the nasal skin with definitive radiotherapy (RT). Of those patients that were followed up by the referring dermatologists, local control and late side effects are reported. This study also aims to investigate the referral characteristics over time.

**MATERIALS AND METHODS:** Medical records were searched for patients with nasal BCCs and cSCCs treated by a single clinician between January 2006 and December 2016 at three sites in Sydney (Mater Hospital, St Vincent's Hospital, and Macquarie University Hospital). Patient, tumour, and treatment factors were collected. Oncological and cosmetic outcome data was obtained by asking referring dermatologists to complete a questionnaire for their referred patients.

**RESULTS:** 93 patients were identified. 57% were female, and the median age was 76. There were 94 BCCs and 7 cSCCs with four patients having two or more lesions treated. Outcome data was available for 40 patients, and median duration of follow-up was 41 months. As at September 2018, 3 BCCs (7.5%) recurred locally, with a mean time to recurrence of 19 months. Late side effects were seen in five patients treated for BCCs. The most common late side effect seen was telangiectasia (3). The rate of referral to the clinician started at 20 referrals in the 2006-2009 period and increased to 43 in the 2014-2016 period.

**CONCLUSION:** This study supports the use of definitive RT in BCC and cSCC of the nose, with minimal late side effects. Referrals increased steadily over the study period.

**Key words:** Skin Neoplasms; Basal Cell Carcinoma, Squamous Cell Carcinoma, Non-melanoma skin cancer, Radiotherapy.

© 2019 The Author(s). Published by ACT Publishing Group Ltd. All rights reserved.

Tighe DG, Karle B, Hollands A, Gottschalk G, Saywell C, Poon T, Gilmour T, Wells J, Stretch J, O'Neill A, Wines N, Li M, Jopp-McKay A, Fogarty GB. Definitive Radiotherapy for Basal Cell Carcinoma and Cutaneous Squamous Cell Carcinoma of the Nose. *Journal of Dermatological Research* 2019; **4(1)**: 156-162 Available from: URL: <http://www.ghrnet.org/index.php/jdr/article/view/2528>

## INTRODUCTION

Non-melanoma skin cancer (NMSC) is the most common type of cancer in humans<sup>[1,2]</sup>. Australia has the highest incidence of NMSC in the world<sup>[2]</sup>, and within Australia NMSC receives the second highest expenditure on cancer, following colorectal cancer<sup>[3]</sup>. Basal cell carcinoma (BCC) and cutaneous squamous cell carcinoma (cSCC) are the two most commonly diagnosed NMSCs<sup>[1]</sup>.

Surgical excision is considered the 'gold standard' treatment for both BCC and cSCC, and there is evidence to substantiate this<sup>[4-9]</sup>. However, surgery may not be suitable for all lesions, especially in areas where surgery may lead to functional or cosmetic morbidity through tissue loss, such as nasal lesions. Furthermore, surgical excision with primary closure of skin tumours on the nose can be difficult due to the poor elasticity of skin in this area, which limits mobility<sup>[10]</sup>. This may then require a flap repair or a skin graft, and these problems may be amplified for larger lesions<sup>[11]</sup>. Radiotherapy (RT) may be an appropriate and equally efficacious option in these circumstances.

There is limited high-level, prospective evidence comparing the efficacy of surgical excision and RT for BCC and cSCC in this patient population<sup>[8,12]</sup>. There is a paucity of Australian data of any level of evidence in this context, despite its prevalence and accepted use of RT for this indication in Australia.

This study is a retrospective audit of a single clinician's treatment with definitive three-dimensional conformal RT (3DCRT) of BCCs and cSCCs on the nose at Genesis Care, St Vincent's Hospital, Genesis Care, Mater Hospital, and Genesis Care, Macquarie University Hospital, in Sydney, Australia. The aim of this study was to assess the efficacy of RT in treating this patient population and to measure the growth of a skin-specific radiotherapy practice.

## METHODS

This project was approved by the Bellberry Human Research Ethics Committee (application number 2018-03-163). Electronic medical records were searched for patient files detailing definitive RT of patients with a biopsy-proven BCC or cSCC on their nose. Inclusion criteria required patients to be over 18 years of age and to be treated with definitive intent by a single radiation oncologist (RO) (GBF) between January 2006 and December 2016. Case referral per year was calculated.

Patient, tumour, and treatment factors were collected for analysis. Patient factors included sex, age, date of referral, and immune status. Tumour factors included the histopathological diagnosis (BCC or cSCC), site, and macroscopic size in greatest diameter of the tumour. Treatment factors included the radiotherapy date, dose and duration, modality used (superficial radiotherapy, 6 mega electron volts (MeV) dosed to 90%, 6 megavoltage photons (MV) dosed to 100%, or

brachytherapy), and field size diameter.

To obtain outcome data, each patient's referring dermatologist was invited to participate in the study. Referring physicians were sent a questionnaire and a list of patients which they had referred for RT. Completed questionnaires provided data on oncological and cosmetic outcomes, including local recurrence (defined as recurrence of the lesion within the previous RT treatment field), salvage therapies used for recurrent tumours, and late radiation side effects at last follow-up. All data was then collated and analysed.

## Methods of Radiotherapy Techniques

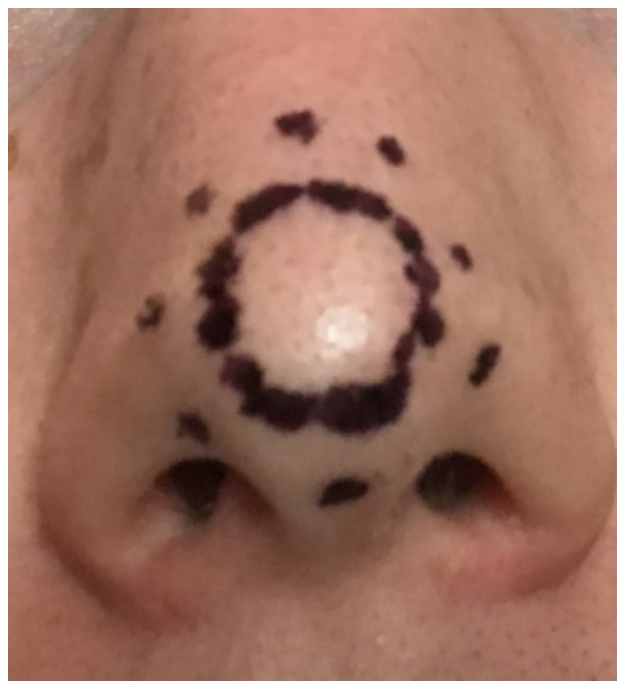The main RT techniques used in these linear accelerator (Linac) dependent departments were 3DCRT. These techniques are described here.

Following consent for and prescription of RT, patients proceeded to planning. This requires multiple processes, including a nursing assessment and treatment simulation.

During simulation, RT treatment position on the treatment machine, usually a Linac, is simulated and captured on an imaging platform, usually a computed tomography (CT) scanner. The patient is immobilised in a comfortable and reproducible position, and the RO clinically marks on the skin the treatment area (Figure 1). When treating nasal lesions, a personalised thermoplastic mask is made and the RO's marks are transferred onto the mask. To aid tumour delineation, wire is placed over these marks to capture them on the CT scan.

Linacs produce skin sparing megavoltage beams, meaning that the peak dose is actually millimetres underneath the skin, depending on the modality and generating energy used. To ensure full dose to skin, a tissue equivalent material known as a bolus is placed on the skin so that the peak dose falls on the true skin surface. The configuration of the bolus differs depending on megavoltage modality used, whether electrons (MeV) or photons (MV).

The position of the cancer on the nose determines the technique used. Where the RO-marked area extends bilaterally on the nose a photon beam approach will be utilized. This is typical if the tip



**Figure 1** RO marks cancer (inner circle) and treatment field (outer circle) on tip of nose.

of nose is involved. If only one side of the nose is identified for treatment, electrons can be used.

**Bilateral nose positioning:** the patient is positioned in a “neutral” position. In this position, the palate is vertical on the CT scan and a headrest supports the neck. A “nose block” is made by filling a small plastic box with bolus (Figure 2). This block is then placed in position over the nose, ensuring that no RO marks or CT wires can be seen when the block is in place. The patient has a CT scan which is transferred electronically to the planning system. With the aid of the wires, the treatment field is captured on the CT. The RO then contours the volumes to be treated and organs to be avoided with RT on the CT scan image, and prescribes radiation to these volumes. The dosimetrists then design beams to achieve the prescription and the RO approves when satisfactory (Figure 3). Treatment can begin when quality assurance benchmarks are met.

**Unilateral nose positioning:** At simulation, the patient is positioned with their head turned to the contralateral side and the nose taped to this side to ensure a flat treatment surface. The nostril is filled with bolus to prevent RT going through the thin alar and unnecessarily irradiating the midline septum. A thermoplastic mask is made with the patient in this position, and the RO marks are transferred onto the mask and wired (Figure 4, Figure 5). The CT scan is performed in this position.

**Electron planning:** a single 6 or 9MeV field is used with RO-prescribed bolus thickness to ensure prescription dose on skin. Field geometry is determined by skin apposition of the Linac head. The electron-defining “cut-out” used should adequately cover the RO

marks. Plan review ensures the CT wires are covered by 90% of the prescribed dose (Figure 6).

## RESULTS

### Patient factors

93 patients with BCCs or cSCCs on their nose were treated from January 1 2006 to December 31 2016 (Table 1). 43% of patients were male and 57% were female. The mean age at treatment was

Table 1 Patient characteristics (n = 93)

Variable	Number	Percentage (%)
<b>Sex</b>		
Male	40	43
Female	53	57
<b>Age at treatment †</b>		
Mean	76	
Range	53-94	
<b>Referrals per period</b>		
2006 – 2009	20	22
2010 – 2013	31	33
2014 – 2016	42	45
<b>Immune status before or after treatment</b>		
Immunocompetent	82	88
Immunosuppressed	11 †	12

† If a patient had multiple lesions treated, the age at their first treatment was used. ‡ Rheumatoid arthritis = 2; Myelodysplasia = 2; Immune thrombocytopenic purpura = 1; Polymyalgia rheumatica = 1; Inflammatory myopathy = 1; Ulcerative colitis = 1; Vasculitis = 1; Pituitary failure = 1; Non-Hodgkin’s lymphoma = 1.




Figure 2 Treatment position for bilateral nose involvement, utilising mask and block bolus. A: Lateral projection; B: Anterior projection.

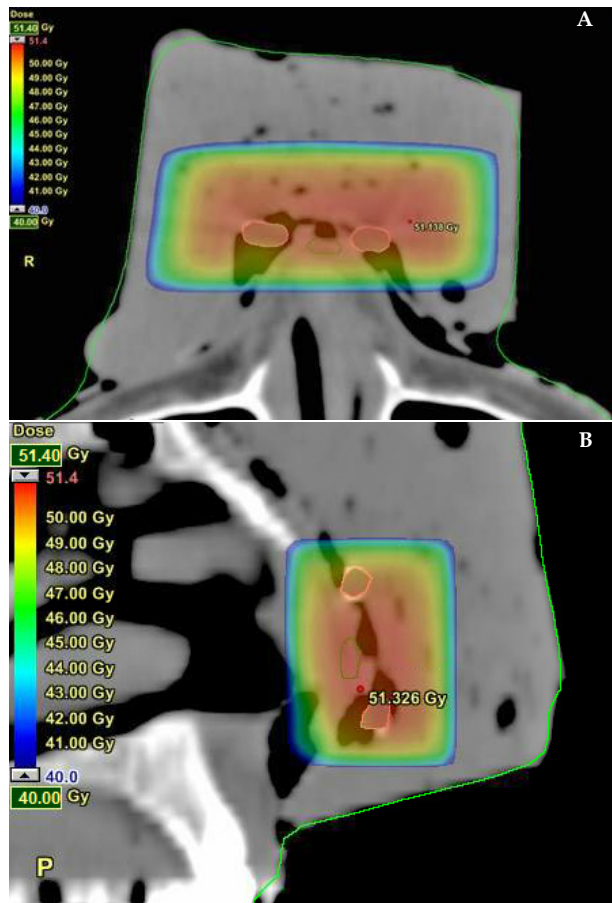


Figure 3 Dosimetry on planning CT for bilateral nose involvement. A: Axial dosimetry; B: Sagittal dosimetry



76 (range 53-94). The rate of referral to the clinician started at 20 referrals in the 2006-2009 period and increased to 42 in the 2014-2016 period (Figure 7). 11 patients were immunosuppressed before, during, or after their treatment. The most common reasons for immunosuppression were medications to treat rheumatoid arthritis, and myelodysplasia. These factors are detailed in Table 1.

### Tumour factors

BCC was the predominate histopathological diagnosis (96) with 7 cSCCs (Table 2). Lesion site was determined according to Figure 8. The most common lesion location was on the tip of nose (34[33%]) followed by the right ala (31[30%]). Types of BCC were diverse, with nodular type being the most common (33[34%]), followed by infiltrative and nodular-infiltrative (14 [15%] for both). Mean macroscopic lesion size, determined clinically, was 1.5 centimetres (range 0.3-4 cm). Lesion size was unavailable from the medical records for 21 patients.

### Treatment factors

RT dosages were usually prescribed according to a three-week fractionation pattern of 45 Gray (Gy) in 15 fractions at five fractions per week (14); or a four-week pattern of 50 Gy in 20 fractions at five fractions per week (21). This meant that most treatments (60 lesions)

Table 2 Tumour characteristics (n = 103 †).

Variable	Number	Percentage (%)
<b>Histopathological diagnosis</b>		
BCC	96	93
cSCC	7	7
<b>Site on nose of BCC or cSCC (n = 103) ‡</b>		
Tip	34	33
Right ala	31	30
Right alar crease	1	1
Left ala	17	17
Left alar crease	4	3
Bridge	16	16
<b>Type of BCC (n = 96)</b>		
Nodular	33	34
Infiltrative	14	15
Nodular-infiltrative	14	15
Morphoeic	8	8
Superficial	7	7
Micronodular	1	1
Other §	5	5
Not documented in histopathology report	10	11
No histopathology available	4	4
<b>Macroscopic lesion size (centimetres) of BCCs (n = 96)</b>		
0-0.99	8	8
1-1.99	49	51
2-2.99	15	16
3-3.99	2	2
≥ 4	1	1
Unknown	21	22
Mean	1.5	
Range	0.3-4	

† Four patients had two or more lesions treated. ‡ See Figure 8 for diagram of external nose anatomy. § Lesions with combined histological subtypes. BCC: basal cell carcinoma; cSCC: cutaneous squamous cell carcinoma

were clustered around a radiation dose of between 45 and 50 Gy. 6MeV was the most common modality used to deliver radiation, followed by 6MV (43[42%] and 38[37%] respectively; Table 3). 3DCRT was therefore the most common treatment modality. Mean field size maximum diameter was 3.7cm (range 1-6.5).

### Outcome factors

Outcome data was available for 40 patients (Table 4). Median duration of follow up was 41 months (range 0-108). Follow-up duration was unknown for 11 patients, five of whom did not present

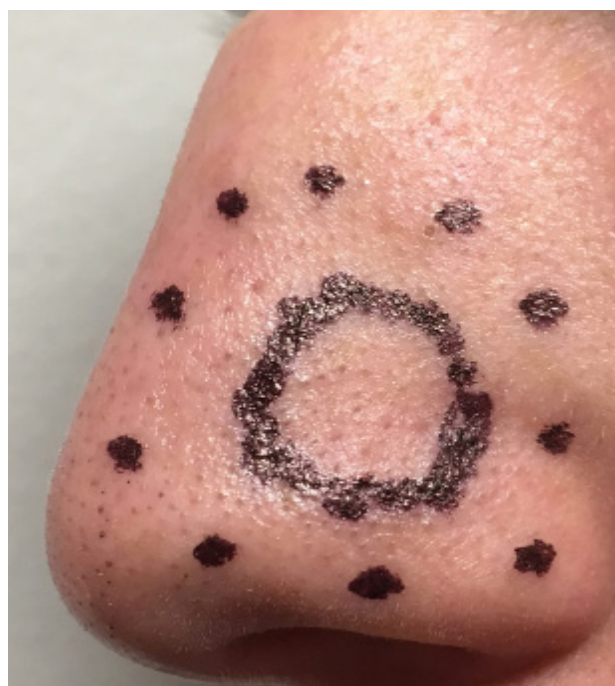

Figure 4 RO marks cancer (inner circle) and treatment field (outer circle) on nasal ala.

Table 3 Treatment characteristics (n = 103).

Variable	Number	Percentage (%)
<b>Radiotherapy dose</b>		
≤40	4	4
40 - 44.99	3	3
45 - 49.99	32	31
50 - 54.99	28	27
≥55	8	8
Early cessation of treatment †	23	22
Incomplete ‡	5	5
<b>Modality</b>		
6MeV	43	42
6MV	38	37
Superficial radiotherapy	15	14
Brachytherapy	7	7
<b>Field size maximum diameter (cm)</b>		
Mean	3.7	
Range	1 - 6.5	
Not recorded	33	

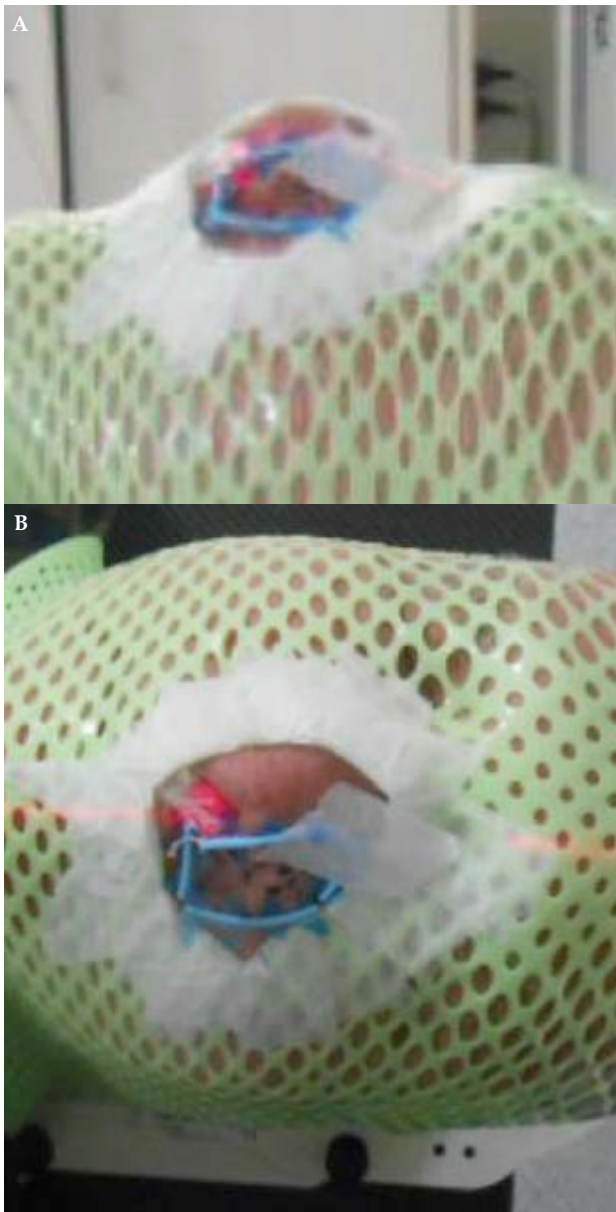†Treatment was ceased early if the radiation oncologist deemed that adequate radiation had been delivered to treat the lesion based on radiation reaction as judged clinically. ‡No-show = 2; infection = 1; requirement for analgesia = 1; unknown = 1

to their referring physician following the RT end date.

**Oncological:** Local recurrence was defined as recurrence of the lesion within the previous treatment field. As at September 2018, 3 lesions had recurred locally (7.5%). The mean time to recurrence post RT was 1.6 years/19 months (range 0.7-2.2 years/8-26 months). All patients who had a local recurrence were immunocompetent.

All recurrent lesions were BCCs. One patient was an 80-year-old male with a 2cm BCC on his left ala of nodular-infiltrative type. The lesion received a total of 42Gy over 15 fractions at 5 fractions a week, delivered by superficial radiotherapy. The patient experienced late side effects of hypopigmentation and telangiectasia in the treatment field 4 months after the RT end date. Biopsy-proven recurrence occurred at the treatment field edge 23 months after the RT end date. The recurrence was treated with a further 40Gy in 20 fractions via superficial radiotherapy, following which there was complete tumour lysis and no recorded further recurrence. A 75-year-old female with a 1.5cm recurrence.

The second patient experiencing recurrence was a 78-year-old male



**Figure 5** Unilateral involvement at simulation. A: Lateral; B: Anterior projection in mask showing wires in place around treatment field, and “pink stuff” bolus in the contralateral nostril.

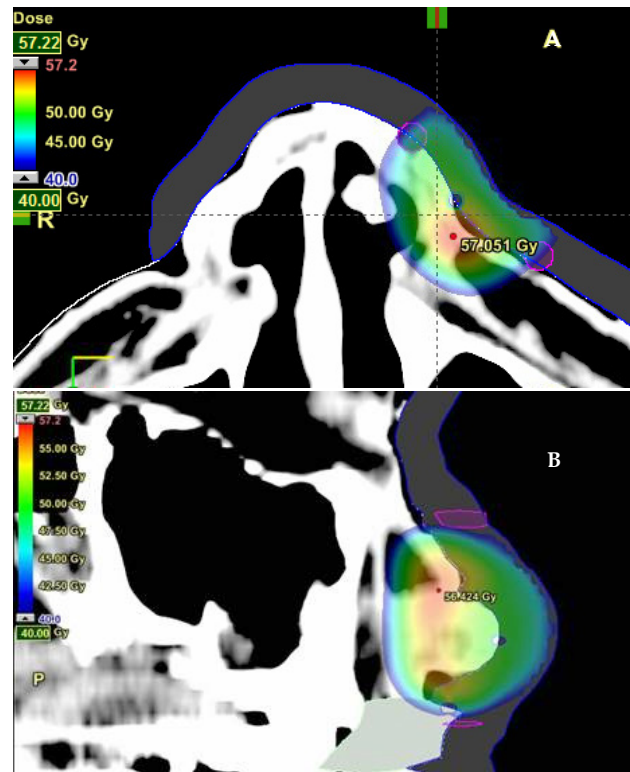
with a 1.5cm nodular BCC on his nasal bridge. 45Gy in 15 fractions at 5 fractions per week were delivered using 6MV. There were no late side effects, however the lesion recurred 26 months following the RT end date. The recurrence was diagnosed using confocal microscopy, and management of the lesion consisted of observation using this modality.

The third recurrence occurred in a 76-year-old male with a nodular

**Table 4** Outcomes (n = 40) Median duration of follow-up = 41 months (range 0-108 months) †.

Variable	Number	Percentage (%)
<b>ONCOLOGICAL</b>		
<b>Local recurrence</b>		
Yes	3	7.5%
No	37	92.5%
<b>Time to recurrence (months)</b>		
Mean	19	
Median	23	
Range	8 - 26	
<b>Method of diagnosing recurrence</b>		
Clinical	1	
Biopsy	2	
<b>Salvage therapy used</b>		
Observation	1	
Surgery	1	
Radiotherapy	1	
<b>COSMETIC</b>		
<b>Late side effects</b>		
Yes	5	12.5
No	33	82.5
Unknown	2	5

† See main text.



**Figure 6** Dosimetry for unilateral nose involvement. A: Axial dosimetry; B: Sagittal dosimetry

BCC on his right ala. The lesion was initially treated with 45Gy in 15 fractions at 5 fractions per week, delivered using 6MeV. Recurrence was biopsy-proven 8 months after the RT end date. The recurrent lesion was then salvaged surgically.

**Cosmetic:** Late side effects were defined as skin changes developing in the treatment field greater than 6 months post-RT end date. Five patients experienced late side effects, all treated for BCCs, with a median time to late side effect of 32.5 months. The most common late side effect seen was telangiectasia.

A 57-year-old female developed telangiectasia in the treatment field after being treated with 55Gy over 25 fractions at 5 fractions per week for a 1.5cm nodular-infiltrative BCC on the right ala. 6MeV was used. Late side effects were seen within 3 years and 5 months after the RT end date.

An 85-year-old female with a 0.8cm superficial BCC on her nasal tip developed a red papule two years following her RT end date. Her original lesion was treated with 53Gy over 25 fractions at 5 fractions per week using 6MV. The recurrent lesion was clinically diagnosed as a solar keratosis and resolved successfully with Aldara application.

A 75-year-old female with a 1.5 cm nodular-infiltrative BCC on her right nasal sidewall was treated with 57.5Gy over 23 fractions at 5 fractions per week delivered via 6MeV. Dosimetry towards the end of treatment revealed the lesion was receiving radiation below the planned dose, thus the dose was increased for the final three fractions. This patient developed telangiectasia in their treatment field within 4 years post-RT end date.

A 64-year-old male with nodular BCCs on his left and right ala had each lesion treated with 50Gy in 20 fractions at 5 fractions per week, delivered using superficial radiotherapy. Two years following his RT end date there was clinically dark pigmentation in the left ala treatment field, which was shown on biopsy to be post-inflammatory hyperpigmentation without evidence of neoplasia.

The fifth patient experiencing late side effects was the 80-year-old male who also experienced recurrence, described as the first case in the 'Oncological' section above.

All patients who developed late side effects were immunocompetent.

## DISCUSSION

In this retrospective audit of a single RO's practice, definitive RT for nasal BCCs and cSCCs showed a 7.5% recurrence rate at a median of 41 months follow-up duration. Randomised data for oncological outcomes includes the study by Avril *et al*<sup>[6]</sup>. This randomized control trial (RCT) observed the difference in local recurrence and cosmetic outcome between surgery and RT for BCC on the face<sup>[6]</sup>, the only RCT comparing these two modalities<sup>[7]</sup>. Surgery yielded a lower four-year local recurrence rate than RT with 0.7% for surgery compared with 7.5% for RT, similar to our study. The cosmetic outcome was rated as 'good' by a five judge panel in 87% of the surgery-treated patients compared to 69% of the RT-treated patients<sup>[6]</sup>. However, the majority of patients treated with RT in the trial were prescribed interstitial brachytherapy<sup>[6]</sup>, whereas external beam RT was the predominant modality used in our study. Our study is therefore consistent with level one evidence, with an acceptable oncological outcome following RT.

There has been no randomized control trial comparing patients with nasal cSCC treated by definitive RT with other modalities<sup>[12]</sup>. A systematic review of observational studies of treatment modalities for non-metastatic cSCC found surgical excision to be the superior treatment for this skin cancer<sup>[12]</sup>. However, the authors note that the

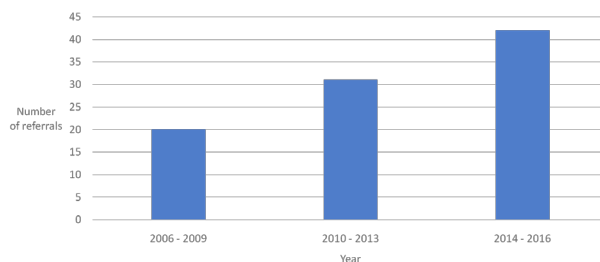


Figure 7 Referrals to the RO for nasal BCC and cSCC over a 10-year period.

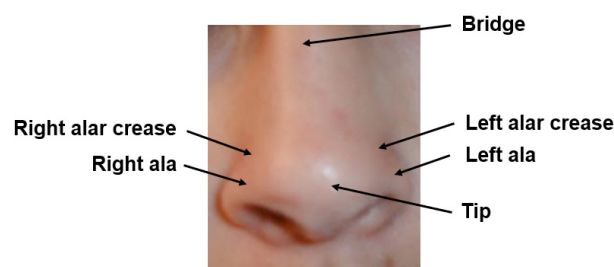


Figure 8 External nose anatomy.

limitations of the included studies render comparison of the outcomes of different radiation treatment modalities difficult. This study found a pooled average recurrence of 5.6% for nasal cSCCs treated with external beam RT<sup>[12]</sup>. The numbers of cSCCs in our study is too low for a meaningful comparison.

The efficacy rate of the RT was high. Therefore our study adds weight to the proposition that RT is an option to treat this tumour effectively when surgery is unsuitable, for example, when patients are elderly or anticoagulated<sup>[13,14]</sup>.

In our study, 87.5% of patients did not experience late side effects with RT. Five patients experienced late side effects, all treated for BCCs. The most common late side effect seen was telangiectasia(3). Randomised data for cosmetic outcomes includes the study by Petit *et al*<sup>[15]</sup>. This study compared the cosmetic results of patients treated for facial BCCs with either surgery or RT, finding that both patient and dermatologist-assessed cosmetic result significantly favoured surgery (87% of surgery-treated patients rated the cosmetic outcome as good, compared with 69% of the RT-treated patients; 79% of dermatologists involved in the trial rated surgery as good, compared to 40% for RT). However, there was no significant difference in the cosmetic outcomes between surgery and RT when the tumour was located on the nose<sup>[15]</sup>. Our study is consistent with the literature with acceptable cosmetic outcome following RT for BCCs on the nose.

This study tracks the development of a skin cancer RT service over time. The rate of referrals started at 20 in the 2006-2009 period and increased to 42 in the 2014-2016 period. Referral increase may signify that the referring dermatologists were appreciative of the service and the option of definitive RT for their patients with cutaneous nasal lesions. This study will hopefully encourage other radiation oncologists (ROs) to develop a skin radiotherapy practice.

Our study is limited by the small dataset for oncological and cosmetic outcomes ( $n = 40$ ). This precluded statistical analysis. Furthermore, we assumed that if a patient did not present to their referring physician following RT, they did not suffer local recurrence or late side effects. However, this assumption could easily be confounded if a patient developed these adverse outcomes but did not present to their physician, or presented to an alternative physician who did not report their findings to the radiation oncologist. As this study was retrospective, it was also limited by data missing



from medical records. Prospective, randomised studies comparing treatment of nasal BCCs and cSCCs by definitive RT with other modalities are required to guide management. This data may inform future prospective trials comparing RT with other treatment modalities for this patient population in the Australian context.

## CONCLUSION

This retrospective, single-clinician study of 93 patients with 103 nasal BCCs and cSCCs treated with definitive RT, with outcome data on 40 patients, supports the use of this modality in preventing local recurrence with minimal late side effects. This study provides a foundation for future prospective trials comparing RT with other modalities in this patient population.

## REFERENCES

1. Australian Institute of Health and Welfare. Skin cancer in Australia. Canberra: AIHW; 2016. URL: <https://www.aihw.gov.au/reports/cancer/skin-cancer-in-australia/contents/table-of-contents>
2. Lomas A, Leonardi-Bee J, Bath-Hextall F. A systematic review of worldwide incidence of nonmelanoma skin cancer. *The British journal of dermatology*. 2012; **166**(5): 1069-80. [DOI: 10.1111/j.1365-2133.2012.10830.x]; [PMID: 22251204]
3. Australian Institute of Health and Welfare. Health system expenditure on cancer and other neoplasms in Australia: 2008–09. Canberra; 2013. URL: <https://www.aihw.gov.au/reports/health-welfare-expenditure/health-system-expenditure-cancer-2008-09/contents/table-of-contents>
4. Ahmed AH, Soyer HP, Saunders N, Boukamp P, Roberts MS. Non-melanoma skin cancers. *Drug Discovery Today: Disease Mechanisms*. 2008; **5**(1): e55-e62. [DOI: 10.1016/j.ddmec.2008.05.007]
5. Ashby MA, McEwan L. Treatment of non-melanoma skin cancer: a review of recent trends with special reference to the Australian scene. *Clinical Oncology (Royal College of Radiologists)*. 1990; **2**(5): 284-94. [PMID: 2261429]
6. Avril MF, Auperin A, Margulis A, Gerbaulet A, Duvillard P, Benhamou E, Guillaume JC, Chalon R, Petit JY, Sancho-Garnier H, Prade M, Bouzy J, Chassagne D. Basal cell carcinoma of the face: surgery or radiotherapy? Results of a randomized study. *British journal of cancer*; 1997; **76**(1): 100-6. [PMID: 9218740]
7. Bath-Hextall FJ, Perkins W, Bong J, Williams HC. Interventions for basal cell carcinoma of the skin. *The Cochrane database of systematic reviews*. 2007(1): Cd003412. [DOI: 10.1002/14651858.CD003412.pub2]; [PMID: 17253489]
8. Clark CM, Furniss M, Mackay-Wiggan JM. Basal Cell Carcinoma: An Evidence-Based Treatment Update. *American Journal of Clinical Dermatology*. 2014; **15**(3): 197-216. [DOI: 10.1007/s40257-014-0070-z.]; [PMID: 24733429]
9. Madan V, Lear JT, Szeimies R-M. Non-melanoma skin cancer. *The Lancet*. 2010; **375**(9715): 673-85. [DOI: 10.1016/S0140-6736(09)61196-X]; [PMID: 20171403]
10. Mazon JJ, Chassagne D, Crook J, Bachelot F, Brochet F, Brune D, Brunin F, Bunescu U, Daly N, Danczak S, Dubois JB, Grangean M, Hoffstetter S, Koechlin M, Huart J, Labib A, Madelain M, Maylin C, Reynaud-Bougnot A, Rozan R, Serpantie P. Radiation therapy of carcinomas of the skin of nose and nasal vestibule: a report of 1676 cases by the Groupe Europeen de Curietherapie. *Radiotherapy and oncology: journal of the European Society for Therapeutic Radiology and Oncology*. 1988; **13**(3): 165-73. [PMID: 3146781]
11. Clarke P. Nonmelanoma skin cancers Treatment options. *Australian Family Physician*. 2012; **41**: 476-80. [PMID: 22762065]
12. Lansbury L, Bath-Hextall F, Perkins W, Stanton W, Leonardi-Bee J. Interventions for non-metastatic squamous cell carcinoma of the skin: systematic review and pooled analysis of observational studies. *BMJ: British Medical Journal*. 2013; **347**. [DOI: 10.1136/bmj.f6153]; [PMID: 24191270]
13. Cancer Council Australia and Australian Cancer Network. Basal cell carcinoma, squamous cell carcinoma (and related lesions) - a guide to clinical management in Australia. Sydney 2008. URL: [https://www.cancer.org.au/content/pdf/HealthProfessionals/ClinicalGuidelines/Basal\\_cell\\_carcinoma\\_Squamous\\_cell\\_carcinoma\\_Guide\\_Nov\\_2008-Final\\_with\\_Corrigendums.pdf](https://www.cancer.org.au/content/pdf/HealthProfessionals/ClinicalGuidelines/Basal_cell_carcinoma_Squamous_cell_carcinoma_Guide_Nov_2008-Final_with_Corrigendums.pdf)
14. Guo S, DiPietro LA. Factors Affecting Wound Healing. *Journal of Dental Research*. 2010; **89**(3): 219-29. [DOI: 10.1177/0022034509359125]; [PMID: 20139336]
15. Petit JY, Avril MF, Margulis A, Chassagne D, Gerbaulet A, Duvillard P, Auperin A, Rietjens M. Evaluation of cosmetic results of a randomized trial comparing surgery and radiotherapy in the treatment of basal cell carcinoma of the face. *Plastic and reconstructive surgery*. 2000; **105**(7): 2544-51. [PMID: 10845311]