

TOPIC HIGHLIGHT

Phakomatosis Pigmentovascularis Cesioflammea

Valeria Silecchia¹, Enrico Valerio², Marco Filippone², Laura Balao², Emanuele Cherubin², Luca Rigon², Ramon Grimalt³, Mario Cutrone⁴

1 Neonatal Intensive Care Unit, Department of Woman and Child Health, University of Padua, Padova, Italy;

2 Neonatal Intensive Care Unit, Ospedale “Pietro Cosma”, Camposampiero (Padova), Italy;

3 Universitat Internacional de Catalunya. Dermatology, Sant Cugat del Vallès. Barcelona, Spain;

4 Pediatric Dermatology Unit, Ospedale “Dell’Angelo”, Mestre (Venice), Italy.

Conflict-of-interest statement: The author(s) declare(s) that there is no conflict of interest regarding the publication of this paper.

Open-Access: This article is an open-access article which was selected by an in-house editor and fully peer-reviewed by external reviewers. It is distributed in accordance with the Creative Commons Attribution Non Commercial (CC BY-NC 4.0) license, which permits others to distribute, remix, adapt, build upon this work non-commercially, and license their derivative works on different terms, provided the original work is properly cited and the use is non-commercial. See: <http://creativecommons.org/licenses/by-nc/4.0/>

Correspondence to: Enrico Valerio, Pediatric Intensive Care Unit, Ospedale San Bortolo, Vicenza, Italy.

Email: enrico.valerio.md@gmail.com

Telephone: +39 0444 75 2887

Fax: +39 0444 75 2796

Received: July 30, 2019

Revised: August 6, 2019

Accepted: September 1, 2019

Published online: December 19, 2019

ABSTRACT

nCPAP-induced nose skin injury is a common issue in NICUs all over the world. Damage may vary from simple hyperemia in the region of application of nasal cannulae up to complete destruction of the columellar region. We here report a case series of three patients displaying various grades of nasal damage, ranging from soft hyperemia to ulcerative lesions, up to complete columellar breakdown. Not only lesions with loss of substance are documented in literature; cases of post-discharge nasal vestibular

stenosis and nasal synechiae obstruction are also reported. Risk factors for nCPAP-induced nasal injury include low birth weight, low gestational age, and increased time on nCPAP. Good clinical practices to prevent and treat nCPAP-induced skin damage are here briefly reviewed; strong efforts must be spent in NICU personnel education in order to enhance awareness about this topic and ensure a correct prevention.

Key words: Phakomatosis cesioflammea; Dermatology; Neonatology; Down syndrome; Trisomy 21

© 2019 The Author(s). Published by ACT Publishing Group Ltd. All rights reserved.

Silecchia V, Valerio E, Filippone M, Balao L, Cherubin E, Rigon L, Grimalt R, Cutrone M. Phakomatosis Pigmentovascularis Cesioflammea. *Journal of Dermatological Research* 2019; 4(2): 187-188 Available from: URL: <http://www.ghrnet.org/index.php/jdr/article/view/2735>

Abbreviations

PPV: Phakomatosis pigmentovascularis

CASE PRESENTATION

A term male newborn with prenatal diagnosis of Down syndrome presented at birth with a widespread vascular capillary malformation involving left hemithorax, arm, buttock, and leg (Figure 1A); an extensive, partly superimposed Mongolian spot was also clearly visible on the left hemibody and right part of the back and buttocks (Figure 1B). Clinical picture was compatible with that of phakomatosis pigmentovascularis cesioflammea. Fundus oculi, cerebral and abdomen ultrasound turned out normal. A cardiac ultrasound revealed atrial septal defect. Cutaneous lesions remained unmodified at 10-month control visit.

KEY LEARNING POINTS

Phakomatosis pigmentovascularis (PPV) represents an heterogeneous family of syndromes in which a pigmentary nevus and a cutaneous capillary malformation coexist. Original classification of 1985^[1] divided PPV into four forms (later in 2003, a fifth form called cutis

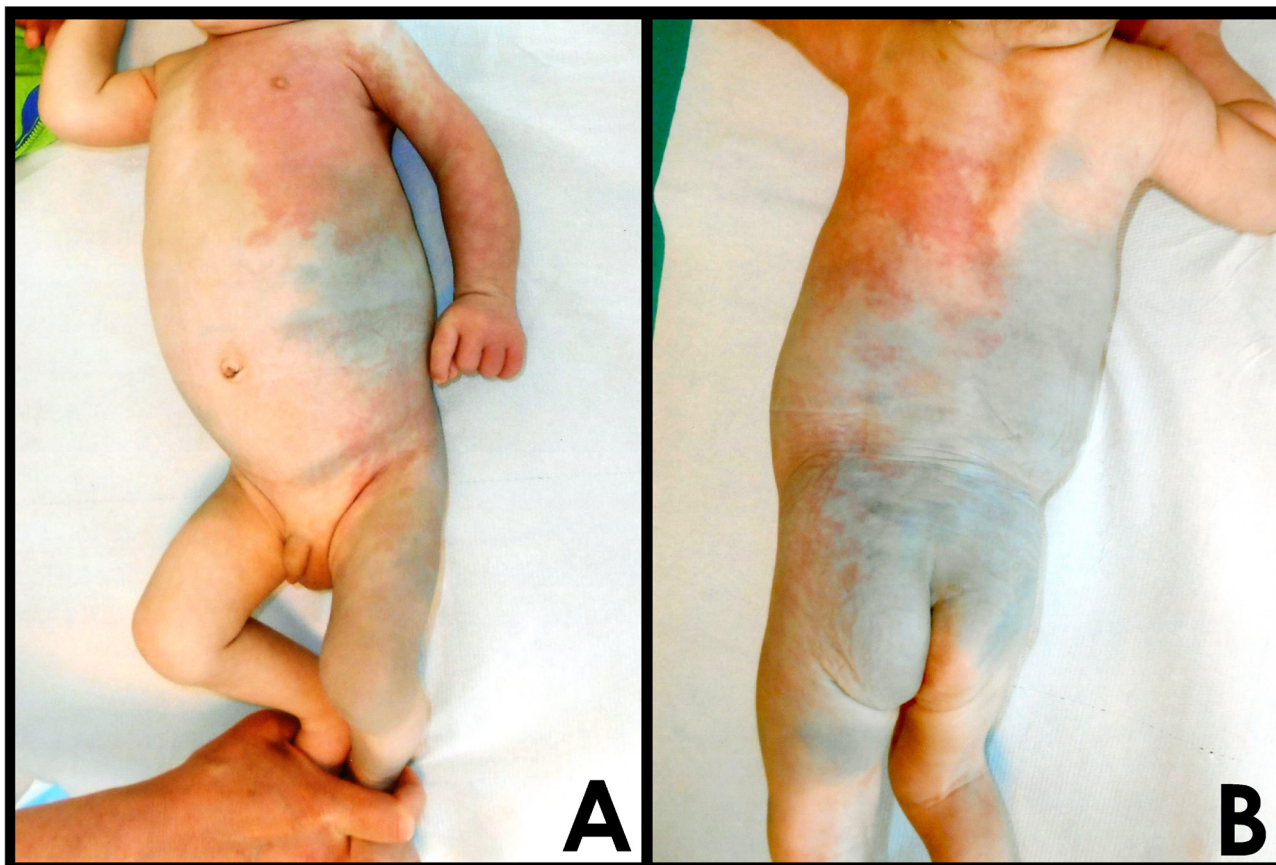


Figure 1 A: Ventral extension of nevus flammeus and Mongolian spot on our patient. B: Dorsal extension of nevus flammeus and Mongolian spot on our patient.

marmorata telangiectastica congenita was added)^[2] according to the associated pigmented lesion; each form was further subdivided in “a” and “b” based on the presence or absence of extracutaneous signs. More recently, Happle^[3] reorganized PPV classification into three forms: phakomatosis cesioflammea (blue spots -”caesius” in Latin- and nevus flammeus); phakomatosis spilorosea (nevus spilus coexisting with a palepink telangiectatic nevus), and phakomatosis cesiomarmorata (blue spots and cutis marmorata telangiectatica congenita).

Phakomatosis cesioflammea represents the most common presentation^[4]. Possibly associated extracutaneous manifestation of this condition include central nervous system defects, melanosis bulbi, glaucoma, asymmetrical length of limbs, Klippel-Trenaunay syndrome, nevus anemicus, and Sturge-Weber syndrome^[5]. This case is of interest since it first describes association of phakomatosis cesioflammea with Down syndrome.

REFERENCES

1. Hasegawa Y, Yasuhara M. Phakomatosis pigmentovascularis type IVa. *Arch Dermatol.* 1985; **121**: 651-5. [PMID: 3994413]
2. Torrelo A, Zambrano A, Happle R. Cutis marmorata telangiectastica congenita and extensive Mongolian spots: type V phakomatosis pigmentovascularis. *Br J Dermatol* 2003; **148**: 342-5. [PMID: 12588390]; [DOI: 10.1046/j.1365-2133.2003.05118.x]
3. Happle R. Phakomatosis pigmentovascularis revisited and reclassified. *Arch Dermatol.* 2005; **141**: 385-8. [PMID: 15781681]; [DOI: 10.1001/archderm.141.3.385]
4. Vidaurri-de la Cruz H, Tamayo-Sánchez L, Durán-McKinster C, Orozco-Covarrubias Mde L, Ruiz-Maldonado R. Phakomatosis pigmentovascularis II A and II B: clinical findings in 24 patients. *J Dermatol.* 2003; **30**: 381-8. [PMID: 12773803]; [DOI: 10.1111/j.1346-8138.2003.tb00403.x]
5. Goyal T, Varshney A. Phakomatosis cesioflammea: first case report from India. *Indian J Dermatol Venereol Leprol.* 2010; **76**: 307. [PMID: 20445318]; [DOI: 10.4103/0378-6323.62973]