

Angiofibroma of Soft Tissue Occurring in Subcutaneous Adipose Tissue and Appearing as Subcutaneous Nodules

Masanori Ban¹, Mariko Seishima²

1 Division of Dermatology, Ban Skin Clinic, Hashima, Japan;
2 Department of Dermatology, Gifu University, Gifu, Japan.

Conflict-of-interest statement: The author(s) declare(s) that there is no conflict of interest regarding the publication of this paper.

Open-Access: This article is an open-access article which was selected by an in-house editor and fully peer-reviewed by external reviewers. It is distributed in accordance with the Creative Commons Attribution Non Commercial (CC BY-NC 4.0) license, which permits others to distribute, remix, adapt, build upon this work non-commercially, and license their derivative works on different terms, provided the original work is properly cited and the use is non-commercial. See: <http://creativecommons.org/licenses/by-nc/4.0/>

Correspondence to: Masanori Ban, Ban Hifuka, Masakicho Magari 1050-1, Hashima City, 501-6227, Japan.

Email: banhifuka@major.ocn.ne.jp

Telephone: +81-58-391-0056

Fax: +81-58-391-0099

Received: December 6, 2020

Revised: December 28, 2020

Accepted: December 30, 2020

Published online: January 29, 2021

ABSTRACT

Angiofibroma of soft tissue is a new entity recently proposed. It appears often in the deep tissue in relation to joints or fibrotendinous structures. Dermatologists may encounter the cases in the slightly shallow tissue. We report three cases occurring in subcutaneous adipose tissue, and clinically appearing as subcutaneous nodules. A 71-year-old male, an eight-year-old male and a 36-year-old female had a 15-mm-diameter nodule on the left buttock, a 10×5 mm one on the lower right heel and a 15×12 mm one on the lateral right dorsum, respectively. The lesions revealed histologically a proliferation of spindle cells in the collagenous or myxoid-to-collagenous stroma, and abundant branching slit-like vascular structures.

Key words: Angiofibroma of soft tissue; Collagenous stroma; Branching slit-like vascular structures

© 2021 The Author(s). Published by ACT Publishing Group Ltd. All rights reserved.

Ban M, Seishima M. Angiofibroma of Soft Tissue Occurring in Subcutaneous Adipose Tissue and Appearing as Subcutaneous Nodules. *Journal of Dermatological Research* 2021; **6(1)**: 210-213 Available from: URL: <http://www.ghrnet.org/index.php/jdr/article/view/3073>

INTRODUCTION

Angiofibroma of soft tissue (AFST) is a recently proposed new entity^[1]. It often appears in the deep tissue in relation to joints or fibrotendinous structures. Dermatologists may encounter the cases in the slightly shallow tissue. We herein report three cases of AFST occurring in subcutaneous adipose tissue, and clinically appearing as subcutaneous nodules.

CASE SERIES

Case 1

A 71-year-old male presented with a half-year history of an induration on his left buttock. Clinical examination revealed a 15-mm-diameter nodule (Figure 1A). It seemed to be filled with fluid. Skin surface was normal. After skin incision and removing blood clots, we found out a nodule embedded in the adipose tissue, and we resected it. Histological examination of the nodule revealed the collagenous stroma accompanied with bland spindle-shaped cells, where a large number of small, thin-walled branching capillaries were seen. Some capillaries showed slit-like spaces. A small number of thick-walled vessels were also found in the marginal region. The lesion did not show mitotic, hyperchromatic or pleomorphic nuclei (Figure 1B). Immunohistochemically, the endothelial cells of the capillaries reacted to CD34 (Figure 1C), and did the pericytes to smooth muscle actin (Figure 1D). The spindle cells were negative for both CD34 and smooth muscle actin. The diagnosis of AFST occurring in the subcutaneous tissue was made.

Case 2

An eight-year-old male had been aware of a slowly growing subcutaneous nodule on the bottom of his right heel for three years. He had no tenderness nor hyperhidrosis. Clinical examination revealed a nodule 10 × 5 mm in size without overlying skin changes. Skin inci-

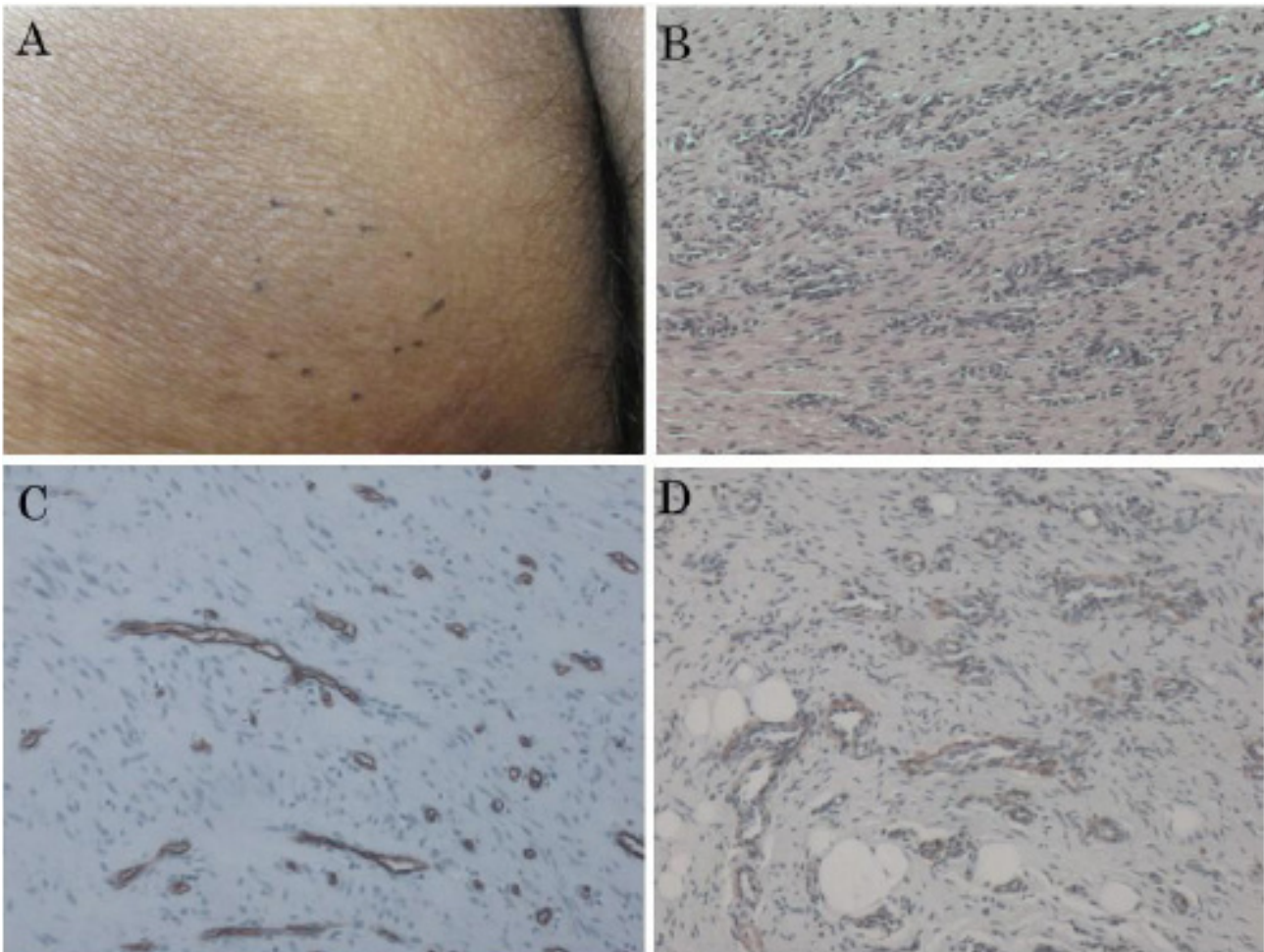


Figure 1 Case 1. (A) A subcutaneous nodule on the left buttock. (B) A large number of small, thin-walled branched capillaries with slit-like spaces scattered in the sclerotic stroma (HE stain, x100). (C) The CD34-positive endothelial cells of the capillaries (x400). (D) The pericytes reacting to smooth muscle actin (x400).

sion and resecting the subcutaneous nodule were performed. Histopathological examination revealed no abnormal vascular components in the dermis. Some eccrine glands, adipose tissue and thick-walled vessels were shown in the deep region (Figure 2A). Below them, collagenous bundles associated with uniform spindle cells proliferated, in which small, branching and thin-walled blood vessels with slit-like spaces were seen. Mitoses, hyalinization, plasma cells, microspheres or spindle cell bundles were not found (Figure 2 B). The endothelial cells of the capillaries reacted to CD34 (Figure 2C), and did the pericytes to smooth muscle actin. Both antibodies did not highlight spindle cells in collagen bundles. The diagnosis of AFST occurring in the subcutaneous tissue was made. It was not considered that AFST extended into the dermis, because no abnormal vasculature was seen there.

Case 3

A 36-year-old female noticed a small subcutaneous nodule on the lateral side of her right dorsum pedis several months ago. It had grown gradually. Clinical examination showed a nodule 15 × 12 mm in size, which had a normal skin color surface and tenderness (Figure 3A). MRI revealed no its connection with the bone. A complete excision was performed. Histological examination showed a proliferation of uniform spindle cells in a myxoid-to-collagenous stroma in the subcutaneous tissue. They were accompanied by branching and slit-like vascular structures (Figure 3B). No cellular dysplasia was found. The endothelial cells of the capillaries reacted to CD34 (Figure 3C). Most

of the pericytes did to smooth muscle actin (Figure 3D), except of some in the myxomatous stroma. Spindle cells showed no reaction to both anti-bodies. The diagnosis of AFST in the subcutaneous tissue was made.

DISCUSSION

As the two main categories of fibroblastic soft tissue tumors with abundant vascularization, nasopharyngeal angiofibroma^[2] and cellular angiofibroma^[3] had been described. The former occurs in the nasal cavity and is histologically characterized by prominent vascularization with remarkable variation in vessel wall thickness, both within and between vessels, ranging from a well-developed muscular coat to a single layer of thin endothelium^[2]. The latter occurs in the vulva, pelvipерineal or paratesticular region and consists of a relatively cellular proliferation of uniform spindle cells set in a collagenous stroma, with abundant small-to-medium sized thick-walled vessels^[3].

In 2012, Mariño-Enríquez and Fletcher^[1] proposed a new entity AFST, which is a slowly growing painless mass located in the soft tissue, often in relation to joints or fibrotendinous structures, and histologically characterized by two components: bland, uniform, likely fibroblastic spindle cells set in a varied collagenous or myxoid stroma, and a prominent and highly characteristic vascular pattern composed of innumerable branching, thin-walled blood vessels. Out of 37 cases they reported, 23 cases arose in the soft tissues of the lower limbs and 6 case in ones of upper limbs. Thirteen cases were adjacent

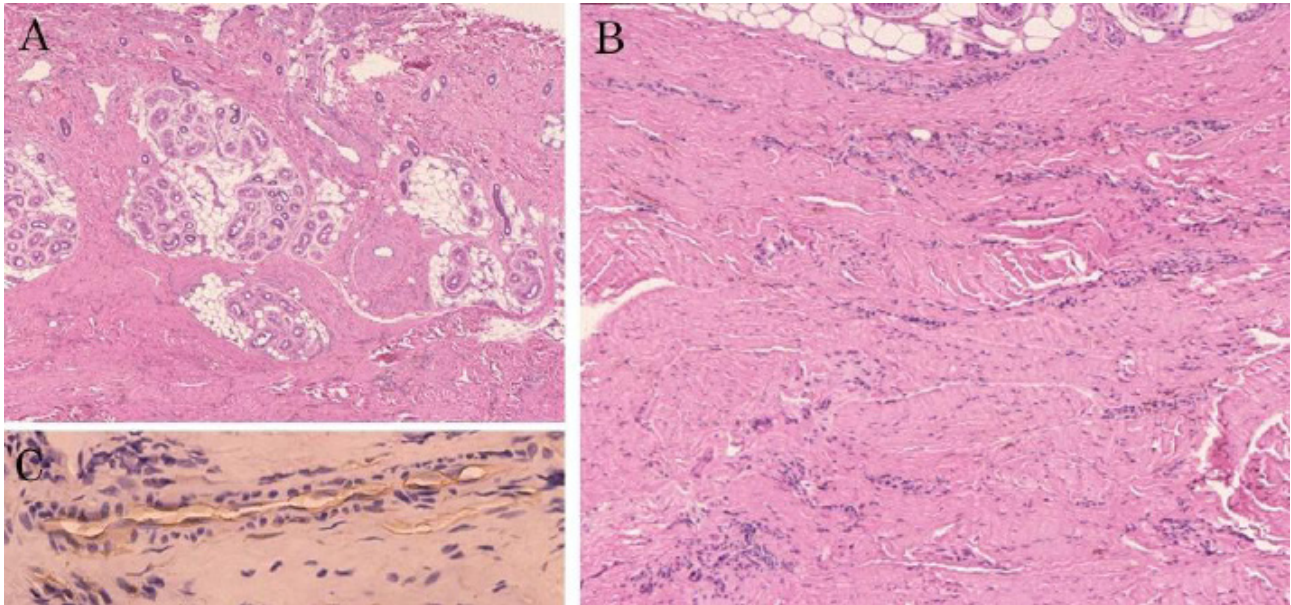


Figure 2 Case 2. (A) No abnormal vascular components in the superficial dermis. Some eccrine glands, adipose tissue and thick-walled vessels in the middle dermis. Sclerotic collagen bundles in the deep dermis (HE stain, x40). (B) Sclerotic collagen bundles and small blood vessels with slit-like spaces under the dermis (HE stain, x100). (C) The CD34-positive endothelial cells of the capillaries (x400).

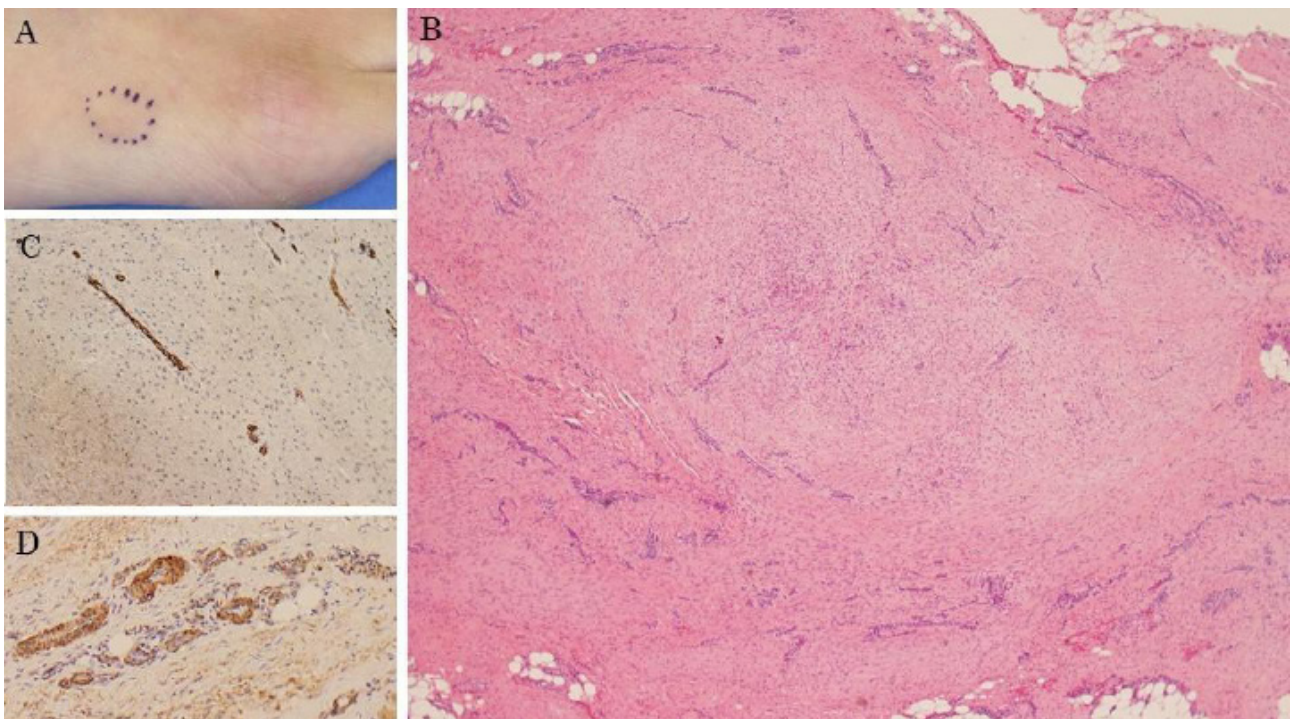


Figure 3 Case 3. (A) A subcutaneous nodule on the right dorsal pedis. (B) Thin-walled branched capillaries with slit-like spaces scattered in the myxoid or sclerotic stroma (HE stain, x40). (C) The positive-CD34 endothelial cells of the capillaries (x200). (D) The pericytes reacting to smooth muscle actin (x400).

to or arising from joint-related structures. Eighteen cases occurred in subfascial or deeper regions, and 15 cases were in subcutaneous fat. Three cases extended into the dermis. To our knowledge 13 English papers^[4-16] on AFST have been published since the report by Mariño-Enríquez and Fletcher. Several pathologists studied cytogenetically, and demonstrated the existence of AHRR-NCOA2 fusion gene in the lesions. There are no reports by dermatologists in the above 13 papers.

The presented 3 cases were AFST occurring in subcutaneous fat, which was clinically observed as subcutaneous nodules. Case 1 had abundant vascular components showing a mature and typical lesion.

We considered that cases 2 and 3 were more immature than case 1 because of their smaller size and smaller number of vascularization. The pericytes without reaction to smooth muscle actin in case 3 might be immature.

Cellular angiofibroma, solitary fibrous tumor, low grade fibromyxoid sarcoma, low-grade myxofibrosarcoma and myxoid liposarcoma are considered as the important differential diagnoses of AFST^[1,16]. Cellular angiofibroma shows more rounded, non-branching vessels. The spindle cell component in most cases is quite cellular and resembles ones of spindle cell lipoma^[1,16]. The typical benign solitary fibrous tumor displays zones of both hypercellular and hypocellular

collagenized stroma in a so called patternless architecture and has a branching hemangiopericytoma-like (staghorn) vasculature^[17]. Low-grade fibromyxoid sarcoma demonstrates contrasting fibrous and myxoid areas, a swirling, whorled growth pattern, and bland, low to moderately cellular spindle cells^[16]. Myxofibrosarcoma reveals a multinodular tumor of low cellularity. The cells have slightly eosinophilic cytoplasm and indistinct cell borders. The nuclei are hyperchromatic, and are mildly pleomorphic, and only have rare mitotic figures. Most tumors have elongated, curvilinear capillaries^[18]. Myxoid liposarcoma is characterized by a monomorphic proliferation of round or slightly fusiform cells and small lipoblasts set in a myxoid matrix, often forming large spaces containing stromal mucin. It shows plexiform, arborizing networks of thin-walled capillaries with univacuolated or multivacuolated lipoblasts^[1,16].

Cutaneous angiofibromas also can be the differential diagnoses. This designation includes several diseases: fibrous papules, pearly penile papules, periungual angiofibromas (Koener tumors) and oral fibromas. In addition, multiple facial angiofibromas are found in tuberous sclerosis, multiple endocrine neoplasia type 1 and Birt-Hogg-Dube syndrome^[19]. Histologically, all of them are composed of a dermal proliferation of fibroblasts in collagenous stroma with an increase in the number of thin-walled, dilated blood vessels. They exist mainly in the dermis not in the soft tissue, which makes it easy to distinguish from AFST. We think their proliferations of spindle cells and vascular components are less pronounced than ones of AFST. Rather, AFST is histologically similar to microvenular hemangioma^[20], which consists of the thin-walled, small branching vessels with inconspicuous vascular lumina and a variable degree of sclerosis. However, these components extend in the superficial and deep dermis not in soft tissue. Further, microvenular hemangioma clinically arises as a purple to red lesion.

In conclusion, AFST is rare for dermatologists, but it should be known as one of the diseases appearing as subcutaneous nodules.

ACKNOWLEDGMENTS

I wish to thank Dr. Yasuo Kitajima (Kizawa memorial hospital) for his help.

REFERENCES

- Mariño-Enríquez A, Fletcher CDM. Angiofibroma of soft tissue: Clinicopathologic characterization of a distinctive benign fibrovascular neoplasm in a series of 37 cases. *Am J Surg Pathol.* 2012; **36**: 500-508. [PMID: 22301504]; [DOI: 10.1097/PAS.0b013e31823defbe]
- Tork CA, Simpson DL. Nasopharyngeal Angiofibroma. StatPearls [Internet]. Treasure Island (FL): StatPearls Publishing; 2020. Available from: <https://www.ncbi.nlm.nih.gov/books/NBK545240/>. [PMID: 31424824]
- Nucci MR, Granter SR, Fletcher CDM. Cellular angiofibroma: a benign neoplasm distinct from angiomyofibroblastoma and spindle cell lipoma. *Am J Surg Pathol.* 1997; **21**: 636-644. [PMID: 9199640]; [DOI: 10.1097/00000478-199706000-00002]
- Schoolmeester JK, Sukov WR, Aubry MC, Folpe AL. Angiofibroma of soft tissue: core needle biopsy diagnosis, with cytogenetic confirmation. *Am J Surg Pathol.* 2012; **36**: 1421-1423. [PMID: 22895276]; [DOI: 10.1097/PAS.0b013e3182627ccb]
- Edgar MA, Lauer SR, Bridge JA, Rizzo M. Soft tissue angiofibroma: report of 2 cases of a recently described tumor. *Hum Pathol.* 2013; **44**: 438-441. [PMID: 23261176]; [DOI: 10.1016/j.humpath.2012.08.021]
- Zhao M, Sun K, Li C, Zheng J, Yu Jin J, et al. Angiofibroma of soft tissue: clinicopathologic study of 2 cases of a recently characterized benign soft tissue tumor. *Int J Clin Exp Pathol* 2013; **6**: 2208-2215. [PMID: 24133600]
- Arbajian E, Magnusson L, Mertens F, Domanski HA, Vult von Styeyrn F, Nord KH. A novel GTF2I/NCOA2 fusion gene emphasizes the role of NCOA2 in soft tissue angiofibroma development. *Genes Chromosomes Cancer.* 2013; **52**: 330-331. [PMID: 23225380]; [DOI: 10.1002/gcc.22033]
- Sugita S, Aoyama T, Kondo K, Keira Y, Ogino J, Nakanishi K, et al. Diagnostic utility of NCOA2 fluorescence in situ hybridization and Stat6 immunohistochemistry staining for soft tissue angiofibroma and morphologically similar fibrovascular tumors. *Hum Pathol.* 2014; **45**: 1588-1596. [PMID: 24856853]; [DOI: 10.1016/j.humpath.2013.12.022]
- Fukuda Y, Motoi T, Kato I, Ikegami M, Funata N, Ohtomo R, et al. Angiofibroma of soft tissue with fibrohistiocytic features and intratumor genetic heterogeneity of NCOA2 gene rearrangement revealed by chromogenic in situ hybridization: a case report. *Pathol Int.* 2014; **64**: 237-242. [PMID: 24888778]; [DOI: 10.1111/pin.12163]
- Yamada Y, Yamamoto H, Kohashi K, Ishii T, Iura K, Maekawa A, et al. Histological spectrum of angiofibroma of soft tissue: histological and genetic analysis of 13 cases. *Histopathology.* 2016; **69**: 459-469. [PMID: 26845637]; [DOI: 10.1111/his.12943]
- Panagopoulos I, Gorunova L, Viset T, Heim S. Gene fusions *AHRR-NCOA2*, *NCOA2-ETV4*, *ETV4-AHRR*, *P4HA2-TBCK*, and *TBCK-P4HA2* resulting from the translocations t(5;8)(17)(p15;q13;q21) and t(4;5)(q24;q31) in a soft tissue angiofibroma. *Oncol Rep* 2016; **36**: 2455-2462. [PMID: 27633981]; [DOI: 10.3892/or.2016.5096]
- Hashino Y, Nishio J, Maeyama A, Aoki M, Nabeshima K, Yamamoto T. Intra-articular angiofibroma of soft tissue of the knee: a case report. *Mol Clin Oncol.* 2017; **7**: 229-232. [PMID: 28781791]; [DOI: 10.3892/mco.2017.1298]
- Bekers EM, Groenen PJTA, Verdijk MAJ, Raaijmakers-van Gelooft WL, Roepman P, Vink R, et al. Soft tissue angiofibroma: Clinicopathologic, immunohistochemical and molecular analysis of 14 cases. *Genes Chromosomes Cancer.* 2017; **56**: 750-757. [PMID: 28639284]; [DOI: 10.1002/gcc.22478]
- Ma HJ, Huang HN, Li L, Chen S, Zhang RY. Clinicopathological characteristics of angiofibroma of soft tissue: report of three cases. *Int J Clin Exp Pathol* 2018; **11**: 3777-3784. [PMID: 31949763]; [PMCID: PMC6962839]
- Ali Z, Anwar F. Angiofibroma of Soft Tissue: A Newly Described Entity; A Case Report and Review of Literature. *Cureus.* 2019; **11**: e6225. [PMID: 31890425]; [DOI: 10.7759/cureus.6225]
- Mindiola-Romero AE, Maloney N, Bridge JA, Korkolopoulou P, Sakellariou S, Linos K. A concise review of angiofibroma of soft tissue: A rare newly described entity that can be encountered by dermatopathologists. *J Cutan Pathol.* 2020; **47**: 179-185. [PMID: 31568567]; [DOI: 10.1111/cup.13580]
- Guillou L, Fletcher JA, Fletcher CD, Mandahl N. Extraleural solitary fibrous tumor and hemangiopericytoma. In: Fletcher CD, Unni KK, Mertens F (ed). *Pathology and genetics of tumours of soft tissues and bone.* Lyon: IARC Press, 2002: 86-88
- Goldblum JR, Folpe AL, Weiss SW. Borderline and malignant fibroblastic/myoblastic tumors. In: Goldblum JR, Folpe AL, Weiss SW (ed). *Enzinger & Weiss's Soft tissue tumors, 7th edn.* Philadelphia: Elsevier Inc, 2020: 306-374
- Macri A, Kwan E, Tanner LS. Cutaneous Angiofibroma StatPearls [Internet]. Treasure Island (FL): StatPearls Publishing; 2020. Available from: <https://www.ncbi.nlm.nih.gov/books/NBK482470/>. [PMID: 29494077]
- Hunt SJ, Santa Cruz DJ, Barr RJ. Microvenular hemangioma. *J Cutan Pathol* 1991; **18**: 235-240. [PMID: 1939781]; [DOI: 10.1111/j.1600-0560.1991.tb01229.x]