

Haemolytic Uremic Syndrome in Children (1955-2015): A 60 Years Journey

Ashraf Bakr, Riham Eid

Ashraf Bakr, Riham Eid, Paediatric Nephrology and Dialysis Unit, Mansoura University Children's Hospital, Egypt

Correspondence to: Riham Eid, Paediatric Nephrology and Dialysis Unit, Mansoura University Children's Hospital, Egypt

Email: rihameid@mans.edu.eg

Telephone: +201004816421

Fax: +20502230376

Received: May 14, 2015

Revised: August 2, 2015

Accepted: August 7, 2015

Published online: October 26, 2015

ABSTRACT

Haemolytic uremic syndrome (HUS) is the most common cause of acute kidney injury in children. HUS was first described in 1955. Since then major advances had been achieved in understanding pathogenesis and improving patient management and outcomes. Despite these achievements, atypical HUS diagnosis and management in developing countries is still mostly impossible because of the very high cost and non-availability of different tests required for diagnosis, lack of consensus on maintenance plasmapheresis therapy or long-term Eculizumab treatment for a-HUS and the high risk of recurrence after renal transplantation are all challenges.

© 2015 ACT. All rights reserved.

Key words: Haemolytic uremic syndrome; Children; Plasma exchange; Eculizumab

Bakr A, Eid R. Haemolytic Uremic Syndrome in Children (1955-2015): A 60 Years Journey. *Journal of Nephrology Research* 2015; 1(2): 69-79 Available from: URL: <http://www.ghrnet.org/index.php/jnr/article/view/1202>

INTRODUCTION

Haemolytic uremic syndrome (HUS) is the most common cause of acute kidney injury (AKI) in children^[1-4]. HUS is defined by the triad

of non-immune haemolytic anaemia (hemoglobin < 10 g/dL) with schistocytes, thrombocytopenia (platelets < 150×10³/mm³) and renal impairment (serum creatinine > upper limit of normal for age)^[5].

Before 1955, cases with acute renal failure following gastroenteritis were explained as either: prerenal failure (severe dehydration), acute tubular necrosis (ATN), sepsis, renal vein thrombosis or disseminated intravascular coagulopathy. Such cases were treated by antibiotics and haemodynamic support only.

Haemolytic uremic syndrome was first described in 1955^[6]. Since then major advances have been achieved in understanding aetiology, pathogenesis, diagnosis and optimum management of such cases. Major mile stones in these 60 years are: linking diarrhoea associated HUS (D+HUS) to Shiga like toxins producing organisms, differentiating HUS into D+HUS and diarrhoea -ve (D-HUS) (this classification was modified later), genetic diagnosis of atypical HUS (a-HUS), plasmapheresis, Eculizumab (considered as the most exciting development in HUS history) use in a-HUS management and finally renal transplantation of HUS patients with end stage renal disease(ESRD).

Despite these advances a lot is still required; a-HUS diagnosis and management in developing countries is still mostly impossible, very high cost of Eculizumab is limiting its widespread use and still no consensus on maintenance plasmapheresis therapy or long-term Eculizumab treatment.

HISTORY OF HAEMOLYTIC UREMIC SYNDROME

Diarrhoea associated (D+HUS)/Typical HUS

In 1955, Gasser et al first described five children with haemolytic anaemia, thrombocytopenia, and renal failure. This combination of clinical presentations was referred to as HUS^[6]. This was followed by reports of similar cases including individual cases, large series and epidemics from different parts of the world^[7-13].

Outbreaks of HUS forced researchers to think into a possible infectious cause. In 1966 the first identified outbreak of HUS was

reported in Wales. A number of possible environmental factors were examined including food, water, and other toxins but no definite cause was detected, however a response to an infection was suspected to be underlying mechanism^[12].

In 1985 Karmali *et al*^[14] showed that patients with HUS preceded by diarrhoea contained *E. coli* strains in their stools which produced a toxin that caused irreversible damage to cultured vero cells (kidney cells from the African green monkey). Another working group demonstrated that the verocytotoxin produced by strains of Enterohemorrhagic *E. coli* (EHEC) associated with HUS is related to Stx of *Shigella dysenteriae* type 1^[15]. Following these descriptions, it is now known that *E. coli*-producing Stx and other factors, are the main causes of paediatric D+HUS^[16].

Hereditary/familial/Diarrhoea –ve/atypical HUS

Hagge *et al*^[17] (1967) reported HUS in 2 siblings, one of them had repeated attacks, developed ESRD and died at age 8 years while the other recovered completely after one attack. This was followed by many reports of HUS in families and cases from non-endemic areas^[18-21] which forced researchers to think that there is different group of HUS patients (other than D+HUS) with possible genetic background.

Complement factor H (CFH) mutations were the first identified genetic association with a-HUS in 1973^[22], while an acquired dysfunction of CFH due to anti-CFH antibodies was described in 2005 for the first time^[23]. Membrane co-factor protein (MCP) mutation in a-HUS was first reported in 2003^[24]. More than 40 different mutations in MCP have been identified so far in patients

with a-HUS^[25-27]. Up to 12% of a-HUS patients have different combinations of 2 or more mutations of CFH, CFI, MCP, C3, (Complement factor B) CFB or (Thrombomodulin) THBD^[28-31]. Despite all these discoveries still 30% of a-HUS cases are unexplained^[5] suggesting that pathogenic pathways and genetic susceptibility loci are still unexplored. Clinical presentation of the different subgroups of HUS and thrombotic thrombocytopenic purpura (TTP) and investigations to confirm diagnosis are summarized in (Table 1)^[5].

CLASSIFICATION

Haemolytic uremic syndrome has been divided into D+HUS and D-HUS, with D+HUS resulting from verocytotoxin-producing *E. coli* and *Shigella dysenteriae* type 1, while a-HUS resulting from all other causes. Because diarrhoea is not a reliable characteristic feature, currently HUS is divided into 'typical' for that due to infective causes and a-HUS for all other causes (Table 2). Typical HUS is more common, with verocytotoxin-producing organisms being the commonest aetiology, however the incidence of Pneumococcal infection as a cause of HUS is higher in some countries^[32].

PATHOGENESIS OF HUS

Diarrheal prodrome is not always bloody

Haemolytic uremic syndrome typically follows an enteric infection with a Shiga toxin-producing *E. coli*, usually serotype O157:H7

Table 1 Clinical presentation of the different subgroups of haemolytic uremic syndrome and thrombotic thrombocytopenic purpura and investigations required for diagnosis^[5].

Age at onset and clinical presentation	Probable diagnosis	Investigations to confirm diagnosis
Neonatal period Severe jaundice Porto colour urine without major hematuria Consanguineous family and/or similar symptoms or neonatal death in siblings	Congenital TTP (Upshaw-Schulman syndrome)	ADAMTS 13 deficiency (< 10%) without anti-ADAMTS 13 antibodies Mutation in ADAMTS13 (autosomal recessive)
Neonatal period-< 6 months Failure to thrive, feeding difficulties, hypotonia ± developmental delay Consanguineous family	Methyl-malonic aciduria-associated HUS	Hyperhomocysteinemia, hypomethioninemia, methylmalonic aciduria Mutation in MMACHC (autosomal recessive)
< 2 years Fever Invasive <i>S. pneumoniae</i> infection (proven or suspected): pneumonia, meningitis, septicaemia, especially if empyema or subdural collection	HUS due to <i>Streptococcus pneumoniae</i>	False positive Coombs test Positive cultures (blood, CSF) or PCR Positive T-activation test (exposure of the Thomsen-Friedenreich antigen on red blood cells) supports the diagnosis
> 6 months-5 years Diarrhea ± melena during the last 2 weeks Endemic region of STEC or <i>Shigella dysenteriae</i> infection	STEC-HUS (<i>Shigella dysenteriae</i> -HUS in endemic regions)	Stool or rectal swab: culture for STEC (Mac Conkey for O157:H7); PCR for Stx Serum: anti-LPS antibodies against the most common serotypes in the local country
Adolescents and adults Fever Central nervous system manifestations No or mild renal involvement Autoimmune context (SLE, APLS, thyroiditis) "From birth to adolescence and adult age No prodromic diarrhea or prodromic diarrhea but any of the following: - age < 6 months or > 5 years - insidious onset - relapse of HUS - suspicion of previous HUS - previous unexplained HUS - post-transplant HUS - pregnancy (post-partum) HUS - non synchronous familial HUS"	Immune TTP Complement-aHUS	ADAMTS 13 deficiency (< 10%) with anti-ADAMTS13 antibodies Complete investigation of the complement system

HUS: hemolytic uremic syndrome; TTP: thrombotic thrombocytopenic purpura; ADAMTS13: A Disintegrin And Metalloproteinase with a Thrombospondin type 1 motif, member 13; MMACHC: methylmalonic aciduria and homocystinuria; CSF: cerebro-spinal fluid; PCR: polymerase chain reaction; STEC: Shiga-toxin producing *Escherichia coli*; Stx: Shiga-like toxin; LPS: lipopolysaccharides

(Figure 1). The infection is almost always non-bloody diarrhoea at first. In 80% of patients, the diarrhoea becomes bloody between one and five days after the onset of diarrhoea^[33]. However, some patients may be infected with *E. coli* O157:H7 and develop HUS, and without having diarrhoea at all^[34,35]. So the presence of non-bloody diarrhoea is not against diagnosis of D+HUS.

The mechanisms by which hemorrhagic colitis and HUS occurs are not fully clear. The bacteria adhere to the mucosa of the colon causing bloody diarrhea then shiga like toxins reach the blood stream and attach to the endothelium of the small arterioles of the kidneys and other organs. The endothelial cells express a toxin-specific receptor that enables the contact between toxin and cells leading to endothelial damage which causes platelet aggregation, activation and fibrin deposition^[36].

Role of Podocyte dysfunction in HUS

Abnormal complement signalling as the only cause of a-HUS has been recently challenged as mutations in diacylglycerol kinase ϵ (DGKE) (which encodes a protein, diacylglycerol kinase ϵ) have been reported in children with a-HUS which is not a component of the complement system. Patients with DGKE mutations developed proteinuria which highlighted podocyte dysfunction as a complication of this form of a-HUS^[37]. Complement activation in a-HUS patients with genetic or autoimmune complement abnormalities, might also result in podocyte dysfunction and vice versa podocyte dysfunction that leads to nephrotic-range proteinuria might also predispose patients to the development of thrombotic microangiopathy (TMA)^[38].

In 2013, Lemaire and colleagues identified compound heterozygous and homozygous mutations in DGKE as the cause of a recessive form of a-HUS. Affected patients had a specific clinical phenotype with disease onset in the first year of life, several relapses before age of 5 years and all progressed to CKD before adulthood, long after the last relapse of a-HUS had occurred. Three of 12 patients developed nephrotic syndrome (NS) due to glomerular filtration barrier dysfunction. Compound heterozygous or homozygous mutations of DGKE were found in 27% of those patients with no anti-CFH autoantibodies or mutations in known complement a-HUS-associated genes detected^[37]. A Spanish cohort of 83 a-HUS children with onset before age of 2 years in 2014 described homozygous or compound heterozygous DGKE mutations in four patients (5%); three of these patients had recurrence of disease, however, also carried heterozygous mutations in THBD or C3^[39].

A two-way relationship between podocyte dysfunction and a-HUS pathogenesis is suggested. On one side, nephrotic-range proteinuria may occur in childhood forms of a-HUS associated with complement dysregulation and also in patients with DGKE genetic. Activation of Diacylglycerol - Protein kinase C (DAG-PKC) signalling is a common pathogenetic mechanism in a-HUS with both complement dysregulation and DGKE deficiency, leading to podocyte dysfunction. Conversely, podocyte dysfunction leading to nephrotic range proteinuria predisposes HUS cases to TMA by inducing prothrombotic abnormalities and endothelial dysfunction^[40].

Complement regulator factor H autoantibodies

Complement regulator factor H (CFH) autoantibodies (CFH-AAs) formation is a common cause of a-HUS; these patients have autoantibodies against CFH domains 19-20 (CFH19-20) which are nearly identical to CFH related protein-1 domains 4-5 (CFHR1 4-5). It is not known why nearly all the patients with autoimmune a-HUS lack CFHR1. CFH-AAs bind to a common site on the loop R1182-L1189 of CFH next to the buried two residues different in

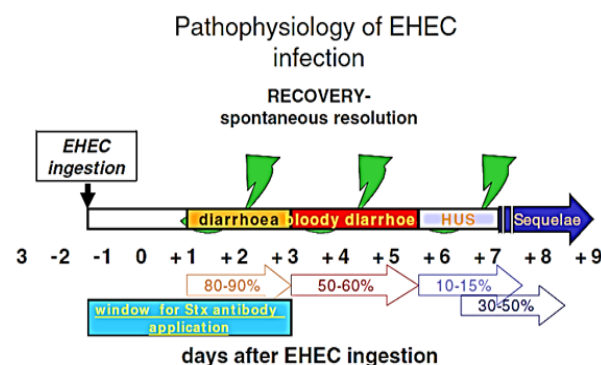


Figure 1: Pathophysiology of Enterohemorrhagic Escherichia coli infection and possible HUS development^[16].

CFH19-20 and CFHR14-5. The crystal structure of CFHR1 4-5 also showed that the conformation of the autoantigenic loop is different on CFH and CFHR1. These data provided the basis for the suggested novel model to explain how CFHR1 deficiency is linked to CFH-AA formation^[41], the autoantigenic epitope of CFH and its homologous site in CFHR1 are structurally different which provides an explanation for formation of autoantibodies caused by deficiency of CFHR1 in autoimmune a-HUS^[41].

CLINICAL PRESENTATION OF HUS

Extra renal manifestations of D+HUS and Diabetes risk

Whereas the kidney and gastrointestinal tract (GIT) are the most commonly affected organs in HUS, central nervous system (CNS), pancreatic, myocardial and skeletal, involvement is also reported^[42-44]. GIT involvement with severe colitis may lead to transmural necrosis with perforation and/or colonic stricture later on^[43,44]. CNS involvement in D+HUS is common and manifest as irritability and seizures, and in more severe cases, paresis, coma, and cerebral oedema. Skeletal muscle involvement manifested as rhabdomyolysis occurs in rare cases, and myocardial involvement is very rare as well^[45,46].

Pancreatic involvement is uncommon in HUS. Autopsy studies reported thrombosis of vessels supplying the islets of Langerhans with preservation of the exocrine pancreas^[47,48]. Little is known about the incidence and management of diabetes mellitus (DM) during D+HUS. A systematic review and metanalysis was conducted in 2005 to detect incidence of DM in D+HUS, severity of HUS attacks associated with DM and long term prognosis of such patients. The incidence of DM (hyperglycaemia requiring insulin) during acute D+HUS in children below 16 years of age was 0-15%, with pooled incidence estimated at 3.2% (95% CI 1.3-5.1). The development of DM was associated with severe disease, marked by CNS symptoms, the need for acute dialysis, and mortality. Children who developed DM during D+HUS and survived, one-third had permanent DM requiring insulin 6 months to 15 years after the acute phase, whereas two-thirds were reported to recover^[49]. No evidence supports that individuals infected with *E. coli* O157:H7 who develop gastroenteritis without HUS are at increased risk of DM^[50].

So frequent monitoring of blood glucose during acute D+HUS is a must, especially for patients on peritoneal dialysis (PD). Early aggressive treatment of hyperglycaemia will prevent ketoacidosis and improve acute outcomes, as in other critically ill patients^[51,52]. Continued loss of islet cells after recovery of acute attack of HUS may be due to ongoing inflammation and fibrosis, or decreased islet reserve which manifests clinically in those predisposed to type 2

DM. So, even cases that were not identified to have hyperglycaemia during the acute phase of D+ HUS may be at long-term risk of DM. Thus, consideration should be given to long-term screening of D+ HUS survivors for DM; the optimal timing of screening is unclear^[50].

LABORATORY TESTS FOR HUS

Diagnosis of HUS depends on careful history taking (Family history, history of diarrhoea and other infections), exclusion of D+HUS [screening for Shiga-toxin producing *E-coli* (STEC)] first followed by ADAMTS13 level assessment to exclude TTP and anti CFH antibodies followed by full complement pathway assessment including genetic studies (Figure 2).

Lactate Dehydrogenase levels in HUS

Lactate dehydrogenase (LDH) level is elevated in HUS and TTP cases. It is not diagnostic but used mainly in follow up. Total serum LDH rises mainly due to the release of red blood cell LDH due to intravascular haemolysis^[53] as in other haemolytic anaemias^[54,55]. This widely accepted belief has not been supported by LDH isoenzyme analysis^[56]. A large proportion of the increase in total serum LDH in patients with TTP is the result of systemic microvascular compromise, rather than erythrocyte lysis. Widespread tissue ischemia caused by occlusion of microvasculature by platelet thrombi has been well described in autopsy studies of patients with fulminant forms of HUS and TTP^[55].

IMAGING OF HUS WITH CENTRAL NERVOUS SYSTEM INVOLVEMENT

The central nervous system (CNS) is involved in 20–50% of HUS cases^[43,47,57]. A toxin-mediated vasculopathy involving the small intracerebral vessels similar to the kidneys is the probable mechanism^[58,59]. Severe fluid and electrolyte disturbances and hypertension may be responsible for encephalopathy in HUS patients^[43,47]. In many cases, Computed tomography (CT) has been the initial diagnostic imaging study of choice because of its greater availability, However magnetic resonant imaging (MRI) is nowadays the modality of choice for the evaluation of most non-traumatic CNS disease in children^[60].

Basal ganglia lesions was reported as the most frequent with HUS^[61-66]. Other findings, including territorial infarction or diffuse white-matter changes similar to posterior leukoencephalopathy, have been described, reflect complications rather than specific changes of the disease^[64,67,68]. Involvement of the basal ganglia is not specific for HUS and is seen in different conditions as severe hypoxia, intoxication and infectious diseases. This supports the theory of a direct or receptor-mediated verotoxin-induced injury as a mechanism of CNS involvement in HUS patients^[69].

MANAGEMENT OF HUS

Antimotility and Antibiotics in D+HUS

Antidiarrheal agents should be avoided in haemorrhagic colitis due EHEC, as it is thought that it lead to retention of Stx within the colon, which could enhance absorption of the toxin and confers greater risk for developing HUS^[70-72]. There is a long history of the discussion of antibiotic treatment for EHEC-induced diarrhoea. *In vitro* studies demonstrated that EHEC produces more toxins when stimulated by nonlethal concentrations of antibiotics, this issue has been under controversial discussion^[16]. During the large EHEC outbreak in

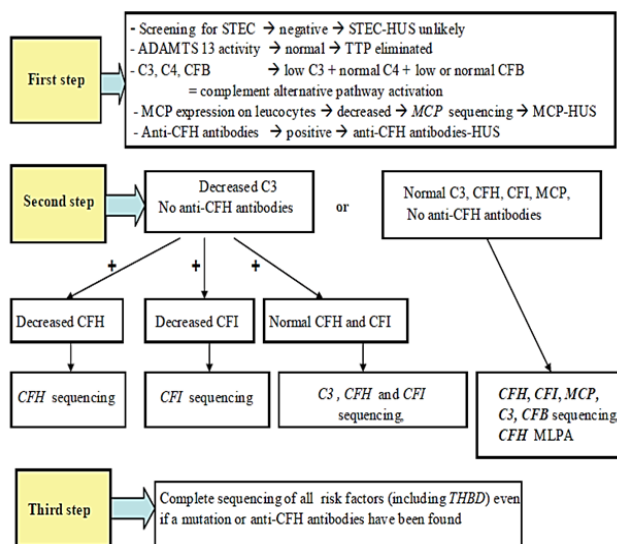


Figure 2 Complement system screening strategy in atypical hemolytic uremic syndrome. STEC: Shiga-toxin producing *Escherichia coli*; ADAMTS 13, A Disintegrin And Metalloproteinase with a Thrombospondin type 1 motif, member 13; CFH: factor H; CFI: factor I; CFB: factor B; MCP: membrane cofactor protein; THBD: thrombomodulin; MLPA, multiplex ligation dependent probe amplification^[5].

Table 2 Classification of HUS, TTP and related disorders^[91]

Table 1 Classification of HUS, TTP and related disorders (ADAMTS13 a disintegrin and metalloproteinase with a thrombospondin type 1 motif, member 13, HIV human immunodeficiency virus, HELLP hemolysis, elevated liver enzymes, low platelet count)

Box 1: etiology advanced

- 1.i. Infection-induced
 - (a) Shiga and shiga-like toxin-producing bacteria, Enterohemorrhagic *Escherichia coli*, *Shigella dysenteriae* type 1
 - (b) *Streptococcus pneumoniae*
- 1.ii. Disorders of complement regulation
 - (a) Genetic
 - (b) Acquired
- 1.iii. ADAMTS13 deficiency
 - (a) Genetic
 - (b) Acquired
- 1.iv. Defective cobalamin metabolism
- 1.v. Quinine-induced

Box 2: etiology unknown

- 2.i. HIV infection
- 2.ii. Malignancy, cancer chemotherapy, ionizing radiation
- 2.iii. Calcineurin inhibitors and transplantation
- 2.iv. Pregnancy HELLP syndrome, contraceptive pill
- 2.v. Systemic lupus erythematosus, anti-phospholipid antibody syndrome
- 2.vi. Glomerulopathy
- 2.vii. Familial not included in level 1
- 2.viii. Unclassified

ADAMTS13 a disintegrin and metalloproteinase with a thrombospondin type 1 motif, member 13, HIV human immunodeficiency virus, HELLP haemolysis, elevated liver enzymes, low platelet count).

Japan in 1996, it was suggested that treatment with Fosfomycin on day 2 after disease onset reduced the risk of developing HUS but this suggestion has several drawbacks. Fosfomycin is rarely used for this indication at all outside of Japan. Furthermore, recent epidemiological studies conducted by the Centre for Disease Control proved that antibiotic therapy for EHEC enteritis resulted in a significantly higher risk of developing HUS^[73]. This adverse outcome may reflect the effect of specific antimicrobial agents on phage induction and subsequent Stx gene expression and transcription or increased Stx release after induced bacteria lysis^[70,74-76].

Some studies demonstrated a harmful effect of antibiotic therapy in haemorrhagic colitis^[75-77]. Other studies have not demonstrated such an association. So currently, there is no consensus on the use of antibiotic therapy in children with haemorrhagic colitis or HUS; however, antibiotics are not usually prescribed in children with HUS until there are specific indications for antibiotic therapy. In conclusion, during the diarrheal phase, antibiotic treatment should be avoided, as beneficial effects regarding initiation of HUS cannot be deduced from recent studies^[70,77,78].

Role of steroids in HUS

In a-HUS as a result of CFH, CFI, C3, THBD, CFB, MCP mutations steroids are of no value, hence not indicated. Nevertheless a small subset of a-HUS patients (6-10%) develops CFH autoantibodies. They bind to C-terminus of CFH and decrease CFH binding to C3b with lack of complement control on cells.

Plasma exchange (PE) removes anti-CFH antibodies, but this effect is transient. Immunosuppressive therapy (steroids, azathioprine, MMF) and Rituximab (anti-CD20 antibody) combined with PE allowed long term dialysis free remission in 60-70% of patients^[23,79,80]. In countries where rapid assessment of CFH antibodies is not readily available or delayed, it is controversial whether to start empirical steroid therapy in all a-HUS cases.

Renal replacement therapy in D+HUS

To date, there is no effective preventive or specific treatment for D+HUS. Symptomatic and supportive measures are the main options^[16,81]. About two thirds of D+HUS children need dialysis therapy. General management of AKI as fluid and electrolyte balance, antihypertensives if required, and initiation of renal replacement therapy when indicated^[16].

In most centers, PD is the preferential choice. However, there is no priority to one or the other. Haemodialysis may be started if a-HUS is suggestive. This is true in older children and those without clear diarrhoea. In younger children, most centres prefer PD. It has been argued that PD may have a higher risk of peritonitis in patients with bloody diarrhoea. However this has not yet been reported^[72].

Platelet transfusions in HUS

Despite thrombocytopenia (30×10^3 - $60 \times 10^3/\text{mm}^3$) or even less, purpuric eruptions are uncommon with no or minimal bleeding reported in children with HUS^[5]. It has been theoretically postulated that transfusions of platelets should be avoided unless there is

severe bleeding or an invasive procedure is to be done. A study compared 22 (30%) cases who received platelet transfusion with 51 (70%) who did not and observed no bleeding complications related to these procedures in either group despite the associated thrombocytopenia^[82].

The rationale for avoiding platelet transfusion is the possibility that infused platelets may worsen the microvascular thrombosis and aggravating course of the disease^[16,82-84]. However, information on the effects of platelet infusions in D + HUS patients is scarce. In 2009 a report of 22 children with D + HUS showed that seven of them (31.8%) required platelet transfusions without reported additional morbidity or mortality^[85]. Due to limitations of studies, platelet transfusion should be avoided or minimized as possible in patients with HUS and decision to give a platelet transfusion must include the consideration that the perceived benefits outweigh the potential complications.

Intravenous Volume Expansion during E-coli O157:H7 infections

HUS can be categorized as either oligoanuric (which probably signifies ATN) or non-oligoanuric. Children with oligoanuric renal failure during HUS generally require dialysis, have more complicated courses, and at increased risk for chronic sequelae than children who experience non-oligoanuric HUS^[86].

Volume expansion during acute *E-coli* O157:H7 infection may oppose the small vessel thrombi formation by improving renal perfusion, preventing glomerular tubular imbalance from hypoperfusion and ischemia, and maintaining tubular flow. Volume expansion may also mitigate the nephrotoxicities of filtered urate^[87,88] and haemoglobin and of Shiga toxin's effects on renal tubular epithelial cells^[89] and monocytes^[90] that are independent of thrombotic changes. However, renal injury can still follow *E coli* O157:H7 infections in well-hydrated children. The only way to prevent HUS is prevention of *E-coli* O157:H7 infections^[86].

GUIDELINES OF THE EUROPEAN PAEDIATRIC STUDY GROUP FOR HUS

The European Paediatric Study Group for HUS in 2006 published "Classification of HUS, TTP and related disorders" (Table 3)^[91]. While the Guidelines for the investigation and initial therapy of D-HUS were published in 2009. The guideline describes a clinical pathway for cases of HUS and is intended to offer an approach based on opinion, as evidence is lacking. It is designed to streamline the recognition of those cases of HUS that have aetiologies other

Table 3 Step 2 of the guideline. Recommended list of investigations for patients identified as having atypical HUS^[92].

Classification	Investigation
	C3 (plasma/serum) ¹
	Factor H and factor I concentration (plasma/serum) ²
1.ii. Disorders of complement regulation	Factor H autoantibody
	MCP (CD46) (surface expression on mononuclear leukocytes by FACS)
	Gene mutation analysis in factor H, factor I, MCP, factor B and C3 ³
1.iii. ADAMTS13 (vWFcp) deficiency inherited or acquired classification	Plasma vWF protease (ADAMTS13) activity \pm inhibitor (plasma) ⁴ . Measure in acute phase of illness. Significant if activity <10% of normal. If low, check for autoantibody inhibitor. Repeat in remission. If persistently low activity in absence of inhibitor, inherited deficiency likely. Genetic confirmation optional at specialized genetic laboratories
1.iv. Cobalamin metabolism	Homocysteine, methylmalonic acid (plasma and urine) \pm mutation analysis in MMACHC gene
2.i. HIV	Serology
2.iv. Pregnancy HELLP syndrome	Pregnancy test, liver enzymes. Always consider pregnancy in teenage girl with HUS or TTP. Investigate as in 1.ii. and 1.iii. Above
2.v. Miscellaneous	Antinuclear antibody, lupus anticoagulant, anti-phospholipid antibodies

ADAMTS13 a disintegrin and metalloproteinase with a thrombospondin type 1 motif, member 13, vWFcp von Willebrand factor cleaving protease, HIV human immunodeficiency virus, HELLP haemolysis, elevated liver enzymes, low platelet count, MCP membrane co-factor protein, FACS fluorescence activated sorter MMACHC methylmalonic aciduria and homocysteinuria type C protein.

than EHEC (Table 4, Figures 3, 4)^[92]. Since then these guidelines are a standard and being followed worldwide and led to marked improvement in understanding and management of this disease. However after introduction of Eculizumab, clinicians worldwide believe that it should be the standard of care for all a-HUS cases^[92-94].

Interventions to promote endothelial cell health

Endothelial cell dysfunction, due to complement activation, is an intermediate stage in the pathogenesis of HUS^[95] so targeting endothelial cell dysfunction is gaining importance in the management of TMA^[96] with promising results in experimental settings. Inhibitors of angiotensin-converting enzyme (ACE), HMG- CoA reductase (statins), and xanthine oxidase as well as antioxidants (such as ascorbic acid) may have beneficial effects a-HUS. ACE inhibitors reduce angiotensin II-mediated oxidative stress within the vessel wall^[97]. By reducing oxidative inactivation of nitric oxide, ACE inhibitors improve endothelium-dependent vasodilation^[97,98].

Therefore, ACE inhibitors may be useful in a-HUS treatment by decreasing oxidant stress and increasing bioavailability of nitric oxide^[97]. Statins improve endothelial cell dysfunction by nitric oxide and decreased thrombogenicity. Statins also have immunomodulatory and anti-inflammatory properties^[99,100]. Allopurinol, is an inhibitor of xanthine oxidase, improve endothelial cell dysfunction^[101-103]. Ascorbic acid restores endothelium-dependent vasodilation by oxidative stress^[104] and increases the bioavailability of nitric oxide by scavenging reactive oxygen species^[95].

Haemolytic uremic syndrome after introduction of Eculizumab

For years, the only available treatment for a-HUS was plasma exchange, outcomes were poor and up to 60% of patients with CFH mutations (the most severe form) developed ESRD shortly after onset^[105]. First report of successful treatment HUS patients with Eculizumab was in 2009^[106]. The drug was approved by the Food and Drug Administration (FDA) for use in a- HUS treatment in September 2011 (FDA. News release September 23, 2011).

Eculizumab (Soliris) is a humanised monoclonal IgG2/4k antibody produced from murine myeloma cells. It is a complement inhibitor, binding to complement protein C5 with high affinity, thus inhibiting cleavage to C5a, a proinflammatory and prothrombotic and C5b, so prevent the generation of the terminal complement complex C5b-9^[94]. It is now used for paroxysmal nocturnal haemoglobinuria (PNH) and was tested for rheumatoid arthritis without success^[107].

A favourable outcome after use of eculizumab in three patients with severe D+HUS and CNS involvement was reported^[108]. A retrospective review of the excessive uncontrolled use of eculizumab, during outbreak of D+HUS in Germany, did not demonstrate a benefit for patients who received eculizumab, compared to patients who did not receive eculizumab^[109]. So no sufficient evidence is available currently to support the use of eculizumab for D+HUS patients^[33,110]. With time, the use of Eculizumab in a-HUS has increased. Renal function recovery has been described even after 6 months of dialysis^[111], neurological and ocular involvement (bilateral serous retinal detachment) were reported also to reverse with eculizumab^[112,113].

Therefore, the presence of extrarenal symptoms is critical when deciding to maintain anti-C5 therapy, regardless of renal replacement therapy requirement. Damage to extrarenal organs can progress in patients without renal function^[114,115]. This indicates subclinical activity, and that an increased platelet count is not always a reliable recovery marker, so other biomarkers of disease activity are required^[116]. Preventive measures (vaccination and if needed prophylactic antibiotics) should be initiated against Neisseria meningitides prior to starting treatment with eculizumab^[117]. Studies of long-term safety and efficacy of eculizumab are still few^[118,119].

Trials of discontinuation of life long maintenance Eculizumab

Discontinuing eculizumab therapy has been described in few reports^[120-125]. The main rationale for discontinuing eculizumab therapy was to protect patients from the risk of the potentially side effects as meningococcal infection^[126,127] and immune-mediated drug reactions, including the theoretical risk of developing neutralizing anti-drug antibodies that ultimately would deprive the patient of a life-saving therapeutic resource. Additionally, eculizumab is among the most expensive life-long medical treatments^[125].

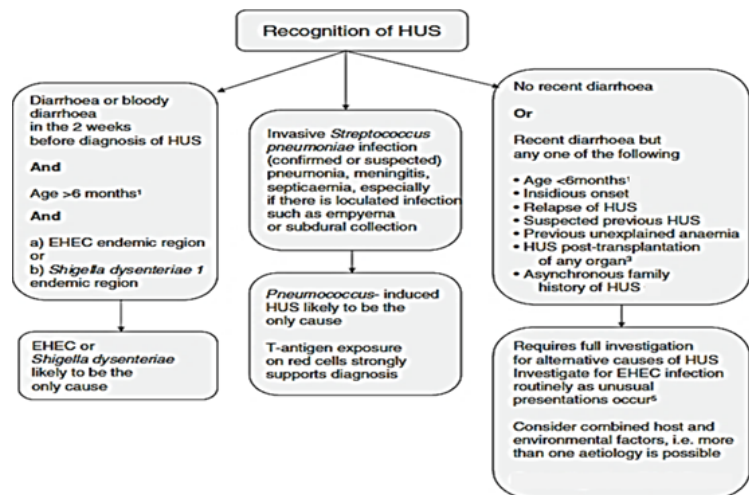


Figure 3 Step 1 of the guideline. Recognition of atypical HUS^[92]. HUS: Haemolytic uremic syndrome, EHEC: enterohemorrhagic E-coli.

Table 4 Genetic abnormalities and clinical outcome in patients with a-HUS^[149].

Complement abnormality	Main effect	Frequency, %	Death or ESRD within one year of first presentation, %	TMA post-transplantation,%
Factor H mutations	Increased activity of C3 convertase (decreased inhibition)	20 – 30	50 – 60	75 – 90
Factor I mutations	Decreased C3b inactivation	2 – 12	42 – 50	45 – 80
C3 mutations	C3 convertase resistant to inhibition	5 – 10	43 – 63	40 – 70
Factor B mutations	C3 convertase stabilisation (increased activity)	1 – 2	50	100
Thrombomodulin (THBD) mutations	Reduced C3b inactivation	0 – 5	50	1/1
Membrane cofactor Protein (MCP) mutations	Increased activity of C3 convertase (decreased inhibition)	3 – 15	0 – 63	≤ 20
Factor H antibodies	Inactive factor H (increased activity of C3)	6 – 10	30 – 40	Greater with elevated antibody levels

Adapted from Noris and Remuzzi^[25], Campistol *et al*^[117], Zuber *et al*^[133] and Fremaux-Bacchi *et al*^[132].

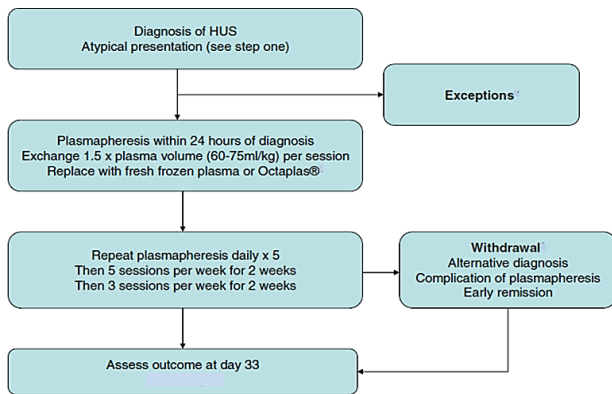


Figure 4 Step 3 of the guideline. Recommendations for the treatment of patients identified as having atypical HUS from step 1^[92].

OUTCOME OF TRANSPLANTED HUS CHILDREN

Patient with D+HUS rarely develop ESRD so renal transplantation is rarely required. However, reviews support that, a recurrence of HUS is the absolute exception in D+ HUS patients so transplantation can be performed without increased risk for failure^[128,129]. Before transplantation all a-HUS cases should have a complete genetic analysis to detect known complement mutations and anti-CFH antibodies and possibly the recurrence risk (Table 4). TMA presents in the transplanted kidney in around 50% of patients who undergo transplantation, and graft failure occurs in 80% – 100% of those with TMA^[25].

With a lack of guidelines, patients in whom a kidney transplant is considered should be evaluated on an individual basis, based on the risk of graft failure and availability of eculizumab^[117,130]. Different protocols to prevent recurrence of TMA including prophylactic plasmapheresis (Figure 5)^[5,131], Eculizumab^[132-134] or both are followed with variable results.

Combined liver and kidney transplantation in HUS

The most common mutation of complement regulatory proteins associated with a HUS is in the gene encoding CFH. Combined liver-kidney transplantation may correct this complement abnormality and prevent recurrence when the defect involves genes encoding circulating proteins that are synthesized in the liver, such as factor H or I. Good outcomes are reported when surgery is combined with intensive plasma therapy^[135].

LONG TERM FOLLOW UP OF D+HUS

Diarrhea associated HUS generally has a good prognosis as more than 95% of children recover from the acute phase^[136], however long-term renal sequelae have been reported in up to 25% of cases^[137]. Long term follow up of all D+HUS patients is mandatory. Studies have suggested that patients with less severe forms of HUS including those with a preserved urine output, may also develop renal sequel at follow up^[138,139].

Studies did not differentiate patients who apparently completely recovered after the acute illness from those who demonstrated persistent renal abnormalities regarding development of long term renal sequel^[78]. A study suggested that a quarter of those who recovered with an absence of proteinuria (<250 mg/day) went to develop renal sequel during long term follow up^[140].

Prognostic factors associated with poor outcomes in D+HUS

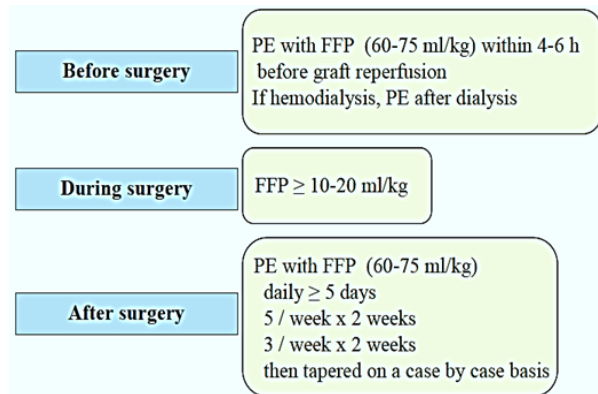


Figure 5 Recommendations for plasmapheresis to prevent post- kidney transplant recurrence of haemolytic uremic syndrome, according to the Consensus Study Group^[135]. PE: plasma exchange, FFP: fresh frozen plasma.

cases include: severity of acute illness (greater infection or host response) including elevated white blood cell count higher than 20×10^3 with neutrophilia^[141], a high serum creatinine^[142], CNS involvement^[34,138,140,143] and hypertension^[138,144]. Compared with patients with oliguria of 8 days or less, those with oliguria greater than 8 days or anuria 1-8 days and those with anuria of greater than 8 days had a step-wise worsening of prognosis^[9,144-146]. Dialysis therapy required for more than 4 weeks was associated with worse prognosis and no patient achieved full renal recovery^[138,141,147,148].

Progression of renal disease in HUS

Children with most severe forms of HUS do not recover from AKI and become dialysis dependence. A second group recovers renal function partially, with persistent proteinuria and hypertension and progress to ESRD within 2-5 years. The third group may recover normal serum creatinine and creatinine clearance but with persistent proteinuria. They are at risk of progressing to CKD and ESRD after 5 -20 years following the acute attack^[150].

Hyperfunction (hyperfiltration injury) of the remaining nephrons after acute attack of HUS is a probable mechanism of deterioration of kidney function after recovery of acute illness leading to progressive scarring and loss of renal function^[150-152]. Histologic changes in biopsied HUS patients during follow up (Biopsies done because of late or persistent proteinuria, hypertension, and prolonged renal failure) show focal and segmental glomerulosclerosis sclerosis (FSGS) and mesangial expansion in the glomeruli^[152]. This may highlight HUS as one of the possible causes of secondary FSGS. Close follow up and prompt control of hypertension to average or low-normal values, and treatment of proteinuria persisting for 6 months after the acute period with ACE inhibitors is recommended^[150].

ATYPICAL HUS IN DEVELOPING COUNTRIES

An adequate diagnostic work-up as an essential requirement for proper therapy, is currently impossible and unaffordable for most a-HUS patients in developing countries. International cooperation facilitating a proper diagnostic work-up in a stringent and cost-efficient manner are indispensable for diagnosis and therapy of many individuals suffering from these serious and life-threatening diseases. Nevertheless, while the costs for complement targeting drugs remain high, treatment of a-HUS patients especially in developing countries will remain a challenge^[153].

CONFLICT OF INTERESTS

The authors declare no conflict of interest.

REFERENCES

1. Srivastava, R.N., et al., Hemolytic uremic syndrome in children in northern India. *Pediatr Nephrol*, 1991. 5(3): p. 284-8.
2. Lanewala, A., et al., Pattern of pediatric renal disease observed in native renal biopsies in Pakistan. *J Nephrol*, 2009. 22(6): p. 739-46.
3. Jamal, A. and A. Ramzan, Renal and post-renal causes of acute renal failure in children. *J Coll Physicians Surg Pak*, 2004. 14(7): p. 411-5.
4. Shimelis, D. and Y. Tadesse, Clinical profile of acute renal failure in children admitted to the department of pediatrics, Tikur Anbessa Hospital. *Ethiop Med J*, 2004. 42(1): p. 17-22.
5. Loirat, C. and V. Fremeaux-Bacchi, Atypical hemolytic uremic syndrome. *Orphanet J Rare Dis*, 2011. 6: p. 60.
6. Gasser, C., et al., [Hemolytic-uremic syndrome: bilateral necrosis of the renal cortex in acute acquired hemolytic anemia]. *Schweiz Med Wochenschr*, 1955. 85(38-39): p. 905-9.
7. Td Davies, P., The haemolytic-uraemic syndrome: a report of ten cases treated in Nairobi. *East Afr Med J*, 1968. 45(3): p. 136-9.
8. Gianantonio, C., et al., The Hemolytic-Uremic Syndrome. *J Pediatr*, 1964. 64: p. 478-91.
9. Gianantonio, C.A., et al., The hemolytic-uremic syndrome. Renal status of 76 patients at long-term follow-up. *J Pediatr*, 1968. 72(6): p. 757-65.
10. Habib, R., H. Mathieu, and P. Royer, [Hemolytic-uremic syndrome of infancy: 27 clinical and anatomic observations]. *Nephron*, 1967. 4(3): p. 139-72.
11. Barnard, P.J. and M. Kibel, The Haemolytic-Uraemic Syndrome of Infancy and Childhood. A Report of Eleven Cases. *Cent Afr J Med*, 1965. 11: p. 4-11.
12. McLean, M.M., C.H. Jones, and D.A. Sutherland, Haemolytic-uraemic syndrome. A report of an outbreak. *Arch Dis Child*, 1966. 41(215): p. 76-81.
13. Ruthven, I.S. and W.M. Fyfe, The haemolytic uraemic syndrome—an epidemic disease? *Scott Med J*, 1968. 13(5): p. 162-5.
14. Karmali, M.A., et al., The association between idiopathic hemolytic uremic syndrome and infection by verotoxin-producing *Escherichia coli*. *J Infect Dis*, 1985. 151(5): p. 775-82.
15. O'Brien, A.O., et al., *Escherichia coli* O157:H7 strains associated with haemorrhagic colitis in the United States produce a *Shigella dysenteriae* 1 (SHIGA) like cytotoxin. *Lancet*, 1983. 1(8326 Pt 1): p. 702.
16. Scheiring, J., S.P. Andreoli, and L.B. Zimmerhackl, Treatment and outcome of Shiga-toxin-associated hemolytic uremic syndrome (HUS). *Pediatr Nephrol*, 2008. 23(10): p. 1749-60.
17. Hagge, W.W., et al., Hemolytic-uremic syndrome in two siblings. *N Engl J Med*, 1967. 277(3): p. 138-9.
18. Chan, J.C., M.G. Eleff, and R.A. Campbell, The hemolytic-uremic syndrome in nonrelated adopted siblings. *J Pediatr*, 1969. 75(6): p. 1050-3.
19. Kaplan, B.S., R.W. Chesney, and K.N. Drummond, Hemolytic uremic syndrome in families. *N Engl J Med*, 1975. 292(21): p. 1090-3.
20. Blattler, W., et al., [Proceedings: Familial hemolytic-uremic syndrome. Studies on pathogenesis in the survivors]. *Schweiz Med Wochenschr*, 1975. 105(51): p. 1773-4.
21. Edelsten, A.D. and S. Tuck, Familial haemolytic uraemic syndrome. *Arch Dis Child*, 1978. 53(3): p. 255-6.
22. Cameron, J.S. and R. Vick, Letter: Plasma-C3 in haemolytic-uraemic syndrome and thrombotic thrombocytopenic purpura. *Lancet*, 1973. 2(7835): p. 975.
23. Dragon-Durey, M.A., et al., Anti-Factor H autoantibodies associated with atypical hemolytic uremic syndrome. *J Am Soc Nephrol*, 2005. 16(2): p. 555-63.
24. Richards, A., et al., Mutations in human complement regulator, membrane cofactor protein (CD46), predispose to development of familial hemolytic uremic syndrome. *Proc Natl Acad Sci U S A*, 2003. 100(22): p. 12966-71.
25. Noris, M. and G. Remuzzi, Atypical hemolytic-uremic syndrome. *N Engl J Med*, 2009. 361(17): p. 1676-87.
26. Kavanagh, D. and T. Goodship, Genetics and complement in atypical HUS. *Pediatr Nephrol*, 2010. 25(12): p. 2431-42.
27. Saunders, R.E., et al., The interactive Factor H-atypical hemolytic uremic syndrome mutation database and website: update and integration of membrane cofactor protein and Factor I mutations with structural models. *Hum Mutat*, 2007. 28(3): p. 222-34.
28. Noris, M., et al., Relative role of genetic complement abnormalities in sporadic and familial aHUS and their impact on clinical phenotype. *Clin J Am Soc Nephrol*, 2010. 5(10): p. 1844-59.
29. Maga, T.K., et al., Mutations in alternative pathway complement proteins in American patients with atypical hemolytic uremic syndrome. *Hum Mutat*, 2010. 31(6): p. E1445-60.
30. Bienaime, F., et al., Mutations in components of complement influence the outcome of Factor I-associated atypical hemolytic uremic syndrome. *Kidney Int*, 2010. 77(4): p. 339-49.
31. Loirat, C., M. Noris, and V. Fremeaux-Bacchi, Complement and the atypical hemolytic uremic syndrome in children. *Pediatr Nephrol*, 2008. 23(11): p. 1957-72.
32. Rees, L., Atypical HUS: time to take stock of current guidelines and outcome measures? *Pediatr Nephrol*, 2013. 28(5): p. 675-7.
33. Petruzzello-Pellegrini, T.N. and P.A. Marsden, Shiga toxin-associated hemolytic uremic syndrome: advances in pathogenesis and therapeutics. *Curr Opin Nephrol Hypertens*, 2012. 21(4): p. 433-40.
34. Brandt, J.R., et al., *Escherichia coli* O157:H7-associated hemolytic-uremic syndrome after ingestion of contaminated hamburgers. *J Pediatr*, 1994. 125(4): p. 519-26.
35. Miceli, S., et al., A clinical and bacteriological study of children suffering from haemolytic uraemic syndrome in Tucuman, Argentina. *Jpn J Infect Dis*, 1999. 52(2): p. 33-7.
36. Proesmans, W., The role of coagulation and fibrinolysis in the pathogenesis of diarrhea-associated hemolytic uremic syndrome. *Semin Thromb Hemost*, 2001. 27(3): p. 201-5.
37. Lemaire, M., et al., Recessive mutations in DGKE cause atypical hemolytic-uremic syndrome. *Nat Genet*, 2013. 45(5): p. 531-6.
38. Noris, M., C. Mele, and G. Remuzzi, Podocyte dysfunction in atypical haemolytic uraemic syndrome. *Nat Rev Nephrol*, 2015.
39. Sanchez Chinchilla, D., et al., Complement mutations in diacylglycerol kinase-epsilon-associated atypical hemolytic uremic syndrome. *Clin J Am Soc Nephrol*, 2014. 9(9): p. 1611-9.
40. Fogo, A.B. and V. Kon, The glomerulus—a view from the inside—the endothelial cell. *Int J Biochem Cell Biol*, 2010. 42(9): p. 1388-97.
41. Bhattacharjee, A., et al., The major autoantibody epitope on Factor H in atypical Hemolytic Uremic Syndrome is structurally different from its homologous site in Factor H related protein 1 supporting a novel model for induction of autoimmunity in this disease. *J Biol Chem*, 2015.
42. Richardson, S.E., et al., The histopathology of the hemolytic uremic syndrome associated with verocytotoxin-producing *Escherichia coli* infections. *Hum Pathol*, 1988. 19(9): p. 1102-8.
43. Siegler, R.L., Spectrum of extrarenal involvement in postdiarrheal hemolytic-uremic syndrome. *J Pediatr*, 1994. 125(4): p. 511-8.
44. Sebbag, H., et al., Colonic stenosis after hemolytic-uremic syndrome. *Eur J Pediatr Surg*, 1999. 9(2): p. 119-20.
45. Askiti, V., et al., Troponin I levels in a hemolytic uremic syndrome patient with severe cardiac failure. *Pediatr Nephrol*, 2004. 19(3): p. 345-8.

46. Ruggenenti, P., M. Noris, and G. Remuzzi, Thrombotic microangiopathy, hemolytic uremic syndrome, and thrombotic thrombocytopenic purpura. *Kidney Int*, 2001. 60(3): p. 831-46.
47. Gallo, E.G. and C.A. Gianantonio, Extrarenal involvement in diarrhoea-associated haemolytic-uraemic syndrome. *Pediatr Nephrol*, 1995. 9(1): p. 117-9.
48. Gianantonio, C.A., et al., The hemolytic-uremic syndrome. *Nephron*, 1973. 11(2): p. 174-92.
49. Suri, R.S., et al., Diabetes during diarrhea-associated hemolytic uremic syndrome: a systematic review and meta-analysis. *Diabetes Care*, 2005. 28(10): p. 2556-62.
50. Suri, R.S., et al., Relationship between *Escherichia coli* O157:H7 and diabetes mellitus. *Kidney Int Suppl*, 2009(112): p. S44-6.
51. van den Berghe, G., et al., Intensive insulin therapy in critically ill patients. *N Engl J Med*, 2001. 345(19): p. 1359-67.
52. Malmberg, K., Prospective randomised study of intensive insulin treatment on long term survival after acute myocardial infarction in patients with diabetes mellitus. DIGAMI (Diabetes Mellitus, Insulin Glucose Infusion in Acute Myocardial Infarction) Study Group. *BMJ*, 1997. 314(7093): p. 1512-5.
53. Cohen, J.A., M.E. Brecher, and N. Bandarenko, Cellular source of serum lactate dehydrogenase elevation in patients with thrombotic thrombocytopenic purpura. *J Clin Apher*, 1998. 13(1): p. 16-9.
54. Bell, W., Thrombotic thrombocytopenic purpura. *JAMA*, 1991. 265(1): p. 91-3.
55. Bukowski, R.M., Thrombotic thrombocytopenic purpura: a review. *Prog Hemost Thromb*, 1982. 6: p. 287-337.
56. Taft, E.G., Thrombotic thrombocytopenic purpura and dose of plasma exchange. *Blood*, 1979. 54(4): p. 842-9.
57. Cimolai, N., B.J. Morrison, and J.E. Carter, Risk factors for the central nervous system manifestations of gastroenteritis-associated hemolytic-uremic syndrome. *Pediatrics*, 1992. 90(4): p. 616-21.
58. Ren, J., et al., Localization of verotoxin receptors in nervous system. *Brain Res*, 1999. 825(1-2): p. 183-8.
59. Taylor, F.B., Jr., et al., Characterization of the baboon responses to Shiga-like toxin: descriptive study of a new primate model of toxic responses to Stx-1. *Am J Pathol*, 1999. 154(4): p. 1285-99.
60. Steinborn, M., et al., CT and MRI in haemolytic uraemic syndrome with central nervous system involvement: distribution of lesions and prognostic value of imaging findings. *Pediatr Radiol*, 2004. 34(10): p. 805-10.
61. DiMario, F.J., Jr., et al., Lacunar infarction of the basal ganglia as a complication of hemolytic-uremic syndrome. MRI and clinical correlations. *Clin Pediatr (Phila)*, 1987. 26(11): p. 586-90.
62. Theobald, I., et al., Central nervous system involvement in hemolytic uremic syndrome (HUS)—a retrospective analysis of cerebral CT and MRI studies. *Clin Nephrol*, 2001. 56(6): p. S3-8.
63. Barnett, N.D., et al., Hemolytic uremic syndrome with particular involvement of basal ganglia and favorable outcome. *Pediatr Neurol*, 1995. 12(2): p. 155-8.
64. Taylor, M.B., A. Jackson, and J.M. Weller, Dynamic susceptibility contrast enhanced MRI in reversible posterior leukoencephalopathy syndrome associated with haemolytic uraemic syndrome. *Br J Radiol*, 2000. 73(868): p. 438-42.
65. Schmidt, S., et al., Brain involvement in haemolytic-uraemic syndrome: MRI features of coagulative necrosis. *Neuroradiology*, 2001. 43(7): p. 581-5.
66. Hager, A., et al., Hemolytic-uremic syndrome with involvement of basal ganglia and cerebellum. *Neuropediatrics*, 1999. 30(4): p. 210-3.
67. Ogura, H., et al., Reversible MR findings of hemolytic uremic syndrome with mild encephalopathy. *AJNR Am J Neuroradiol*, 1998. 19(6): p. 1144-5.
68. Signorini, E., et al., Central nervous system involvement in a child with hemolytic uremic syndrome. *Pediatr Nephrol*, 2000. 14(10-11): p. 990-2.
69. Ho, V.B., et al., Bilateral basal ganglia lesions: pediatric differential considerations. *Radiographics*, 1993. 13(2): p. 269-92.
70. Tarr, P.I., C.A. Gordon, and W.L. Chandler, Shiga-toxin-producing *Escherichia coli* and haemolytic uraemic syndrome. *Lancet*, 2005. 365(9464): p. 1073-86.
71. Andreoli, S.P., et al., Hemolytic uremic syndrome: epidemiology, pathophysiology, and therapy. *Pediatr Nephrol*, 2002. 17(4): p. 293-8.
72. Zimmerhackl, L.B., Epidemiology, pathogenesis and therapeutic modalities in hemolytic-uremic syndrome. *Kidney Blood Press Res*, 1998. 21(2-4): p. 290-2.
73. Slutsker, L., et al., A nationwide case-control study of *Escherichia coli* O157:H7 infection in the United States. *J Infect Dis*, 1998. 177(4): p. 962-6.
74. Karch, H., et al., New aspects in the pathogenesis of enteropathic hemolytic uremic syndrome. *Semin Thromb Hemost*, 2006. 32(2): p. 105-12.
75. Wong, C.S., et al., The risk of the hemolytic-uremic syndrome after antibiotic treatment of *Escherichia coli* O157:H7 infections. *N Engl J Med*, 2000. 342(26): p. 1930-6.
76. Safdar, N., et al., Risk of hemolytic uremic syndrome after antibiotic treatment of *Escherichia coli* O157:H7 enteritis: a meta-analysis. *JAMA*, 2002. 288(8): p. 996-1001.
77. Zimmerhackl, L.B., *E. coli*, antibiotics, and the hemolytic-uremic syndrome. *N Engl J Med*, 2000. 342(26): p. 1990-1.
78. Garg, A.X., et al., Long-term renal prognosis of diarrhea-associated hemolytic uremic syndrome: a systematic review, meta-analysis, and meta-regression. *JAMA*, 2003. 290(10): p. 1360-70.
79. Watt, T., B. Warshaw, and H.M. Katzenstein, Atypical hemolytic uremic syndrome responsive to steroids and intravenous immune globulin. *Pediatr Blood Cancer*, 2009. 53(1): p. 90-1.
80. Kwon, T., et al., Successful pre-transplant management of a patient with anti-factor H autoantibodies-associated haemolytic uraemic syndrome. *Nephrol Dial Transplant*, 2008. 23(6): p. 2088-90.
81. Bitzan, M., Treatment options for HUS secondary to *Escherichia coli* O157:H7. *Kidney Int Suppl*, 2009(112): p. S62-6.
82. Weil, B.R., S.P. Andreoli, and D.F. Billmire, Bleeding risk for surgical dialysis procedures in children with hemolytic uremic syndrome. *Pediatr Nephrol*, 2010. 25(9): p. 1693-8.
83. Scheiring, J., A. Rosales, and L.B. Zimmerhackl, Clinical practice. Today's understanding of the haemolytic uraemic syndrome. *Eur J Pediatr*, 2010. 169(1): p. 7-13.
84. Iijima, K., I. Kamioka, and K. Nozu, Management of diarrhea-associated hemolytic uremic syndrome in children. *Clin Exp Nephrol*, 2008. 12(1): p. 16-9.
85. Matsell, D.G. and C.T. White, An outbreak of diarrhea-associated childhood hemolytic uremic syndrome: the Walkerton epidemic. *Kidney Int Suppl*, 2009(112): p. S35-7.
86. Ake, J.A., et al., Relative nephroprotection during *Escherichia coli* O157:H7 infections: association with intravenous volume expansion. *Pediatrics*, 2005. 115(6): p. e673-80.
87. O'Regan, S. and E. Rousseau, Hemolytic uremic syndrome: urate nephropathy superimposed on an acute glomerulopathy? An hypothesis. *Clin Nephrol*, 1988. 30(4): p. 207-10.
88. Kaplan, B.S. and P.D. Thomson, Hyperuricemia in the hemolytic-uremic syndrome. *Am J Dis Child*, 1976. 130(8): p. 854-6.
89. Hughes, A.K., et al., Cytotoxic effect of Shiga toxin-1 on human glomerular epithelial cells. *Kidney Int*, 2000. 57(6): p. 2350-9.
90. Ramegowda, B. and V.L. Tesh, Differentiation-associated toxin receptor modulation, cytokine production, and sensitivity to Shiga-like toxins in human monocytes and monocytic cell lines. *Infect Immun*, 1996. 64(4): p. 1173-80.
91. Besbas, N., et al., A classification of hemolytic uremic syndrome and thrombotic thrombocytopenic purpura and related disorders. *Kidney Int*, 2006. 70(3): p. 423-31.
92. Ariceta, G., et al., Guideline for the investigation and initial therapy of diarrhea-negative hemolytic uremic syndrome. *Pediatr*

- Nephrol, 2009. 24(4): p. 687-96.
93. Bu, F., et al., Familial atypical hemolytic uremic syndrome: a review of its genetic and clinical aspects. *Clin Dev Immunol*, 2012. 2012: p. 370426.
 94. Zuber, J., et al., Use of eculizumab for atypical haemolytic uraemic syndrome and C3 glomerulopathies. *Nat Rev Nephrol*, 2012. 8(11): p. 643-57.
 95. Nayer, A. and A. Asif, Atypical Hemolytic-Uremic Syndrome: A Clinical Review. *Am J Ther*, 2014.
 96. Goldberg, R.J., et al., The role of endothelial cell injury in thrombotic microangiopathy. *Am J Kidney Dis*, 2010. 56(6): p. 1168-74.
 97. Koh, K.K., et al., Mechanism by which quinapril improves vascular function in coronary artery disease. *Am J Cardiol*, 1999. 83(3): p. 327-31.
 98. Koh, K.K., et al., Anti-inflammatory and metabolic effects of candesartan in hypertensive patients. *Int J Cardiol*, 2006. 108(1): p. 96-100.
 99. Blanco-Colio, L.M., et al., Anti-inflammatory and immunomodulatory effects of statins. *Kidney Int*, 2003. 63(1): p. 12-23.
 100. O'Driscoll, G., D. Green, and R.R. Taylor, Simvastatin, an HMG-coenzyme A reductase inhibitor, improves endothelial function within 1 month. *Circulation*, 1997. 95(5): p. 1126-31.
 101. Yiginer, O., et al., Allopurinol improves endothelial function and reduces oxidant-inflammatory enzyme of myeloperoxidase in metabolic syndrome. *Clin Res Cardiol*, 2008. 97(5): p. 334-40.
 102. Butler, R., et al., Allopurinol normalizes endothelial dysfunction in type 2 diabetics with mild hypertension. *Hypertension*, 2000. 35(3): p. 746-51.
 103. George, J., et al., High-dose allopurinol improves endothelial function by profoundly reducing vascular oxidative stress and not by lowering uric acid. *Circulation*, 2006. 114(23): p. 2508-16.
 104. Beckman, J.A., et al., Ascorbate restores endothelium-dependent vasodilation impaired by acute hyperglycemia in humans. *Circulation*, 2001. 103(12): p. 1618-23.
 105. Besbas, N., et al., Neonatal onset atypical hemolytic uremic syndrome successfully treated with eculizumab. *Pediatr Nephrol*, 2013. 28(1): p. 155-8.
 106. Gruppo, R.A. and R.P. Rother, Eculizumab for congenital atypical hemolytic-uremic syndrome. *N Engl J Med*, 2009. 360(5): p. 544-6.
 107. Hillmen, P., et al., Long-term safety and efficacy of sustained eculizumab treatment in patients with paroxysmal nocturnal haemoglobinuria. *Br J Haematol*, 2013. 162(1): p. 62-73.
 108. Lapeyraque, A.L., et al., Eculizumab in severe Shiga-toxin-associated HUS. *N Engl J Med*, 2011. 364(26): p. 2561-3.
 109. Menne, J., et al., Validation of treatment strategies for enterohaemorrhagic *Escherichia coli* O104:H4 induced haemolytic uraemic syndrome: case-control study. *BMJ*, 2012. 345: p. e4565.
 110. Noris, M., F. Mescia, and G. Remuzzi, STEC-HUS, atypical HUS and TTP are all diseases of complement activation. *Nat Rev Nephrol*, 2012. 8(11): p. 622-33.
 111. Povey, H., et al., Renal recovery with eculizumab in atypical hemolytic uremic syndrome following prolonged dialysis. *Clin Nephrol*, 2014. 82(5): p. 326-31.
 112. Avila, A., et al., Remission of aHUS neurological damage with eculizumab. *Clin Kidney J*, 2015. 8(2): p. 232-236.
 113. David, R., S. Hochberg-Klein, and R. Amer, Resolution of ocular involvement with systemic eculizumab therapy in atypical hemolytic-uremic syndrome. *Eye (Lond)*, 2013. 27(8): p. 997-8.
 114. Bekassy, Z.D., et al., Eculizumab in an anephric patient with atypical haemolytic uraemic syndrome and advanced vascular lesions. *Nephrol Dial Transplant*, 2013. 28(11): p. 2899-907.
 115. Salem, G., J.M. Flynn, and S.R. Cataland, Profound neurological injury in a patient with atypical hemolytic uremic syndrome. *Ann Hematol*, 2013. 92(4): p. 557-8.
 116. Dorresteijn, E.M., N.C. van de Kar, and K. Cransberg, Eculizumab as rescue therapy for atypical hemolytic uremic syndrome with normal platelet count. *Pediatr Nephrol*, 2012. 27(7): p. 1193-5.
 117. Campistol, J.M., et al., An update for atypical haemolytic uraemic syndrome: diagnosis and treatment. A consensus document. *Nefrologia*, 2013. 33(1): p. 27-45.
 118. Legendre, C.M., et al., Terminal complement inhibitor eculizumab in atypical hemolytic-uremic syndrome. *N Engl J Med*, 2013. 368(23): p. 2169-81.
 119. Licht, C., et al., Efficacy and safety of eculizumab in atypical hemolytic uremic syndrome from 2-year extensions of phase 2 studies. *Kidney Int*, 2015.
 120. Carr, R. and S.R. Cataland, Relapse of aHUS after discontinuation of therapy with eculizumab in a patient with aHUS and factor H mutation. *Ann Hematol*, 2013. 92(6): p. 845-6.
 121. Mache, C.J., et al., Complement inhibitor eculizumab in atypical hemolytic uremic syndrome. *Clin J Am Soc Nephrol*, 2009. 4(8): p. 1312-6.
 122. Zuber, J., et al., New insights into postrenal transplant hemolytic uremic syndrome. *Nat Rev Nephrol*, 2011. 7(1): p. 23-35.
 123. Cayci, F.S., et al., Eculizumab therapy in a child with hemolytic uremic syndrome and CFI mutation. *Pediatr Nephrol*, 2012. 27(12): p. 2327-31.
 124. Gulleroglu, K., et al., Neurologic involvement in atypical hemolytic uremic syndrome and successful treatment with eculizumab. *Pediatr Nephrol*, 2013. 28(5): p. 827-30.
 125. Ardissino, G., et al., Discontinuation of eculizumab maintenance treatment for atypical hemolytic uremic syndrome: a report of 10 cases. *Am J Kidney Dis*, 2014. 64(4): p. 633-7.
 126. Struijk, G.H., et al., Meningococcal sepsis complicating eculizumab treatment despite prior vaccination. *Am J Transplant*, 2013. 13(3): p. 819-20.
 127. Ram, S., L.A. Lewis, and P.A. Rice, Infections of people with complement deficiencies and patients who have undergone splenectomy. *Clin Microbiol Rev*, 2010. 23(4): p. 740-80.
 128. Zimmerhackl, L.B., et al., Renal transplantation in HUS patients with disorders of complement regulation. *Pediatr Nephrol*, 2007. 22(1): p. 10-6.
 129. Loirat, C. and P. Niaudet, The risk of recurrence of hemolytic uremic syndrome after renal transplantation in children. *Pediatr Nephrol*, 2003. 18(11): p. 1095-101.
 130. Saland, J., Liver-kidney transplantation to cure atypical HUS: still an option post-eculizumab? *Pediatr Nephrol*, 2014. 29(3): p. 329-32.
 131. Davin, J.C., et al., Prophylactic plasma exchange in CD46-associated atypical haemolytic uremic syndrome. *Pediatr Nephrol*, 2009. 24(9): p. 1757-60.
 132. Fremeaux-Bacchi, V., et al., Genetics and outcome of atypical hemolytic uremic syndrome: a nationwide French series comparing children and adults. *Clin J Am Soc Nephrol*, 2013. 8(4): p. 554-62.
 133. Zuber, J., et al., Eculizumab for atypical hemolytic uremic syndrome recurrence in renal transplantation. *Am J Transplant*, 2012. 12(12): p. 3337-54.
 134. Le Quintec, M., et al., Complement genes strongly predict recurrence and graft outcome in adult renal transplant recipients with atypical hemolytic and uremic syndrome. *Am J Transplant*, 2013. 13(3): p. 663-75.
 135. Saland, J.M., et al., Liver-kidney transplantation to cure atypical hemolytic uremic syndrome. *J Am Soc Nephrol*, 2009. 20(5): p. 940-9.
 136. Repetto, H.A., [Long-term course of the renal lesion of the hemolytic-uremic syndrome]. *Medicina (B Aires)*, 1987. 47(1): p. 108.
 137. Mele, C., G. Remuzzi, and M. Noris, Hemolytic uremic syndrome. *Semin Immunopathol*, 2014. 36(4): p. 399-420.
 138. Tonshoff, B., et al., Outcome and prognostic determinants in the hemolytic uremic syndrome of children. *Nephron*, 1994. 68(1): p. 63-70.
 139. Gagnadoux, M.F., et al., Long-term (15-25 years) outcome of

- childhood hemolytic-uremic syndrome. *Clin Nephrol*, 1996. 46(1): p. 39-41.
140. Spizzirri, F.D., et al., Childhood hemolytic uremic syndrome in Argentina: long-term follow-up and prognostic features. *Pediatr Nephrol*, 1997. 11(2): p. 156-60.
 141. Fitzpatrick, M.M., et al., Long term renal outcome of childhood haemolytic uraemic syndrome. *BMJ*, 1991. 303(6801): p. 489-92.
 142. Miyazaki, S., [The etiology and clinical features of hemolytic uremic syndrome]. *Rinsho Ketsueki*, 1994. 35(4): p. 341-5.
 143. Kelles, A., M. Van Dyck, and W. Proesmans, Childhood haemolytic uraemic syndrome: long-term outcome and prognostic features. *Eur J Pediatr*, 1994. 153(1): p. 38-42.
 144. Huseman, D., et al., Long-term prognosis of hemolytic uremic syndrome and effective renal plasma flow. *Pediatr Nephrol*, 1999. 13(8): p. 672-7.
 145. Monnens, L., et al., Treatment of the hemolytic-uremic syndrome. Comparison of the results of heparin treatment with the results of streptokinase treatment. *Helv Paediatr Acta*, 1978. 33(4-5): p. 321-8.
 146. Gillor, A., et al., [Diagnosis and treatment of cardiac rhabdomyomas]. *Monatsschr Kinderheilkd*, 1986. 134(7): p. 445-9.
 147. Small, G., et al., Hemolytic uremic syndrome: defining the need for long-term follow-up. *Clin Nephrol*, 1999. 52(6): p. 352-6.
 148. Hughes, D.A., T.J. Beattie, and A.V. Murphy, Haemolytic uraemic syndrome: 17 years' experience in a Scottish paediatric renal unit. *Scott Med J*, 1991. 36(1): p. 9-12.
 149. Franchini, M., Atypical hemolytic uremic syndrome: from diagnosis to treatment. *Clin Chem Lab Med*, 2015.
 150. Repetto, H.A., Long-term course and mechanisms of progression of renal disease in hemolytic uremic syndrome. *Kidney Int Suppl*, 2005(97): p. S102-6.
 151. Dieguez, S., et al., Renal functional reserve evolution in children with a previous episode of hemolytic uremic syndrome. *Nephron Clin Pract*, 2004. 97(3): p. c118-22.
 152. Caletti, M.G., G. Gallo, and C.A. Gianantonio, Development of focal segmental sclerosis and hyalinosis in hemolytic uremic syndrome. *Pediatr Nephrol*, 1996. 10(6): p. 687-92.
 153. Hofer, J., T. Giner, and H. Safouh, Diagnosis and treatment of the hemolytic uremic syndrome disease spectrum in developing regions. *Semin Thromb Hemost*, 2014. 40(4): p. 478-86.
- Peer reviewer:** Zuo, Li MD PhD, Department of Nephrology, Peking University People's Hospital, 11 Xizhimennan Street, Haidian District, Beijing, 100044, China.