

## Alternative Approach to Removal of a Retained Chest Tube

Modupeola Diyaolu<sup>1</sup>, MD; Bethany Malone<sup>1</sup>, MD; Michael S. Firstenberg<sup>2</sup>, MD

1 Summa Health System, Department of Surgery, Summa Akron City Hospital, Akron, OH, the United States;

2 Department of Surgery, The Medical Center of Aurora, Aurora CO and Northeast Ohio Medical Universities, Rootstown, OH, the United States.

**Conflict-of-interest statement:** The author(s) declare(s) that there is no conflict of interest regarding the publication of this paper.

**Open-Access:** This article is an open-access article which was selected by an in-house editor and fully peer-reviewed by external reviewers. It is distributed in accordance with the Creative Commons Attribution Non Commercial (CC BY-NC 4.0) license, which permits others to distribute, remix, adapt, build upon this work non-commercially, and license their derivative works on different terms, provided the original work is properly cited and the use is non-commercial. See: <http://creativecommons.org/licenses/by-nc/4.0/>

**Corresponding Author:** Michael S Firstenberg, MD, FACC, The Medical Center of Aurora, 1444 S. Potomac Street, Suite 390, Aurora, CO 80012, Adjunct Faculty, College of Graduate Studies and Associate Professor of Surgery and Integrative Medicine, Northeast Ohio Medical University, Rootstown, Ohio, the United States

Email: [msfirst@gmail.com](mailto:msfirst@gmail.com)  
Telephone: +386-1-522-9626

Received: August 26, 2019

Revised: October 19, 2019

Accepted: October 21, 2019

Published online: November 24, 2019

### ABSTRACT

Chest tubes are a staple of cardiothoracic surgery used both in the pre-operative setting and post-operatively. Placement of the chest tube is equally as important as removal. When a chest tube cannot be removed, most often due to a suture through the tube, it typically results in the patient returning to the operating room for an additional procedure. Alternatively, by using fiberoptic bronchoscopy, the physician can visualize the problem and use endoscopic instruments to correct it, thereby saving the patient from having to endure another invasive procedure.

**Keywords:** Monosymptomatic enuresis; Desmopressin; Attention

deficit hyperactivity disorder; Body mass index; Family history

© 2019 The Author(s). Published by ACT Publishing Group Ltd. All rights reserved.

Diyaolu M, Malone B, Firstenberg MS. Alternative Approach to Removal of a Retained Chest Tube. *Journal of Nephrology Research* 2019; 5(1): 162-163 Available from: URL: <http://www.ghrnet.org/index.php/jnr/article/view/2762>

### INTRODUCTION

Closing a thoracotomy incision requires closure of the chest wall with re-approximation of the ribs and intercostal spaces using a large caliber needle with sturdy absorbable suture. Given the relative size of the needle, the chest tube may inadvertently be caught while suturing the chest wall. In such cases, a return to the operating room for surgical removal is often necessary. However, we present a case in which a fiberoptic bronchoscope and endoscopic forceps were used to visualize and cut suture which had been placed through a chest tube during thoracotomy closure.

### CASE PRESENTATION

The patient is a 25 year old female with a history of intravenous drug abuse who had previously been admitted for bilateral pneumonia and MRSA bacteremia. This was complicated by left empyema, native tricuspid valve infective endocarditis and subsequent multiple bilateral septic embolic to the lung. Due to her empyema, concerns for a trapped lung, and undrained infected complex pulmonary space, she was taken for right thoracotomy for a complete decortication. A 32 French chest tube was placed towards the apex of the thoracic cavity and a second tube was placed along the diaphragm thru separate stab incisions lower in the chest at the end of the procedure. The incision was then closed with heavy 0-suture to re-approximate the intercostal spaces and the muscle and fascial layers with 2-0 suture.

Post-operatively, she remained on mechanical ventilation for two days due to failed spontaneous breathing trials. However, she was extubated on post-operative day 3. The chest tubes remained to suction until post-operative day 5. On post-operative day 6, the anterior chest tube was pulled, however the posterior chest tube was unable to be removed. At this time, it was suspected that one of the thoracotomy closure sutures had been placed through the tube.

Hoping to avoid the need for re-operation, while the patient was still in the ICU, the patient was prepped and draped in a sterile fashion at the bedside. A flexible fiberoptic bronchoscope was prepped with chlorhexidine, the chest tube was disconnected from the dry seal canister and the scope was introduced through the lumen of the tube (Figure 1). A purple suture was visualized near the sentinel hole of the chest tube. Endoscopic forceps were utilized to repeated grasp and rip the suture (Figure 2). Both the chest tube and bronchoscope were removed from the thorax and an occlusive dressing was applied.

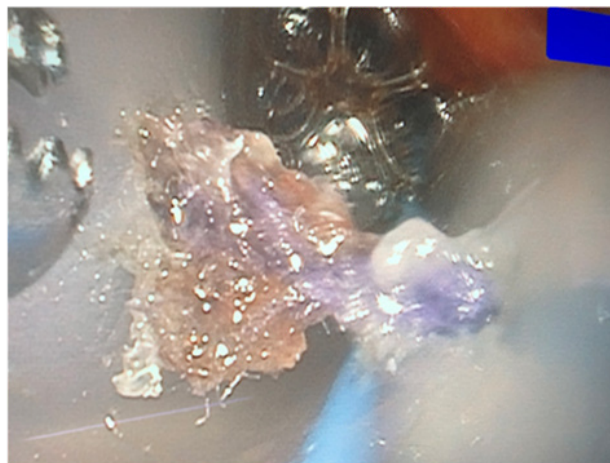## DISCUSSION

Chest tubes have been used since the early 1920s for the management and treatment of various thoracic pathologies. While chest tubes are the mainstay treatment for pneumothorax, they are also consistently used after thoracic procedures such as lobectomies, decortication and wedge resections. The severe pain experienced post-operatively from a thoracotomy contributes to perioperative morbidity and mortality<sup>[1-4,7]</sup>. Alar *et al* demonstrated a significant impact in the quality of life of patients who have undergone a thoracotomy<sup>[2]</sup>. They found that not only did patients experience bodily pain, but they also have significant impairment of social functioning, mental health and emotional problems. Numerous studies have been dedicated to perfecting techniques to decrease post-operative pain after thoracotomies. The muscle sparing technique has been shown to decrease narcotic requirement post-operatively and, overall, decrease pain<sup>[5,6]</sup>.

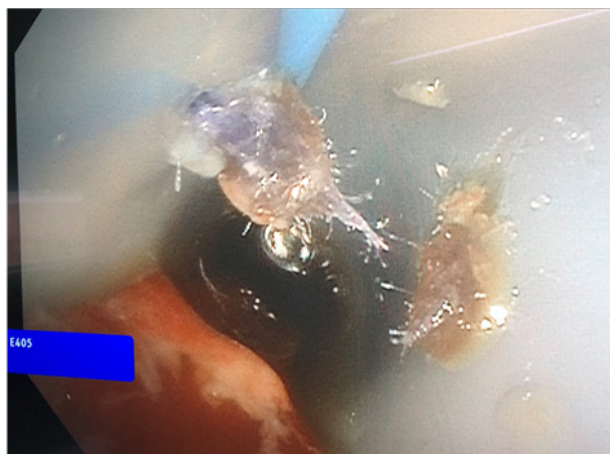
Typically, when a chest tube is caught by the suture that is closing the chest wall it would require an additional operation for a redo thoracotomy. This re-exposes the patient to the risk of anesthesia, re-operation, and increased pain. Fiberoptic bronchoscopy has mainly been used in respiratory care and has been an important tool in management of tracheostomies especially in patients who are obese and critically ill<sup>[7,8]</sup>. In this case, by utilizing a bronchoscope and endoscopic instruments to cut the suture, it has provided a minimally invasive technique that prevents reoperation and, for the patient, provides a less stressful, painless procedure. This technique should be considered whenever a chest tube cannot be easily removed as direct fiberoptic bronchoscopy via the tube might not only provide insight to the etiology, but also allow for definitive non-operative treatment.

## REFERENCES

1. Bottiger BA, Esper SA, Stafford-Smith M. Pain management strategies for thoracotomy and thoracic pain syndromes. *Semin Cardiothorac Vasc Anesth.* 2014; 18(1): 45-56. [PMID: 24336691]; [DOI: 10.1177/1089253213514484]
2. Alar T, Ceylan KC, Kaya SO, Sevinç S, Sigirli D, Özçelik C. How does the type of thoracotomy affect the patient quality of life? A short form-36 health survey study. *Surg Today.* 2014; 44(2): 264-270. [PMID: 23584276]; [DOI: 10.1007/s00595-013-0586-5]
3. García-Tirado J, Rieger-Reyes C. Suture Techniques of the Intercostal Space in Thoracotomy and Their Relationship With Post-Thoracotomy Pain: A Systematic Review. *Arch Bronconeumol (English Ed.)* 2012; 48(1): 22-28.; [DOI: 10.1016/j.arbr.2011.04.011]
4. Jiwnani S, Ranganathan P, Patil V, Agarwal V, Karimundackal G, Pramesh CS. Pain after posterolateral versus nerve-sparing thoracotomy: A randomized trial. *Journal of Thoracic and*



**Figure 1** Visualization of suture (purple) used to close rib space following thoracotomy.



**Figure 2** Suture cut using endoscopic forceps which then allowed for easy tube removal.

5. *Cardiovascular Surgery.* [PMID: 30195601]; [DOI: 10.1016/j.jtcvs.2018.07.033]
6. Uzzaman MM, Robb JD, Mhandu PCE, Khan H, Baig K, Chaubey S, Whitaker DC. A meta-analysis comparing muscle-sparing and posterolateral thoracotomy. *Ann Thorac Surg.* 2014; 97(3): 1093-1102. [PMID: 24209426]; [DOI: 10.1016/j.athoracsur.2013.08.014]
7. Akçali Y, Demir H, Tezcan B. The effect of standard posterolateral versus muscle-sparing thoracotomy on multiple parameters. *Ann Thorac Surg.* 2003; 76(4): 1050-1054. [DOI: 10.1016/S0003-4975(03)00565-4]
8. Kalso E, Perttunen K, Kaasinen S. Pain after thoracic surgery. *Acta Anaesthesiol Scand.* 1992; 36(1): 96-100. [PMID: 1539485]; [DOI: 10.1111/j.1399-6576.1992.tb03430.x]
9. Romero CM1, Cornejo RA, Ruiz MH, Gálvez LR, Llanos OP, Tobar EA, Larrondo JF, Castro JS. Fiberoptic bronchoscopy-assisted percutaneous tracheostomy is safe in obese critically ill patients: A prospective and comparative study. *J Crit Care.* 2009; 24(4): 494-500. [PMID: 19327297]; [DOI: 10.1016/j.jcrc.2008.06.001]
10. Saritas A, Saritas PU, Kumaz MM, Beyaz SG, Ergonenac T. The role of fiberoptic bronchoscopy monitoring during percutaneous dilational tracheostomy and its routine use into tracheotomy practice. *J Pakistan Med Assoc.* 2016; 66(1): 83-89.