

Acute Infective Portal Vein Thrombosis Secondary to Acute Sigmoid Diverticulitis

Antonio Cheesman, Anas Gremida, Mary Burton

Antonio Cheesman, Anas Gremida, Mary Burton, Internal Medicine Department, St Louis University School of Medicine, St Louis, MO, the United States

Mary Burton, Gastroenterology Department, St Louis University School of Medicine, St Louis, MO, the United States

Correspondence to: Antonio Cheesman, MD, Internal Medicine Department, St Louis University School of Medicine, 3635 Vista Avenue, Desloge Towers 14th Floor, St. Louis MO 63110-0250

Email: cheesmanar@slu.edu

Telephone: +1-305-842-0651

Received: February 20, 2015

Revised: March 24, 2015

Accepted: March 30, 2015

Published online: April 21, 2015

ABSTRACT

Infective thrombosis of the portal vein may complicate any infectious process of the abdominal portion of the gastrointestinal tract. The diagnosis requires a high index of suspicion, and the most common findings include fever, abdominal pain and abnormal liver function tests. Abdominal CT scan is the preferred diagnostic modality. Treatment should be initiated immediately, including empiric use of antibiotics and concomitant anticoagulation in view of the high mortality rate.

© 2015 ACT. All rights reserved.

Key words: Portal vein thrombosis, Pylephlebitis, Diverticulitis.

Cheesman A, Gremida A, Burton M. Acute Infective Portal Vein Thrombosis Secondary to Acute Sigmoid Diverticulitis. *Journal of Gastroenterology and Hepatology Research* 2015; 4(4): 1582-1584 Available from: URL: <http://www.ghrnet.org/index.php/joghr/article/view/1066>

INTRODUCTION

Infective thrombosis of the portal vein or pylephlebitis, is a rare condition that may complicate any infectious process of the abdominal portion of the gastrointestinal tract. The diagnosis can be challenging due to lack of specific clinical findings. A high index of suspicion in patients with intra-abdominal infections is crucial given the high mortality rate associated with this clinical entity. We present a case and review existing literature.

CASE REPORT

We present the case of a 52 year old male with past medical history significant for cholecystitis with laparoscopic cholecystectomy at age 32, and long-standing tobacco use (40 pack years), who was admitted with a five day history of fevers (up to 103 F), right upper quadrant abdominal pain, and jaundice. Physical exam was also notable for a positive Murphy's sign.

Initial laboratory analysis revealed leukocytosis (30,000 cells/ μ L), a predominantly cholestatic pattern with direct hyperbilirubinemia (5.8 mg/dL), elevated alkaline phosphatase (569 U/L), and mild AST (93 U/L) and ALT (85 U/L) elevations. Viral hepatitis panel was negative. Daily blood cultures were also negative. On imaging, magnetic resonance cholangiopancreatography (MRCP) revealed left portal vein thrombosis (PVT) and acute diverticulitis of the sigmoid colon with focal wall thickening and surrounding inflammation (Figures 1, 2). A liver biopsy showed acute hepatitis with focal canalicular cholestasis. Further extensive workup proved unrevealing, including: Malignancy screening (chest CT, PSA level, colonoscopy, protein electrophoresis, Jak2 V617F and BCR-ABL major/minor mutation analysis); autoimmune studies (ANA, C-ANCA, P-ANCA, IgG4, AMA); and Thrombophilic disorder studies (Anticardiolipin Abs, Lupus anticoagulant screen, AT III, Protein C/S activity, Factor V Leiden, Prothrombin gene mutation, B2-glycoprotein Abs, and MTHFR Mutation A1298C analysis).

The patient was diagnosed with infectious portal vein thrombosis in the context of acute sigmoid diverticulitis. He was treated with Piperacillin-Tazobactam for 7 days, transitioned to Ciprofloxacin and Metronidazole for another 3 weeks. In addition, he was started on a Heparin drip and transitioned to oral Warfarin to complete 6 months of treatment after discharge. The patient progressed well with rapid resolution of symptoms, correction of leukocytosis and hyperbilirubinemia.

DISCUSSION

The diagnosis of pylephlebitis is frequently delayed and requires a high index of suspicion in view of its non-specific clinical presentation and high mortality rate (25%)^[1-3]. The most common findings include fever, abdominal pain and abnormal liver function tests^[4,5]. It is important to note that up to 60% of patients may have no or minimal clinical features secondary to the primary cause at time of evaluation^[6]. Typical associated risk factors include diverticulitis (30%, mostly sigmoid), appendicitis (19%), inflammatory bowel disease (6%), pancreatitis (5%), infectious enteritis (4%), and recent abdominal surgeries^[3,7-9]. Although diverticulitis is the most common cause of pylephlebitis, pylephlebitis is a rare complication of diverticulitis (3%).

Abdominal CT scan is the preferred image modality for diagnosis and typically reveals acute PVT with intraluminal gas suggesting suppurative thrombophlebitis^[10]. The differential diagnosis for PVT

in non-cirrhotic patients is broad, and consideration for an underlying malignancy (adenocarcinomas, myeloproliferative disorders), autoimmune (antiphospholipid syndrome, inherited thrombophilia (factor V Leiden, prothrombin gene mutation, protein C/S deficiencies), or medication related (oral contraceptives, hormone replacement, tamoxifen) disorder should be given^[8]. However, no underlying etiology may be identified in up to 70% of cases^[4].

Blood cultures may be used to guide antibiotic therapy (positive in 23-88% of cases)^[11,2]. The most common associated organisms include *Bacteroides fragilis*, followed by *Escherichia coli*, *Viridans streptococci*, *Proteus mirabilis* and *Klebsiella pneumoniae*^[3,5,11]. Percutaneous catheter aspiration is rarely done, but may be helpful in case of negative blood cultures and lack of response to empiric antibiotics^[7,12]. Treatment should be started immediately with parenteral Piperacillin-Tazobactam, transitioned to an oral Quinolone and Metronidazole to complete a total of 4-6 weeks. Concomitant anticoagulation is subject to debate. In a recent study by Kanellopoulou *et al* patients treated with anticoagulation in addition to standard antibiotic therapy showed better outcome^[9]. Previous studies reported benefit limited only to patients with thrombosis extending beyond the portal vein^[13], or lack of outcome differences all together^[1]. Based on the most recent evidence, anticoagulation for 3-6 months should be considered to prevent extension of thrombosis and favor recanalization (reported in up to 92.6% of patients)^[8].

Treatment delay may result in various complications including thrombosis extension, septic emboli with hepatic abscess formation, bowel ischemia, and portal hypertension^[5,9,14]. Death typically results from sepsis, peritonitis, intestinal bleeding, or portal vein rupture^[3].

We report a case of infective thrombosis of the portal vein resulting from acute sigmoid diverticulitis successfully treated with empiric antibiotics in addition to anticoagulation, and hope to raise awareness of this rare entity often requiring multiple laboratory and imaging tests prior to diagnosis, resulting in potentially fatal delays in the early initiation of appropriate therapy.

ACKNOWLEDGEMENTS

Antonio Cheesman, MD: Case identification, Manuscript writing and edition. Anas Gremida, MD: Manuscript writing and edition. Mary Burton, MD: Attending physician in charge of case, Manuscript revision.

Informed Consent: Informed consent was obtained for case reporting and publication. All patient identifier data was concealed.

CONFLICT OF INTERESTS

There are no conflicts of interest with regard to the present study.

REFERENCES

- 1 Baril N, Wren S, Radin R, Ralls P, Stain S. The role of anticoagulation in pylephlebitis. *American journal of surgery* 1996; **172**(5): 449-452; discussion 52-3
- 2 Plemmons RM, Dooley DP, Longfield RN. Septic thrombophlebitis of the portal vein (pylephlebitis): diagnosis and management in the modern era. *Clinical infectious diseases: an official publication of the Infectious Diseases Society of America* 1995; **21**(5): 1114-1120
- 3 Falkowski AL, Cathomas G, Zerz A, Rasch H, Tarr PE. Pylephlebitis of a variant mesenteric vein complicating sigmoid diverticulitis. *Journal of radiology case reports* 2014; **8**(2): 37-45
- 4 Waxman BP, Cavanagh LL, Nayman J. Suppurative pylephlebitis

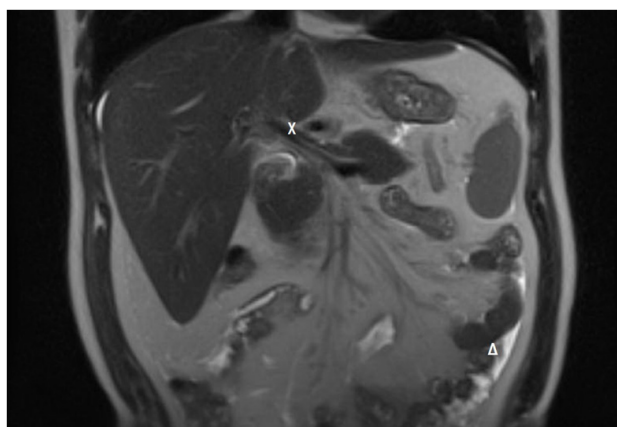


Figure 1 Abdominal MRI (Coronal T2 view): X Portal vein thrombosis, Δ Sigmoid inflammatory changes.

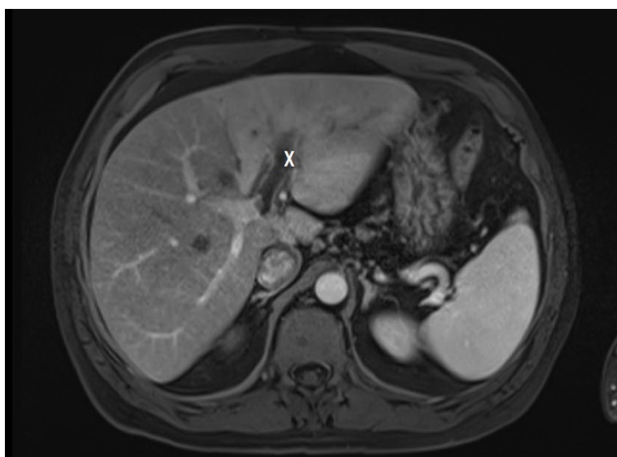

Figure 2 Abdominal MRI (Axial viba arterial view): X Portal vein thrombosis.

- and multiple hepatic abscesses with silent colonic diverticulitis. *The Medical journal of Australia* 1979; **2(7)**: 376-378
- 5 Saxena R, Adolph M, Ziegler JR, Murphy W, Rutecki GW. Pylephlebitis: a case report and review of outcome in the antibiotic era. *The American journal of gastroenterology*. 1996; **91(6)**: 1251-1253
 - 6 Chang YS, Min SY, Joo SH, Lee SH. Septic thrombophlebitis of the porto-mesenteric veins as a complication of acute appendicitis. *World journal of gastroenterology: WJG* 2008; **14(28)**: 4580-4582
 - 7 Vivas I, Bilbao JI, Martinez-Cuesta A, Benito A, Delgado C, Velazquez P. Combination of various percutaneous techniques in the treatment of pylephlebitis. *Journal of vascular and interventional radiology: JVIR*. 2000; **11(6)**: 777-780
 - 8 Condat B, Pessione F, Helene Denninger M, Hillaire S, Valla D. Recent portal or mesenteric venous thrombosis: increased recognition and frequent recanalization on anticoagulant therapy. *Hepatology* 2000; **32(3)**: 466-470
 - 9 Kanellopoulou T, Alexopoulou A, Theodossiades G, Koskinas J, Archimandritis AJ. Pylephlebitis: an overview of non-cirrhotic cases and factors related to outcome. *Scandinavian journal of infectious diseases* 2010; **42(11-12)**: 804-811
 10. Kashiura M, Tanabe T, Akashi A, Hamabe Y. Pylephlebitis: a severe complication of intra-abdominal infection. *Internal medicine* 2014; **53(24)**: 2829
 - 11 Kasper DL, Sahani D, Misdraji J. Case records of the Massachusetts General Hospital. Case 25-2005. A 40-year-old man with prolonged fever and weight loss. *The New England journal of medicine* 2005; **353(7)**: 713-722
 - 12 Pelsang RE, Johlin F, Dhadha R, Bogdanowicz M, Schweiger GD. Management of suppurative pylephlebitis by percutaneous drainage: placing a drainage catheter into the portal vein. *The American journal of gastroenterology* 2001; **96(11)**: 3192-3194
 - 13 Duffy FJ, Jr., Millan MT, Schoetz DJ, Jr., Larsen CR. Suppurative pylephlebitis and pylethrombosis: the role of anticoagulation. *The American surgeon* 1995; **61(12)**: 1041-1044
 - 14 Nishimori H, Ezoe E, Ura H, Imaizumi H, Meguro M, Furuhashi T, Katsuramaki T, Hata F, Yasoshima T, Hirata K, Asai Y. Septic thrombophlebitis of the portal and superior mesenteric veins as a complication of appendicitis: report of a case. *Surgery today* 2004; **34(2)**: 173-176

Peer reviewer: Luis Rodrigo, Professor, Gastroenterology Department, University Hospital Central of Asturias, c/ Celestino Villamil s. nº, 33.006. Oviedo. Spain.