

Endoscopic Management of Variceal Haemorrhage

Alessandra Dell'Era, Francesca Iannuzzi, Roberto de Franchis

Alessandra Dell'Era, Francesca Iannuzzi, Roberto de Franchis, Gastroenterology Unit, Luigi Sacco University Hospital, Via G. B. Grassi 74, Milan 20157, Italy

Alessandra Dell'Era, Roberto de Franchis, Department of Clinical and Biomedical Sciences, Luigi Sacco University Hospital, University of Milan, Via G. B. Grassi 74, Milan 20157, Italy

Correspondence to: Alessandra Dell'Era, Gastroenterology Unit, Luigi Sacco University Hospital, Via G. B. Grassi 74, Milan 20157, Italy

Email: albertotringali@hotmail.com

Telephone: +39-02-39043300

Received: December 2, 2014

Revised: January 15, 2015

Accepted: January 18, 2015

Published online: March 21, 2015

ABSTRACT

One of the most important complications of portal hypertension, in the setting of liver cirrhosis or of non-cirrhotic portal hypertension, is upper gastrointestinal bleeding from ruptured gastroesophageal varices and portal hypertensive gastropathy. The management of the acute variceal bleeding is a multidisciplinary process that includes the initial assessment of the patient, effective resuscitation, timely diagnosis, control of bleeding and prevention of early rebleeding and complications such as infection, hepatorenal syndrome, or hepatic encephalopathy. Antibiotic prophylaxis, conservative targets for blood transfusions and combination therapy with vasoactive drugs and endoscopic treatments are the first-line measures in the management of acute variceal bleeding; transjugular intrahepatic portosystemic shunts should be proposed early to high-risk patients or as a rescue therapy for those who fail first-line treatment.

© 2015 ACT. All rights reserved.

Key words: Esophageal varices; Gastric varices; Ectopic varices; Acute variceal bleeding; Endoscopic variceal ligation; Endoscopic sclerotherapy; Antibiotic prophylaxis; Vasoactive drugs; TIPS

Dell'Era A, Iannuzzi F, de Franchis R. Endoscopic Management of Variceal Haemorrhage. *Journal of Gastroenterology and Hepatol-*

ogy Research 2015; 4(3): 1507-1514 Available from: URL: <http://www.ghrnet.org/index.php/joghr/article/view/1121>

INTRODUCTION

Portal hypertension, as a complication of liver cirrhosis or in the setting of non-cirrhotic portal hypertension, leads to different complications ranging from the development of varices to upper gastrointestinal bleeding from ruptured gastroesophageal varices and portal hypertensive gastropathy, to ascites, hepatorenal syndrome and hepatic encephalopathy^[1]. Portal hypertension is defined as an increase in the portal venous pressure above the normal values of 1-5 mmHg. Nowadays we don't usually measure directly the portal pressure but estimate it using the hepatic venous pressure gradient (HVPG), measured as the difference between the wedged (portal vein) and the free hepatic venous pressures (inferior vena cava). The HVPG value of 10 mmHg is used to define clinically significant portal hypertension, the level of portal pressure above which complications can arise^[2-5].

The prevalence of varices in cirrhotic patients ranges from 30 to 60%, according to the presence of decompensation^[6] and prospective studies have shown that more than 90% of patients will develop esophageal varices during their lifetime (Figure 1). The expected incidence of newly developed varices is about 5% per year^[7,8]. Once varices develop their rate of progression in size is 5-30% per year according to the study population and follow-up endoscopic schedule^[8-12]. The main prognostic factors associated to progression of small to large varices are decompensated cirrhosis (Child B/C), alcoholic etiology of cirrhosis, HVPG and the presence of red wale markings on the esophageal varices at the time of baseline endoscopy^[9,11,13].

Acute variceal bleeding in patients with cirrhosis indicates decompensation and a high-risk of death^[6]. The annual rate of bleeding, in absence of treatment, is 10%-15%^[14,15]. The most important predictors are variceal size^[8,10,16], presence of red signs on varices^[17,18], and severity of liver dysfunction defined by the Child-Pugh classification^[15]. These risk indicators have been combined in the North Italian Endoscopy Club (NIEC) index, which allows the classification of patients into different groups with a predicted 1-year bleeding risk ranging between 6 and 60%. The risk of bleeding is

very low (1%-2%) in patients without varices at the first examination, and increases to 5% per year in those with small varices, and to 15% per year in those with medium or large varices at diagnosis. Another important determinant of variceal bleeding is the degree of portal pressure: variceal bleeding only occurs if the HVPG reaches a threshold value of 12 mmHg, if the HVPG is reduced below 12 mmHg or by more than 20% of the baseline levels the risk of bleeding is substantially reduced^[19].

In patients with cirrhosis, ruptured esophageal varices cause approximately 70% of all upper digestive bleeding^[20] and are the second most common cause of mortality for cirrhotic patients^[21]. Mortality from variceal bleeding has greatly decreased during the last decades to the current rates of 6-12%^[6,10,22-24]. Causes of bleeding related death (i.e. any death occurring within 6 weeks from hospital admission for variceal bleeding)^[25] are uncontrolled bleeding in 4-8% of cases^[26-28], rebleeding and infection, renal failure, hepatic encephalopathy (these are also prognostic indicators of morbidity and mortality after the first bleeding)^[29]. Other factors independently associated with a higher mortality are severe liver dysfunction, HVPG >20 mmHg and active bleeding at endoscopy^[30,31].

MANAGEMENT OF VARICEAL BLEEDING

The management of the acute variceal bleeding is a multidisciplinary process^[25] that includes the initial assessment of the patient, effective **resuscitation**, timely diagnosis, control of bleeding, and prevention of early rebleeding and complications such as infection, hepatorenal syndrome, or hepatic encephalopathy. **Blood volume restitution** should be performed to maintain hemodynamic stability; packed red blood cells should be transfused conservatively aiming at hemoglobin levels between 7-8 g/dL^[25,32] avoiding over transfusion which could be the cause of rebleeding^[33,34]. Transfusion policy, however, should also consider the presence of co-morbidities, age, hemodynamic status and ongoing bleeding. Definitive recommendations regarding **management of coagulopathy and thrombocytopenia** cannot be made on the basis of currently available data^[25]. **Antibiotic prophylaxis** should be instituted from admission. It should consist of oral quinolones for most patients considering intravenous ceftriazone in patients with advanced cirrhosis, in hospital settings with high prevalence of quinolone-resistant bacterial infections and in patients on previous quinolone prophylaxis^[25,35,36]. Vasoactive

drugs (terlipressin, somatostatin, octreotide, vapreotide) should be started as soon as possible, even before endoscopy^[37]. Vasoactive drugs used in combination with endoscopic therapy allow a better control of hemorrhage than drug therapy or endoscopy alone^[38]. No significant differences have been found in several studies between different vasoactive drugs in the control of the index bleeding and in the prevention of recurrence. Terlipressin is the only vasoactive drug that has a positive effect on survival^[14]. In clinical practice the choice of the vasoactive drug is based on its availability and on its cost. Vasoactive drugs therapy should be prolonged for 2-5 days according to control of bleeding and can be stopped after 24 hours free from bleeding. A post hoc analysis of a trial suggested that with higher dose of somatostatin (500 µg/h) control of bleeding and better survival can be achieved in significantly higher proportion of patients^[39], but this finding has never been confirmed in other trials.

Endotracheal intubation may be needed in selected cases^[37]. **Balloon tamponade** can also be used as a bridge therapy to obtain temporary hemostasis (maximum 24 hours)^[40]. Recently preliminary studies have shown that the placement of self-expanding metallic stents as an alternative to balloon tamponade for the control of refractory variceal hemorrhage may be beneficial^[41,42] but these findings must be confirmed in other trials before their use can be introduced in clinical practice.

Emergency EGD may be at the same time diagnostic and therapeutic. When it is performed early, 39-44% of patients present with active bleeding, 33-44% with signs of recent bleeding (clots or "white nipple" on varices)^[43] and 12-28% have no sign of active or recent hemorrhage^[28].

ESOPHAGEAL VARICEAL BLEEDING

Endoscopic treatment of EV may be performed by endoscopic sclerotherapy (ES) and endoscopic variceal ligation (EVL).

Endoscopic Sclerotherapy (ES)

ES, first described in 1939 by Crafford and Frenckner^[44] is currently performed using flexible catheters with a short needle tip (23 or 25 gauge). Different sclerosant agents (e.g. sodium morrhuate, podidocanol, ethanolamine, alcohol, and sodium tetradecyl sulphate) have been used in controlled trials^[45] and nowadays the most commonly used agents are ethanolamine oleate (5%) or polidocanol (1%-2%) in Europe, and sodium morrhuate (5%) in the United States^[46,47]. The injection of the sclerosant agent may be performed into the variceal lumen (intravariceal) or adjacent to it (paravariceal) inducing thrombosis of the vessel and inflammation of the surrounding tissues^[48,49] leading to fibrosis and resulting in variceal obliteration^[50]. Paravariceal injection forms a fibrotic layer around varices while intravariceal injection, directly induces variceal thrombosis. Injection of sclerosant should be first made immediately below the bleeding point (1-3 mL) and then in the remaining varices near the bleeding one (2-3 mL injections). The total amount of sclerosant per session is usually 10-15 mL. Both intravariceal and paravariceal injections have been associated with good outcomes^[51] and no differences have been found with different sclerosants^[52], the volume injected, or frequency of sessions^[53].

Compared to EVL, ES is easier to use since it does not require to withdraw and reinsert the endoscope.

Complications of ES are more frequent than those of EVL^[47,54-60]. The complications can be classified as local: esophageal ulcers, ulcer bleeding, and esophageal stricture; cardiovascular and respiratory: pleural effusion, acute respiratory distress syndrome, and pericarditis;

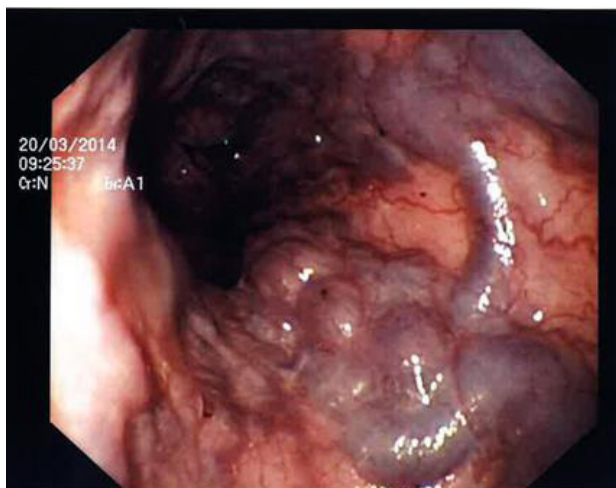


Figure 1 Large esophageal varices at EGD.

and systemic: fever, bacteremia, spontaneous bacterial peritonitis, distant embolism or abscess^[61]. Frequent minor complications that do not require treatment occur within the first 24-48 hours: retrosternal chest pain, low grade fever, dysphagia, asymptomatic pleural effusions, nonspecific chest radiographic changes^[48]. Esophageal ulcers occur in up to 90% of patients and may cause bleeding in 20% of patients^[59,62]. They should be prevented and treated with proton pump inhibitors; the efficacy of sucralfate in treating these ulcers and preventing rebleeding is not clear^[63]. Bacteremia may occur in up to 35% of patients and may be responsible for the development of abscesses and spontaneous bacterial peritonitis^[64,65]. Less frequent complications are esophageal stenoses (2-10% of cases) and esophageal perforation^[48]. Death for post-ES complications may occur in 2% of patients^[66].

In a Cochrane meta-analysis ES was not shown to be superior to the vasoactive drug therapy for the control of bleeding, rebleeding, and mortality^[67].

Endoscopic Variceal Ligation (EVL).

Endoscopic Variceal Ligation (EVL). The first reports of EVL appeared in 1988 by Stiegmann *et al*^[68]. While ES used chemical action to obliterate varices, EVL causes a mechanical strangulation with rubber bands that induces thrombosis with ischemic necrosis of the mucosa. EVL consists in placing rubber rings on esophageal varices after sucking them into a plastic cylinder attached to the tip of the endoscope^[69,70] (Figure 2). In the beginning single-shot ligators were used, requiring the use of an overtube with all the complications of its use; nowadays multiple-shot (4-10 bands) devices are commonly used and the procedure is simpler and faster^[46]. During an emergency EGD the bleeding varix is identified; the endoscope is then removed from the patient and the banding device is loaded. The endoscope is then reinserted into the esophagus up to the gastroesophageal junction to identify the varices. Then the tip of the endoscope is oriented toward the varix and a continuous suction is applied until the varix fills the cap. At this moment the band can be 'fired'^[70]. The bands should be placed on the varix at the point of bleeding or starting from the gastroesophageal junction in a helical fashion^[48] for 6-8 cm within the palisade and perforating zones^[61]. The rubber bands on the ligated varix detach in 1-10 days leaving shallow esophageal ulcers and smaller esophageal varices. The ulcers generated by EVL are bigger and shallower than those of ES and heal more rapidly^[61,71]. The scars that may be generated by EVL ulcers^[72], make subsequent redevelopment of varices more difficult. After band ligation patients should start with liquids at room temperature for the first 12 h and then take soft foods gradually. A recent trial has shown that proton pump inhibitor therapy is associated with smaller ulcers but the total number and the symptoms were not different^[73]. Varices are considered eradicated when they have either disappeared or cannot be sucked and banded by the ligator^[46]. Variceal eradication is obtained in about 90% of patients with up to 4 banding sessions^[46] but recurrence is not uncommon^[74].

A meta-analysis of 7 randomized controlled trials (RCTs) showed that there is a tendency toward benefit of EVL compared to ES in terms of control of bleeding, recurrent bleeding, side effects, need for fewer endoscopic treatments, and survival^[60]. Therefore, EVL has become the treatment of choice for variceal bleeding but ES can be used when EVL is technically difficult^[25,37].

Compared to ES, EVL has a higher frequency of recurrent varices^[75-77] but they can be treated with repeated EVL^[77].

Minor complications of EVL, that respond well to oral analgesia and antacids, include chest pain and transient dysphagia. Serious,

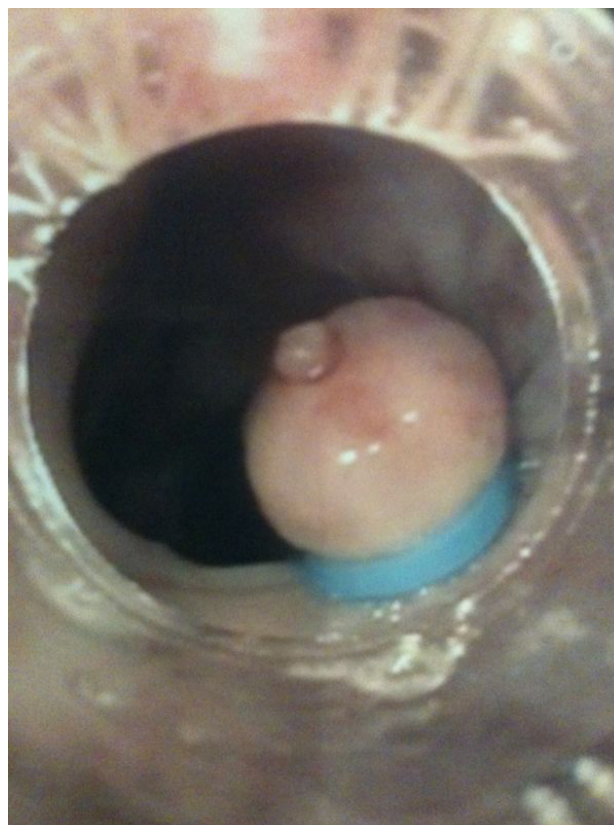

Figure 2 Esophageal varices band ligation of a varix with a white nipple.

but rare, complications include massive bleeding from untimely sloughing of bands, esophageal perforation (mostly for the use of overtube), esophageal strictures^[78] and bacteremia^[79] even if with a lower frequency than with ES^[80]. Finally, there are reports that EVL may cause worsening of and/or appearance of PHG^[81].

COMBINATION THERAPY

Vasoactive drugs and endoscopic therapy

Vasoactive drugs and endoscopic therapy. Combination of vasoactive drugs plus EVL/ES is the standard of care for variceal bleeding^[25,37]. In fact, a meta-analysis of 8 trials demonstrated that combined therapy (endoscopic plus vasoactive drugs) compared to endoscopic therapy alone (ES or EVL) improved control of bleeding and 5-day hemostasis without differences in severe side effects or mortality^[38].

EVL plus ES

EVL plus ES. Some studies have been performed on the combination of EVL and ES in order to achieve variceal eradication more quickly and thus reduce the likelihood of rebleeding^[39] and the incidence of recurrent varices^[82]. A meta-analysis of 7 RCTs by Singh *et al* showed that combination therapy had no advantage over EVL alone in the control of bleeding varices, prevention of rebleeding or reducing mortality^[83] with a significant increase in esophageal strictures.

FAILURES OF ENDOSCOPIC THERAPY

Current guidelines define treatment failure a failure to control acute variceal bleeding within 24 hours, or failure to prevent clinically significant rebleeding or death within 5 days of treatment^[25].

Approximately 10-15% of patients have a risk of treatment failure^[28,37]. Child-Pugh class, shock at admission, presence of portal vein thrombosis, active bleeding at endoscopy, and elevated HVPG >20mmHg have been shown to be predictive of treatment failure^[28,31]. A second attempt at endoscopic therapy can be tried, possibly changing the endoscopic technique^[25,84] but if this is unsuccessful a more aggressive approach by shunt therapy (TIPS or surgical) may be needed^[25,37] (Figure 3). Indeed, a recent trial showed a significant reduction in treatment failures and in mortality by early use of TIPS (within 72 hours after admission) in patients with active variceal bleeding and in Child-Pugh class B cirrhosis or class C disease^[85].

GASTRIC VARICEAL BLEEDING

Bleeding from gastric varices (GV) is less frequent but more severe than bleeding from EV^[20]. The treatment of GV is more difficult than that of EV because of the torrential blood outflow and their treatment modality depends on their location in the stomach and relation with EV. The Sarin classification is most widely used^[20,25]. Gastroesophageal varices type 1 (GOV1) are an extension of esophageal varices along the lesser curvature of the stomach and have the same behavior of EV as far as haemostasis and rebleeding is concerned and therefore should be treated as EV^[86]. Gastroesophageal varices type 2 (GOV2) located in the fundus of the stomach have been treated with different endoscopic techniques including ES, EVL, obliteration with glue and thrombin injection.

ES

ES was shown to be ineffective and with a high rate of complications^[87], possibly because the high volume of blood flowing through GV may wash away the sclerosant.

Gastric varices obliteration

Gastric varices obliteration consist in the injection of a tissue adhesive (polymers of cyanoacrylate) into a varix; the tissue adhesive upon contact with blood immediately polymerizes obliterating the varix. Complications of this procedure are rare but may be severe (with a mortality rate 0.5%): rebleeding due to extrusion of the glue cast (4.4%), sepsis (1.3%), pulmonary, cerebral, or splenic emboli

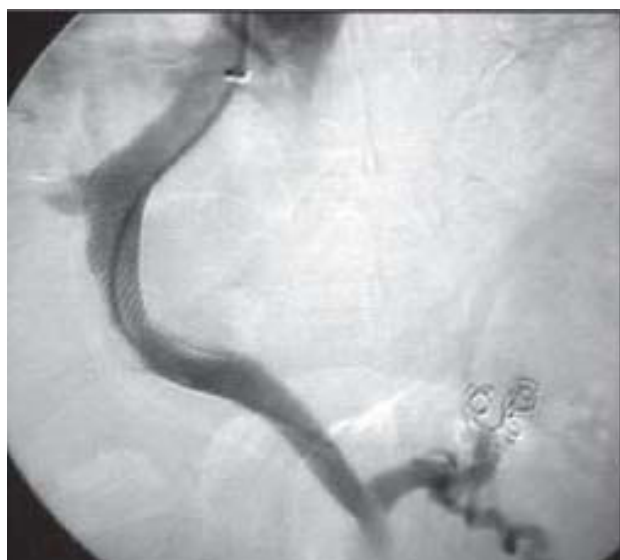


Figure 3 Portal venogram after Transjugular Intrahepatic Portosystemic shunt placement.

(0.7%), gastric ulcer formation (0.1%) and mesenteric hematoma associated with hemoperitoneum and bacterial peritonitis (0.1%)^[88]. Gastric varices obliteration is effective for acute fundal GV bleeding as it allows a better control of bleeding and reduces the rate of rebleeding^[87,89-93] in comparison with alternative treatments. In the United States cyanoacrylate use is not approved by the Food and Drug Administration.

EVL

EVL was shown to be similar to cyanoacrylate in controlling active bleeding but with higher rebleeding rate^[89]. Therefore, EVL is recommended as an alternative option, where tissue adhesives are not available^[37].

Intravariceal thrombin injection

Intravariceal thrombin injection was useful in achieving initial hemostasis in GV bleeding without significant side effects in preliminary studies^[87,94-96] but further evidence is needed before its use could be recommended in clinical practice.

In case of treatment failure of pharmacological and endoscopic therapy TIPS should be considered, sometimes associated with coil embolization of GV^[37].

The actual recommendation for the treatment of GV is to use tissue adhesive (e.g. N-butyl-cyanoacrylate) for acute bleeding from isolated gastric varices (IGV) and gastroesophageal varices type 2 (GOV2) that extend beyond the cardia; in acute bleeding from gastroesophageal varices type 1 (GOV1) EVL or tissue adhesive can be used^[25,37].

ECTOPIC VARICEAL BLEEDING

Portal hypertension may be responsible not only for the development and/or bleeding of esophageal and gastric varices but also of varices in other sites, e.g. in the duodenum, rectum and peristomal. Ectopic variceal bleeding is rare (less than 5% of portal-hypertensive related bleeding episodes) but mostly occurs from duodenal varices. No formal recommendation on their optimal treatment can be made because no clinical trials have been made. To date they are treated like EV or GV and the preferred treatment depends mainly on local expertise and location of the varices^[97-99].

ES

ES was shown to be effective in controlling bleeding from duodenal^[100,101], rectal^[102,103], and stomal varices^[104,105].

Ectopic varices obliteration

Ectopic varices obliteration. Cyanoacrylate glue injection has been successfully used to obliterate bleeding duodenal^[106,107], jejunal^[108], and rectal varices^[109].

EVL

EVL for bleeding duodenal varices is challenging because of limited visibility from the banding hood. It may be useful for temporary hemostasis but rebleeding is a problem^[110,111]. However, several cases of successful treatment of rectal varices using EVL have been reported^[112,113].

RECOMMENDATIONS

Blood transfusion should be aimed at hemoglobin levels between 7-8 g/dL.

Definitive recommendations regarding management of coagulopathy and thrombocytopenia cannot be made on the basis of currently available data.

Antibiotic prophylaxis should be instituted from admission, oral quinolones for most patients considering intravenous ceftriaxone in patients with advanced cirrhosis, in hospital settings with high prevalence of quinolone-resistant bacterial infections and in patients on previous quinolone prophylaxis.

Vasoactive drugs (terlipressin, somatostatin, octreotide, vapreotide) should be started as soon as possible, even before endoscopy, and should be maintained for 2-5 days according to control of bleeding and can be stopped after 24 hours free from bleeding.

Vasoactive drugs should be used in combination with endoscopic therapy.

Emergency EGD may be at the same time diagnostic and therapeutic.

Esophageal variceal bleeding may be treated by endoscopic variceal ligation or endoscopic sclerotherapy.

Gastric variceal bleeding: Gastroesophageal varices type 1 (GOV1) should be treated as esophageal varices; Gastroesophageal varices type 2 (GOV2) should be treated with different endoscopic techniques including ES, EVL, obliteration with glue and thrombin injection.

Ectopic variceal bleeding: No formal recommendation on their optimal treatment can be made because no clinical trials have been made. To date they are treated like EV or GV and the preferred treatment depends mainly on local expertise and location of the varices.

TIPS should be used as an early treatment for high-risk patients or as a rescue therapy for patients who do not respond to endoscopic and drug therapy.

CONFLICT OF INTERESTS

The authors declare that they have no conflict of interests.

REFERENCES

- Bosch J, García-Pagán JC. Complications of cirrhosis. I. Portal hypertension. *J Hepatol* 2000; **32**: 141-156
- Rigau J, Bosch J, Bordas JM, Navasa M, Mastai R, Kravetz D, Bruix J, Feu F, Rodés J. Endoscopic measurement of variceal pressure in cirrhosis: correlation with portal pressure and variceal hemorrhage. *Gastroenterology* 1989; **96**: 873-880.
- Garcia-Tsao G, Groszmann RJ, Fisher RL, Conn HO, Atterbury CE, Glickman M. Portal pressure, presence of gastroesophageal varices and variceal bleeding. *Hepatology* 1985; **5**: 419-424
- Ter Borg PC, Van Donselaar M, Van Buuren HR. Clinical events after TIPS: correlation with hemodynamic findings. *Gastroenterology* 1998; **115**: 1607
- Kumar A, Sharma P, Sarin SK. Hepatic venous pressure gradient measurement: time to learn! *Indian Journal of Gastroenterology* 2008; **27**: 74-80
- D'Amico G, Garcia-Tsao G, Pagliaro L. Natural history and prognostic indicators of survival in cirrhosis: a systematic review of 118 studies. *Journal of Hepatology* 2006; **44**(1): 217-231
- Christensen E, Fauerholdt L, Schlichting P, Juhl E, Poulsen H, Tygstrup N. Aspects of the natural history of gastrointestinal bleeding in cirrhosis and the effect of prednisone. *Gastroenterology* 1981; **81**: 944-952
- D'Amico G. Esophageal varices: from appearance to rupture; natural history and prognostic indicators. In Portal Hypertension in the 21st Century, R. J. Groszmann and J. Bosch, Eds., pp. 147-154, Kluwer Academic Publishers, Dordrecht, The Netherlands, 2004
- Merli M, Nicolini G, Angeloni S, Rinaldi V, De Santis A, Merkel C, Attili AF, Riggio O. Incidence and natural history of small esophageal varices in cirrhotic patients. *J Hepatol* 2003; **38**: 266-272
- Bosch J, Gonzales-Abrales J, Garcia-Pagan JC. Clinical manifestations and management of bleeding episodes in cirrhotics. *Textbook of Hepatology From Basic Science to Clinical Practice* 2007; **1**: 640-657
- Zoli M, Merkel C, Magalotti D, Gueli C, Grimaldi M, Gatta A, Bernardi M. Natural history of cirrhotic patients with small esophageal varices: a prospective study. *Am J Gastroenterol* 2000; **95**: 503-508
- Merkel C, Marin R, Angeli P, Zanella P, Felder M, Bernardinello E, Cavallarin G, Bolognesi M, Donada C, Bellini B, Torboli P, Gatta A, Gruppo Triveneto per l'Iperensione Portale. A placebo-controlled clinical trial of nadolol in the prophylaxis of growth of small esophageal varices in cirrhosis. *Gastroenterology* 2004; **127**: 476-484
- Vorobioff J, Groszmann RJ, Picabea E, Gamen M, Villavicencio R, Bordato J, Morel I, Audano M, Tanno H, Lerner E, Passamonti M. Prognostic value of hepatic venous pressure gradient measurements in alcoholic cirrhosis: a 10-year prospective study. *Gastroenterology* 1996; **111**: 701-709
- D'Amico G, Pagliaro L, Bosch J. Pharmacological treatment of portal hypertension: an evidence-based approach. *Semin Liver Dis* 1999; **19**: 475-505
- North Italian Endoscopic Club for the Study and Treatment of Esophageal Varices. Prediction of the first variceal hemorrhage in patients with cirrhosis of the liver and esophageal varices. A prospective multicenter study. *N Engl J Med* 1988; **319**(15): 983-989
- Merkel C, Zoli M, Siringo S, van Buuren H, Magalotti D, Angeli P, Sacerdoti D, Bolondi L, Gatta A. Prognostic indicators of risk for first variceal bleeding in cirrhosis: a multicenter study in 711 patients to validate and improve the North Italian Endoscopic Club (NIEC) index. *Am J Gastroenterol* 2000; **95**: 2915-2920
- Groszmann RJ, Bosch J, Grace ND, Conn HO, Garcia-Tsao G, Navasa M, Alberts J, Rodes J, Fischer R, Bermann M. Hemodynamic events in a prospective randomized trial of propranolol versus placebo in the prevention of a first variceal hemorrhage. *Gastroenterology* 1990; **99**: 1401-1407
- Polio J, Groszmann RJ, Reuben A, Sterzel RB, Better OS. Portal hypertension ameliorates arterial hypertension in spontaneously hypertensive rats. *J Hepatol* 1989; **8**: 294-301
- Ruiz-del-Arbol L, Urman J, Fernández J, González M, Navasa M, Monescillo A, Albillos A, Jiménez W, Arroyo V. Systemic, renal, and hepatic hemodynamic derangement in cirrhotic patients with spontaneous bacterial peritonitis. *Hepatology* 2003; **38**: 1210-1218
- Sarin SK, Lahoti D, Saxena SP, Murthy NS, Makwana UK. Prevalence, classification and natural history of gastric varices: a long-term follow-up study in 568 portal hypertension patients. *Hepatology* 1992; **16**: 1343-1349
- Calès P, Pascal JP. Natural history of esophageal varices in cirrhosis (from origin to rupture). *Gastroenterol Clin Biol* 1988; **12**: 245-254
- Carbonell N, Pauwels A, Serfaty L, Serfaty L, Fourdan O, Lévy VG, Poupon R. Improved survival after variceal bleeding in patients with cirrhosis over the past two decades. *Hepatology* 2004; **40**: 652-659
- Garcia-Tsao G, Bosch J. Management of varices and variceal hemorrhage in cirrhosis. *The New England Journal of Medicine* 2010; **362**(9): 823-832

- 24 El-Serag HB, Everhart JE. Improved survival after variceal hemorrhage over an 11-year period in the Department of Veterans Affairs. *Am J Gastroenterol* 2000; **95**: 3566-3573
- 25 de Franchis R. Revising consensus in portal hypertension: report of the Baveno V consensus workshop on methodology of diagnosis and therapy in portal hypertension. *J Hepatol* 2010; **53**: 762-768
- 26 de Franchis R, Dell'Era A, Fazzini L, Zatelli S, Savojarado V, Primignani M. Evaluation and follow-up of patients with portal hypertension and oesophageal varices: how and when. *Dig Liver Dis* 2001; **33**: 643-646
- 27 D'Amico G, Luca A. Natural history. Clinical-haemodynamic correlations. Prediction of the risk of bleeding. *Baillieres Clin Gastroenterol* 1997; **11**: 243-256
- 28 D'Amico G, De Franchis R. Upper digestive bleeding in cirrhosis. Post-therapeutic outcome and prognostic indicators. *Hepatology* 2003; **38**: 599-612
- 29 del Olmo JA, Peña A, Serra MA, Wassel AH, Benages A, Rodrigo JM. Predictors of morbidity and mortality after the first episode of upper gastrointestinal bleeding in liver cirrhosis. *J Hepatol* 2000; **32**: 19-24
- 30 Ben-Ari Z, Cardin F, McCormick AP, Wannamethee G, Burroughs AK. A predictive model for failure to control bleeding during acute variceal haemorrhage. *J Hepatol* 1999; **31**: 443-450
- 31 Moitinho E, Escorsell A, Bandi JC, Salmerón JM, García-Pagán JC, Rodés J, Bosch J. Prognostic value of early measurements of portal pressure in acute variceal bleeding. *Gastroenterology* 1999; **117**: 626-631
- 32 Villanueva C, Colomo A, Bosch A, Concepción M, Hernandez-Gea V, Aracil C, Graupera I, Poca M, Alvarez-Urturi C, Gordillo J, Guarner-Argente C, Santaló M, Muñoz E, Guarner C. Transfusion strategies for acute upper gastrointestinal bleeding. *N Engl J Med* 2013 Jan 3; **368**(1): 11-21
- 33 Kravetz D, Sikuler E, Groszmann RJ. Splanchnic and systemic hemodynamics in portal hypertensive rats during hemorrhage and blood volume restitution. *Gastroenterology* 1986; **90**: 1232-1240
- 34 Castañeda B, Morales J, Lionetti R, Moitinho E, Andreu V, Pérez-Del-Pulgar S, Pizcueta P, Rodés J, Bosch J. Effects of blood volume restitution following a portal hypertensive-related bleeding in anesthetized cirrhotic rats. *Hepatology* 2001; **33**: 821-825
- 35 Bernard B, Grangé JD, Khac EN, Amiot X, Opolon P, Poynard T. Antibiotic prophylaxis for the prevention of bacterial infections in cirrhotic patients with gastrointestinal bleeding: a meta-analysis. *Hepatology* 1999; **29**: 1655-166
- 36 Fernández J, Ruiz del Arbol L, Gómez C, Durandez R, Seradilla R, Guarner C, Planas R, Arroyo V, Navasa M. Norfloxacin vs ceftriaxone in the prophylaxis of infections in patients with advanced cirrhosis and hemorrhage. *Gastroenterology* 2006; **131**: 1049-1056; quiz 1285
- 37 Garcia-Tsao G, Sanyal AJ, Grace ND, Carey WD; Practice Guidelines Committee of American Association for Study of Liver Diseases; Practice Parameters Committee of American College of Gastroenterology. Prevention and management of gastroesophageal varices and variceal hemorrhage in cirrhosis. *Am J Gastroenterol* 2007; **102**(12): 922-938
- 38 Bañares R, Albillos A, Rincón D, Alonso S, González M, Ruiz-del-Arbol L, Salcedo M, Molinero LM. Endoscopic treatment versus endoscopic plus pharmacologic treatment for acute variceal bleeding: a meta-analysis. *Hepatology* 2002; **35**: 609-615
- 39 Cotton P. Combination therapies may speed healing, reduce rebleeding of esophageal varices. *JAMA* 1991; **266**(2): 187-188
- 40 de Franchis R. Updating consensus in portal hypertension: report of the Baveno IV consensus workshop on methodology of diagnosis and therapy of portal hypertension. *J Hepatol* 2005; **43**: 167-176
- 41 Hubmann R, Bodlaj G, Czompo M, Benkö L, Pichler P, Al-Kathib S, Kiblböck P, Shamyieh A, Biesenbach G. The use of self-expanding metal stents to treat acute esophageal variceal bleeding. *Endoscopy* 2006; **38**(9): 896-901
- 42 Wright G, Lewis H, Hogan B, A. Burroughs, D. Patch, J. O'Beirne. A self-expanding metal stent for complicated variceal hemorrhage: experience at a single center. *Gastrointest Endosc* 2010; **71**(1): 71-78
- 43 de Franchis R, Pascal JP, Ancona E, Burroughs AK, Henderson M, Fleig W, Groszmann R, Bosch J, Sauerbruch T, Soederlund C. Definitions, methodology and therapeutic strategies in portal hypertension. A Consensus Development Workshop, Baveno, Lake Maggiore, Italy, April 5 and 6, 1990. *Journal of Hepatology* 1992; **15**(1-2): 256-261
- 44 Crafford C, Frenckner P. New surgical treatment of varicose veins of the esophagus. *Acta Oto-Laryngologica* 1939; **27**: 422-429
- 45 Helmy A, Hayes PC. Review article: current endoscopic therapeutic options in the management of variceal bleeding. *Aliment Pharmacol Ther* 2001; **15**: 575-594
- 46 Villanueva C, Colomo A, Aracil C, Guarner C. Current endoscopic therapy of variceal bleeding. *Best Pract Res Clin Gastroenterol* 2008; **22**: 261-278
- 47 Park WG, Yeh RW, Triadafilopoulos G. Injection therapies for variceal bleeding disorders of the GI tract. *Gastrointest Endosc* 2008; **67**: 313-323
- 48 de Franchis R, Primignani M. Endoscopic treatments for portal hypertension. *Semin Liver Dis* 1999; **19**: 439-455
- 49 Westaby D. Emergency and elective endoscopic therapy for variceal haemorrhage. *Baillieres Clin Gastroenterol* 1992; **6**: 465-480
- 50 Pushpanathan C, Idikio H. Pathological findings in the esophagus after endoscopic sclerotherapy for variceal bleeding. *Am J Gastroenterol*. 1986 Jan; **81**(1): 9-13
- 51 Sarin SK, Nanda R, Sachdev G. Intravariceal versus paravariceal sclerotherapy: a prospective, controlled, randomised trial. *Gut* 1987; **28**(6): 657-662
- 52 Bhargava DK, Singh B, Dogra R, Dasarathy S, Sharma MP. Prospective randomized comparison of sodium tetradecyl sulfate and polidocanol as variceal sclerosing agents. *Am J Gastroenterol* 1992; **87**(2): 182-186
- 53 Akriviadis E, Korula J, Gupta S, Ko Y, Yamada S. Frequent endoscopic variceal sclerotherapy increases risk of complications. Prospective randomized controlled study of two treatment schedules. *Dig Dis Sci* 1989; **34**(7): 1068-1074
- 54 Sanowski RA, Waring JP. Endoscopic techniques and complications in variceal sclerotherapy. *J Clin Gastroenterol* 1987; **9**: 504-513
- 55 Schuman BM, Beckman JW, Tedesco FJ, Griffin JW Jr, Assad RT. Complications of endoscopic injection sclerotherapy: a review. *Am J Gastroenterol* 1987; **82**: 823-830
- 56 Cohen LB, Korsten MA, Scherl EJ, Velez ME, Fisse RD, Arons EJ. Bacteremia after endoscopic injection sclerosis. *Gastrointest Endosc* 1983; **29**: 198-200
- 57 Sarles HE, Sanowski RA, Talbert G. Course and complications of endoscopic variceal sclerotherapy: a prospective study of 50 patients. *Am J Gastroenterol* 1985; **80**: 595-599
- 58 Haynes WC, Sanowski RA, Foutch PG, Bellapravalu S. Esophageal strictures following endoscopic variceal sclerotherapy: clinical course and response to dilation therapy. *Gastrointest Endosc* 1986; **32**: 202-205
- 59 Baillie J, Yudelman P. Complications of endoscopic sclerotherapy of esophageal varices. *Endoscopy* 1992; **24**(4): 284-291

- 60 Laine L, Cook D. Endoscopic ligation compared with sclerotherapy for treatment of esophageal variceal bleeding. A meta-analysis. *Annals of Internal Medicine* 1995; **123**(4): 280-287
- 61 Lo GH. The role of endoscopy in secondary prophylaxis of esophageal varices. *Clin Liver Dis* 2010; **14**: 307-323
- 62 Lee JG, Lieberman DA. Complications related to endoscopic hemostasis techniques. *Gastrointest Endosc Clin N Am* 1996; **6**: 305-321
- 63 Burroughs AK, McCormick PA. Prevention of variceal rebleeding. *Gastroenterol Clin North Am* 1992; **21**: 119-147
- 64 Selby WS, Norton ID, Pokorny CS, Benn RA. Bacteremia and bacterascites after endoscopic sclerotherapy for bleeding esophageal varices and prevention by intravenous cefotaxime: a randomized trial. *Gastrointest Endosc* 1994; **40**: 680-684
- 65 Rolando N, Gimson A, Philpott-Howard J, Sahathevan M, Casewell M, Fagan E, Westaby D, Williams R. Infectious sequelae after endoscopic sclerotherapy of oesophageal varices: role of antibiotic prophylaxis. *J Hepatol* 1993; **18**: 290-294
- 66 Schuman BM, Beckman JW, Tedesco FJ, Griffin JW Jr, Assad RT. Complications of endoscopic injection sclerotherapy: a review. *Am J Gastroenterol* 1987; **82**: 823-830
- 67 D'Amico G, Pagliaro L, Pietrosi G, Tarantino I. Emergency sclerotherapy versus vasoactive drugs for bleeding oesophageal varices in cirrhotic patients. *Cochrane Database of Systematic Reviews* 2010; **3**: CD002233
- 68 Stiegmann GV, Goff JS, Sun JH, Davis D, Bozdech J. Endoscopic variceal ligation: an alternative to sclerotherapy. *Gastrointest Endosc* 1989; **35**(5): 431-434
- 69 Stiegmann GV, Goff JS, Michaletz-Onody PA, Korula J, Lieberman D, Saeed ZA, Reveille RM, Sun JH, Lowenstein SR. Endoscopic sclerotherapy as compared with endoscopic ligation for bleeding esophageal varices. *N Engl J Med* 1992; **326**: 1527-1532
- 70 Cárdenas A. Management of acute variceal bleeding: emphasis on endoscopic therapy. *Clin Liver Dis* 2010; **14**: 251-262
- 71 Young MF, Sanowski RA, Rasche R. Comparison and characterization of ulcerations induced by endoscopic ligation of esophageal varices versus endoscopic sclerotherapy. *Gastrointest Endosc* 1993; **39**: 119-122
- 72 Polski JM, Brunt EM, Saeed ZA. Chronology of histological changes after band ligation of esophageal varices in humans. *Endoscopy* 2001; **33**(5): 443-447
- 73 Shaheen NJ, Stuart E, Schmitz SM, Mitchell KL, Fried MW, Zacks S, Russo MW, Galanko J, Shrestha R. Pantoprazole reduces the size of postbanding ulcers after variceal band ligation: a randomized, controlled trial. *Hepatology* 2005; **41**: 588-594
- 74 Bosch J, García-Pagán JC. Prevention of variceal rebleeding. *Lancet* 2003; **361**: 952-954
- 75 Hou MC, Lin HC, Kuo BI, Chen CH, Lee FY, Lee SD. Comparison of endoscopic variceal injection sclerotherapy and ligation for the treatment of esophageal variceal hemorrhage: a prospective randomized trial. *Hepatology* 1995; **21**: 1517-1522
- 76 Sarin SK, Govil A, Jain AK, Guptan RC, Issar SK, Jain M, Murthy NS. Prospective randomized trial of endoscopic sclerotherapy versus variceal band ligation for esophageal varices: influence on gastropathy, gastric varices and variceal recurrence. *J Hepatol* 1997; **26**: 826-832
- 77 Hou MC, Lin HC, Lee FY, Chang FY, Lee SD. Recurrence of esophageal varices following endoscopic treatment and its impact on rebleeding: comparison of sclerotherapy and ligation. *J Hepatol* 2000; **32**: 202-208
- 78 Garcia-Pagan JC, Bosch J. Endoscopic band ligation in the treatment of portal hypertension. *Nature Clinical Practice Gastroenterology & Hepatology* 2005; **2**: 526-535
- 79 Bolognesi M, Balducci G, Garcia-Tsao G, Gatta A, Gines P, Merli M, Rodes J, Stiegmann GV. Complications in the medical treatment of portal hypertension. Proceedings of the third Baveno international consensus workshop on definitions, methodology and therapeutic strategies. In: de Franchis R, ed. Portal hypertension III. Oxford (UK): *Blackwell Science*; 2001: 180-201
- 80 Lo GH, Lai KH, Shen MT, Chang CF. A comparison of the incidence of transient bacteremia and infectious sequelae after sclerotherapy and rubber band ligation of bleeding esophageal varices. *Gastrointest Endosc* 1994; **40**: 675-679
- 81 Pereira-Lima JC, Zanette M, Lopes CV, de Mattos AA. The influence of endoscopic variceal ligation on the portal pressure gradient in cirrhotics. *Hepato-Gastroenterol* 2003; **50**(49): 102-106
- 82 de la Pena J, Rivero M, Sanchez E, Fábrega E, Crespo J, Pons-Romero F. Variceal ligation compared with endoscopic sclerotherapy for variceal hemorrhage: prospective randomized trial. *Gastrointest Endosc* 1999; **49**(4): 417-423
- 83 Singh P, Pooran N, Indaram A, Bank S. Combined ligation and sclerotherapy Versus ligation alone for secondary prophylaxis of esophageal variceal bleeding: a meta-analysis. *Am J Gastroenterol* 2000; **97**(3): 623-629
- 84 Saeed ZA, Michaletz PA, Winchester CB, Woods KL, Dixon WB, Hieser MC, Gentry KR, Ramirez FC. Endoscopic variceal ligation in patients who have failed endoscopic sclerotherapy. *Gastrointest Endosc* 1990; **36**(6): 572-574
- 85 Garcia-Pagan JC, Caca K, Bureau C, Laleman W, Appenrodt B, Luca A, Abralde JG, Nevens F, Vinel JP, Mössner J, Bosch J; Early TIPS (Transjugular Intrahepatic Portosystemic Shunt) Cooperative Study Group. Early use of TIPS in patients with cirrhosis and variceal bleeding. *NEJM* 2010; **362**: 2370-2379
- 86 Ryan BM, Stockbrugger RW, Ryan JM. A pathophysiologic, gastroenterologic, and radiologic approach to the management of gastric varices. *Gastroenterology* 2004; **126**(4): 1175-1189
- 87 Sarin SK, Mishra SR. Endoscopic therapy for gastric varices. *Clin Liver Dis* 2010; **14**(2): 263-279
- 88 Cheng LF, Wang ZQ, Li CZ, Lin W, Yeo AE, Jin B. Low incidence of complications from endoscopic gastric variceal obturation with butyl cyanoacrylate. *Clin Gastroenterol Hepatol* 2010; **8**(9): 760-766
- 89 Tan PC, Hou MC, Lin HC, Liu TT, Lee FY, Chang FY, Lee SD. A randomized trial of endoscopic treatment of acute gastric variceal hemorrhage: N-butyl-2-cyanoacrylate injection versus band ligation. *Hepatology* 2006; **43**(4): 690-697
- 90 Lo GH, Lai KH, Cheng JS, Chen MH, Chiang HT. A prospective, randomized trial of butyl cyanoacrylate injection versus band ligation in the management of bleeding gastric varices. *Hepatology* 2001; **33**(5): 1060-1064
- 91 D'Imperio N, Piemontese A, Baroncini D, Billi P, Borioni D, Dal Monte PP, Borrello P. Evaluation of undiluted N-butyl-2-cyanoacrylate in the endoscopic treatment of upper gastrointestinal tract varices. *Endoscopy* 1996; **28**(2): 239-243
- 92 Huang YH, Yeh HZ, Chen GH, Chang CS, Wu CY, Poon SK, Lien HC, Yang SS. Endoscopic treatment of bleeding gastric varices by N-butyl-2-cyanoacrylate (Histoacryl) injection: long-term efficacy and safety. *Gastrointest Endosc* 2000; **52**(2): 160-167
- 93 Sarin SK, Jain AK, Jain M, Gupta R. A randomized controlled trial of cyanoacrylate versus alcohol injection in patients with isolated fundic varices. *Am J Gastroenterol* 2002; **97**(4): 1010-1015
- 94 Ramesh J, Limdi JK, Sharma V, Makin AJ. The use of thrombin injections in the management of bleeding gastric

- varices: a single-center experience. *Gastrointest Endosc* 2008; **68(5)**: 877-882
- 95 Przemioslo RT, McNair A, Williams R. Thrombin is effective in arresting bleeding from gastric variceal hemorrhage. *Dig Dis Sci* 1999; **44(4)**: 778-781
- 96 Datta D, Vlavianos P, Alisa A, Westaby D. Use of fibrin glue (beriplast) in the management of bleeding gastric varices. *Endoscopy* 2003; **35(8)**: 675-678
- 97 Machida T, Sato K, Kojima A, Takezawa J, Sohara N, Kakizaki S, Takagi H, Mori M. Ruptured duodenal varices after endoscopic ligation of esophageal varices: an autopsy case. *Gastrointest Endosc* 2006; **63(2)**: 352-354
- 98 Lebrech D, Benhamou JP. Ectopic varices in portal hypertension. *Clin Gastroenterol* 1985; **14(1)**: 105-121
- 99 Cutler CS, Rex DK, Lehman GA. Enteroscopic identification of ectopic small bowel varices. *Gastrointest Endosc* 1995; **41(6)**: 605-608
- 100 Barbish AW, Ehrinpreis MN. Successful endoscopic injection sclerotherapy of a bleeding duodenal varix. *Am J Gastroenterol* 1993; **88(1)**: 90-92
- 101 Gertsch PH, Blumgart LH. Cure of a bleeding duodenal varix by sclerotherapy. *Br J Surg* 1988; **75(7)**: 717
- 102 Wang M, Desigan G, Dunn D. Endoscopic sclerotherapy for bleeding rectal varices: a case report. *Am J Gastroenterol* 1985; **80(10)**: 779-780
- 103 Sato T, Yamazaki K, Toyota J, Karino Y, Ohmura T, Suga T. The value of the endoscopic therapies in the treatment of rectal varices: a retrospective comparison between injection sclerotherapy and band ligation. *Hepatol Res* 2006; **34(4)**: 250-255
- 104 Spier BJ, Fayyad AA, Lucey MR, Johnson EA, Wojtowycz M, Rikkers L, Harms BA, Reichelderfer M. Bleeding stomal varices: case series and systematic review of the literature. *Clin Gastroenterol Hepatol* 2008; **6(3)**:346-352
- 105 Wolfsen HC, Kozarek RA, Bredfeldt JE, Fenster LF, Brubacher LL. The role of endoscopic injection sclerotherapy in the management of bleeding peristomal varices. *Gastrointest Endosc* 1990; **36(5)**: 472-474
- 106 Liu Y, Yang J, Wang J, Chai G, Sun G, Wang Z, Yang Y. Clinical characteristics and endoscopic treatment with cyanoacrylate injection in patients with duodenal varices. *Scand J Gastroenterol* 2009; **44(8)**: 1012-1016
- 107 Benedetti G, Sablich R, Lacchin T, Masiero A. Endoscopic treatment of bleeding duodenal varices by bucrylate injection. *Endoscopy* 1993; **25(6)**: 432-433
- 108 Hekmat H, Al-Toma A, Mallant MP, Mulder CJ, Jacobs MA. Endoscopic N-butyl-2-cyanoacrylate (Histoacryl) obliteration of jejunal varices by using the double balloon enteroscope. *Gastrointest Endosc* 2007; **65(2)**: 350-352
- 109 Ryu SH, Moon JS, Kim I, Kim YS, Lee JH. Endoscopic injection sclerotherapy with N-butyl-2-cyanoacrylate in a patient with massive rectal variceal bleeding: a case report. *Gastrointest Endosc* 2005; **62(4)**: 632-635
- 110 Shiraiishi M, Hiroyasu S, Higa T, Oshiro S, Muto Y. Successful management of ruptured duodenal varices by means of endoscopic variceal ligation: report of a case. *Gastrointest Endosc* 1999; **49(2)**: 255-257
- 111 Yoshida Y, Imai Y, Nishikawa M, Nakatukasa M, Kurokawa M, Shibata K, Shimomukai H, Shimano T, Tokunaga K, Yonezawa T. Successful endoscopic injection sclerotherapy with N-butyl-2-cyanoacrylate following the recurrence of bleeding soon after endoscopic ligation for ruptured duodenal varices. *Am J Gastroenterol* 1997; **92(7)**:1227-1229
- 112 Levine J, Tahiri A, Banerjee B. Endoscopic ligation of bleeding rectal varices. *Gastrointest Endosc* 1993; **39(2)**: 188-190
- 113 Firoozi B, Gamagaris Z, Weinshel EH, Bini EJ. Case report: endoscopic band ligation of bleeding rectal varices. *Dig Dis Sci* 2002; **47(7)**: 1502-1505

Peer reviewers: Li Yuyuan, Professor, Department of Gastroenterology and Hepatology, Guangzhou First Municipal People's Hospital, 1 Panfu Road, Guangzhou, China; Hamdy Sliem, Professor of internal medicine, faculty of medicine, Suez canal university, Ismailia, Egypt; Nasser Hamed Mousa, Associate Professor, Tropical Medicine and Hepatology, Mansoura University, Mansoura City, 35516/20, Egypt.