

Gastrointestinal Foreign Bodies: Clinical Aspects and Endoscopic Management

M Bini

M Bini, Endoscopic Unit, Ospedale Niguarda, Milan, Italy
Correspondence to: M Bini, Endoscopic Unit, Ospedale Niguarda, Milan, Italy
Email: marta.bini@ospedaleniguarda.it
Telephone: +1-39-0264442770 Fax :+39-0264442911
Received: December 2, 2014 Revised: February 19, 2015
Accepted: February 20, 2015
Published online: March 21, 2015

ABSTRACT

Foreign body ingestion is one of the commonest indication for emergency endoscopy. It is usually accidental. More than 85-90% of ingested FB will pass spontaneously. Symptoms depends on several factors and in a percentage as high as 50% can be asymptomatic. Hematemesis, peritonitis or intoxication symptoms are less frequent but alarming symptoms. History is the first step of the diagnostic process. The diagnosis should repose on one or more diagnostic procedures. FB endoscopic retrieval needs a well experienced endoscopist, particularly when it comes to paediatric patients. Endoscopic FB retrieval should be performed with anaesthesiologic assistance in order to provide adequate sedation or general anaesthesia; airway protection must always be guaranteed. Many FB retrieval devices are available and the choice should be done on the basis of FB shape and dimensions as well as on the operator expertise. The "pre-endoscopy" test of the device can be useful also in avoiding the choice of devices that might be "trapped or stuck" to the grasped object causing the impossibility to extract the endoscope. Use of wide operative channel endoscope is advisable for it will allow us to choose any of the available devices since specific FB retrieval devices for pediatric or neonatal scopes with a 2 mm operative channel are not always available. If necessary for an expert endoscopist, under general anaesthesia and with adequate airway protection, it is possible to use a standard endoscope even in children under 12 month of age. Pointed objects must be retrieved with the sharp or pointed end distal to the scope. If necessary, they can be cautiously guided into the gastric lumen where they can be easily reoriented in order to grasp and let the pointed end trail and not lead. Rectal FB may be found in children, psychiatric patients, victims of assault as a result of injury caused by medical practitioners. Objects used for sexual gratification can sometimes

demand for endoscopic removal from rectum or colon. Rectal FB can be asymptomatic and the diagnosis can at times be very difficult. Endoscopic retrieval is possible if the object is not too large and if it's close enough to the anus. When deeply located beyond the rectum FB may require a surgical approach.

© 2015 ACT. All rights reserved.

Key words: Endoscopic management, Foreign body

Bini M. Gastrointestinal Foreign Bodies: Clinical Aspects and Endoscopic management. *Journal of Gastroenterology and Hepatology Research* 2015; 4(3): 1524-532 Available from: URL: <http://www.ghrnet.org/index.php/joghr/article/view/1123>

INTRODUCTION

Foreign body (FB) ingestion is one of the main non haemorrhagic indications for emergency endoscopy^[1,2]. It is usually accidental and is more common in paediatric population (peak incidence between 6 months and 6 years). More than 85-90% of ingested FB will pass spontaneously the GI tract and will be eventually evacuated. Medical intervention after FB ingestion is required in 10-20% of patients mainly in certain patients considered "at risk" (Table 1). In the great majority of the cases, endoscopy solves the problem and about 1% of cases surgery is required for exploration and extraction. It is mandatory to spend time to acquire accurate history, physical examination followed by front and lateral x rays. In case of endoscopy failure, surgery is mandatory. After retrieval 24 hours admission should be only considered when complications are suspected or surgery is considered.

Table 1 Patients at risk of FB ingestion or impaction.

| |
|--|
| Children between 6 months/6 years age |
| Elderly patients |
| Edentulous patients |
| Impaired vision patients |
| Mentally impaired patients |
| Patient with previous GI surgery |
| Patients with oesophageal motility disorders |
| Patient with oesophageal stenosis |
| Prisoners or those who seek secondary gain after an access to a medical facility |

SYMPTOMS

The most common symptoms for FB ingestion are shown in Table 2

The above symptoms may also vary depending on the following: (1) Localization of FB; (2) Size/Shape of FB; (3) Composition and content of FB; (4) Time elapse from the ingestion; (5) Onset of Complications.

Obstructive symptoms and signs are more common when FB is stuck at the upper oesophageal sphincter (UES) level or in the cervical oesophagus. In a percentage as high as 50%, ingested FB can be asymptomatic. Small children may show unexplained food intake refusal as well as persistent crying. Signs like Hematemesis, peritonitis or intoxication symptoms are less frequent but alarming.

Vomit, pain, peritonitis may be the initial clinical presentation of a lower GI tract FB.

In some cases, mainly infants, elderly patients or mentally impaired patients, ingestion of the FB may have been unwitnessed; for this reason, even in the absence of positive history, a patient presenting with the above symptoms, should lead us to consider a possible FB ingestion.

Table 2 Symptoms for FB ingestion.

| |
|--------------------------|
| Pain |
| Dysphagia |
| Drooling |
| Regurgitation |
| Coughing |
| Airway obstruction signs |
| Hematemesis |
| Fever |
| Mediastinitis |
| Peritonitis |
| Intestinal obstruction |

DIAGNOSIS

History is the first step of the diagnostic process. Pre-existing GI pathologies can increase the risk of FB impaction (Table 3), thus information about previous dysphagia, previous GI surgery or reflux esophagitis should be carefully recorded^[1]. The presence of dental hardware, type and content of recent meals (like chicken or fish that may contain bones) as well as positive history of psychiatric disorders may also provide important information.

The diagnosis should repose on one or more diagnostic procedures^[1,3,4].

Biplane radiography of neck, chest and abdomen is useful in case of radiopaque foreign bodies.

CT scan may provide information in case of small FB foreign bodies, which could not be detected by radiography, still it can miss totally translucent FB.

Endoscopy is the most common and useful procedure for the detection and localization of FB especially radiopaque objects. It also states the presence of possible mucosal lesions.

Patients with persistent symptoms and suspected FB ingestion should undergo upper GI endoscopy even in case of unrevealing X-ray evaluation.

Table 3 Pathological conditions at risk of FB impaction.

| |
|--|
| Oesophageal motility disorders |
| Oesophageal strictures (peptic or neoplastic) |
| Achalasia |
| Oesophageal Diverticula |
| Patient with previous oesophageal and GI surgery |

TIMING

Once FB body ingestion is confirmed, the first step of management is to decide whether patient needs medical intervention and if the intervention is urgent^[5,6].

The indication for urgent endoscopic removal is based not only on patient's clinical conditions or symptoms, but also on the localization, shape and content or composition of the ingested FB.

FB Localization

FB impaction occurs most often in areas where GI tract shows physiological narrowing (Figure 1), angulations or pathological stenosis, UES and pylorus are the areas where a FB will most probably suck.

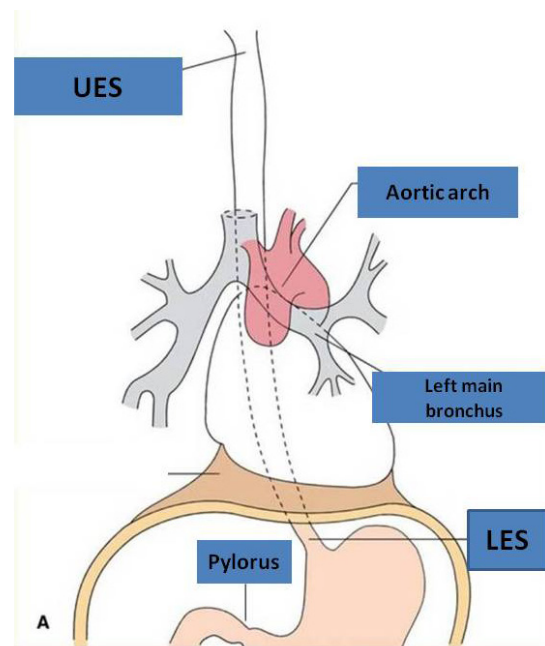


Figure 1 Physiological Upper GI narrowing areas.

Physiological Upper GI narrowing areas

Impacted FB which cause obstruction, pain, drooling require urgent removal. In the absence of obstruction symptoms, removal can be postponed not beyond 12-24 hrs from presentation, except in case of sharp or potentially harmful object. Longer delays may lead to a higher risk of complications^[7,8].

FB shape

Sharp or acuminated objects (Figures 2,3,4,5,6,7) should be immediately detected by radiography or endoscopy if radiography is negative. Those which are located in the oesophagus should be immediately removed. Sharp objects that reach the gastric lumen will most often pass spontaneously. There is an increased risk of complications (up to 35%) due to the FB transit and they should be retrieved if the endoscopic removal can be done safely. Gastric FB which does not pass the pylorus also needs to be removed.

FB Localization

FB in the oesophagus must be removed as soon as possible if they cause obstruction and/or the patient is symptomatic. Coins or non

sharp objects localized in the distal oesophagus might spontaneously progress into the gastric lumen. If the patient is asymptomatic, endoscopic retrieval may be delayed for 12-24 hours unless the FB is a button battery, which will be discussed later.

Stomach FB must be removed urgently only if they are potentially harmful. If not, most FB will spontaneously transit into the duodenum and eventually will pass into the colon. Patient should be monitored with daily radiographs and clinical evaluation. Surgical intervention is required if FB fails to progress or complications like hematemesis, melena, GI obstruction, peritonitis arise.

Due to their dimensions some FB may not pass the pylorus. If they are still in the gastric lumen after 48-72 h endoscopic removal can be scheduled.

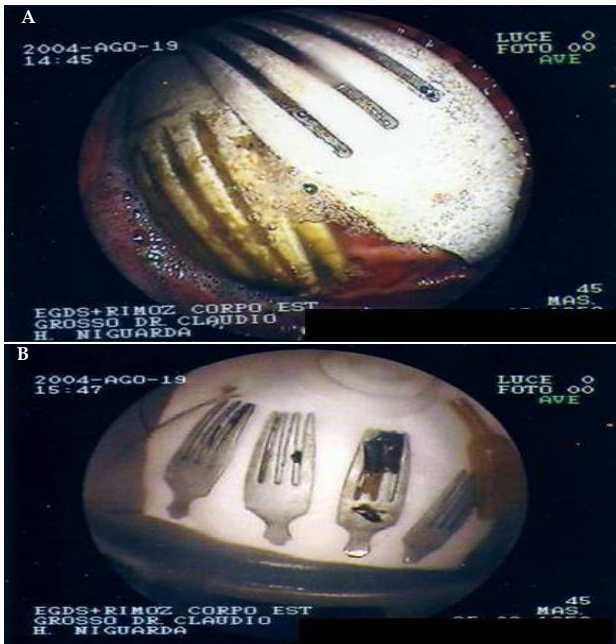

Figure 2 Forks.

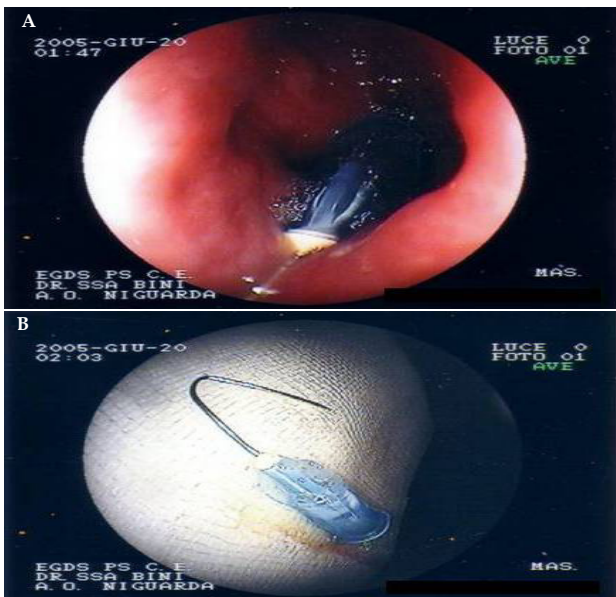


Figure 3 Needle.

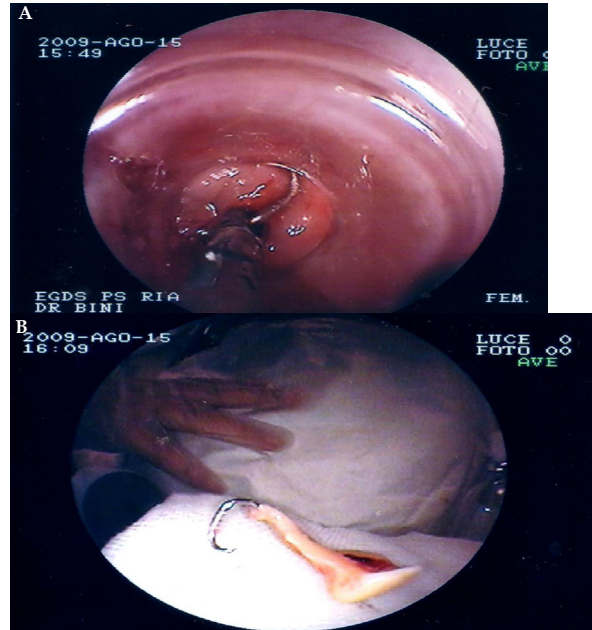


Figure 4 Dental hardware.

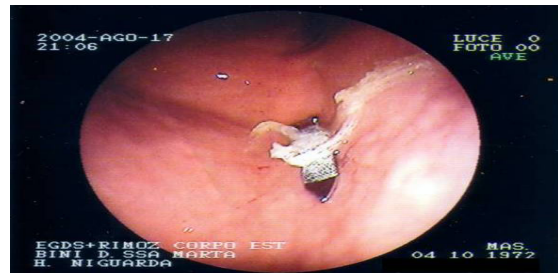


Figure 5 Nail file.

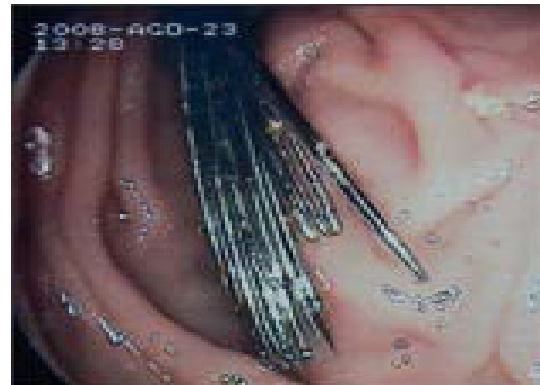


Figure 6 Needles.

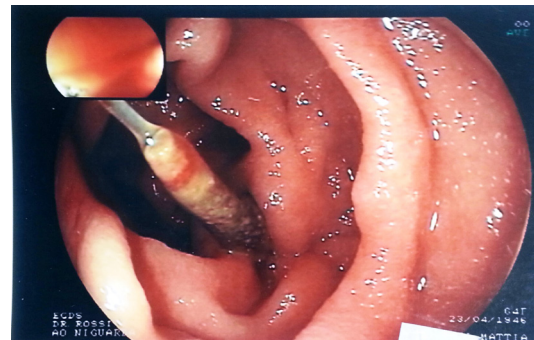


Figure 7 Duodenal perforation due to a toothpick.

FB content

Certain FB may not be harmful for their localization or shape, but just for their content or composition^[9-12].

This is the case of drugs, swallowed by “body packers” for international trafficking. Endoscopic manoeuvres might increase the risk of rupture of these packets and GI absorption of the substance in potentially lethal amounts, thus any attempt of endoscopic removal of these packets should be avoided.

These peculiar FB are usually radiopaque and can be localized on radiography or CT scan. Patient must be carefully monitored for possible overdose signs and symptoms. Urgent surgical removal is necessary if there is a documented failure of progression of the packets along the GI tract or in case of intoxication or obstruction symptoms onset^[13,14].

Ingested small metallic objects with a possible lead content may cause lead poisoning due to metal absorption. Lead haematological levels should be monitored and if they are increased, FB should be retrieved. Some type of FB are worth a specific argumentation:

FOOD BOLUS: Food bolus (Figure 8) is the most common foreign body in adults. Food impaction is more common in elderly patients or patients with underlying oesophageal diseases (Eosinophilic esophagitis, peptic or neoplastic strictures, motility disorders)^[15].

Radiography should be performed to identify the presence of bones which could increase the risk of perforation in case of delayed diagnosis or during removal manoeuvres.

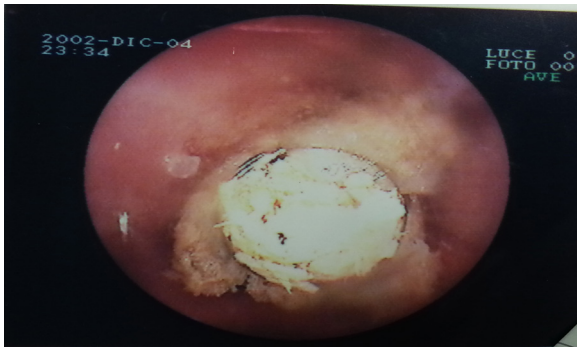


Figure 8 Food bolus.

COINS: Coins are the most frequent FB in paediatric population. In 10-16% of cases ingestion can be asymptomatic^[16] (Figure 9). Diagnosis should be ruled out or confirmed by biplane radiography.

Coins impacted in the upper oesophagus may cause partial or total obstruction, drooling, pain and should be immediately removed.

Literature data show that coins lodged in the medium or lower oesophagus usually are less symptomatic and have a probability as high as 30% of passing spontaneously^[1,2]. According to this observation, patients with coins or similar objects (i.e. buttons) localized in the middle or lower oesophagus may be radiologically and clinically monitored; endoscopic retrieval should be performed if coin fails to pass into the stomach after 12-24 hr. Coins located in the stomach do not need endoscopic removal unless they remain in the gastric lumen for more than 2 or 3 weeks (Figure 10).

MAGNETS: This kind of FB ingestion has become more frequent in recent years due to the widespread popularity of toys containing magnets and more common use of hear aids.

In 2007 the U.S Consumer Products Safety Commission (USCPSC) issued the first warning after the death of a 20-month-old-child, as

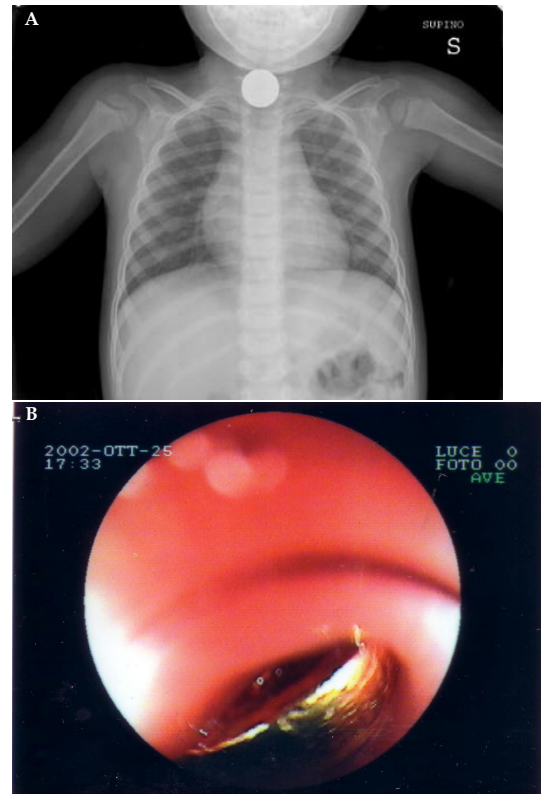


Figure 9 A: Coin in the proximal oesophagus; B: Coin at the UES.

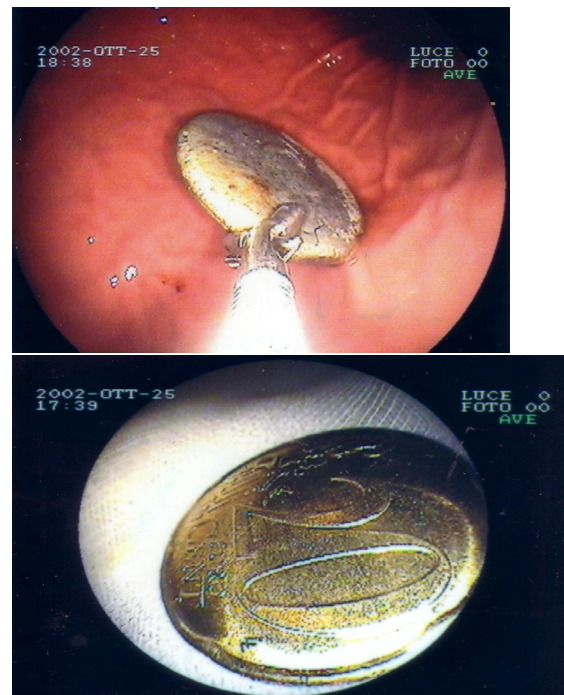


Figure 10 Retrieval of a coin from the gastric lumen.

well as 33 other cases of ingestion. The risk of complications due to magnet ingestion becomes real when two or more magnets are involved (Figure 11).

Mutual attraction of magnets located in different intestinal loops may lead to compression, necrosis of intestinal wall and subsequent perforation^[17-21].

In 2012 a NASPGHAN committee of experts developed an algorithm for the management of ingested magnets in children^[21], shown in figure 12.

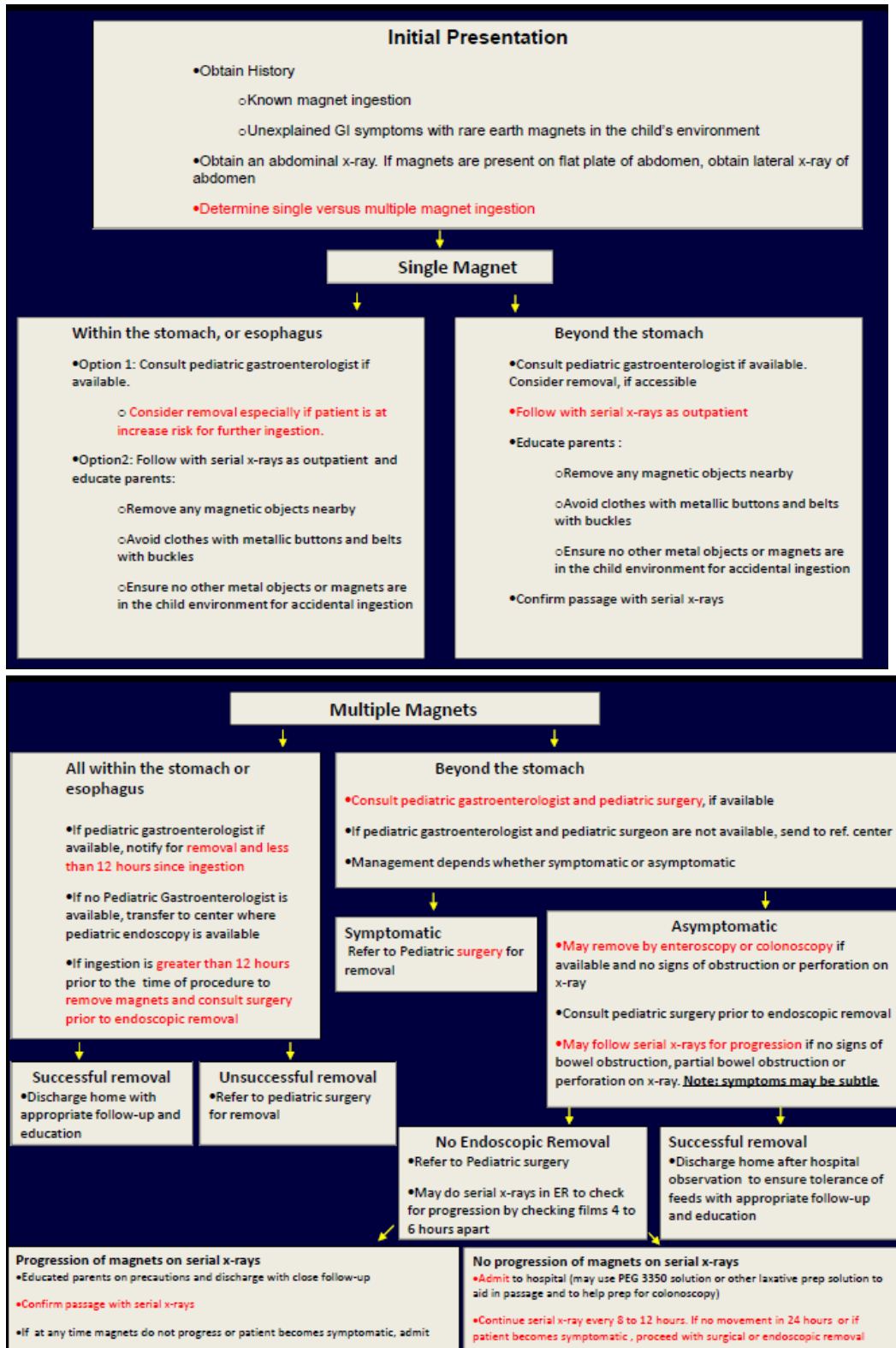


Figure 12 NASPGHAN Algorithm for management Magnets in children. (Journal of Pediatric Gastroenterology & Nutrition: Sept 2012; 55, 3: 239-242)

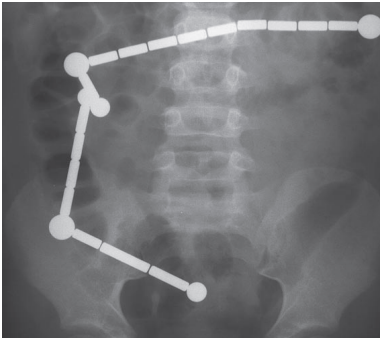


Figure 11 23 magnets ingested by 9 yr old. NEJM 360; 26 June 25, 2009; from L. d'Avolio, Policlinico S. Matteo Pavia.

DISK BATTERIES: Disk battery (DB) ingestion is worth a special consideration. This event has also become more frequent after the widespread use of toys, watches, hearing aids containing such kind of battery^[22-25].

Disk batteries can be of different sizes and voltage. Lithium larger diameter disk batteries cause more severe damages due to their higher voltage.

DB ingestion can cause mucosal damage due to: (1) leakage of caustic substances (alkali); (2) direct pressure; (3) generation of an electric current which can cause liquefaction necrosis and perforation.

Possible complications due to DB ingestion are shown in table 4

Fatal complications have increased since this kind of batteries became of common use.

National Capital Poison Center has reported 117 cases of severe complications and 29 deaths due to complications after DB ingestion (most fatal cases subsequent to aorto-esophageal fistula and massive bleeding^[22,23,24,26]). Certain conditions are at higher risk of major complications (Table 5).

There is an absolute indication to immediate endoscopic removal of DB located in the oesophagus.

The possibility of DB ingestion has to be ruled out with the appropriate diagnostics (Radiography, endoscopy) also in absence of symptoms since a high risk of major complications is documented by literature in case of delayed or missed diagnosis.

Once in the stomach, the risk of tissue damage is less high, still an endoscopic evaluation is necessary in order to point out possible lesions due to previous lodging of the battery in the oesophagus especially when the exact time of ingestion is unknown.

Table 4 Complications of DB ingestion.

| |
|-----------------------------------|
| Vocal cord paralysis |
| Oesophageal perforation |
| Oesophageal stricture |
| Tracheal stenosis |
| Tracheomalacia |
| Tracheoesophageal fistula |
| Haemorrhage from Arterial fistula |
| Infection |
| Death |

Table 5 Higher risk of DB ingestion complications.

| |
|---|
| Children younger than 4 years |
| Large diameter DB >20 mm (high voltage) |
| Multiple DB ingestion |
| Unwitnessed ingestion |
| Delayed diagnosis |
| Delayed removal |

ENDOSCOPIC TECHNIQUE FOR FB RETRIEVAL

FB endoscopic retrieval needs a well experienced endoscopist, particularly when it comes to paediatric patients. NASPGAN edited specific criteria that the endoscopist should accomplish to perform operative endoscopic procedures in children.

Endoscopic FB retrieval should be performed with anaesthesiologic assistance in order to provide adequate sedation or general anaesthesia; airway protection must always be guaranteed.

Softness of upper airways wall, in small children, can determine a higher risk of airflow obstruction due to FB compression and to endoscopic manoeuvres which must always be delicate and cautious.

Hyperinflation should be avoided because it can determine compression of the diaphragm and subsequent respiratory stress^[16,27,28].

Many FB retrieval devices (Figure 13) are available and the choice should be done on the basis of FB shape and dimensions as well as on the operator expertise. Testing the grasp on a "twin" or similar object (when available) may be useful in order to choose the most efficient device^[27,29].

This "pre-endoscopy" test of the device can be useful also in avoiding the choice of devices that might be "trapped or stuck" to the grasped object causing the impossibility to extract the endoscope.

Use of wide operative channel endoscope is advisable for it will allow us to choose any of the available devices since specific FB retrieval devices for pediatric or neonatal scopes with a 2 mm operative channel are not always available. If necessary for an expert endoscopist, under general anaesthesia and with adequate airway protection, it's possible to use a standard endoscope even in children under 12 month of age. Pointed objects must be retrieved with the sharp or pointed end distal to the scope.

If necessary, they can be cautiously guided into the gastric lumen where they can be easily reoriented in order to grasp and let the pointed end trail and not lead (Figure 14).

To reduce the risk of oesophageal wall perforation an overtube or bell-shaped latex hood device can be used for protection figure 15.

Food bolus impacted in the middle or lower oesophagus in some cases may be cautiously pushed forward into the gastric lumen. Still any forcing or stressing must be avoided specially in case of possible underlying oesophageal stricture. In this case food bolus should be extracted.

To this purpose variceal band ligation plastic caps can be particularly useful.

The cap loaded on the tip of the scope increases strength of aspiration and creates a space where food bolus can be sucked and removed more easily.

More than one intubation and aspiration might be necessary to completely remove food bolus which can be quite large.

It must be reminded that in case there is a possibility that the bolus contains bone fragments particular attention and precautions should be taken during the manoeuvres.

In some cases the passage of the FB through the upper oesophageal sphincter (UOS) might be difficult. Particularly large or irregular shaped FB, (i.e. dental hardware with metal hooks) can more easily be extracted under general anaesthesia in a curarized patient thanks to the complete relaxation of the voluntary muscles at (UOE) and ipofarinx. Magill forceps can also be a helpful device during extraction a FB from the ipofarinx

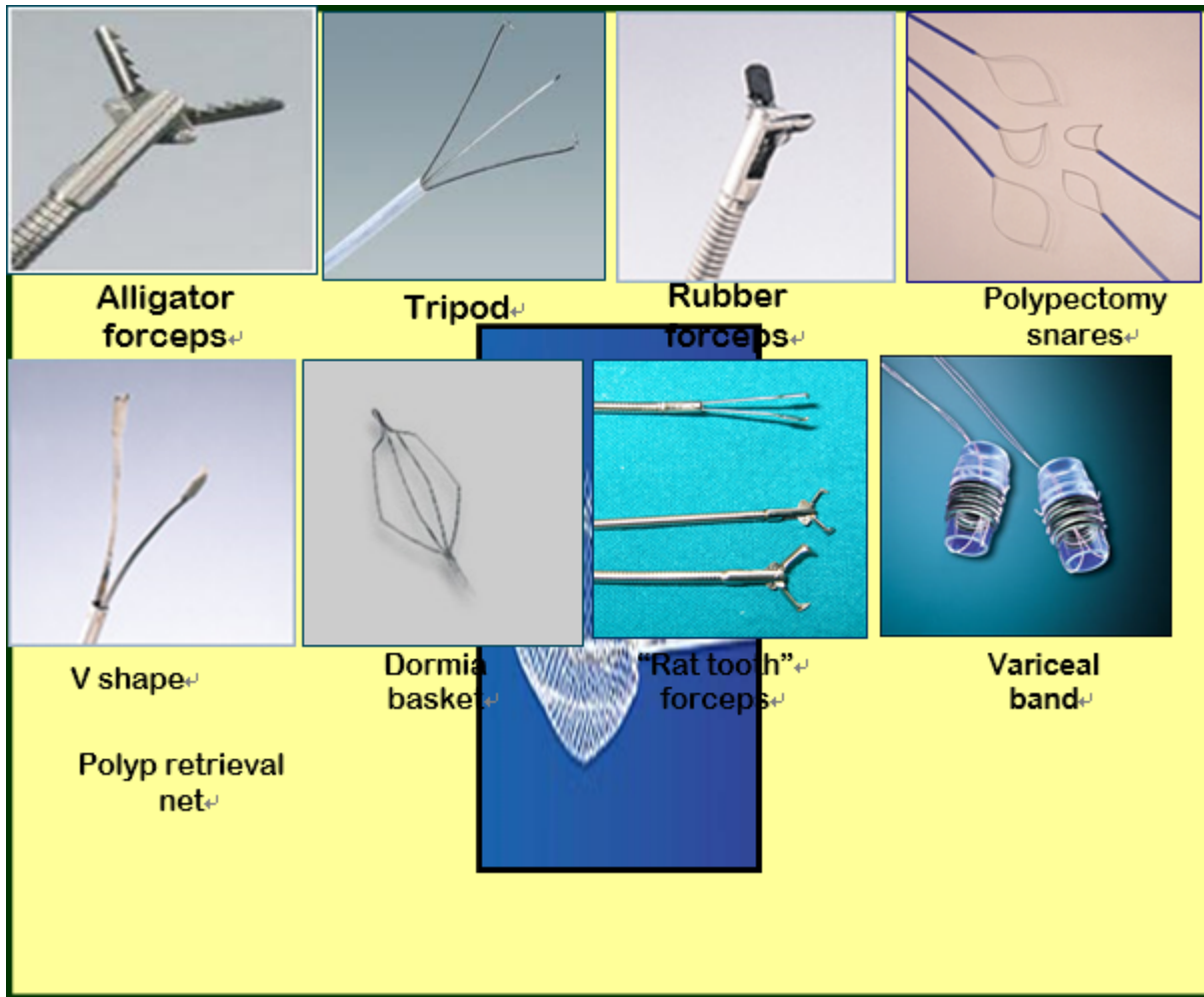


Figure 13 F.B. Retrieval devices.

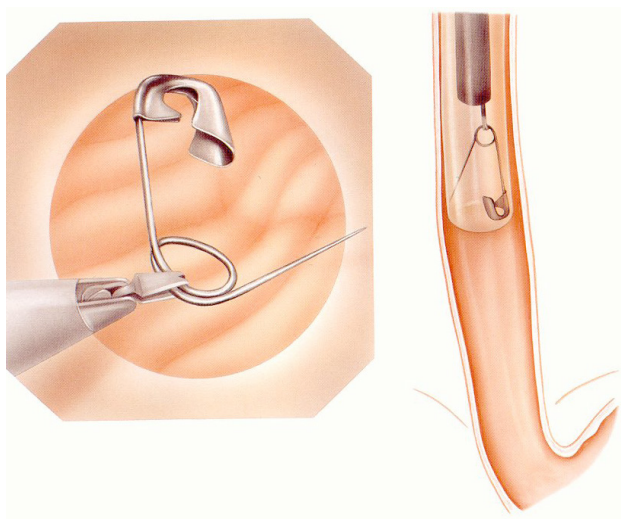


Figure 14 Orientation of a sharp FB during endoscopic retrieval.




Figure 15 Overtubes and bell shaped rubber.

Colon-rectum FB

They may be found in children, psychiatric patients, victims of assault^[30], as a result of injury caused by medical practitioners (e.g. broken rectal thermometers or broken enema catheter tips, Figure 16). Objects used for sexual gratification can sometimes demand for endoscopic removal from rectum or colon.

Rectal FB can be asymptomatic and the diagnosis can at times be very difficult^[30].

Common symptoms are shown in table 6.

Patients are often reluctant to ask for medical attention and usually they attend to the emergency room after they did more than one attempt to remove the object by themselves; these maneuvers might have caused rectal lesions. A delay in the diagnosis can lead to major complications like rectal or colon perforation.

Endoscopic retrieval is possible if the object is not too large and if it's close enough to the anus.

Retrieval of very large objects, figure 17, can be a challenge for the endoscopist “fantasy” in order to find a proper device or sometimes “invent” one capable to grip and hold the FB and extract it through the anal sphincter.

When deeply located beyond the rectum FB may require a surgical approach.

Lake *et al* determined that approximately 55% of RFB located in the sigmoid eventually required celiotomy for removal, as opposed to only 24% in cases of rectal objects.

Polypectomy snares are the most used device for endoscopic removal of large RFB.

An abdominal X-ray is advisable after the endoscopic procedure, especially if it was challenging or difficult, in order to rule out perforation.

| Table 6 Symptoms related to a lower GI tract FB. |
|--|
| Pain |
| Rectal bleeding |
| Fever |
| Abscess |
| Intestinal obstruction |

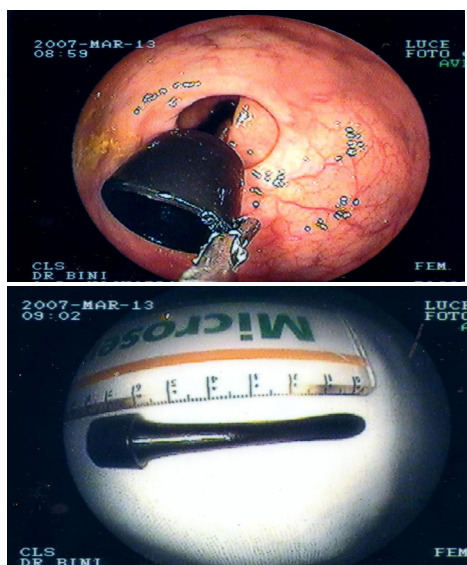


Figure 16 Rectal FB (Enema device).



Figure 17 A: Rubber dildo deeply inserted in the sigmoid colon; B: Rubber dildo grasped with a “handcrafted” device made inserting an endoscopic guide wire through a pusher catheter in order to create a snare, capture the FB and firmly pull it down; D: FB after endoscopic removal.

CONFLICT OF INTERESTS

The authors declare that they have no conflict of interests.

REFERENCES

1 Gundling F, Seidl H, Stark T, Schneider A, Schepp W. Management of impacted foreign bodies in the upper gastrointestinal tract in adult patients: results of a retrospec-

- tive case series. *Z Gastroenterol* 2012 Dec; **50(12)**: 1287-1291
- 2 Waltzman ML, Baskin M, Wypij D, Mooney D, Jones D, Fleisher GA Randomized Clinical Trial of the management of esophageal coins in children. *Pediatrics* 2005; Sep; **116(3)**: 614-619
 - 3 Foreign Bodies Milton T. Smith, Roy K.H. Wong. Gastrointest Endoscopy. *Clin N Am* 17 2007; 361-382
 - 4 Llompart A, Reyes J, Ginard D, Barranco L, Riera J, Gaya J, Obrador A Endoscopic management of foreign bodies in the esophagus. Results of a retrospective series of 501 cases. *Gastroenterol Hepatol.* 2002 Aug-Sep; **25(7)**: 448-451
 - 5 Hsieh CH, Wang YC, Chen RJ, Fang JF, Lin BC, Hsu YP, Kao JL, Kao YC, Yu PC, Kang SC. Comparison of the clinical presentations of ingested foreign bodies requiring operative and nonoperative management. *Int Surg* 2005 Apr-Jun; **90(2)**: 99-102
 - 6 Eisen GM, Baron TH, Dominitz JA, Faigel DO, Goldstein JL, Johanson JF, Mallory JS, Raddawi HM, Vargo JJ, Waring JP, Fanelli RD, Wheeler-Harborough J. Guideline for the management of ingested foreign bodies. *Gastrointest Endosc* 2002 Jun; **55(7)**: 802-806
 - 7 Lai AT, Chow TL, Lee DT, Kwok SP. Risk factors predicting the development of complications after foreign body ingestion. *Br J Surg* 2003 Dec; **90(12)**: 1531-1535
 - 8 Sung SH, Jeon SW, Son HS, Kim SK, Jung MK, Cho CM, Tak WY, Kweon YO Factors predictive of risk for complications in patients with oesophageal foreign bodies. *Dig Liver Dis* 2011 Aug; **43(8)**: 632-635. doi: 10.1016/j.dld.2011.02.018. Epub 2011 Apr 3
 - 9 GCK Wong, KK Lai, CH Chung. Management of body packers in the emergency department. *Hong Kong Journal of Emergency Medicine*
 - 10 Coon T, Miller M, Shirazi F, Sullivan J. Lead toxicity in a 14-year-old female with retained bullet fragments. *Pediatrics* 2006; **117(1)**: 227-230
 - 11 Jessica L. VanArsdale, Richard D. Leiker, Mel Kohn, T. Allen Merritt and B. Zane Horowitz. Lead Poisoning From a Toy Necklace *Pediatrics* 2004; **114**: 1096
 - 12 Chronic Lead Toxicity From Retained Foreign Body, TANAZ FARZAN DANIALIFAR, MD, MUN-WAH NG, MD, CATHERINE HUNTER, MD, and HILLEL NAON, MD Children's Hospital Los Angeles, Keck School of Medicine, University of Southern California. *Consultant For Pediatricians* 2012; **10**: 338-339
 - 13 Mandawa N et al. Establishment of a definitive protocol for the diagnosis and management of body packers Emerg. *Med J* 2011; **28**: 98-101
 - 14 Booker RJ, Smith JE, Rodger MP Packers, pushers and stuffers- managing patients HYPERLINK "http://www.ncbi.nlm.nih.gov/pubmed/19386860" Emerg Med J. 2009
 - 15 Katsinelos P, Kountouras J, Paroutoglou G, Zavos C, Mimidis K, Chatzimavroudis G. Endoscopic techniques and management of foreign body ingestion and food bolus impaction in the upper gastrointestinal tract: a retrospective analysis of 139 cases. *J Clin Gastroenterol* 2006 Oct; **40(9)**: 784-789
 - 16 Rossi A, Bini M. Ingestione di corpi estranei in età pediatrica. Management e rimozione endoscopica. In: Gestione di un Servizio di Endoscopia Digestiva (Cosentino F, Battaglia G, Ricci E), fascicolo 18. Ed. Area
 - 17 Encinas JL, Garcia-Bermejo C, Andres AM, Burgos L, Hernández P, Tovar JA. Multiple intestinal perforations due to ingestion of magnetized pieces of a toy. *An Pediatr (Barc)* 2005 Nov; **63(5)**: 457-458
 - 18 Sunny Z Hussain, Athos Bousvaros, Marc Gilger, Peter Mamula, Sandeep Gupta, Roert Kramer and R,Adam Noe Management of ingested magnets in children I *JPGN* 2012 Volume 55, Number 3
 - 19 Hernández Anselmi E, Gutiérrez San Román C, Barrios Fontoba JE, Ayuso González L, Valdés Dieguez E, Lluna González J, Roca Molla A, García-Sala Viguer C, Gómez Montes J, Cortina Orts H. Intestinal perforation caused by magnetic toys. *Journal of Pediatric Surgery* 2007; **42**: E13-E16
 - 20 Wildhaber BE, Le Coultre C, Genin B. Ingestion of magnets: innocent in solitude, harmful in groups. *Journal of Pediatric Surgery* 2005; **40**: E33-E35
 - 21 Management of Ingested Magnets in children. *Journal of Pediatric Gastroenterology & Nutrition* 2012; **55(3)**: 239-242
 - 22 Injuries from Batteries Among Children Aged <13 Years – United States, 1995–2010 - Morbidity and Mortality Weekly Report, Weekly/ Vol. 61 / No. 34 August 31, 2012
 - 23 Emerging Battery-Ingestion Hazard: Clinical Implications Toby Litovitz, Nicole Whitaker, Lynn Clark, Nicole C. White and Melinda Marsolek. *Pediatrics*; originally published online May 24, 2010
 - 24 Fatal Button Battery Ingestion: 29 reported cases National Capital Poison Center. <http://www.poisson.org/battery/fatalcases.asp>
 - 25 Panella NJ, Kirse DJ, Pranikoff T, Evans AK. Disk Battery Ingestion: Case Series With Assessment of Clinical and Financial Impact of a Preventable Disease. *Pediatr Emerg Care* 2013 Jan 29; **29(2)**: 165-169
 - 26 Endoscopic retrieval devices. www.giejournal.org Volume 69, No. 6 : 2009 *GASTROINTESTINAL ENDOSCOPY* 997
 - 27 Faigel DO, Stotland BR, Kochman ML, Hoops T, Judge T, Kroser J, Lewis J, Long WB, Metz DC, O'Brien C, Smith DB, Ginsberg GG. Device choice and experience level in endoscopic foreign object retrieval: An in vivo study. *Gastrointestinal Endoscopy* 1997 **45**: 490-492
 - 28 Consensus Statement Sulle Urgenze Endoscopiche Non Emorragiche In Et  Pediatrica. Progetto Airone, 2008
 - 29 Nelson DB, Bosco JJ, Curtis W, Faigel DO, Kelsey PB, Leung JW, et al. Endoscopic retrieval devices. *Gastrointest Endosc* 1999; **50**: 932-934
 - 30 Ruiz del Castillo J, Selles Dechent R, Millan Scheiding M, Zum rraga Navas P, Asencio Arana F. Colorectal trauma caused by foreign bodies introduced during sexual activity: diagnosis and management. *Enferm Dig* 2001; **93(10)**: 631-634
- Peer reviewers:** Toshiro Iizuka MD, Toranomon Hospital, Department of Gastroenterology, 2-2-2 toranomon Minato-ku Tokyo Japan; Hideki Iijima, M.D., PhD, Associate Professor, Department of Gastroenterology and Hepatology, Osaka University Graduate School of Medicine, 2-2 Yamadaoka, Suita, Osaka, 565-0871, Japan; Iruru Maetani, MD, Professor, Division of Gastroenterology, Department of Internal Medicine, Toho University Ohashi Medical Center, 2-17-6 Ohashi Meguro Tokyo 153-8515, Japan.