

Brunner's Gland Hyperplasia: A Rare Cause Of Gastric Outlet Obstruction and a Review of Treatment Strategies

Duminda Bernard Suraweera, MD, Jaimin Amin, MD, Armine Baltayan, MD, Richard Hu, MD

Duminda Bernard Suraweera, Jaimin Amin, Armine Baltayan, Department of Medicine, Olive View-UCLA Medical Center, the United States

Richard Hu, Division of Gastroenterology, Olive View-UCLA Medical Center, David Geffen School of Medicine at UCLA, the United States

Correspondence to: Richard Hu, MD, Division of Gastroenterology, Olive View-UCLA Medical Center, David Geffen School of Medicine at UCLA, the United States

Email: RichardHu@mednet.ucla.edu

Telephone: +1-818-364-3205 Fax: +1-818-364-4573

Received: April 16, 2015 Revised: June 16, 2015

Accepted: June 21, 2015

Published online: July 21, 2015

Review of Treatment Strategies. *Journal of Gastroenterology and Hepatology Research* 2015; 4(7): 1698-1701 Available from: URL: <http://www.ghrnet.org/index.php/joghr/article/view/1173>

INTRODUCTION

Brunner's gland hyperplasia is a benign lesion arising from the duodenum. It accounts for 10.6% of benign tumors in the duodenum and is often an incidental finding on endoscopy with the majority of patients being asymptomatic^[1]. Most lesions are less than 1cm in size and account for about 6.9% of endoscopically removed polyps in the duodenum^[1]. Rarely Brunner's gland hyperplasia can result in gastrointestinal bleeding, obstruction and abdominal pain^[2]. We report an unusual case of Brunner's gland hyperplasia leading to severe gastric outlet obstruction requiring surgical intervention.

ABSTRACT

Brunner's gland hyperplasia, sometimes referred to as Brunneroma or Brunner's hamartoma, is a benign lesion arising from the duodenum. We report an unusual case of Brunner's gland hyperplasia leading to severe gastric outlet obstruction requiring surgical intervention. A literature review of previous Brunner's gland hyperplasia cases leading to gastric outlet obstruction and the treatment strategies pursued in such cases suggest that size and pedunculation were important characteristics in determining amenability for endoscopic treatment.

© 2015 ACT. All rights reserved.

Key words: Brunner gland; hyperplasia; duodenal polyp; gastric outlet obstruction

Suraweera DB, Amin J, Baltayan A, Hu R. Brunner's Gland Hyperplasia: A Rare Cause Of Gastric Outlet Obstruction and a

CAES REPORT

A 59 year old female with history of hypertension presented with acutely worsening oral intolerance for 3 days. Patient reported symptoms initially began with early satiety and progressed to vomiting 3 months prior to presentation. Review of symptoms was otherwise negative. On presentation patient was having non-bilious non-bloody episodes of vomiting daily, occurring immediately after meals for 3 days and reported a 25lb weight loss over 2 months. Physical exam was notable for mild discomfort in epigastric region upon deep palpation. Labs were notable for a creatinine of 3.32 (normal, 0.6-1.3mg/dL). CT done at that time showed gastric distension possibly secondary to gastric outlet obstruction. Upper GI series showed distension of the stomach with retention of contrast material most suggestive of a near complete gastric outlet obstruction (Figure 1). Esophagogastroduodenoscopy (EGD) showed pyloric channel narrowing and a clean-based antral ulcer (Figure 2).

Biopsies were negative for malignancy. Patient underwent exploratory laparotomy and distal gastrectomy with gastrojejunostomy.

Gross examination of the distal gastrectomy was described as a 14cm × 7cm × 2cm portion of distal stomach and duodenum. The serosal surface was unremarkable, smooth with a pink tan. When opened, the mucosal surface exhibited a 2cm × 2cm polypoid mass that was 0.5cm from the pylorus. Pathology was consistent with Brunner's gland hamartoma (Figures 3 and 4). Patient recovered well and remained symptom free at 6 month follow up.

DISCUSSION

The Brunner's gland is found in the proximal duodenum and secretes alkaline-based mucus to protect the duodenal lining from gastric acid. The etiology of Brunner's gland hyperplasia is not known. It is hypothesized that excess gastric acid secretion or increased inflammation may lead to hyperplasia^[2]. Previously Brunner's gland hyperplasia was divided into circumscribed nodular hyperplasia, diffuse nodular hyperplasia and adenomatous hyperplasia, however recently it is hypothesized that these represent progression of a single clinical entity^[3]. Conditions associated with Brunner's gland hyperplasia include uremia, chronic pancreatitis and *Helicobacter*

pylori infection^[4-6]. On extremely rare occasions adenocarcinoma has been shown to arise from Brunner's gland hyperplasia with immunohistochemistry evidence of increased p53 antigen expression within the gland^[7,8]. Often Brunner's gland hyperplasia is asymptomatic and only diagnosed incidentally on endoscopy. It is most often found in the duodenal bulb where it appears as a mucosal protrusion or polyp ranging from 0.5 to 1.5 cm in size^[2]. Brunner's gland hyperplasia becomes rarer as you get further from the duodenal bulb: duodenal bulb 57% of cases, second portion of duodenum 27%, third portion of duodenum 7%, jejunum 2%, terminal ileum 2% and 5% found on the pylorus^[9]. Patients most commonly present with abdominal pain and gastrointestinal bleeding, but obstruction and intussusception are rare clinical presentations^[10].

Although radiographic imaging and EUS can aid in diagnosis, definitive diagnosis requires tissue pathology^[11]. It is estimated that duodenography has a reliability of 61% and a 20% false negative rate^[12]. Endoscopy has a sensitivity of 72-89%, however biopsies may be non-diagnostic as lesions are submucosal and may be missed on pinch biopsy^[13]. Treatment is resection via endoscopy, laparoscopy or laparotomy. Endoscopic polypectomy is a cost effective, less invasive approach that has been shown to be an effective and safe alternative to surgery^[14]. In our extensive literature review we found that size and pedunculation were important factors in determining which treatment modality was pursued^[15-26]. Typically, endoscopic polypectomy was

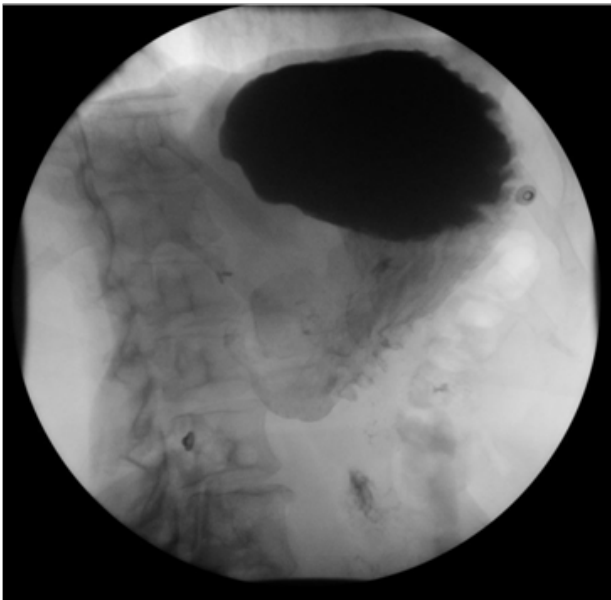


Figure 1 Upper GI series showing distended stomach with retained contrast fifteen minutes post ingestion with very minimal amount of contrast proceeding to the duodenum.

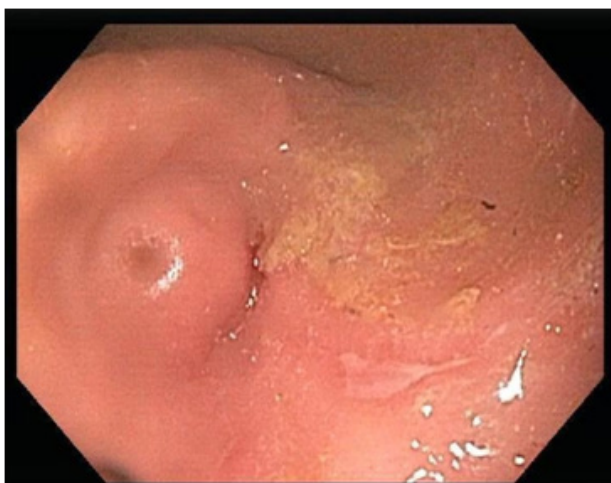

Figure 2 EGD showing pyloric channel narrowing and an antral ulcer.

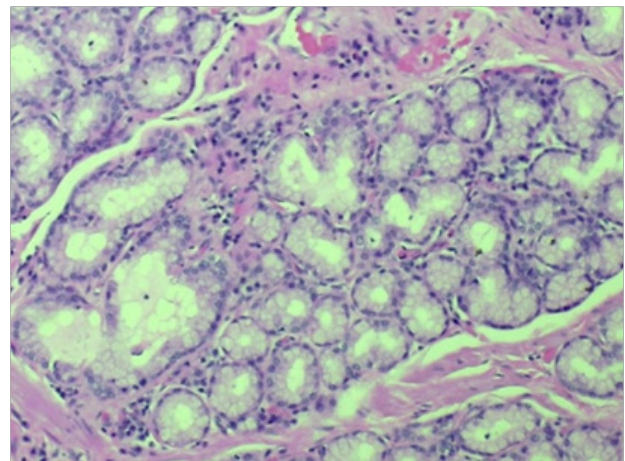


Figure 4 High power view, H&E stain, glands are composed of benign uniform columnar cells.

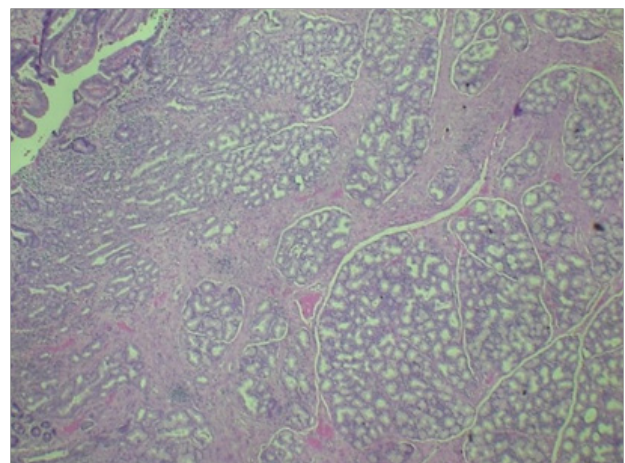


Figure 3 Low power view, H&E stain, shows proliferating glands underneath gastric mucosa (upper left corner) in a lobular pattern.

attempted in patients with polyps of less than 5 cm in size and with a pedunculated characteristic^[18,20,21,26]. Surgery was the preferred modality for polyps 5 cm or larger^[16,17,22-24].

One unique aspect of our case is the finding of an antral ulcer that may have been associated with the patient's Brunner's gland hamartoma. To our knowledge there has only been one case report of a concurrent antral ulcer and Brunner's gland hamartoma^[27]. While the exact pathophysiology of this phenomenon is unclear, it may be that the gastric outlet obstruction leads upstream mucosal damage leading to peptic ulcers, gastritis and esophagitis. Fuse *et al.* measured the thickness of the Brunner's gland in 297 cases of surgically resected peptic ulcer disease and found a negative correlation between distance of the peptic ulcer from pylorus and thickness of the Brunner's gland^[28]. The authors' concluded that this pattern was likely due to increased gastric acid secretion leading to hyperplasia of the Brunner's gland. Another possible relation between peptic ulcers and Brunner's gland hyperplasia is that both have an association with *Helicobacter pylori*. Kovacevic *et al.* conducted a prospective study involving 19,100 patients of which 5 patients were found to have concurrent *H. pylori* infection from the 7 patients found to have Brunner gland adenoma^[6]. Although it seems *Helicobacter pylori* infection may be common in patients with Brunner's gland adenoma, the exact pathogenesis is not known. The patient in this case tested negative for *Helicobacter pylori*. The severity of the patient's presenting symptoms, with near complete gastric outlet obstruction, also makes our case distinct. The obstruction was so severe that the hamartoma could not be accessed through endoscopy. Thus the patient underwent laparotomy and is the setting of her very severe gastric outlet obstruction, distal gastrectomy with gastrojejunostomy was performed.

CONCLUSION

In summary, we presented an unusual case of Brunner's gland hyperplasia that led to severe gastric outlet obstruction requiring surgical intervention. Our case supports the notion that in evaluation of patients with gastric outlet obstruction, a benign pathology of Brunner's gland hyperplasia should be included into the differential diagnosis. Furthermore, on review of the literature we conclude that management of gastric outlet obstruction from Brunner's gland hyperplasia depends on severity of symptoms and endoscopic accessibility.

CONFLICT OF INTERESTS

There are no conflicts of interest with regard to the present study.

REFERENCES

- 1 Hochter W, Weingart J, Seib HJ, Ottenjann R. Duodenal polyps. Incidence, histologic substrate and significance. *Deutsche medizinische Wochenschrift (1946)* 1984; **109**: 1183-1186
- 2 Franzin G, Musola R, Ghidini O, Manfrini C, Fratton A. Nodular hyperplasia of Brunner's glands. *Gastrointestinal endoscopy* 1985; **31**: 374-378
- 3 Iusco D, Roncoroni L, Violi V, Donadei E, Sarli L. Brunner's gland hamartoma: 'over-treatment' of a voluminous mass simulating a malignancy of the pancreatic-duodenal area. *Journal of the pancreas* 2005; **6**: 348-353
- 4 Paimela H, Tallgren LG, Stenman S, von Numers H, Scheinin TM. Multiple duodenal polyps in uraemia: a little known clinical entity. *Gut* 1984; **25**: 259-263
- 5 Stolte M, Schwabe H, Prestele H. Relationship between diseases

- of the pancreas and hyperplasia of Brunner's glands. *Virchows Archiv A, Pathological anatomy and histology* 1981; **394**: 75-87
- 6 Kovacevic I, Ljubicic N, Cupic H, Doko M, Zocak M, Troskot B, Kujundzic M, Banic M. *Helicobacter pylori* infection in patients with Brunner's gland adenoma. *Acta medica Croatica: casopis Hrvatske akademije medicinskih znanosti* 2001; **55**: 157-160
- 7 Kushima R, Stolte M, Dirks K, Vieth M, Okabe H, Borchard F, Hattori T. Gastric-type adenocarcinoma of the duodenal second portion histogenetically associated with hyperplasia and gastric-foveolar metaplasia of Brunner's glands. *Virchows Archiv: an international journal of pathology* 2002; **440**: 655-659
- 8 Faller G, Kirchner T. Low-grade intraepithelial neoplasia of Brunner's gland. *Histopathology* 2005; **47**: 118-119
- 9 Walden DT, Marcon NE. Endoscopic injection and polypectomy for bleeding Brunner's gland hamartoma: case report and expanded literature review. *Gastrointestinal Endoscopy* 1998; **47**: 403-407
- 10 Fuller JW, Cruse CW, Williams JW. Hyperplasia of Brunner's glands of the duodenum. *The American Surgeon* 1977; **43**: 246-250
- 11 Levine JA, Burgart LJ, Batts KP, Wang KK. Brunner's gland hamartomas: clinical presentation and pathological features of 27 cases. *The American journal of gastroenterology* 1995; **90**: 290-294
- 12 Gourtsoyiannis NC, Bays D, Papaioannou N, Theotokas J, Barouxis G, Karabelas T. Benign tumors of the small intestine: pre-operative evaluation with a barium infusion technique. *European journal of radiology* 1993; **16**: 115-125
- 13 Hedges AR. Hamartoma of Brunner's gland causing pyloric obstruction and a biliary fistula. Case report. *Acta chirurgica Scandinavica* 1988; **154**: 475-476
- 14 Park JH, Park CH, Park JH, Lee SJ, Lee WS, Joo YE, Kim HS, Choi SK, Rew JS, Kim SJ. The safety and usefulness of endoscopic polypectomy for treatment of Brunner's gland adenomas. *The Korean journal of Gastroenterology = Taehan Sohwagi Hakhoe chi* 2004; **43**: 299-303.
- 15 Krishnamurthy P, Junaid O, Moezzi J, Ali SA, Gopalswamy N. Gastric outlet obstruction caused by Brunner's gland hyperplasia: case report and review of literature. *Gastrointestinal Endoscopy* 2006; **64**: 464-467
- 16 Bastlein C, Decking R, Voeth C, Ottenjann R. Giant Brunneroma of the duodenum. *Endoscopy* 1988; **20**: 154-155
- 17 Mumtaz R, Shah IA, Ramirez FC. Brunner's gland hamartoma simulating a pancreatic mass with duodenal obstruction. *Gastrointestinal Endoscopy* 2002; **56**: 932-493
- 18 Kehl O, Buhler H, Stamm B, Amman RW. Endoscopic removal of a large, obstructing and bleeding duodenal Brunner's gland adenoma. *Endoscopy* 1985; **17**: 231-223
- 19 Varma D, Prakash K, Augustine P, Mahadevan P, Ramesh H. Brunner's gland adenoma with circumferential duodenal involvement. *Indian journal of gastroenterology: official journal of the Indian Society of Gastroenterology* 2001; **20**: 243-244
- 20 Jansen JM, Stuijbergen WN, van Milligen de Wit AW. Endoscopic resection of a large Brunner's gland adenoma. *The Netherlands journal of medicine* 2002; **60**: 253-255
- 21 Kang BK, Park NS, Jin DH, Ahn TH, Park MB, Lee KJ, Han YJ, Park HJ. Endoscopic resection of a giant duodenal Brunner's gland adenoma. *The Korean journal of gastroenterology = Taehan Sohwagi Hakhoe chi* 2008; **52**: 106-109
- 22 Dhinakar M, Allaya DJ, Golash V. A Rare Case of Brunneroma Duodenum causing Gastric Outlet Obstruction. *Oman medical journal* 2010; **25**: 44-46
- 23 Coriat R, Mozer-Bernardeau M, Terris B, Chrysostalis A, Prat F, Chaussade S. Endoscopic resection of a large Brunner's gland hamartoma. *Gastroenterologie clinique et biologique* 2008; **32**: 11-14

- 24 de Nes LC, Ouwehand F, Peters SH, Boom MJ. A large Brunner's gland hamartoma causing gastrointestinal bleeding and obstruction. *Digestive surgery* 2007; **24**: 450-2.
- 25 Gokhale U, Pillai GR. Large Brunner's Gland Hamartoma: A Case Report. *Oman medical journal* 2009; **24**: 41-3.
- 26 Rocco A, Borriello P, Compare D, De Colibus P, Pica L, Lacono A, Nardone G. Large Brunner's gland adenoma: case report and literature review. *World journal of Gastroenterology* 2006; **12**: 1966-8.
- 27 Cavallaro G, Albanese V, Taranto F, Pustorino S, Baldari S. Brunner's adenoma, esophageal reflux and gastric ulcer. A case report. *Chir Ital* 2000; **52**: 703-6.
- 28 Fuse Y, Tsuchihashi Y, Takamasu M, Kodama T, Fujita S, Kashima K. Thickness of Brunner's glands and its clinical significance in peptic ulcer diseases. *Gastroenterol Jpn* 1989; **24**: 512-8.

Peer reviewer: Marco Bustamante, MD, PhD, Endoscopy Unit, University Hospital La Fe, Bulevar Sur, sn, Valencia 46017, Spain.