

Finding out Serologically Active Gastritis Subjects by Conventional Endoscopy and Picking out Subjects Who might be Benefit from *Helicobacter pylori* Eradication as a Primary Prevention for Gastric Cancer

Byung Chul Kim, Sung Ho Kwon

Byung Chul Kim, Department of Internal Medicine, Hangsarang Hospital, Ulsan, Korea

Sung Ho Kwon, Department of Internal Medicine, Kangnam medical clinic, Ulsan, Korea

Correspondence to: Byung Chul Kim, Department of Internal Medicine, Hangsarang Hospital, Bunyeoungro 51 Nam-gu, Ulsan 680-804, Korea

Email: orion828@naver.com

Telephone: +82-55-269-0975

Fax: +82-52-256-7175

Received: May 2, 2015

Revised: May 30, 2015

Accepted: June 1, 2015

Published online: June 21, 2015

ABSTRACT

AIM: In Korea biennial endoscopy is performed on regular base, therefore endoscopic description regarding gastric cancer risk is very important. Based on recent studies classifying gastritis status by serum pepsinogen (PG) profiles we tried to find out relationships between serological gastritis status and specific endoscopic mucosal appearances.

METHODS: We performed endoscopic examinations and serum PG sampling (PG I and II and I/II ratio) and rapid urea test for a total of 170 subjects who visited our health promotion center from June 2014 to September 2014, endoscopic images were collected and those images were compared with each PG test results.

RESULTS: Among endoscopic parameters, PG based highly active inflammation groups were associated with body rugal hyperplastic gastritis (24.7), followed by body spotty erythema (16.6), body xanthoma (10.6), antrum swelling of areae gastrica (9.8) in order of high odds ratio (P -value <0.05). For serological mild atrophic gastritis, the cut-off value of endoscopic atrophic border (EAB) was

closed type 3 by Kimura-Takemoto classification.

CONCLUSION: By conventional endoscopy we could discriminate highly active gastritis group with the aid of mucosal status, we also be able to select people who are benefit from *H.pylori* eradication as primary gastric cancer prevention with EAB.

© 2015 ACT. All rights reserved.

Key words: Atrophic gastritis; Pepsinogen; Endoscopy

Kim BC, Kwon SH. Finding out Serologically Active Gastritis Subjects by Conventional Endoscopy and Picking out Subjects Who might be Benefit from *Helicobacter pylori* Eradication As a Primary Prevention for Gastric Cancer. *Journal of Gastroenterology and Hepatology Research* 2015; 4(6): 1643-1648 Available from: URL: <http://www.ghrnet.org/index.php/joghr/article/view/1191>

INTRODUCTION

With progression of technology it is possible to get high quality endoscopic images by conventional white light endoscopy and several studies have tried to achieve clues such as *Helicobacter pylori* (*H.pylori*) infection or mucosal activity and inflammation or gastric atrophy with gastric mucosal status. In addition to traditional useful value of endoscopic atrophic border (EAB) supported by Operative Link on Gastritis Assessment (OLGA) for gastritis staging, useful and reliable method to assess gastric mucosal status is pepsinogen (PG) based serological approach. Recent published study^[1] showed that gastric mucosal status could be classified into four groups based on *H.pylori* status, PG I, II, I/II ratio, and serological chronic atrophic gastritis (CAG)-synonym for extensive atrophic gastritis- [Group A, *H.pylori* (-) and (CAG) (-); Group B, *H.pylori* (+) and CAG (-); B- α ,

PG I \leq 70 ng/mL and PG I/II ratio $>$ 3.0; B- β , PG I $>$ 70 ng/mL and PG I/II ratio $>$ 3.0; B- γ , PG I $>$ 70 ng/mL and PG I/II ratio \leq 3.0; II-30, PG II $>$ 30 ng/ml; Group C, *H.pylori* (+) and CAG (+); CI-0, PG I \leq 30 ng/mL; CI-30, PG I $>$ 30 ng/ml and \leq 50 ng/mL; CI-50, PG I $>$ 50 ng/mL; Group D, *H.pylori* (-) and CAG (+)], and they found out some subgroups (group B- γ , II-30, *H.pylori* antibody titer $>$ 500 U/mL) have high risk of gastric cancer (GC) (especially diffuse type GC) comparable to that of group C. Yanaoka *et al*^[2] showed *H.pylori* eradication was effective for preventing GC only in serological mild atrophic gastritis. Our main concern was how to correlate these meaningful serological gastritis status with endoscopic findings, which might help us decide which person should be followed strictly or could benefit from primary GC prevention such as *H.pylori* eradication.

MATERIALS AND METHODS

1. Subjects and endoscopic examinations

We consecutively enrolled a total of 170 subjects from June 2014 to September 2014 who visited our health-promotion center for

screening endoscopy showing *H.pylori* associated gastric mucosal appearances with positive *H.pylori* test (rapid urea test using CLO Helicobacter-detection kits-Asan Pharm Co., Ltd., Seoul, Korea), we used 11 endoscopic parameters mainly based on Nomura *et al*^[3] and Cho *et al*^[4] (Figure 1). Subjects were excluded from the study if they had history of *H.pylori* eradication or if they had been taking any medicine influencing gastric mucosal appearance (any acid suppressive medication or non-steroidal anti-inflammatory agent) within eight weeks prior to examination, also we excluded subjects when they had any of past medical illness like liver or heart problem or malignant diseases. All subjects had already requested *H.pylori* test and PG study for gastric cancer screening in pre-questionnaire. They were under conventional white light endoscopy using a GIF-Q260 (Olympus Co., Tokyo, Japan) and endoscopic mucosal images were collected for each individual such as body diffuse erythema (B_DE) (graded as 1 when it could be identified by close-up observation of mucosa due to light red color and 2 when easily identified at some distance due to dark red color), body type (B_type) A and B and C (A, mosaic-like appearance; B, diffuse homogenous redness; C, untypical pattern), body spotty erythema (B_SE) (graded as 1 when it could be

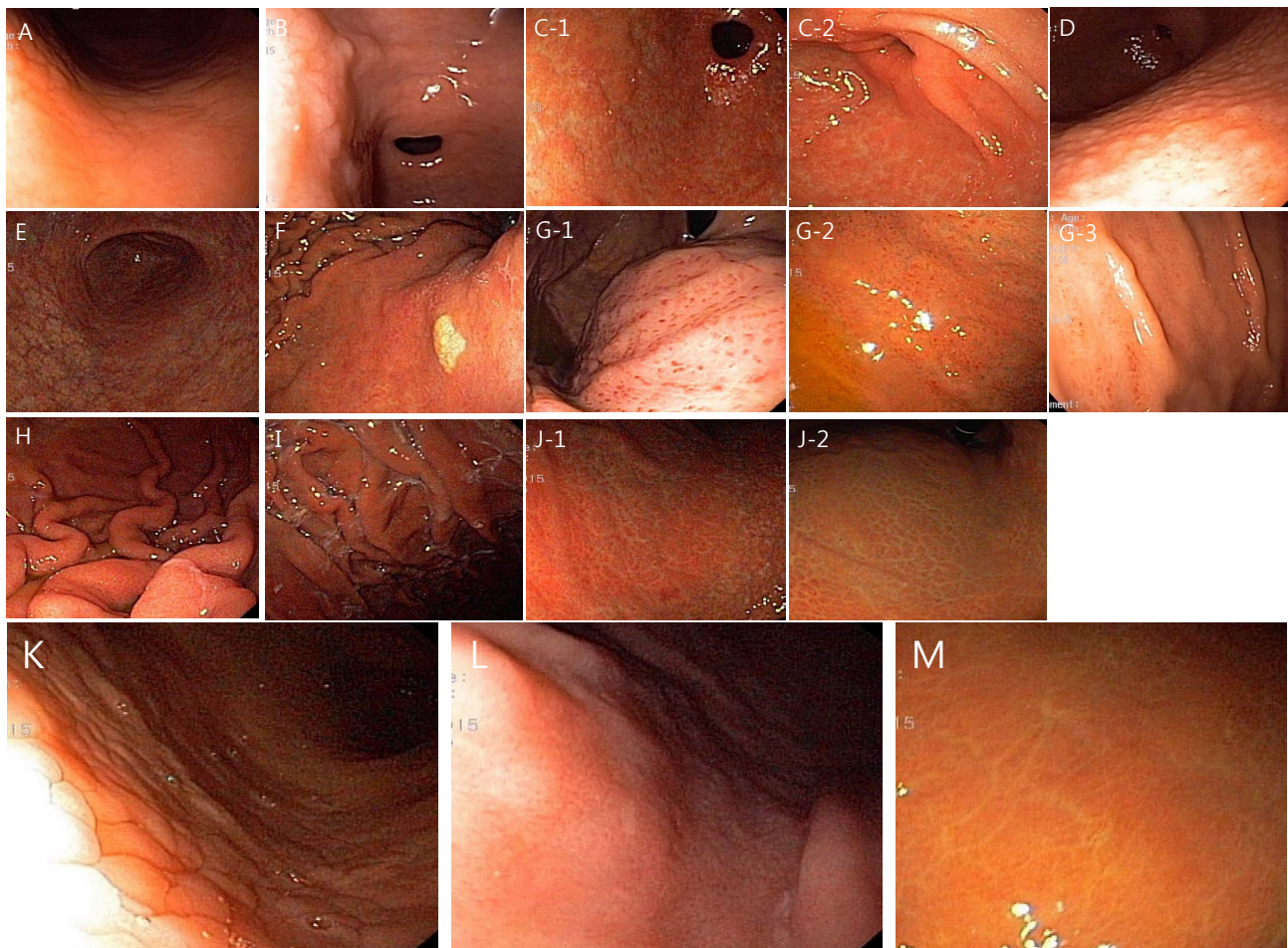


Figure 1 Representative mucosal findings. (A) Antrum swelling of areae gastrica - gastric area-like structure of small soft elevation (A_SAG(1)). (B) Antrum intestinal metaplasia - small elevated white plaques are scattered on the antrum (A_IM(1)). (C-1) Antrum diffuse erythema - uniformly expanded mucosal surface (A_LFG(1)). (C-2) same as C-1 but lighter red color (A_DE(1)). (D) Antrum lymphofollicular gastritis - numerous nodular structure on the mucosal surface (A_LFG(1)). (E) Antrum visible vessel (A_VV(1)). (F) Body xanthoma - yellow white spot (B_xan(1)). (G-1) Body spotty erythema - clearly seen multiple spotty small erythema in the fundus and body area (B_SE(3)). (G-2) visible spotty erythema at distance but not as clear as G-1 (B_SE(2)). (G-3) visible spotty erythema only in close observation (B_SE(1)). (H) Body rugal hyperplasia - thickened or tortuous fold even with appropriate inflation of the stomach with air (B_RHG(1)). (I) Body exudate - white mucinous fluid sticking to the mucosa (B_EXU(1)). (J-1) Body diffuse erythema (B_DE(2)). (J-2) same as J-1 but lighter red color than J-1 (B_DE(1)). (K) Body type A - mosaic-like appearance (B_type(1)). (L) Body type B - diffuse homogenous redness (B_type(2)). (M) Body type C - untypical pattern (B_type(3)).

seen only in body greater curvature and 3 when clearly seen in fundus and body, and 2 when observed but neither 1 or 3), body xanthoma (B_xan), body rugal hyperplastic gastritis (B_RHG): when gastric fold width was equal or over 5mm with the aid of opening width (7 mm) of jaw of biopsy forcep despite sufficient aeration, antrum swelling of areae gastrica (A_SAG), antrum diffuse erythema (A_DE) (graded as 1 or 2 as described above), antrum visible vessel (A_VV), antrum lymphofollicular gastritis (A_LFG), antrum intestinal metaplasia (A_IM) (when whitish plaques were scattered on the mucosal surface). Each type of EAB (as C-1~3, closed type 1~3; O1~3, open type 1~3) was also described as suggested by Kimura-Takemoto^[5]. All endoscopic procedures were performed by main author to avoid inter-observer variability.

This study was approved by Korea National Institute for Bioethics Policy (KoNIBP).

2. Serum pepsinogen(PG) levels

Fasting blood samplings for serum PG test were done before each endoscopy session, and were centrifuged immediately at 4°C. Serum concentrations of PG I and II were measured by a latex enhanced turbidimetric immunoassay (HBI Co., Anyang, Korea), and PGI to PG II (PG I/II) ratio were calculated.

Statistical analysis

We used SPSS ver. 18.0 for Windows Software (SPSS Inc., Chicago, IL, USA) for logistic regression analysis to obtain odds ratio of each endoscopic finding associated with Group B-γ or II-30, and with MedCalc ver. 15 (MedCalc Software bvba Acacialaan 22 8400 Ostend Belgium) for receiver operator characteristic (ROC) curve and area under curve (AUC) to get optimal cut-off value of EAB compatible with extensive atrophic gastritis (Group C). *P*-value <0.05 was regarded as statistically significant.

RESULTS

1. Characteristics of subjects

A total of 170 subjects were included in the study. The mean age was 47.4 years with a range from 14 to 73 years (102 men and 68 women). The mean serum PG I level was 74.5 ng/ml and mean serum PG II level was 20.1 ng/ml and mean PG I/II ratio was 4.1 (Table 1). We subdivided EAB into 12 categories and only 4 subjects showed no discernible EAB, and 56(33%) subjects were above EAB C-3 (Open type) by Kimura-Takemoto classification (Table 2). Among the specific mucosal findings, body diffuse erythema was the most common (92.3%) and followed by antrum diffuse erythema (64.7%), and antrum visible vessel (61.2%), when it comes to body type, type B was the most common (52.4%), and followed by type A (37.1%) and type C (7.1%), the remaining 6 cases showed normal mucosal appearance [regular arrangement of collecting venules (RAC)] (3.5%), numbers of respective gastric mucosal status were shown in Table 3. As for serological grouping, Group B was more frequent than Group C (82.9% vs 17.1%) and group B-γ cases were 14 (8.2%), and II-30 cases were 21 (12.4%), thus active gastritis cases were 26 cases (15.3%). In Group C, group CI-50 was the most frequent (7.1%) and group CI-0 was the least frequent (4.1%) (Table 4).

2. Association between endoscopic mucosal appearances and PG-based serologically active gastritis (Group B-γ or II-30).

All endoscopic mucosal appearances were categorical variables and all variables were used for logistic regression analyses, we used reference category as 0 for negative finding of respective mucosal

Table 1 Baseline characteristics of the Subjects.

	Total (n=170)
Gender	
Male	102(60)
Female	68(40)
Age (years, mean±SD)	47.4 ± 9.9
Observed diseases	1(0.6)
Acute gastric mucosal lesion	23(13)
Peptic ulcer (gastric/duodenal/both)	7/14/2
Early gastric cancer (all intestinal type)	2(1.2)
Serum pepsinogens (mean±SD)	
Pepsinogen I (ng/ml)	74.5± 58.2
Pepsinogen II (ng/ml)	20.1± 14.6
Pepsinogen I/II ratio	4.1± 1.6
Helicobacter status	
Total CLO	170
Positive CLO	170(100)

CLO: the rapid urease test.

Table 2 Distribution of endoscopic atrophic border.

	Total n=170(%)
no visible atrophic border	4(2.4)
AG C1	13(7.6)
AG C1~C2	5(2.9)
AG C2	32(18.8)
AG C2~C3	22(12.9)
AG C3	38(22.4)
AG C3~O1	7(4.1)
AG O1	20(11.8)
AG O1~O2	11(6.5)
AG O2	14(8.2)
AG O2~O1	3(1.8)
AG O3	1(0.6)

AG C1, atrophic gastritis closed type 1; C2, closed type 2; C3, closed type 3; O1, open type 1; O2, open type 2; O3, open type 3.

Table 3 Endoscopic mucosal appearances.

	Total n=170(%)
B_DE(1)	67(39.4)
B_DE(2)	90(52.9)
B_type(1)	63(37.1)
B_type(2)	89(52.4)
B_type(3)	12(7.1)
B_EXU(1)	79(46.5)
B_SE(1)	26(15.3)
B_SE(2)	31(18.2)
B_SE(3)	20(11.8)
B_xan(1)	21(12.4)
B_RHG(1)	30(17.6)
A_SAG(1)	43(25.3)
A_LFG(1)	9(5.3)
A_VV(1)	104(61.2)
A_DE(1)	101(59.4)
A_DE(2)	9(5.3)
A_IM(1)	6(3.5)

B_DE, body diffuse erythema; B_DE(1), body diffuse erythema grade 1; B_DE(2), body diffuse erythema grade 2; B_type, body type; B_type(1), body type A; B_type(2), body type B; B_type(3), body type C; B_EXU(1), body exudate existed; B_SE, body spotty erythema; B_SE(1), body spotty erythema grade 1; B_SE(2), body spotty erythema grade2; B_SE(3), body spotty erythema grade 3; B-xan(1), body xanthoma existed; B_RHG(1), body rugal hyperplastic gastritis existed; A_SAG(1), antrum swelling of areae gastrica existed; A_LFG(1), antrum lymphofollicular gastritis existed; A_VV(1), antrum visible vessel existed; A_DE(1), antrum diffuse erythema grade 1; A_DE(2), antrum diffuse erythema grade 2; A_IM(1), antrum intestinal metaplasia existed.

pattern. Without regard to statistical significance (P -value <0.05) positive correlations (odds ratio > 1) for active gastritis were noted in the Body type C, body spotty erythema grade 2 and grade 3, body xanthoma, body rugal hyperplastic gastritis, antrum swelling of areae gastrica, antrum lymphofollicular gastritis, antrum visible vessel, and negative correlations (odds ratio < 1) were noted in the body diffuse erythema, body type A and type B, body exudate, body spotty erythema grade 1, antrum diffuse erythema, antrum intestinal metaplasia. We observed four statistically significant (P -value <0.05) endoscopic mucosal patterns all of which showed positive correlations for active gastritis, those were B_RHG, B_SE(3), B_xan, A_SAG and each odds ratio showed highest in B_RHG (24.7), followed by B_SE(3) (16.6), B_xan (10.6), A_SAG (9.8), this means if body RHG exist, the possibility of active gastritis will be 24.7 times higher than without body RHG. (Table 5).

3. Correlation between EAB and serological chronic atrophic gastritis (Group C)

Receiver operator characteristic (ROC) curve and area under curve were obtained to find out optimal EAB type to predict serological chronic atrophic gastritis (Group C), the AUC was 0.758 and the optimal cut-off value of EAB type was type C-3, with 64.2% sensitivity and 73.2% specificity (Figure 2).

Table 4 Serological gastric mucosal status.	
Total n=170(%)	
Group B	141(82.9)
group B - α	77(45.3)
group B - β	50(29.4)
group B - γ	14(8.2)
Group C	29(17.1)
group CI-0	7(4.1)
group CI-30	10(5.8)
group CI-50	12(7.1)
II-30	21(12.4)
II-30 or group B - γ	26(15.3)

Group B, rapid urease test(+) and chronic atrophic gastritis (CAG) absent; B- α , pepsinogen (PG) I \leq 70 ng/mL and PG I/II ratio > 3.0 ; B- β , PG I $>$ 70 ng/mL and PG I/II ratio > 3.0 ; B- γ , PG I $>$ 70 ng/mL and PG I/II ratio ≤ 3.0 ; II-30, PG II > 30 ng/mL; Group C, rapid urease test(+) and CAG present; I-0, PG I ≤ 30 ng/mL; I-30, PG I > 30 ng/ml and ≤ 50 ng/mL; I-50, PG I > 50 ng/mL.

Table 5 Association between endoscopic mucosal appearances and pepsinogen (PG) based serologically active gastritis (Group B- γ or II-30).		
Mucosal parameter	P-value	Odds ratio
B_DE		
B_DE(1)	0.214	0.186
B_DE(2)	0.572	0.493
B_type		
B_type(1)	0.327	0.154
B_type(2)	0.717	0.514
B_type(3)	0.871	1.405
B_EXU(1)	0.362	0.533
B_SE		
B_SE(1)	0.467	0.467
B_SE(2)	0.453	1.933
B_SE(3)	0.002	16.608
B_xan(1)	0.017	10.609
B_RHG(1)	0.000	24.714
A_SAG(1)	0.004	9.765
A_LFG(1)	0.188	4.049
A_VV(1)	0.633	1.386
A_DE		
A_DE(1)	0.221	0.436
A_DE(2)	0.999	0.000
A_IM(1)	0.133	0.035

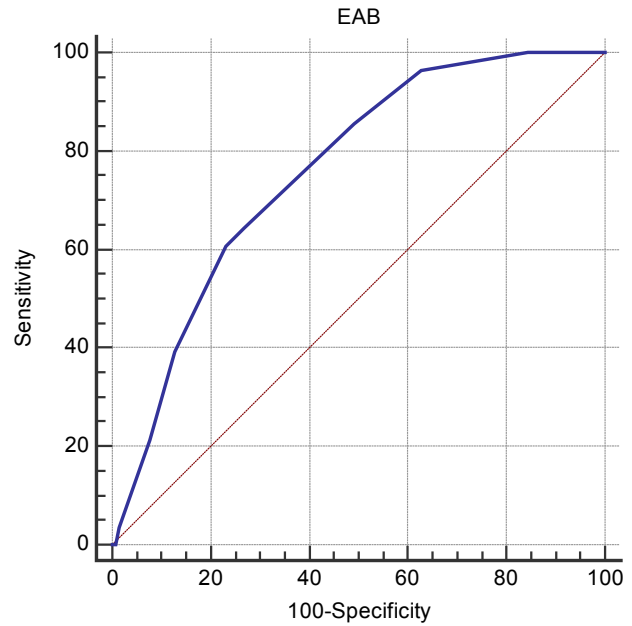


Figure 2 Receiver operator characteristic (ROC) curve and area under curve to find out group C by endoscopic atrophic border by Kimura-Takemoto classification. the AUC was 0.758 and the optimal cut-off value of EAB type was C-3, with 64.2% sensitivity and 73.2% specificity. C-3, closed type 3.

DISCUSSION

Non-cardia GC could be occurred via two pathways, one is slowly progression type as suggested by Correa^[6], the other suggestion^[7] is fast progression type bypassing the Correa pathway. As Uemura *et al*^[8] showed that Intestinal type gastric cancer was related with corpus dominant gastritis, intestinal metaplasia, severe atrophic gastritis and diffuse type gastric cancer was more related to pan-gastritis, moderate atrophic gastritis. Handy EAB has been proved to be useful tool assessing intestinal type GC (mainly slow progressing type) risk^[9-10], however EAB classification supported by OLGA has a weak point, that is OLGA itself has no significance of body gastritis that can contribute to GC with poorer histologic type without high stage of OLGA system^[11].

Several studies have revealed that highly active inflammation in *H.pylori* infected subjects could directly cause diffuse type gastric cancer by bypassing the atrophy and intestinal metaplasia^[12-14]. Yanaoka *et al*^[15] showed elevated PG II level was correlated with diffuse type gastric cancer and several other studies revealed PG II elevation was related to severity of gastritis activity in non-atrophic gastritis^[16-17]. There have been efforts to identify these subgroups, actually Kiyohira *et al*^[18] showed gastritis severity and gastric mucosal status could be well documented by serum PG. Recent Japanese studies^[1,19] uncovered some groups of atrophy free subject showed GC risk equivalent to extensive atrophic gastritis especially diffuse type GC, the main characteristics of these subgroups were elevated PG II.

Considering Hunter *et al*^[20] that *H.pylori* infection contribute more to PG II elevation than to PG I, and Iranian study^[21] suggesting that PG II could be good surrogate marker for body morphological change after *H.pylori* infection, and major portion of PG II was originated from the active gastritis by neutrophil cell infiltration, we could come to conclusion that *H.pylori* infected active gastritis creating more neutrophil infiltration would cause more PG II elevation.

Referring to Kiyohira *et al.*^[18], PG II continue to elevate till histologic atrophy reach to moderate grade, in contrast, PG I remained relatively stable level. We can easily infer from them that maximal PG II level could be achieved at the moderate atrophy, which means maximal neutrophil induced active gastritis would be in that time and naturally the highest chance of diffuse type GC would be supposed to occur, these could be supported by carcinogenesis by unique *H.pylori* induced neutrophilic proliferative zone foveolitis (PNF) and Malgun cell change suggested by Lee^[22], also that is just the moment when *H.pylori* eradication would be the most effective thing for preventing GC.

As Korean physician practicing daily routine screening endoscopy it is natural to pursue practical method to assess the risk of GC by conventional white light endoscopy. Luckily as progression of optical and electronic technology, various mucosal findings have been identified. As for *H.pylori* infection status, Yan *et al.*^[23] and Cho *et al.*^[4] revealed valuable results. Watanabe *et al.*^[24] showed more various and realistic mucosal findings related to current *H.pylori* infection and after *H.pylori* eradication. Nomura *et al.*^[3] assessed gastritis activity and inflammation using the similar mucosal findings suggested by Watanabe *et al.*^[24], they showed that combination of swelling of areae gastrica with diffuse redness in the corpus and swelling of areae gastrica with visible vessel in the antrum were useful findings for neutrophil infiltration in gastric mucosa.

The main concern was endoscopic findings that could be useful to assess the risk of the two GC type (slowly growing intestinal type and rapid progressing diffuse type). Therefore bearing in mind EAB as a yardstick for intestinal type GC and various mucosal patterns for diffuse type GC, we could make reasonable strategy.

Recently Lee *et al.*^[25] revealed PGI and PG I/II ratio decreased significantly as EAB progressed, and we also searched relationships between serology and EAB. Yanaoka *et al.*^[2] showed *H.pylori* eradication was effective for preventing GC only in serologically mild atrophic gastritis, we uncovered which EAB could be matched with upper limit of serologically mild atrophic gastritis, the cut-off value of EAB for group C being above type C-3, this identification was similar to that of several previous studies, however there were differences, first most of previous studies identified serologic values to discriminate open type atrophic gastritis from closed type, we took different approach from opposite side: defining optimal EAB for serologically significant value, second we subdivided EAB in more detail (12 categories) because in Korea endoscopy is more dominant GC screening tool than any other method including serologic study, consequently we need to get much more delicate description for endoscopic findings than just simple delineation of open or closed type. When it comes to therapeutic consideration our result could be partially supported by recent study by Take *et al.*^[26], they reported one of significant factors for prophylactic effect of *H.pylori* eradication against GC was initial endoscopic mild atrophic gastritis (EAB type C-1 and C-2). If we consider *H.pylori* eradication, EAB type C-3 could be a valid limitation [in this study 114 subjects (67%)], and above EAB type C-3 we might consider strict endoscopic follow up [in this study 56 subjects (33%)].

Evaluating mucosal status to make up for weak point of EAB, our finding showed four significant mucosal appearances suggesting serologically active gastritis (Group B- γ or II-30). If endoscopists bump into these mucosal findings, they could recommend *H.pylori* eradication to patient with better confidence.

We could not performed *H.pylori* antibody titer test being originally included in Yoshida *et al.*^[1], this study was based on "Health check-up protocol" not focusing individual active gastritis study

and actually when we made the protocol we referred to watanabe *et al.*^[27] reporting that all cancers in high *H.pylori* titer group belonged to Group B- γ , inevitably some portion of active gastritis subjects in Group B might be omitted and performing genuine Korean active gastritis study would be the way to go. Because we depend on CLO test for *H.pylori* identification, some *H.pylori* positive subjects might be exempted from the study, however we used EAB and various endoscopic findings: we must have tried to find out *H.pylori* by other methods if we had confronted abnormal mucosal findings with negative CLO test (actually all of four subjects who showed no visible EAB had abnormal mucosal patterns), consequently most of the exempted cases might be Group D not Group B and thinking of our main purpose they would not be considered as candidate for primary GC prevention. Unlike Cho *et al.*^[4] our study showed body type B (52.4%) was more frequent than body type A (37.1%), this could be attributed to subjects showing very small sized mosaic pattern, we regarded them as type B. Lymphofollicular gastritis as a rising risk factor for GC did not show statistically significant feature (P-value 0.188, odd ratio 4.0) but we expect larger scale study may improve its significance. We hope better endoscopic GC risk stratification strategy will emerge in the near future.

CONFLICT OF INTERESTS

There are no conflicts of interest with regard to the present study.

REFERENCES

- 1 Yoshida T, Kato J, Inoue I, Yoshimura N, Deguchi H, Mukoubayashi C, Oka M, Watanabe M, Enomoto S, Niwa T, Maekita T, Iguchi M, Tamai H, Utsunomiya H, Yamamichi N, Fujishiro M, Iwane M, Takeshita T, Ushijima T, Ichinose M. Cancer development based on chronic active gastritis and resulting gastric atrophy as assessed by serum levels of pepsinogen and Helicobacter pylori antibody titer. *Int. J. Cancer* 2014; **134**: 1445-1457
- 2 Yanaoka K, Oka M, Ohata H, Yoshimura N, Deguchi H, Mukoubayashi C, Enomoto S, Inoue I, Iguchi M, Maekita T, Ueda K, Utsunomiya H, Tamai H, Fujishiro M, Iwane M, Takeshita T, Mohara O, Ichinose M. Eradication of Helicobacter pylori eradication prevents cancer development in subjects with mild gastric atrophy identified by serum pepsinogen levels. *Int J Cancer* 2009; **125**: 2697-2703
- 3 Nomura S, Terao S, Adachi K, Kato T, Ida K, Watanabe H, Shimbo T; Research Group for Establishment of Endoscopic Diagnosis of Chronic Gastritis. Endoscopic diagnosis of gastric mucosal activity and inflammation. *Digestive Endoscopy* 2013; **25**: 136-146
- 4 Cho JH, Chang YW, Jang JY, Shim JJ, Lee CK, Dong SH, Kim HJ, Kim BH, Lee TH, Cho JY. Close observation of gastric mucosal pattern by standard endoscopy can predict Helicobacter pylori Infection status. *J Gastroenterol Hepatol* 2013; **28**: 279-284
- 5 Kimura K, Takemoto T. An endoscopic recognition of the atrophic border and its significance in chronic gastritis. *Endoscopy* 1969; **3**: 87-97
- 6 Correa P. A human model of gastric carcinogenesis. *Cancer Res* 1988; **48**: 354-3560
- 7 Inoue M, Tajima K, Matsuura A, Suzuki T, Nakamura T, Ohashi K, Nakamura S, Tominaga S. Severity of chronic atrophic gastritis and subsequent gastric cancer occurrence: a 10-year prospective cohort study in Japan. *Cancer Lett* 2000; **161**: 105-112
- 8 Uemura N, Okamoto S, Yamamoto S, Matsumura N, Yamaguchi S, Yamakido M, Taniyama K, Sasaki N, Schlemper RJ. Helicobacter pylori Infection and the development of gastric cancer. *N Engl J Med* 2001; **345**: 784-789
- 9 Quach DT, Le HM, Nguyen OT, Nguyen TS, Uemura N; The severity of endoscopic gastric atrophy could help to predict Opera-

- tive Link on Gastritis Assessment gastritis stage. *J Gastroenterol Hepatol* 2011; **26**: 281-285
- 10 Quach DT, Le HM, Hiyama T, Nguyen OT, Nguyen TS, Uemura N. Relationship between endoscopic and histologic gastric atrophy and intestinal metaplasia. *Helicobacter* 2013; **18**: 151-157
 - 11 Jang SH, Kim KM. Assessment of gastritis using Operative Link for Gastritis Assessment System. *The Korean Journal of Helicobacter and Upper Gastrointestinal Research* 2013; **13(1)**: 20-24
 - 12 Correa P, Houghton J. Carcinogenesis of Helicobacter pylori. *Gastroenterology* 2007; **133**: 659-672
 - 13 Nardone G, Rocco A, Malfertheiner P. Helicobacter pylori and molecular events in precancerous gastric lesions. *Aliment Pharmacol Ther* 2004; **20**: 261-270
 - 14 Vauhkonen M, Vauhkonen H, Sipponen P. Pathology and molecular biology of gastric cancer. *Best Pract Res Clin Gastroenterol* 2006; **20**: 651-674
 - 15 Yanaoka K, Oka M, Yoshimura N, Mukoubayashi C, Enomoto S, Iguchi M, Magari H, Utsunomiya H, Tamai H, Arii K, Yamamichi N, Fujishiro M, Takeshita T, Mohara O, Ichinose M. Risk of gastric cancer in asymptomatic, middle-aged Japanese subjects based on serum pepsinogen and Helicobacter pylori antibody levels. *Int. J. Cancer* 2008; **123**: 917-926
 - 16 Plebani M, Basso D, Cassaro M, Brigato L, Scrigner M, Toma A, Di Mario F, Rugge M. Helicobacter pylori serology in patients with chronic gastritis. *Am J Gastroenterol* 1996; **91**: 954-958
 - 17 Mårdh E, Mårdh S, Mårdh B, Borch K. Diagnosis of gastritis by means of a combination of serological analysis. *Clin Chim Acta* 2002; **320**: 17-27
 - 18 Kiyohira K, Yoshihara M, Ito M, Haruma K, Tanaka S, Chayama K. Serum pepsinogen concentration as a marker of Helicobacter pylori infection and the histologic grade of gastritis; evaluation of gastric mucosa by serum pepsinogen levels. *J Gastroenterol* 2003; **38**: 332-338
 - 19 Watanabe M, Kato J, Inoue I, Yoshimura N, Yoshida T, Mukoubayashi C, Deguchi H, Enomoto S, Ueda K, Maekita T, Iguchi M, Tamai H, Utsunomiya H, Yamamichi N, Fujishiro M, Iwane M, Tekeshita T, Mohara O, Ushijima T, Ichinose M. Development of gastric cancer in nonatrophic stomach with highly active inflammation identified by serum levels of pepsinogen and Helicobacter pylori antibody together with endoscopic rugal hyperplastic gastritis. *Int. J. Cancer* 2012; **131**: 2632-2642
 - 20 Hunter FM, Correa P, Fontham E, Ruiz B, Sobhan M, Samloff IM. Serum pepsinogens as markers of response to therapy for Helicobacter pylori gastritis. *Dig Dis Sci* 1993; **38**: 2081-2086
 - 21 Massarrat S, Haj-Sheykholeslami A, Mohamadkhani A, Zendehtdel N, Aliasgari A, Rakhshani N, Stolte M, Shahidi SM. Pepsinogen II Can Be a Potential Surrogate Marker of Morphological Changes in Corpus before and after H.pylori eradication. *BioMed Research International* 2014; **2014**: 481607
 - 22 Lee IC. Critical pathogenic steps to high risk Helicobacter pylori gastritis and gastric carcinogenesis. *World J Gastroenterol* 2014 June 7; **20(21)**: 6412-6419
 23. Yan SL, Wu ST, Chen CH, Hung YH, Yang TH, Pang VS, Yeh YH. Mucosal patterns of Helicobacter pylori –related gastritis without atrophy in the gastric corpus using standard endoscopy. *World J Gastroenterol* 2010 January 28; **16(4)**: 496-500.
 - 24 Watanabe K, Nagata N, Nakashima R, Furuhashi E, Shimbo T, Kobayakawa M, Sakurai T, Imbe K, Niikura R, Yokoi C, Akiyama J, Uemura N. Predictive findings for Helicobacter pylori –uninfected, -infected and –eradicated gastric mucosa: Validation study. *World J Gastroenterol* 2013 July 21; **19(27)**: 4374-4379
 - 25 Lee JY, Kim N, Lee HS, Oh JC, Kwon YH, Choi YJ, Yoon KC, Hwang JJ, Lee HJ, Lee A, Jeong Y, Jo HJ, Yoon H, Shin CM, Park YS, Lee DH. Correlations Among Endoscopic, Histologic and Serologic Diagnoses for the Assessment of Atrophic Gastritis. *Journal of Cancer Prevention* 2014; **19**: 47-55
 - 26 Take S, Mizuno M, Ishiki K, Hamada F, Yoshida T, Yokota K, Okada H, Yamamoto K. Seventeen-year effects of eradicating Helicobacter pylori on the prevention of gastric cancer in patients with peptic ulcer; a prospective cohort study. *J Gastroenterol* 29 Oct 2014. DOI 10.1007/s00535-014-1004-5.
 - 27 Watanabe M, Kato J, Inoue I, Yoshimura N, Yoshida T, Mukoubayashi C, Deguchi H, Enomoto S, Ueda K, Maekita T, Iguchi M, Tamai H, Utsunomiya H, Yamamichi N, Fujishiro M, Iwane M, Tekeshita T, Mohara O, Ushijima T, Ichinose M. Development of gastric cancer in nonatrophic stomach with highly active inflammation identified by serum levels of pepsinogen and Helicobacter pylori antibody together with endoscopic rugal hyperplastic gastritis. *Int. J. Cancer* 2012; **131**: 2632-2642

Peer reviewers: Natalia Elguezabal, Animal Health Department, NEIKER-Tecnalia, Basque Institute for Agricultural Research and Development, Parque Tecnológico Bizkaia, Edif. 812-L 48160, Derio, Bizkaia, Spain; Michael Kew Lim, Department of Colorectal Surgery, Christchurch Hospital, Riccarton Avenue, Christchurch 8011, New Zealand.

