

Clinical Presentations of Secondary Aortoenteric Fistulae: Case Report and Literature Review

Camille S Thelin, Jared T Geist, John J Hutchings, Daniel L Raines

Camille S Thelin, MS, MD Department of Gastroenterology and Hepatology, Tulane University School of Medicine, LA 70112-2822, USA

Jared T Geist, MD, Gastroenterology Associates, Suite 540 of WK Pierremont Health Center, 8001 Youree Drive, Shreveport, LA

John J Hutchings, MD, Department of Gastroenterology, Louisiana State University Health Sciences Center New Orleans, LA 70112-2822, USA

Daniel L Raines, MD, Department of Gastroenterology, Louisiana State University Health Sciences Center New Orleans, LA 70112-2822, USA

Correspondence to: Camille Thelin, MS, MD, Department of Gastroenterology and Hepatology, Tulane University School of Medicine 1430 Tulane Ave, SL 35, New Orleans, Louisiana, 70112-2822, USA

Email: cthelin1@tulane.edu

Telephone: +1-504-903-1744

Fax: +1-504-988-2188

Received: February 12, 2014

Revised: March 28, 2015

Accepted: April 2, 2015

Published online: May 21, 2015

ABSTRACT

Aortoenteric fistulae (AEF) are a rare and potentially life-threatening cause of upper gastrointestinal bleeding. Here, we present a case of bleeding from a secondary AEF with an unusual pattern. Our case was quite atypical in that our patient had multiple episodes of self-limiting overt bleeding over the course of two years, which is in stark contrast to the paradigm of “herald bleeding” followed by a second catastrophic bleed, which is often fatal in secondary AEFs. We also retrospectively analyzed the literature over the last decade (2002-2012), pulling case reports and reviews that identified patients with secondary AEFs, and the diagnostic methods utilized. We categorized these secondary AEFs by age, sex, time from initial surgery to diagnosis, presenting symptoms, location of fistula, intervention taken, and outcome. The objective was to find the

similarities in these cases and thus propose a diagnostic workup, or guideline, for identifying this specific type of bleed in comparison to other gastrointestinal bleeds. The conclusion remains similar to those of the authors that we reviewed: the initial diagnosis of secondary AEFs—and thus the ability to reduce their complications—remains a problem.

© 2015 ACT. All rights reserved.

Key words: Gastrointestinal bleeding; Secondary; Aortoenteric; Fistula; Obscure; Herald bleed

Thlein CS, Geist JT, Hutchings JJ, Raines DL. Clinical Presentations of Secondary Aortoenteric Fistulae: Case Report and Literature Review. *Journal of Gastroenterology and Hepatology Research* 2015; 4(5): 1618-1626 Available from: URL: <http://www.ghrnet.org/index.php/joghr/article/view/1218>

INTRODUCTION

Aortoenteric fistulas (AEF) are a rare and potentially life-threatening cause of gastrointestinal bleeding (GIB). AEFs can be further subclassified as primary or secondary fistulas.

Primary AEFs are those which occur in patients with no previous aortic surgery or trauma. Most primary AEFs are due to atherosclerotic aortic aneurysms, other causes include infection such as syphilis or tuberculosis. Secondary AEFs are those which are most often caused by graft repair prostheses, which then erode into adjacent bowel, usually the small bowel. Other etiologies include ulcers, tumor invasion, trauma, radiation therapy, and foreign body perforation. It was first reported in 1953 by Brock, while the first successful repair was reported in 1957 by Herberer (Champion, 1981)^[1].

The classical triad of an abdominal AEF was first outlined by Sir Astley Cooper in 1829^[1]. It consists of abdominal pain, a sentinel hemorrhage, followed by a massive gastrointestinal bleed—after an

interval free of symptoms—that can lead to exsanguination. This sentinel hemorrhage is often referred to as the “herald hemorrhage” or “herald bleed,” for this bleed is an indication of something that is going to occur.

In a recent review article, this triad was present only in 11% of patients with primary AEFs^[1]. The time between the sentinel hemorrhage and subsequent bleeding episodes is highly variable ranging from mere hours to months^[1]. This high variability makes diagnosing secondary AEFs a difficult task. The diagnosis of AEF requires a high degree of clinical suspicion and the appropriate clinical setting.

In fact, the diagnostic yield with upper endoscopy is relatively low, around 40%^[1]. However, it is still a necessary test to rule out other more commonly encountered etiologies causing massive upper gastrointestinal bleeding.

The diagnostic yield is increased to approximately 60% when using CT^[1]. Abnormalities typically seen on CT include air adjacent to or within the aorta, and IV contrast seeping into the bowel adjacent to the aorta, or in the case of secondary AEF, extravasation of contrast into the tissue surrounding the graft^[2].

Here, we present a case of bleeding from an AEF with an unusual bleeding pattern. Our case was quite unusual in that our patient had multiple episodes of self-limiting overt bleeding over the course of 2 years. This is in stark contrast to the paradigm of “herald bleeding” followed by second catastrophic bleed, which is often fatal.

We also reviewed the case literature over the last decade, pulling case reports that identified patients with secondary aortoenteric fistulas, in order to garner further information on classical presentation of patients.

CASE REPORT

A 72-year old white male, with a history of HLD, AAA repair, diverticular bleed status post a subtotal colectomy, CAD, and HTN was referred to our facility with recurrent episodes of obscure overt GIB, manifesting as melena.

The patient had an extensive workup prior to admission including multiple upper endoscopies, colonoscopies, capsule endoscopy, double balloon enteroscopy, and a tagged red blood cell scan were ordered, which failed to reveal a bleeding source. Even previous exploratory laparotomy had also been performed to exclude a secondary AEF and was reportedly negative, as was the patient’s physical exam. Overall, the patient had required multiple admissions for blood transfusions over a year, receiving upwards of 30 units in all.

At his last admission at our facility, his initial hemoglobin and hematocrit was 10.7 and 30.8, respectively. The following day, he underwent an upper and lower double-balloon enteroscopy; this was performed with heparin provocation, intraprocedurally. Again, no bleeding source was discovered.

With no source identified, the patient was scheduled to be discharged, however immediately prior to discharge, he again developed hematemesis. Push enteroscopy was performed and the presumed fistulous tract associated with adherent blood clot was discovered (Figure 2: Push enteroscopic images showing a suture confirming presence of aortoenteric fistula—marked by red arrows—and the cause of the patient’s recurrent obscure overt gastrointestinal bleeding).

A CT scan of the abdomen and pelvis was performed and confirmed the presence of the fistulous tract associated with fusiform aneurysm of the abdominal aorta (Figure 1: axial and sagittal images, respectively, of CT A/P with IV and PO contrast revealing an

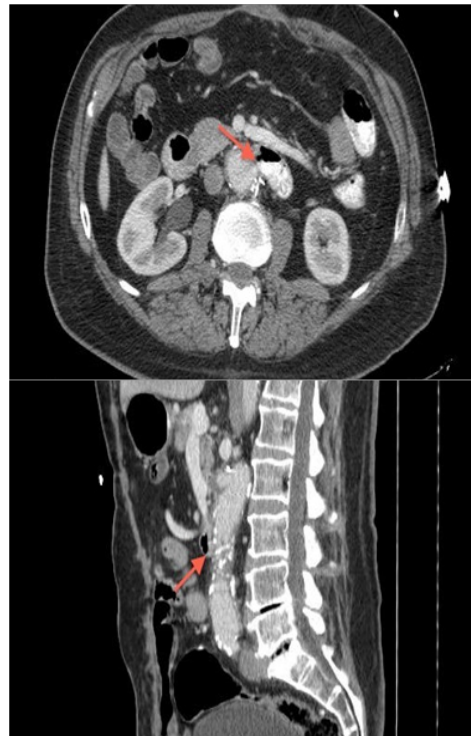

Figure 1 CT scan of abdomen and pelvis with IV and PO contrast revealing an infrarenal saccular aneurysm with direct connection to the third portion of the duodenum (arrow).

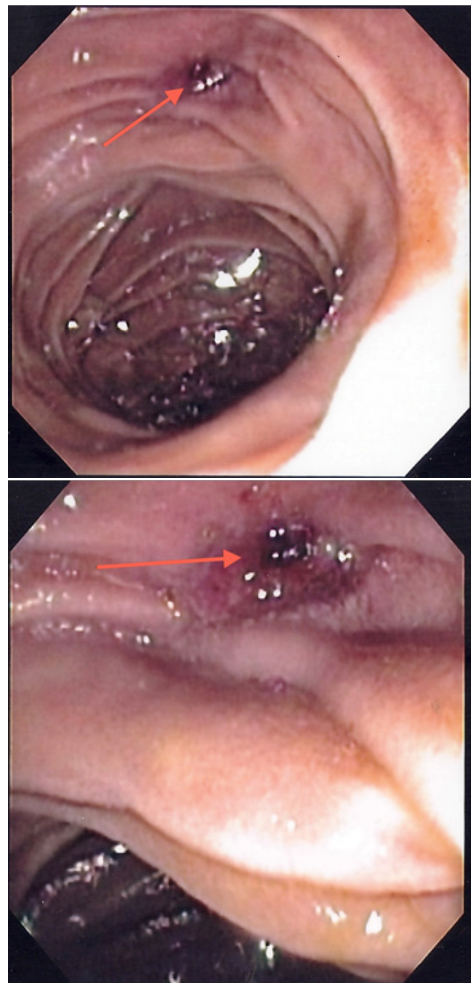


Figure 2 Push enteroscopy showing a suture confirming presence of aortoenteric fistula and the cause of the patient’s recurrent obscure overt gastrointestinal bleeding (arrow).

infrarenal saccular aneurysm—marked by red arrows—with direct connection to the third portion of the duodenum).

CT surgery and cardiology were consulted and a Gore ELG cuff was placed endovascularly to repair the fistula. The patient was able to be discharged soon thereafter with no complications. At follow-up, the patient has had no recurrence of GI bleeding.

METHODS

Using the search engine Entrez PubMed and the MESH terms “secondary aortoenteric fistula,” data was collected from case reports over a ten-year period, from 2002-2012. The search produced 43 articles that had been filtered for English translation and human species. Eleven articles were excluded for including information only about primary aortoenteric fistulas. Some of the articles included several case reports within, and therefore a total of 42 patients were involved in this study.

Each case report was categorized into a spreadsheet including categories for age, sex, time from initial surgery to diagnosis of secondary AEF, presenting symptoms, location of secondary AEF, intervention taken, and outcome. The following discussion summarizes that data (Table 1).

RESULTS

From 2002 to 2012, 42 patients were identified with secondary AEFs. The time from initial operation to time of diagnosis of secondary AEF was quite drastic: from one day to 20 years (unknown, $N=8$). The majority of patients were men (35:7, male:female), with an age range from 35-91 years old (mean age = 70 years old).

Preoperative diagnosis was made using several tools, including EGD, colonoscopy, multi-detector CT (MDCT), single-detector CT A/P with contrast, single-detector CT A/P without contrast, angiography, virtual endoscopy, and even in one case, autopsy. (Only 33 of 42 case reports mentioned diagnostic tools.)

Of the diagnostic tools used, the abdominal/pelvic CT scan was used on 21 patients. It was initially positive in 15 cases (5/15 were MDCT), and initially negative in 6 cases (1/6 was MDCT). There were a total of 4 repeat single-detector CT scans, with only 50% being positive ($N=2/4$). Therefore, CT scan confirmed the source in 45.5% of patients in which diagnostic tools were mentioned ($N=15/33$). Interestingly, five patients benefited primarily from the contrast used in CT scanning and not the scan itself, for the secondary AEF was identified due to extravasation of contrast (either Visipaque or Gastrografin).

In contrast, CT angiography was used on 13 patients; only 2 were negative for fistula and/or extravasation. Thus, it was positive in 11/13 patients, confirming the source of the fistula in 33.3% of total patients in which diagnostic tools were mentioned ($N=11/33$).

The EGD was performed on 20 patients. It was initially positive for fistula in only 5 patients, while being negative for 15 patients. There were a total of 4 repeat EGDs; with 100% being negative for fistula, while 50% identified ulcers. Thus, EGD only confirmed the source in 15% in which diagnostic tools were mentioned ($N=5/33$). (It should be noted that the esophagus was the site of a secondary AEF in one patient, during which the EGD easily identified the site.)

Similarly, the colonoscopy was only successful in identifying two cases of fistulas; and thus confirming the source in 6% of patients in which diagnostic tools were mentioned ($N=2/33$). (It should be noted that the sigmoid and rectum were the sites of fistulization in two patients, during which the above-mentioned colonoscopies easily identified the source.)

Overall, the duodenum was most common the site for the identified fistulas; it represented 82.9% of patients included in the case reports ($N=29/35$; unknown, $N=7$). One patient even had multiple duodenal fistulas. Of those 29 patients, the third portion of the duodenum was revealed as most commonly involved in secondary AEF ($N=11$); the second portion of the duodenum was identified in 3 patients and the fourth portion in 2 patients. Other sites for the AEFs included esophageal ($N=1$), jejunum ($N=2$), appendiceal ($N=1$), sigmoid ($N=1$), and rectal ($N=1$). One interesting case even mentioned a fistula distal to the Ampulla of Vater, at the junction of the common bile duct and main pancreatic duct.

Of all 42 patients reviewed, 22 presented with a “herald bleed,” the classical presentation aforementioned. Thus, the herald bleed was evident in 52.4% of patients included ($N=22/42$). And while not qualified as a herald bleed in the case reports, 10 patients had some type of “rectal bleeding/LGIB,” 18 had “melena,” 14 had “hematemesis/hematochezia/upper GI bleed,” and five had nondescript “GIB.” Unfortunately, the mean length of bleeding was non-calculable, as most case reports did not mention the duration of the bleed.

Those not presenting with a herald bleed, or GIB of some sort, presented with either abdominal pain ($N=6$), nondescript back pain ($N=5$), lower extremity pain and/or ischemia ($N=3$), weight loss ($N=2$), fever ($N=10$), small bowel obstruction ($N=1$), infection (ranging from leukocytosis with elevated CRP, to purulent abscesses near graft sites, to osteomyelitis, to bacteremia, and finally to sepsis; $N=8$), hypovolemia/hypotensive shock ($N=8$), or syncope ($N=2$).

Once patients were identified as having a secondary AEF, they underwent treatment. Thirty-three of the 42 had excision of the original stent-graft and endovascular repair, while nine patients either underwent conservative treatment with antibiotics and blood product resuscitation, or died on the way to the OR ($N=2$). Some even opted for no treatment at all ($N=4$).

Overall there were 17 deaths and 8 unknown outcomes. However, the outcome was not grim for all patients: 20 of the 42 patients were recorded as being healthy at follow-up. The shortest follow-up period recorded was at two months, while the longest was at six years.

DISCUSSION

While many agree on the diverse presentation of those presenting with a secondary AEF, there is little concise information available on properly identifying these patients ahead of a fatal bleed. The reason is that there are several rate-limiting steps that influence each patient differently: including time from original surgery, length of bleed once noticed, and methods used to identify the source of that bleed.

This retrospective study initially set out to prove that there were similarities in the presentations of these patients, and thus, there could be a set diagnostic workup or guideline for identifying a bleed from a secondary AEF versus another type of gastrointestinal bleed. The objective was to reduce complications from secondary AEFs, for they can often be calamitous.

However, one of our major setbacks included that most of the case reports reviewed are surgical in nature, and not gastroenterological. Thus, the focus of the reports is mainly on the types of interventions made once a secondary AEF was identified and not on the methods of identification, nor the presentation of the patient. These details would have influenced the acuity of detection of a secondary AEF bleed, and thus our conclusions are hindered from lack of detail. The main hindrance being that the case reports do not properly identify the interval of time from the initial “sentinel” bleed to the second large bleed.

Table 1 Summary of case reports reporting secondary aortoenteric fistula from 2002-2012.

Case Report	Diagnostic tool	Pt Info	Time from Surgery to Diagnosis of AEF	Presenting symptoms	Herald Bleed?	Location of fistula	Intervention	Outcome	Obscure Facts
Solomon B, et al[13] (2012)	CT angiography +	78 M	6 yrs	2-week history of abdominal pain, fever, and anemia	No	Duodenal	Percutaneous drainage; duodenoduodenectomy; wide debridement	Expired 6mo post-op (unrelated events)	AEF associated with Pott's disease (2nd lumbar vertebral body) + adjacent psoas abscess
Tan GW, et al[14] (2012)	EGD/C-scope -; 3mo later: CT aortogram +	79 M	9 yrs (?)	Rectal bleeding x1	Yes	Duodenal (3rd part)	Endovascular aortic stent-graft insertion; stent-grafts to renal arteries; B/L chimney laparotomy for debridement	7mo f/u healthy	Tan GW, et al
Kakkos SK, et al[15] (2011)	Unknown	70 M	9 mo	Recurrent bleeding	No	Duodenal	Axillofemoral bypass graft, removal prostheses, closure of aortic stump & duodenal defect	Death POD#5	B/L chimney stent grafts to renal arteries
Tse DM, et al[16] (2011)	EGD, C-scope -; CT colon +; CT aortogram +	91 M	9 yrs	Rectal bleeding x3 occasions within 1month period	No	Aorto-appendiceal	CT abdomen; endovascular repair with aorto-uni-iliac device with a femoral-femoral crossover graft	6 mo f/u healthy	Developed lumbar spine osteomyelitis 2/2 AEF
La Greca G, et al[17] (2011)	C-scope +; EGD -; CT angiography +	71 M	6 yrs	Recurrent fever & x1 episode rectal hemorrhage	Yes	Duodenum (Treitz's ligament)	Debridement of large necrotic tissue, graft removal, aortic defect closed, fistula excised, Roux-en-Y gastrojejunostomy	9 mo f/u healthy then...	La Greca G, et al
Chari, et al[18] (2011)	EGD +; confirmed by CT A/P+	86 M	8 yrs	Melena, hypotension, hematemesis (HGB 6.5/24)	Yes	Duodenal sutures	Fistula excised, aortic defect repaired, omental flap interposed b/w sutured duodenum and aorta	1yr f/u healthy	RAEF (recurrent 2AEF)
Djoric P, et al[19] (2010)	CT angiography +; C-scope +; EGD -	71 M	6yrs	Hematemesis, fevers, rigors; BCx neg so DC --> 1yr later 4d h/o	No	Duodenal (2nd part)	Emergent placement of bifurcated Zenith stent graft	Septicemia; B/L bronchoPNA	
Yang, et al[20] (2010)	EGD -; CT A/P +	73 M	8 yrs	Recurrent rectorrhagia/ chronic bleeding cutaneous fistula L groin	Yes	Duodenal (3rd part)	Aortic graft excision, infrarenal aortic stump closed with retrocolic greater omentum flap coverage, segmental excision of 3rd-4th duodenal and primary duodenojejunal anastomosis	1yr f/u healthy	
Kibria R, et al[21] (2010)	EGD -; CT A/P +	78 F	Unknown	Intermittent fevers with leukocytosis x 2 mo	No	Jejunum	Right subclavian-bifemoral extra-anatomic bypass with an 8mm ringed-PTFE graft, followed by repair of the jejunal fistula, excision of the graft and closure of the aortic stump	Refused surgery; expired 1mo later in hospice	
Luo CY, et al[22] (2010)	CT A/P, EGD, C-scope -; repeat CT A/P -; 2nd C-scope +	62 M	6 wks	Recurrent sepsis (3mo h/o Enterobacter cloacae)	No	Distal duodenum	Emergency surgery-left infected aortoiliac artery excision, oversewing the aortic stump, right axillofemoral bypass, and sigmoid colectomy with an end-colostomy-was performed	45mo f/u healthy	Site of fistula
Killeen RP, et al[23] (2009)	MDCT A/P +	79 F	3 yrs	Repeated bloody stools	Yes	Rectal		Full recovery s/p surgery	
Roche-Nagle, et al[24] (2009)	Unknown	79 M	Unknown	SBO: hyperactive bowel sounds and epigastric discomfort	No	Jejunum	Emergent surgery	Unknown	
				GIB unknown specifics	No	Unknown	Endovascular surgery		

Table 1 Summary of case reports reporting secondary aortoenteric fistula from 2002-2012.									
Case Report	Diagnostic tool	Pt Info	Time from Surgery to Diagnosis of AEF	Presenting symptoms	Herald Bleed?	Location of fistula	Intervention	Outcome	Obscure Facts
Ozguç H, et al[25] (2008)	Unknown	34 M	Unknown	Massive LGIB (massive hematochezia and HD instability)	Yes	SB (not specified)	Emergent surgery; prosthesis wrapped with vascularized pedicle of omentum that passed through mesentery of transverse colon	15mo f/u excellent condition	Patient with h/o Behcet disease Dx 8mo prior
de Loos ER, et al[26] (2008)	CT angiography (intra-operative) +	44 M	10yrs	Unresponsive hypovolemic shock 2/2 bleeding	Yes	Unknown	Endovascular surgery with extra-anatomical bypass; spontaneous regression of fistula 12mo later	44 mo f/u good condition; refused further surgery	Extra-anatomical revascularization of Les
Civilimi E, et al[27] (2008)	Unknown	35 M	Unknown	Fever, thoracic pain, several episodes of GIB	Yes	Esophageal (mid thorax)	Unfit for endovascular surgery 2/2 comorbidity	Hospitalized then de-compensates on D#2 --> sent OR	Esophageal fistula
Alkim H, et al[28] (2008)		Same patient	POD 2	Severe shock, respiratory distress, severe GIB			Endovascular surgery	5mo f/u healthy	
		35 M	9 mo	Back/LLE, pain x1.5mo; F/Cx15d; FOBT negative	No	None found	None	D/C with Abx	Behcet's disease
		Same patient	1 yr	Severe back/LLE; increasing F/C; fatigue/weight loss; FOBT negative; bacteremic	No	None found	None	D/C with Abx	
		Same patient	1 yr 3 mo	Massive UGIB	Yes	2nd-3rd part duodenum	Graft excised; new tubular hemo-shield graft inserted omentoplasty	6mo f/u c distal anastomic site aneurysm	
		Same patient	1 yr 7 mo	Hypotensive crisis	No	Anastomic site (unknown)	Total graft excision/ aortic closure/ axillobifemoral extra-anatomic bypass	6yr f/u healthy	
Mohammadzade MA, et al[29] (2007)	CT A/P +; U/S +; ex-lap +	77 M	6yrs	Hematemesis/ melena	Yes	Unknown	Duodenorrhaphy and aortic reconstruction with patch graft at proximal suture line of aortic prosthesis; omentoplasty	Unknown	
Sharif MA, et al[30] (2007)	CT scan +	67 M	10 mo	Profuse sweating, backache, feeling of malaise, stable H/H	No	Duodenum (multiple)	Unsuccessful code resuscitation	Perished	
	CT scan +	70 M	4 mo	Epigastric discomfort, fever, melena	Yes	Unknown	Conservative treatment 2/2 aggressive myelodysplastic condition/ poor prognosis	Perished 2mo later; no postmortem exam	h/o Crohn's disease; h/o aggressive myelodysplastic condition
Kotsis T, et al[31] (2006)		53M	9 yrs	Fatigue; acute LLE ischemia; no melena; no hematemesis	No		Angiography	Surgery	
		Same pt	POD 1	After angiography/transfusion → massive melena	No	3rd part duodenum	Endovascular surgery with LLE reperfusion	10 mo f/u healthy	
Verhey P, et al[32] (2006)	Visceral arteriography #1 -; ER angiography c lateral abd aortogram +	66 F	8 yrs	UGIB	No	Duodenal	Aortic Endograph	6 mo f/u healthy	Eroded duodenal stent

Table 1 Summary of case reports reporting secondary aortoenteric fistula from 2002-2012.

Case Report	Diagnostic tool	Pt Info	Time from Surgery to Diagnosis of AEF	Presenting symptoms	Herald Bleed?	Location of fistula	Intervention	Outcome	Obscure Facts
Shapiro M, et al[33] (2006)	Unknown	83 F	Unknown	Hypertensive, tachycardic, anemic, and leukocytic	Yes	Duodenal	Stent graft exclusion of the aortoduodenal fistula to control the acute bleeding; stent graft repair of aortoduodenal fistula	1yr f/u healthy	
Biancari F, et al[34] (2006)	EGD --> duodenal ulcer; confirmed c CT A/P	51 M	Unknown	Hematemesis, melena, leukocytic	Yes	Duodenal (3rd part)	X-Lap with graft resection	8mo f/u healthy	
Yoshimoto K, et al[35] (2005)	MDCI --> virtual endoscopy +	64 F	9 yrs	Fever, bacteremic	No	3rd part duodenum	Segmental resection of the duodenum and duodenojejunal bypass; prosthesis exposed in duodenum wrapped with a vascularized pedicle	Unknown	
Kastinelos P, et al[36] (2005)	EGD -; repeat EGD too much blood to ID site; urgent ex-lap --> died	72 M	Unknown	3d h/o melena	Yes	3rd part duodenum	Ex-lap	Perished of massive bleeding 2/2 dissection	
	EGD-; autopsy +	69 M	7yrs	Hematemesis/ melena	Yes	3rd part duodenum	Transfused 4u pRBCs --> scheduled for angiography	Perished 3d later	
	EGD-; CT A/P contrast --> extravasation	73 M	3yrs	Hematemesis/ melena/ circulatory instability; 3 episodes melena previous mo	Yes	2nd part duodenum	Transfused 3u pRBCs --> EGD --> scheduled for laparotomy	Perished prior to laparotomy 2/2 massive bleed	
	EGD-; CT A/P (4d later) --> extravasation	72 M	4yrs	Upper abdominal pain radiating to back, fever, syncope, several episodes melena; extravasation of enteric contrast	Yes	Unknown	Transfused 3u pRBCs --> EGD --> CT c contrast --> Immediately transferred to OR	Perished 2/2 massive bleed	
	EGD- (repeatedly); CT A/P c contrast -; aortography/ scintigraphy -; repeat EGD --> duodenal ulcer	73 M	3 yrs	Melena x5 during 1yr	Yes	Distal to papilla of Vater	Aortography and scintigraphy c radiolabeled red cells	Perished 2/2 massive bleed	
	EGD+; confirmed with CT A/P c contrast+	82 F	5 yrs	Melena POD#7 s/p transtrochanteric fx of R femur	Yes	2nd part duodenum	Emergent AEF --> transferred to OR	Perished 2/2 massive bleed	
Perez RO, et al[37] (2005)	C-scope +	62 M	Unknown	LGIB	Yes	Sigmoid colon	Laparotomy		Presentation in sigmoid colon
	CT A/P c gastrografin --> extravasation	72 F	6wks	Paraprostatic extravasation of enteric contrast; fever, leukocytosis, abd pain, purulent groin drainage	No	Duodenum	Removal of infected graft and aorto-to-popliteal bypass graft	Wks s/p healthy	
Limani K, et al[39] (2005)	EGD+, CT A/P and MRI precluded pseudoaneurysm	71M	20 years	Recurrent hematemesis/melena/ general fatigue	Yes	Duodenum (3rd part)	Prosthesis removal/bowel resection with gastrojejun Roux	Unknown	Gastrojejunal primary anastomosis associated with the case

Table 1 Summary of case reports reporting secondary aortoenteric fistula from 2002-2012.

Case Report	Diagnostic tool	Pt Info	Time from Surgery to Diagnosis of AEF	Presenting symptoms	Herald Bleed?	Location of fistula	Intervention	Outcome	Obscure Facts
Perks FJ, et al[40] (2004)	EGD -, MDCT angiography +	82M	5 yrs	Hematemesis/ melena/ fresh rectal bleeding/ lumbar pain	Yes	3 rd part duodenum	Transferred for surgery	Perished in transit to OR	
	EGD, precontrast MDCT -, MDCT angiography --> extravasation; confirmed c ex-lap	74M	8 wks	Large volume of hematemesis and melena	Yes	3 rd part duodenum	Laparotomy	Continued hemorrhage prevented tx --> died	
	Unknown	63M	8yrs	Collapse, melena, and large-volume bleeding per rectum 8 days	Yes	Duodenum	Emergent laparotomy; replacement graft	Unknown	
Puwaneswary M, et al[41] (2003)	P c contrast --> extravasation	78M	10yrs	Abdominal pain and LGIB	Yes	Duodenal (3 rd part)	Laparotomy	POD #1 MI with death	
del Pozo AJ, et al[42] (2003)	EGD+ for blood clot, which was removed and fistula found	72M	14 mo	Fever/ melena	No	Duodenum	Graft resection/ axillary- iliac bypass	4mo f/u healthy	
Kar B, et al[43] (2002)	CT A/P, MRI, repeat CT -, ex-lap --> "presumed AEF"	76M	23 mo	Fever, weight loss, leukocytosis	No	Duodenum	Excision of stent-graft	1yr f/u healthy	Presumed aortoenteric fistula; EGD showed healed duodenal perforation; no bleed
Roos JE, et al[44] (2002)	EGD/C-scope -; repeat EGD + fresh blood/0 source; MDCT (Visipaque) +	69M	13 yrs	x2 discrete GIB treated conservatively; 3wks prior to admission --> melena; DOA: severe hematemesis/ hematochezia	Yes	Duodenum	Transfusion pRBCs/FFP/plasma expander; endovascular stent grafting	Unknown	
Chang MW, et al[45] (2002)	Emergent CT+ -->exploratory laparotomy	81M	20 days	Massive melena/ hematemesis (coffee-ground in NGT)	Yes	Duodenum (4th part)	Previous woven graft removed; duodenal continuity reconstructed; extra-anatomical vascular bypass (R axillary-bifemoral bypass) performed	Death POD#2 2/2 hypovolemia	

Key: 2/2, secondary to; (-), negative for fistula; (+) positive for fistula; C-scope, colonoscopy; DOA, dead on arrival; EGD, esophagogastroduodenoscopy; GIB, gastrointestinal bleed; L, left; LLE, left lower extremity; LGIB, lower gastrointestinal bleed; mo, months; NGT, nasogastric tube; pt, patient; POD, post-operative day; R, right; yrs, years.

As we stand now, the main diagnostic workup for suspected secondary AEF is influenced by the presence of active bleeding alongside hemodynamic instability. The problem with this current standard is that many patients fail to be properly identified for treatment with the initial herald bleed. And thus, these patients find themselves in a code-like situation and then perish, as was seen in our study: 17/34 (unknown outcome, $N = 8$) passed away secondary to a massive bleed prior to receiving surgical attention, representing 41%.

This diagnostic delay, which often enough leads to fatality, is mainly due to an initial low index of suspicion, a benign-looking GIB, a lengthy elapsed time between primary surgery and bleed throwing focus towards another culprit, difficulty in viewing the most common site of fistulization (duodenal) with using EGD, and most of all, atypical, nonspecific manifestations[5,10].

Another characterization flaw commonly found in these case reports was that GIB is defined differently by the authors; some authors do not even describe the type of GIB. GIB was defined using many different terminologies, such as “acute rectal bleeding,” “rectorrhagia,” “hematochezia,” “melena,” “hematemesis,” “bloody stools,” “GIB,” “LGIB,” and “UGIB.”

While review articles state that infection is the most common frequent fistula precipitant and note sepsis as the predominant clinic manifestations of early stages of fistula formation, our study showed that most patients actually did present with bleeding as the most common presentation[5,6,10]. We calculated that 22 patients presented with a herald-like bleed from the case reports, thus representing 52.4% of the patients involved ($N = 42$). This does not quite validate the Armstrong PA, *et al* review (2005), where 18/25 patients (72%) experienced a herald bleed, but yet is more supportive than the claim of Alankar S, *et al* (1999), Heikkinen L, *et al* (2003), and Busuttill SJ, *et al* (2001) who state that most herald bleeds are self-limiting and thus are easily missed[4-6,9]. Thus, we conclude as many before us in those patients with previous aortic grafts and a presentation of some type of GIB, a secondary aortoenteric fistula should be at the forefront of the differential diagnosis. We might go so far as saying that it should be assumed, and that diagnostic imaging should be used to corroborate that assumption.

Source identification of this bleeding was mainly done using CT scan methods (61.9%; $N=21$), unlike that which some previous review articles conclude: for example, T, *et al* (2011) concluded that the most frequent tool was UGI endoscopy; and Chenu C, *et al* (2008) stated that CT scan only confirmed diagnosis in 33 patients (80% cases reviewed)[3,7]. Meanwhile, Armstrong PA, *et al* (2005) agreed that CT was appropriate diagnostic method, and found that 26/28 patients (93%) demonstrated CT abnormalities consistent with AEF and calculated a 93% sensitivity of detecting AEF[9]. Baril D, *et al* (2002) also showed that CT scans were appropriate for identification, with 12/14 patients (85.7%) showing abnormalities indicative of AEF (ie, loss of fat plan between the intestine and aorta, air or fluid around the aorta, or a direct visualization of a communication between the intestinal lumen and aorta)[8]. And while we agree that the CT scan is the preferred initial diagnosis test for those with secondary AEF and that the EGD has less sensitivity than CT scan (our study found 15/21 CT scan initially positive and only 5/20 EGD initially positive), the bottom-line remains that not one single diagnostic tool yields >80% specificity and sensitivity[11-12].

Thus, while the overall aim of this retrospective study was to provide a diagnostic guideline in identifying patients with secondary AEFs based on similarities in their presentation, we have instead ended up supporting the conclusion of those aforementioned reviews, which states that the initial diagnosis of secondary AEFs—and thus

the ability to reduce their complications—remains a problem.

We urge our colleagues to be specific in their descriptions of these secondary AEF presentations in future case reports. We suggest including clinical history (age, sex, original surgery), physical findings (paying special attention to presenting symptoms—specifically, if there was there a herald bleed, type of GIB and length of time), duration of original implant to secondary AEF, secondary AEF location, duration of secondary AEF symptoms to treatment, intervention, and outcome in these case reports.

If perhaps we can obtain a type of standardization in writing up these case reports, then perhaps we might be able to achieve this study’s goal in retrospectively reviewing the literature and finding a common theme in the presentation of secondary AEF, so as to save these patient’s lives.

ACKNOWLEDGMENTS

Author contributions: Hutchings conceived and designed the study; Thélin and Geist performed acquisition of the data through Entrez PubMed; Geist wrote the case report and provided the images; Thélin analyzed and interpreted the data, and drafted the abstract and manuscript; Hutchings revised and edited the manuscript; Raines was the attending doctor for the patient and gave final approval of the version to be published.

CONFLICT OF INTERESTS

There are no conflicts of interest with regard to the present study.

REFERENCES

- 1 Saers SJ, Scheltinga MR. Primary aortoenteric fistula. *Br J Surg* 2005; **92**: 143-52. [PMID: 15685700. doi: 10.1002/bjs.4928]
- 2 Vu QD, Menias CO, Bhalla S, Peterson C, Wang LL, Balfé DM. Aortoenteric fistulas: CT features and potential mimics. *RadioGraphics* 2009; **29**: 197-209. [PMID: 19168845. doi: 10.1148/rg.291075185]
- 3 Simon T, Feller E. Case Report: Diverse Presentation of Secondary Aortoenteric Fistulae. *Case Rep Med* 2011;406730. [PMID: 22242028. doi: 10.1155/2011/406730]
- 4 Alankar S, Barth MH, Shin DD, Hong JR, Rosenberg WR. Aortoduodenal fistula and associated rupture of abdominal aortic aneurysm after endoluminal stent graft repair. *Journal of Vascular Surgery* 2003; **37**(2): 465-468. [PMID: 12563224. doi: 10.1067/mva.2003.81]
- 5 Heikkinen L, Valtonen M, Lepantalo M, Saimanen E, Jarvinen A. Infrarenal endoluminal bifurcated stent graft infected with *Listeria monocytogenes* *Journal of Vascular Surgery* 1999; **29**(3): 554-556. [PMID: 10069921. doi: 10.1016/S0741-5214(99)70285-5]
- 6 Busuttill SJ, Goldstone J. Diagnosis and management of aortoenteric fistulas. *Seminars in Vascular Surgery* 2001; **14**(4): 302-311. [PMID: 11740838. doi: 10.1053/svas.2001.27888]
- 7 Chenu C, Marcheix B, Barcelo C, Rousseau H. Aortoenteric Fistula after endovascular abdominal aortic aneurysm repair: case report and review. *European Journal of Vascular and Endovascular Surgery* 2009 **37**(4): 401-406. [PMID: 19211278. doi: 10.1016/j.ejvs.2008.11.037]
- 8 Baril DT, Carroccio A, Ellozy SH, Palchik E, Sachdev U, Jacobs TS, Marin ML. Evolving strategies for the treatment of aortoenteric fistulas. *J Vasc Surg* 2006.**44**(2): 250-7. [PMID: 16890849. doi: 10.1016/j.jvs.2006.04.031]
- 9 Armstrong PA, Back MR, Wilson JS, Shames ML, Johnson BL, Bandyk DF. Improved outcomes in the recent management of secondary aortoenteric fistula. *J Vasc Surg* 2005; **42**: 660-666. [PMID: 16242551. doi: 10.1016/j.jvs.2005.06.020]

Thelin CS *et al.* Bleeding Patterns Observed in Aortoenteric Fistulae

- 10 D. Bergqvist, H. Björkman, T. Bolin, P. Dalman, J. Elfström, O. Forsberg, L. Johansen, S. Karacagil, P.-Å. Karlqvist, T. Länne, G. Plate, E. Ribbe, L. Spangen, J. Stenbaek, M. Thomsen, B. Wiklund, K.-A. Ångquist. Secondary aortoenteric fistulae-changes from 1973 to 1993. *Eur J Vasc Endovasc Surg* 1996; **11**: 425-428. [PMID: 8846176. doi: 10.1016/S1078-5884(96)80175-4]
- 11 Champion MC, Sullivan SN, Coles JC, Goldbach M, Waltson WC. Aortoenteric fistula. Incidence, presentation recognition, and management. *Ann Surg* 1982; **195**: 314-317. [PMID: 7059240. doi: 10.1097/00000658-198203000-00011]
- 12 Montgomery RS, Wilson SE. The surgical management of aortoenteric fistulas. *Surg Clin North Am* 1996; **76**: 1147-1157. [PMID: 8841369. doi: 10.1016/S0039-6109(05)70503-X]

Peer reviewer: Francis Seow-Choen, Director, Seow-Choen Colorectal Centre, 290 Orchard Road, Paragon #06-06 Singapore.

