

## Endoscopic Management of Benign Biliary Strictures

Alberto Tringali

Alberto Tringali, SC Endoscopia Digestiva Ed Interventistica, Ospedale Niguarda Ca Granda, Milano, Italy

Correspondence to: Alberto Tringali, SC Endoscopia Digestiva Ed Interventistica, Ospedale Niguarda Ca Granda, Milano, Italy

Email: [albertotringali@hotmail.com](mailto:albertotringali@hotmail.com)

Telephone: +390264442770 Fax: +390264442901

Received: December 3, 2014 Revised: May 12, 2015

Accepted: May 16, 2015

Published online: July 25, 2015

### ABSTRACT

Benign biliary stricture result from different group of diseases with variable natural history. Table 1 lists the common causes of benign biliary stricture. Post-operative and inflammatory stricture are the most common. Endoscopic retrograde cholangiopancreatography (ERCP) has become a golden standard for treating benign biliary strictures. ERCP for the treatment of BBS is preferred over surgery and the percutaneous approach due to its low invasiveness, because it is safer and repeatable. Percutaneous approach can be useful in case of failure of ERCP for “rendezvous” techniques, in patients with surgically modified anatomy and non-accessible papilla. Multistenting procedure has been proven efficacy and safe treatment for benign biliary strictures. Despite significant advances in endoscopic techniques, differentiating malignant from benign strictures can still be challenging and chronic pancreatitis as well as non-anastomotic stricture post liver transplantation as cause of benign biliary strictures remain resistant to endoscopic treatments. The short term outcome following endoscopic treatment of benign biliary stricture is excellent but long-term outcome is poor mainly for high rate of recurrence. The use of covered metallic stents for the treatment of benign biliary strictures is still under investigation, clinical trials are underway to establish the best approach to the

treatment of the benign biliary stricture. This article focuses on the endoscopic management of benign biliary strictures and elaborates on optimal treatments strategies for the more common causes.

© 2015 ACT. All rights reserved.

**Key words:** Biliary Tract Diseases [C06.130] Common Bile Duct Diseases [C06.130.120.250] Cholangiopancreatography, Endoscopic Retrograde ERCP; Primary Sclerosing Cholangitis; Pancreatitis, Chronic [C06.689.750.830] Liver Transplantation [E04.210.650]

Tringali A. Endoscopic Management of Benign Biliary Strictures. *Journal of Gastroenterology and Hepatology Research* 2015; 4(7): 1671-1683 Available from: URL: <http://www.ghrnet.org/index.php/joghr/article/view/1303>

### TABLE 1

#### 1. Causes of Benign Biliary Stenosis

##### *Post-operative*

Cholecystectomy

Hepatic resection

Biliary Anastomosis

Liver transplantation

Biliary reconstruction

Biliary enteric anastomosis (hepatico-jejunostomy, choledocho-jejunostomy, pancreaticoduodenectomy (Whipple procedure)

Percutaneous therapy for hepatocellular carcinoma (HCC): trans catheter arterial chemoembolization (TACE); radiofrequency ablation (RFA), percutaneous ethanol injection (PEI)

#### 2. Inflammatory

Chronic Pancreatitis and pseudo cyst

PSC

Autoimmune cholangiopathy (IgG 4 cholangiopathy)

Vasculitis ( LES, Behcet)

Post-radiation therapy

**3. Infections** (e.g. recurrent bacterial cholangitis; *Ascaris lumbricoides*, *clonorchis sinensis*, *opisthorchis viverrini*, tuberculosis, histoplasmosis, schistosomiasis, CMV, HIV, parasites)

**4. Ischemic**

A. Hepatic artery thrombosis or stenosis

B. Prolonged trasplantation organ ischemic: cold and warm ischemic times

C. Portal biliopathy

**5. Post-traumatic**

Blunt abdominal trauma

Motorized vehicle accident

**6. Others**

A. Mirizzi syndrome

B. Post -biliary sphincterotomy

C. Post-treatment of biliary lymphoma

D. Papillary mucinous biliary tumor

**INTRODUCTION**

The benign biliary strictures are a topic in continuous evolution. The differentiation between benign and malignant strictures is not always so simple and requires integration of more diagnostic techniques. Endoscopic treatment is the gold standard although the recurrence rate in especially situations such as stenosis from chronic pancreatitis and non- anastomotic post liver transplant is still high. The technique of multistenting remains the standard treatment. Treatment with metallic endoprosthesis in refractory strictures is promising though still burdened by a high rate of migration. The new metallic stent may reduce the rate of migration by allowing the use of these stents in the near future as a first choice. In this review we assessed the best diagnostic and therapeutic approach to benign biliary strictures.

**CLASSIFICATION**

Classification systems for benign strictures have been adapted from postoperative stricture findings. The Bismuth classification is the most commonly system used and is based on stricture location and relationship to the confluence<sup>[1]</sup> (Table 2, figure 1).

**Clinical features**

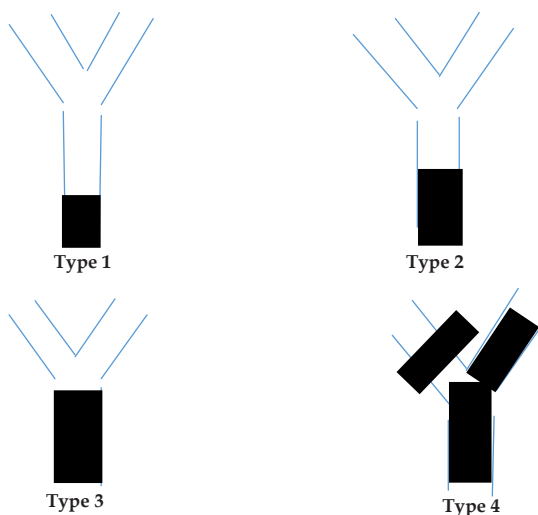
Benign biliary strictures are associated with a broad spectrum of presentations, from subclinical disease with mild elevation in liver function tests to complete hepatic obstruction with jaundice. Recurrent cholangitis is a life-threatening complication of biliary strictures. Biliary stones may develop above the stricture and chronic low-grade biliary obstruction may have devastating long-term consequences by leading to secondary biliary cirrhosis and development of end-stage liver disease<sup>[2]</sup>.

**Diagnosis and evaluation of biliary stricture**

Evaluation of biliary strictures can usually be undertaken in a stepwise fashion, incorporating the medical history, clinical presentation, laboratory studies and non-invasive cross sectional imaging (US, CT, MRI, EUS) and cholangiography (MRCP vs

**Table 2** Bismuth classification of benign strictures.

Classification	Benign strictures
I	Low CHD stricture, >2 cm distal to hilum
II	Proximal CHD stricture, < 2 cm distal to hilum
III	Hilar involvement up to proximal extent of CHD but confluence preserved
IV	Confluence involved, no communication between left and right ducts
V	Involvement of right hepatic branch alone or with common duct



**Figure 1** Bismuth Classification of benign biliary stricture.

ERCP).

Before deciding a therapeutic plan, it is relevant to investigate the stricture. The signs and symptoms of biliary obstruction (abnormal liver function tests, jaundice, abdominal pain, and cholangitis) and evidence of biliary dilatation on imaging are consistent with suspect of biliary strictures. It is paramount to exclude malignancy with a detailed medical history to identify risk factors for differing causes.

Clinical presentation may be helpful in discriminating postoperative and malignant strictures.

Laboratory investigations that may contribute to the diagnosis include tumor marker elevations in CA 19.9, CEA e CA-125 and IgG-4 levels. Overall, the sensitivity and specificity of tumour marker measurements are low but may be useful in conjunction with other diagnostic modalities where diagnostic doubt exists<sup>[3]</sup>. IgG4 levels are elevated in 75% of cases of Type I or LPSP variant of autoimmune pancreatitis (AIP) and value over twice the upper limit are highly specific for IgG4 related sclerosing cholangitis<sup>[4-5]</sup>.

Some ductal features on MRCP and ERCP may suggest malignant or benign etiology of biliary strictures. The cholangiographic features of a malignancy strictures is a long (> 10 mm), asymmetric and irregular stenosis. However, these criteria are not particularly sensitive or specific<sup>[6]</sup>.

Therefore, unless abdominal imaging detects biliary mass lesions, further endoscopic work-up is warranted to determine the etiology of biliary strictures.

ERCP with routine cytology and transpapillary biopsy is the first diagnostic test of choice, especially in that these strictures often require treatment with dilation and/or stenting. Advances in endoscopic and cytopathologic techniques and accessories have improved the diagnostic yield of endoscopic work-up. These

advances include EUS +/-FNA, IDUS, cholangioscopy and ancillary cytology techniques. If initial ERCP with routine cytology and biopsy is non-diagnostic, one or a combination of these diagnostic techniques is used. The choice of what next diagnostic modality should be individualized and depends on local expertise, patients' anatomy, comorbidities (e.g. PSC), preferences and sensitivity and specificity of the tests (Table 3). The majority of these techniques are still under evaluation in clinical trials. A proposed algorithm of diagnostic approach to BBS is provided in figure 6.

<b>Tecnique</b>	<b>Sensitivity</b>
Intraductal brushing during ERCP	27-56%
Endobiliary forceps biopsy	44-80% cholangiocarcinoma 33-71% pancreatic cancer
ERCP with intraductal US	58-90%
EUS	25-100%
EUS FNA all biliary strictures	43-89%
ESU FNA for prohimal strictures	25-90%
EUS FNA for distal biliary stricture	60-80%

**Traditional Therapy**

Surgery has been considered the traditional treatment of BBS but it is associated with significant morbidity and mortality rates of approximately 9-28% and 0-2.6 % respectively<sup>[7-9]</sup>. The reported rates of recurrent stricture requiring further interventions range from 10 to 30%<sup>[9-11]</sup>. However beginning in the 1970s, minimally invasive therapies gained greater acceptance. With advances in endoscopy approaches and the development of endoscopic stenting<sup>[12]</sup> and double balloon endoscopy for patients with altered gastrointestinal anatomy<sup>[13]</sup>, endoscopic management is emerging as an effective option, less invasive and better tolerated. Accordingly, the management of BBS is shifting from surgical to endoscopic treatment<sup>[14]</sup>.

**ANTIBIOTIC TREATMENT BEFORE ENDOSCOPIC PROCEDURE**

The risk of cholangitis persist until the stricture resolution is achieved because of the static bile provides an excellent culture medium for bacterial growth. The goal of therapy is to increase the radius of the stricture because according to the Poiseuille's law the resistance to flow in a tube is inversely proportional to the fourth exponent of the tube's radius. Therefore patients with obstructing lesions should receive prophylactic broad spectrum antibiotics before an endoscopic procedure according to the ASGE guideline because the risk of bacteremia in this setting rises to 18%<sup>[15]</sup>. The duration of antibiotic prophylaxis is guided by the outcome of the intervention, i.e., whether or not it was successful in relieving the obstruction<sup>[16]</sup>. The choice for antibiotic prophylaxis include piperacillin, cefuroxime and ciprofloxacin<sup>[17]</sup>.

**ENDOSCOPIC MANAGEMENT**

Endoscopic treatment of BBS involves four technical steps

**(1) Negotiating the stricture:** Negotiating benign biliary stricture (Figure 2) is often much more difficult than neoplastic because the stenosis, may be asymmetric and with associated fibrosis that makes them thin and tighter. The therapeutic procedure for biliary strictures require a high degree of experience and use of general anesthesia that helps to achieve a successful outcome<sup>[18]</sup>.

It is often necessary to use hydrophilic guidewires with variable diameter (0.035, 0.021, or 0.08 inch) and with different characteristics (straight or curved J shaped tip) to get across. Forceful maneuvers may create false passages and should be avoided. Guidewires are critical in maintaining biliary access, directing the catheter and stent into the correct segment and in minimizing contrast contamination of the biliary tree. Few comparative studies are available to guide choice of wire in traversing difficult strictures. Manipulation of guidewires requires high skill and optimal fluoroscopic imaging. The standard catheter used is 5 F in size and is passed over a 0.035 inch guidewire. Several other approaches have been used in such a situation. The 7 F Sohendra screw-type stent extractor (Cook Medical) is useful in difficult stricture<sup>[19]</sup>. Another technique is to use inflated stone retrieval balloon positioned just distal to the stricture results in stretching of the bile duct and modification of the axis of the guidewire. Papillotome may also be used to achieve the same result. Once the stricture is crossed, the stiffer guidewire is useful to facilitate dilation and stent placement. Sphincterotomy permit repeated stent exchanges and to allow for side-by side placement of large bore stents. A combined endoscopic and percutaneous approach ("rendezvous") can be used when a stricture cannot be crossed at ERCP<sup>[20]</sup>. Early studies found hydrophilic wires to be more successful in cannulation across strictures compared with traditional monofilament wires<sup>[21,22]</sup>. In case of complete transection or ligation for postoperative strictures a guidewire cannot be passed across the lesion and thus endotherapy alone is not feasible and surgical reconstruction is indicate.

**(2) Obtain a biliary specimen:** Tissue acquisition (Figure 3) is a key element in the evaluation of stricture characterization. In a review, all available sampling techniques during ERCP procedure were evaluated<sup>[23]</sup>. Overall the results for pathologic examinations of tissues acquired remain frustratingly low for schirrous nature of many tumors, difficulty in targeting the stricture and small tissue acquired.

**(3) Dilating the stricture:** Insertion of the guidewire across the stricture is followed by placement of a 6 Fr catheter over the guidewire and by mechanical dilation with a bougie system with a 9.5 Fr Cotton sleeve (Cook Medical) or with hydrostatic balloon with

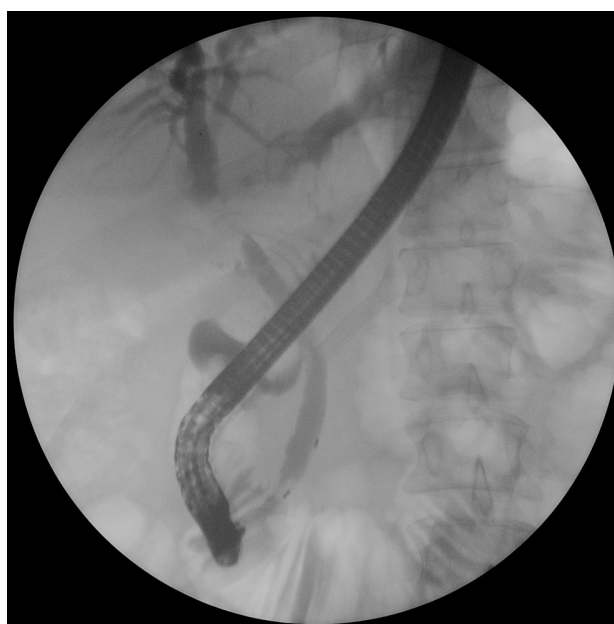

Figure 2 Cholangiographic feature of benign biliary stricture.

different caliber (4-12 mm) (Max Force , Boston Scientific) advanced over a guidewire and across the stricture under fluoroscopic control. The time of balloon inflation is usually 30 to 60 seconds.

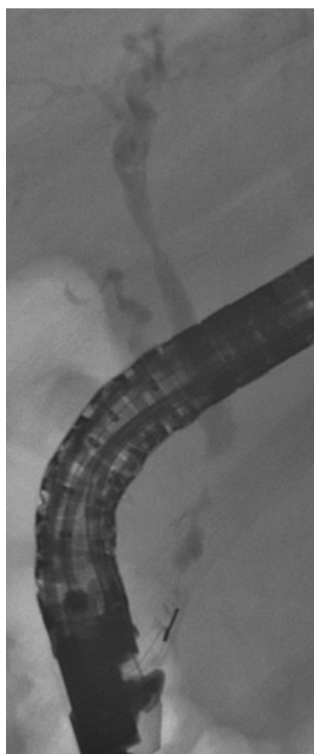
The main goal of stricture dilation is to open the common bile duct achieving bile drainage. There are no head-to-head comparisons between the two techniques. The size of the bile duct distal to the stricture guided the degree of dilatation. Anecdotally, balloon dilation of focal strictures has the advantage of showing a waist fluoroscopically, the persistence of which indicates a need for further dilatation. Dilatation soon after biliary anastomosis can lead to dehiscence, so a more cautious approach is required in this setting.

Although immediately effective, endoscopic balloon dilation alone, is considered inadequate and associated with a high restenosis rate (up to 47%)<sup>[24-27]</sup>. Therefore most strictures should be stented after dilatation, although this is not an absolute rule, and does depend on the underlying cause. Pneumatic dilatations should be performed only in cases of effective need and only during the very first endoscopic procedure. It is very likely that the forceful disruption of the scar may add further traumatic damage to the tissue and consequential development of a new fibrotic reaction.

**(4) Biliary stent placement:** Stent placement keeps the stricture open for a prolonged period, allowing scar remodeling and consolidation. The choice of the number and type of stent is dependent mainly on the etiology of biliary stricture. According to ESGE guidelines, simultaneous placement of multiple plastic stents ("multistenting") (Figure 4) for benign strictures of the CBD is technically feasible in >90% of patients; endoscopy provides the highest long-term biliary patency rate in 90% of postoperative biliary strictures and in 65% of strictures related to chronic pancreatitis<sup>[28]</sup>.

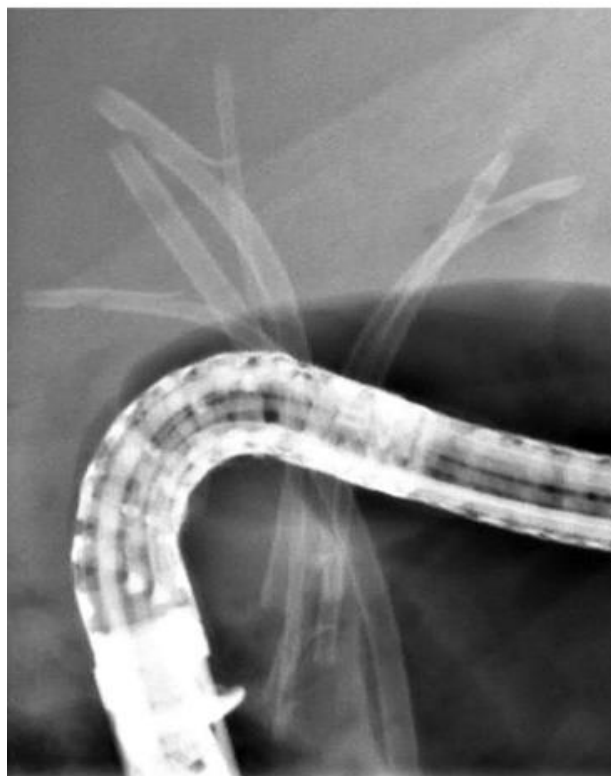

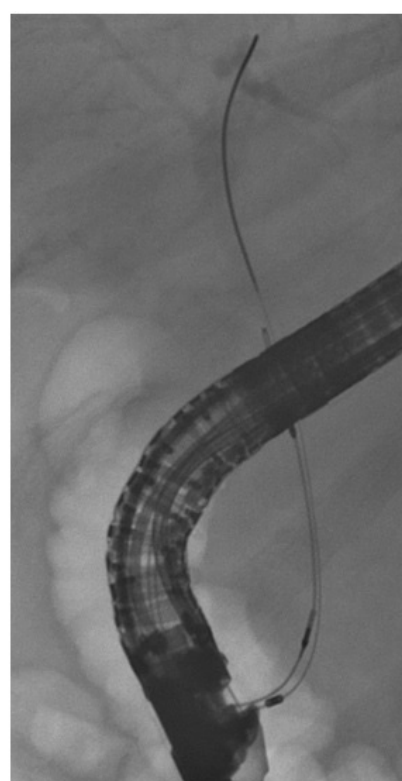
Figure 3 Biopsy of the biliary stricture.



Bile duct stricture



Forceps biopsy



Brush

Figure 4 Multistenting.



The main limitation of the multi-stenting strategy is the need for multiple ERCP sessions over the one-year period that increases costs and may decrease patient compliance.

A systematic review comparing plastic versus metal stent has been published by van Boeckel *et al* which showed that placement of multiple plastic stent was the best choice based on clinical success, risk of complication<sup>[29]</sup>. This review had unfortunately several limitations. First no randomized trial comparing both stents have been conducted. Second there was a wide variety in treatment protocols in the various studies with plastic stents. The risk of stricture recurrence is a main problem, therefore a metal stents have been developed to overcome the limits of multi-stenting technique. SEMs (Figure 5) allows an expansion diameter 3 times that a standard 10 Fr plastic stent and requiring single procedure to achieve the same result of a multistenting.

The uncovered metal stent are associated with higher rate of occlusion due to epithelial hyperplasia<sup>[30]</sup>. This results in the stent embedded within the wall of the duct make them no removable and may lead to a chronic inflammatory process, which could theoretically predispose to an increased risk of cholangiocarcinoma<sup>[31]</sup>. Another potential complication of SEMs in benign disease is secondary stricture formation<sup>[32-34]</sup>.

These factors have limited the use of uncovered SEMs for the treatment of benign biliary stricture.

Fully covered SEMs has been designed to prolong the duration of patency preventing occlusion from reactive tissue hyperplasia and stent embedment.

Early studies on fully covered SEMs placed without the intention of subsequent removal had a high rate of occlusion at approximately 2 years.

Most published SEMs studies have stent therapy with a duration of 2 to 6 months, and stricture resolution has ranged from 60% to 100% at the time of stent removal<sup>[32,35-39]</sup>.

On the other hand, the covering of metal stents can increase the risks of stent migration.

Migration rates have varied between 10% and 40%. To solve this problem partially covered SEMs (PC-SEMS) were used for BBS. PC-SEMS are uncovered at both the proximal and distal ends of the stent that theoretically decrease the rate of stent migration but increase the risk of tissue embedment and difficulty in removing the stent.

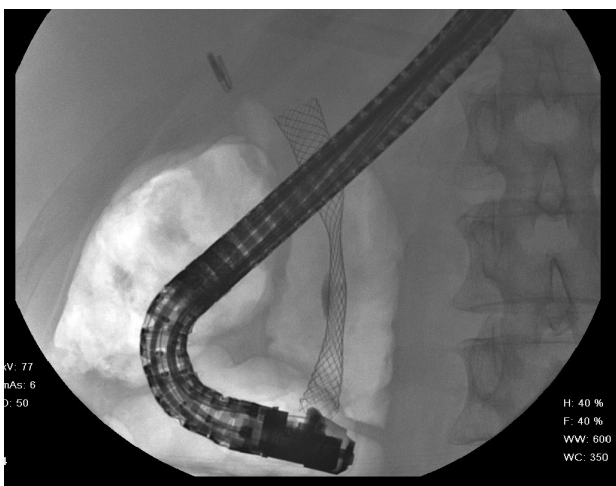


Figure 5 SEMs placement.

Kahaleh *et al* used PC-SEMS in 65 patients and stricture resolution was obtained in 90% at a median follow-up of 12 months after removal. In 14% of patients the metal stents migrated and in 9% there was mucosal hyperplasia at the level of the uncovered part of the stents (32).

A new stent designs with anchoring flaps or a variable contour (Niti-S bumpy-type stent, Taewoong Medical, Seoul, Korea), in order to reduce the risk of migration of covered stents, have been studied by Park *et al*<sup>[40]</sup>. These stents were placed in patients with BBS of different causes. Nevertheless, stent migration was found in 33% of patients with stents with flared ends.

Preliminary data of a multicenter study on the use of fully covered SEMs in benign strictures have been recently reported by Devière *et al* in abstract form at the Digestive Disease Week 2012<sup>[41]</sup>. The authors enrolled 187 patients with BBS related to chronic pancreatitis (CP), orthotopic liver transplantation (OLT) and biliary surgery, with mean follow-up after removal of 209 days. Overall stricture resolution was found in 82% (CP 86%, n=44; OLT 68%, n=15; post-cholecystectomy 100%, n=6) of the patients. The study is still ongoing, but results are however encouraging.

In a recent large prospective multinational study Deviere evaluated the stricture resolution and ability to remove covered SEMs in benign biliary stricture<sup>[42]</sup>.

Overall removal success and stricture resolution were achieved for approximately 75% of patients. The overall rates of stricture resolution were 79.7% in patients with chronic pancreatitis, 68.3% post liver transplantation and 72.2% in the post cholecystectomy group<sup>[42]</sup>. A proposed algorithm of management of benign biliary strictures is provided in figure 7.

**Endoscopic versus surgical Treatment**

A direct comparison of surgical and endoscopic therapy was published in 1993 in a non- randomized trial which showed similar long-term success rate<sup>[43]</sup>.

**Management of specific disorders**

**(1) Postoperative stricture:** Patients who undergo liver transplantations are at higher risk of developing BBS (20-30%). Biliary stricture after cholecystectomy represent the second cause of post-operative stricture. The cause of post-operative stricture is a consequence of direct ductal trauma (partial or complete transection

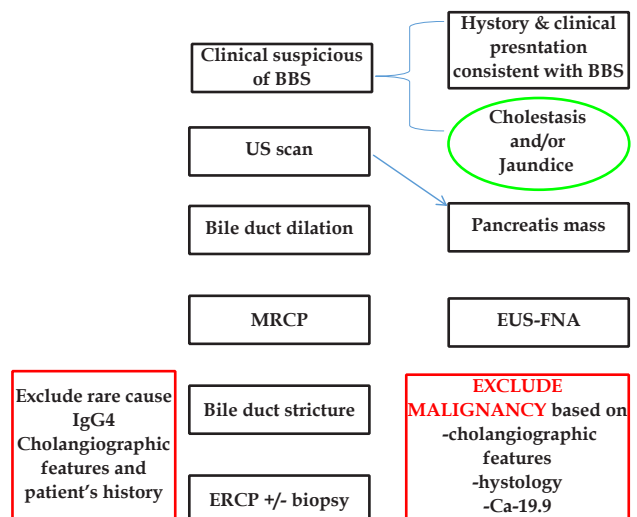


Figure 6 Proposed Algorithm of diagnosis of BBS.

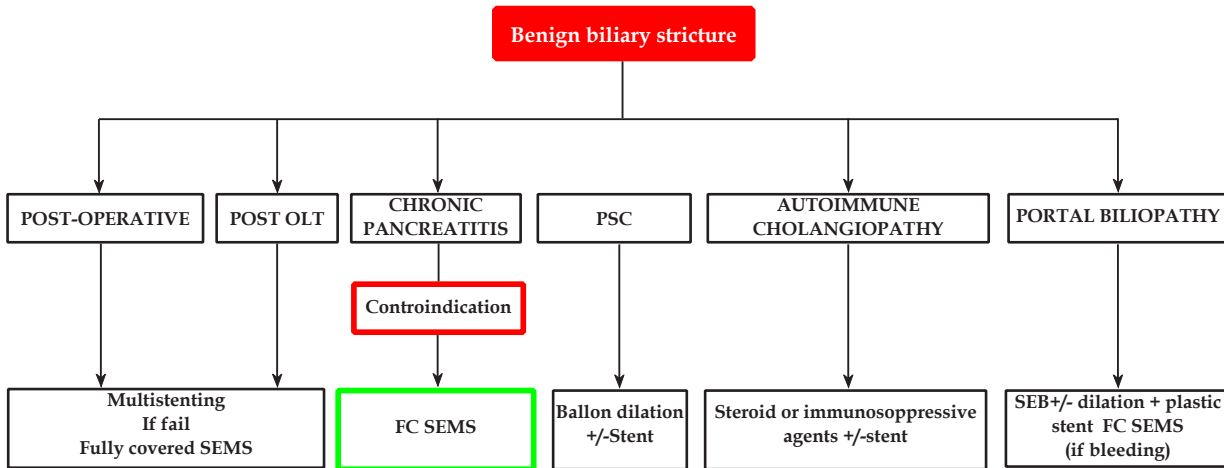


Figure 7 Proposed Algorithm of Endoscopic management of Benign Biliary stricture.

by clipping or ligation) or ischemic insult from thermal or dissection injury. The diagnosis occur usually 6 to 12 months after surgery and earlier presentation can be associated with bile leak. The widespread application of laparoscopic approach to cholecystectomy has been associated with an increasing incidence of bile duct injuries. Estimated incidence has increased from approximately 0.1 to 0.6% compared with earlier studies where open cholecystectomy was the mainstay of treatment<sup>[44-46]</sup>. Management of bile duct injuries has been predominantly surgical in the past. Although initial surgical success was reported to be more than 90% , follow up studies have found a 9% to 25% recurrence rate, a morbidity rate of 40% and a mortality of 1.3 to 1.7%<sup>[44,47-49]</sup>. Endoscopic therapy has been associated with variable success with reported response rates between 40 to 90%. Several variations in endoscopic stent protocols have been described for the treatment of postoperative benign biliary strictures with successful stricture resolution reported in 74-90% of patients<sup>[25,50]</sup>. The Amsterdam protocol suggested to place two 10 Fr stents whenever possible and exchanged every 3 months for a period of 1 year. Bergman reported a technical success of 80% with a recurrence stenosis occurring in 20% of patients after a median follow-up of 9.1 years<sup>[51]</sup>. Costamagna *et al* reported a more aggressive biliary stent approach to overcome high rate of recurrence consist of placing as many stents as possible during each ERCP session with elective stent exchange performed every 3 months<sup>[52]</sup>. At each exchange, all previously placed stents were removed and the maximum number of large diameter stents inserted, as permitted by the diameter of the duct distal to the stricture and the diameter of the stricture itself. The treatment protocol was stopped when complete morphologic disappearance of the stricture was demonstrated by occlusion cholangiography after stent removal and confirmed by subsequent cholangiography performed through the nasobiliary drain 24-48 later. On a intention to treat analysis endoscopic treatment was successful in 89% of case. The outcomes of endoscopic management depend on both the etiology and location of the stricture. Distal lesions (Bismuth I and II) show a better success rate than proximal biliary lesions (Bismuth III, 80 vs 25 %)<sup>[25]</sup>.

Larger, fully or partially covered metallic stents may improve the results for patients with biliary stricture. Treatment with covered metallic stents or bioabsorbable stents warrants further evaluation (14, 32). Surgical management should be considered when these endoscopic techniques are not effective<sup>9, 44, 48</sup>. Roux-en-, Y

hepaticojejunostomy (HJ) is the most frequently used type of biliary reconstruction<sup>[53,54]</sup>, although hepatoduodenostomy can be selectively used for Bismuth–Strasberg classification E1 or E2 strictures<sup>[55]</sup>. Previously published data have shown that endoscopic treatment is at least as effective as surgical treatment for BBS with reported success rate of 80%. Although there are no randomized controlled trials comparing the two modalities, retrospective a case series have shown similar long term results and re-stenosis rates.

**Post-transplant biliary complications:** Biliary complication after liver transplantation occur in about 5 to 30%<sup>[64-66]</sup>. Post-transplant biliary strictures are classified as anastomotic and non-anastomotic and early (within 1 month) or late. Early stricture (within 1-2 months) are generally related to peri-operative events (excessive cautery, dissection, tension of the duct anastomosis) and are mostly anastomotic. Usually have the best response rate to endoscopic treatment with a stricture resolution after 3 months in most cases. Late stricture are caused by vascular insufficiency and fibrosis<sup>[67,68]</sup>. Usually require 12 to 24 month of endoscopic stenting with stent exchange every 3 months to ensure a durable response. Long-term response to endoscopic treatments has been reported in 70-90% of cases. Most anastomotic strictures occur within the first year after LT. Among the etiological factors underlying early anastomotic stricture, technical issues appear to be the most important in the development of BBS<sup>[69]</sup>. The cholangiographic appearance of anastomotic stricture is characterized by a single, short stricture in the middle portion of the common bile duct. Bile leakage is an independent risk factor for the development of anastomotic stricture<sup>[70]</sup>. With regard to anastomotic strictures with later onset, the findings mostly implicate fibrotic scarring arising from ischemia damage of the anastomosis<sup>[71-73]</sup>. The incidence of duct-to-duct anastomotic stricture in right lobe living-donor transplant recipients has been consistently higher than in recipients of whole-liver grafts<sup>[74]</sup>. This difference has been attributed to the limited blood supply at the anastomosis and to the presence of multiple, small-caliber donor bile ducts<sup>[72]</sup>. Non-anastomotic stricture (10-25% of cases) shows multiple intrahepatic lesions and occurs earlier than anastomotic stricture, with a mean time to stricture of 3 to 6 months<sup>[75,76]</sup>. Multiple factors contribute to non-anastomotic strictures, including ischemic injury from hepatic artery thrombosis, donor hypotension during cardiac death, long warm and cold ischemic times, reperfusion injury, immunologically-induced injuries, such as ductopenic rejection, and cytotoxic injury induced

**Table 4** SEMS for post transplant biliary complications.

Author	N patients	Stent type	Clinical success (%)	c (%)	Migration rate (%)	Complication (%)	Follow up median
Vanderbroucke <sup>1</sup> <i>et al</i> <sup>[86]</sup> , 2006	17	PC SEMS <sup>1</sup>	67.00%	Nr <sup>3</sup>	Nr <sup>3</sup>	4%	37.8 +/-17.2
Kahaleh M <i>et al</i> <sup>[32]</sup> , 2008	16	PC SEMS <sup>1</sup>	92.00%	6%	14%	11.4%	Nr
Mahajan A <i>et al</i> <sup>[38]</sup> , 2009	9	FC SEMS <sup>2</sup>	100%	0%	4%	28%	Nr
Traina M <i>et al</i> <sup>[37]</sup> , 2009	16	FCSEMS <sup>2</sup>	81.00%	NR	37%	0%	10 month
Chaput U <i>et al</i> <sup>[39]</sup> , 2010	22	PCSEMS <sup>1</sup>	86.00%	5.00%	27.00%	23.00%	Nr
Garcia-Pajares F <i>et al</i> <sup>[57]</sup> , 2010	22	5 PC 17 FC	86.4%	5%	22.7%	41%	12.5 months
Hu L. <i>et al</i> <sup>[58]</sup> , 2011	13	FC SEMS <sup>2</sup>	92%	8%	0%	0%	12
Tarantino I <i>et al</i> <sup>[59]</sup> , 2012	39	FCSEMS <sup>2</sup>	71.8%	14.3%	33.3%	0%	Nr
	15		53.3%	25%	46.7%	0%	21 month
Haapamaki C <i>et al</i> <sup>[60]</sup> , 2012	17	FCSEMS <sup>2</sup>	100%	11%	23%	Nr <sup>3</sup>	5
Poley JW <i>et al</i> <sup>[61]</sup> , 2012	6	FCSEMS <sup>2</sup>	80.00%	NR <sup>3</sup>	Nr <sup>3</sup>	Nr <sup>3</sup>	12
Sauer P <i>et al</i> <sup>[62]</sup> , 2012	9	FCSEMS <sup>2</sup>	67.00%	17%	Nr <sup>3</sup>		
Ceredo-Rodriguez J <i>et al</i> <sup>[63]</sup> , 2013	55	19 PC 36FC	74% 70%	NR <sup>3</sup>	Feb-19 Feb-36	NR <sup>3</sup>	Nr <sup>3</sup>

<sup>1</sup> PC SEMS, <sup>2</sup> FC SEMS, <sup>3</sup> Nr.

**Table 5** SEMS for Chronic Pancreatitis .

Author	N patients	Stent type	Clinical success (%)	Recurrence rate (%)	Migration rate (%)	Complication (%)	Follow up after stenting
Deviere J <i>et al</i> <sup>[97]</sup> , 1994	20	Uncovered	90%	10%	0%	0%	33 months
Van Berkel AM <i>et al</i> <sup>[98]</sup> , 2004	13	Uncovered	69.2%	30.8%	7.6%	0%	50 month
Bruno M <i>et al</i> <sup>[99]</sup> , 2005	7	Covered	28.5%	71.5%	28.5%	Nr	6 month
Tringali A <i>et al</i> <sup>[100]</sup> , GIE 2005 abst	24	Uncovered n=18 Covered n= 4	33.5 %	66.5 %	Nr	Nr	61 month
Kahaleh <i>et al</i> <sup>[101]</sup> , 2008	32	Covered	77%	22%	14%	7%	12 month
Behm B <i>et al</i> <sup>[102]</sup> , 2009	20	Partially Covered	90%	10%	5%	15%	22 month (median)
Mahajan A <i>et al</i> <sup>[38]</sup> , 2009	19	Covered	58%	42%	5%	11%	Until event occur
Cahen DL <i>et al</i> <sup>[103]</sup> , 2012	6	Covered	67%	33%	33%	67%	20 months
Perri T <i>et al</i> <sup>[104]</sup> , 2012	17	10 flared FCSEMS	90% 43%	Nr	40% 100%	10% 57%	24 months

by bile salts and cytomegalovirus infection<sup>[77,78]</sup>. They typically occur at the hepatic confluence and can progress to the intrahepatic ducts, occasionally in multiple locations<sup>[79]</sup>. The accumulation of biliary sludge and casts is thought to arise from sloughing of the biliary epithelium caused by underlying ischemic states or immunological injury<sup>[80,81]</sup>. The response to endoscopic treatment, is low, ranging from 0 % to 50% and treatment is usually more prolonged<sup>[82-85]</sup>. Up to 30 to 50% of patient require retransplantation despite endoscopic therapy<sup>[72,83]</sup>. The poor response to endoscopic treatment is likely related to the multifocal stricture, associated sludge and casts and recurrence of underlying disorders<sup>[76]</sup>.

The clinical success, recurrence, migration and complication rates are summarized in table 4

A recent systematic review compared the efficacy and safety of multiple plastic stents versus covered self-expandable metal stents in anastomotic biliary strictures.

They found 8 studies involving 440 patients treated by plastic stent with overall technical success rates ranging from 92% to 100%. Comparison of stricture resolution rates between the subgroups (early vs late ABS) and stent duration (< 12 months vs > 12 months) showed that stricture resolution rates were 84.3% (range 72-92%) for early ABS and 86.5% (range 64-100%) for late ABS. The stricture resolution rates for stent duration of less than 12 months was 78.3% compared with 97% for duration longer than 12 months. The authors found that the stricture resolution rates with SEMS in OLT patients were also high when stent duration was 3 months or longer (89.5%: range 80%-95%) compared with a duration less than 3 months (71.8%: range 53%-86%) evaluating all the articles published that used SEMS in this setting<sup>[32,37-39,56-63]</sup>. The corresponding stricture recurrence rates were 15% and 8% respectively. Furthermore the stricture resolution rates were 82,2% (range 53-94%) for SEMS as

primary therapy (75 patients) and 78% (range 67-95%) for secondary therapy (125 patients). Although the overall adverse event rates were low, the overall SEMS migration rate was significant at 16%. They concluded that although SEMSs appeared to be a promising option in the endoscopic management of ABSs after liver transplantation, current evidence does not suggest a clear advantage of SEMS use over MPSs for this indication<sup>86</sup>. There are several limitations to this review. First, the available data was in the form of case series in which either MPSs or SEMSs were used and each studies enrolled small number of patients. Second significant heterogeneity existed among the studies with respect to primary outcome, patient selection, stent protocol, stent duration, types of SEMSs, and follow-up periods.

**Chronic pancreatitis**

Surgery is still considered the gold standard treatment for benign biliary strictures related to chronic pancreatitis<sup>[87]</sup>. Common bile duct strictures occur in 10% to 30% of patients with chronic pancreatitis<sup>[88]</sup>. Endoscopic therapy is a reasonable first-line management option; however, it tends to be less effective in treating strictures secondary to calcific pancreatitis and surgical bypass should always be considered if the patient is an appropriate surgical candidate and endoscopic therapy fails. Short-term (1-month) results in the treatment of biliary stricture with plastic or SEMS are similar regarding success and complication rates. Although short-term results are excellent with immediate relief of cholestasis in almost all cases, it remains unclear whether endoscopic plastic stent placement can achieve definitive stricture resolution, especially in tight fibrotic stricture<sup>[89]</sup>. Cahen reported a success rate of only 38% for endoscopic plastic stent placement. In effort to improve these results has been used a multi-stenting technique with a 60% of response<sup>[90]</sup>. Long-term results of endoscopic treatment have not been encouraging. The

poor results of endoscopic therapy for chronic pancreatitis following plastic stent have encouraged the use of self expandable metal stent (SEMS). However the majority of the study reporting the use of uncovered SEMS have been small with variable results<sup>[91,92]</sup> but with complications related to stent occlusion for mucosal hyperplasia<sup>[93]</sup>. Attempts to overcome such drawbacks by placing covered SEMS that have larger “dilation” diameter than plastic stents which can be achieved after one endoscopic procedure. Short term (1 month) results fort biliary stenting are similar for plastic and SEMS in terms of success and complication rates. Long-term, results for temporary biliary stenting are summarized in table 5. Successful treatment was reported in 31% with single plastic stent and 62% with simultaneous multiple plastic stents. A single non-randomized trial comparing single plastic versus multiple plastic stent showed overall clinical success in 24% vs 92% patients, respectively ( $p < 0.01$ )<sup>[94]</sup>. Furthermore use of uncovered stent or partially covered in this setting has been abandoned because of disappointing long-term results<sup>[95,96]</sup>. Uncovered SEMS for BBS are not advocated and partially or fully covered SEMS have been used with a success rate of 50%-80% on follow up for 22-28 months. The trials result of covered SEMS in the treatment of biliary stricture due to chronic pancreatitis are summarized in table 5. The resolution stricture rates ranged from 28-90% with a recurrence rates from 10-75% showing that we are away from the target. A recently multicenter trial using fully covered SEMS (FCSEMS) in BBS was conducted including 127 patients of CP. It concluded that FCSEMS may be useful for treatment of BBS particularly in patients with CP<sup>[42]</sup>. In our unit we placed one fully covered metal stent in patients unfit to surgery considering the low success rate of plastic stent in the long term follow up and the need for repeated ERCP procedure with higher cost and better patient compliance.

**PSC:** PSC is a chronic progressive inflammatory disorder affecting the medium and large intrahepatic and extrahepatic bile ducts. About 15-60% of patients with PSC develop a dominant stricture. Endoscopic management focuses on treatment of dominant strictures because the stricturing process is diffuse, with most patients having intrahepatic and extrahepatic duct involvement.

The management of PSC with a dominant stricture is challenging and depends on multiple factors; the difficulty in distinguishing malignant from benign strictures, the difficulty in managing proximal and multiple strictures, the high rate of secondary bacterial cholangitis, and the lack of definitive therapeutic strategies aside from liver transplantation, are all critical factors in deciding the best approach to management. Malignancy always needs to be considered and excluded in the management of dominant strictures. The prevalence of cholangiocarcinoma in PSC ranges from 8% to 25%<sup>[105,106]</sup>. Management decisions should consider the impact on liver transplantation, the only cure for PSC. Progression of PSC is generally slow, and early management of dominant strictures should be designed to improve symptoms and quality of life without jeopardizing successful and timely transplant. Endoscopic biliary dilatation of dominant strictures, usually with multiple sessions, achieves clinical and biochemical response in around 80% of cases<sup>[107,108]</sup>.

Several studies have shown a better predicted Mayo risk score after endoscopic therapy<sup>[109-111]</sup>.

These studies were mainly observational, with endoscopic treatment combined with Ursodeoxycholic acid, making it difficult to draw conclusions on endotherapy alone. One retrospective study found complication rates to be higher with stenting compared with dilatation alone<sup>[112]</sup> which led Ponsion and colleagues to propose a

short-term stenting protocol of 11 days that has reported success on cholestatic complaints in about 83% of cases and a reintervention free porportion after 1 and 3 years were respectively of 80% and 60%<sup>[113]</sup>. Most clinicians therefore perform biliary dilatation up to 24 Fr and apply a biliary stent to maintain patency, with administration of prophylactic antibiotics during and after the procedure. No prospective studies have compared the optimal duration of stent therapy with the frequency of endoscopic dilatation of dominant strictures. Our position is to favour short term stent placement (4 weeks) because ERCP usually in these patients require multiple techniques such as sphincterotomy, dilation, brushing, biopsy that may cause edema reducing the possibility of stricture resolution. Placement of a single stent avoid cholangitis and provide better dilation. No studies have compared the endoscopic versus surgical therapies for dominant strictures.

**Autoimmune cholangiopathy (IgG4 cholangiopathy):** IgG4 cholangiopathy or IgG4 sclerosing cholangitis remains an evolving clinical entity, with endoscopic management playing a supportive role to immunosuppressive therapy. It is a unique systemic inflammatory condition characterized by IgG4 plasma cell infiltration of various organs as well as high serum IgG4. AIC may occur as an isolated biliary disease with or without AIP causing biliary stricture at any point in the biliary tree or pancreatic ducts<sup>[114]</sup>. Most patients with IgG4 cholangiopathy have associated autoimmune pancreatitis, and biliary obstruction can be from primary biliary inflammation or secondary to a pancreatic mass. Diagnosis can be difficult and confused with PSC, especially in the absence of reliable histology and when IgG4 staining is not available. A study by Nakazawa and colleagues proposed the use of cholangiographic characteristics to differentiate PSC from IgG4 cholangiopathy<sup>[115,116]</sup>. The usefulness of these features was disputed in a study comparing cholangiogram interpretation of PSC, cholangiocarcinoma, and IgG4 cholangiopathy, with interobserver agreement of only 0.18<sup>[117]</sup>. Although response to corticosteroid therapy is less predictable than with pancreatic disease, medical therapy and immunosuppression remains the primary therapy. There is minimal literature describing endoscopic therapy for IgG4 cholangiopathy but, based on general principles, endoscopic stenting has a role to temporary relieve jaundice during medical therapy waiting for a diagnosis, which is confirmed by a response and regression of strictures after starting steroid treatment<sup>[118]</sup>.

**HIV related stricture:** HIV cholangiopathy is a rare condition, first described in the late 1980s, that is associated with cholangiographic abnormalities including papillary stenosis, sclerosing cholangitis, and biliary strictures. Extrahepatic biliary strictures alone or combined with intrahepatic duct strictures and papillary stenosis occur in approximately one third of patients. It typically occurs in patients with CD4 counts less than 100/mm<sup>3</sup>, and is therefore an extremely rare entity in the current era of highly active anti retroviral therapy (HAART). HIV cholangiopathy is associated with chronic biliary tract infections, most commonly with *Cryptosporidium parvum* but also cytomegalovirus, *Microsporidium*, and *Cyclospora*. Because patients with HIV cholangiopathy have advanced disease with a short median survival, treatment is designed to control symptoms. Antimicrobial therapy does not generally improve symptoms or cholangiographic appearance. Endoscopic sphincterotomy is effective at relieving pain in patients with papillary stenosis<sup>[119,120]</sup>.

Extrahepatic biliary strictures are best managed with plastic stent therapy, whereas Castiella and colleagues described response to ursodeoxycholic acid for intrahepatic sclerosis<sup>[121]</sup>.

**Portal biliopathy:** The term portal biliopathy was first coined



in the 1990s, where it was used to describe abnormalities in the intrahepatic and extrahepatic biliary tract, gallbladder and cystic duct secondary to portal hypertension. It is common in portal vein thrombosis and less often in cirrhosis and non-cirrhotic portal fibrosis. Studies in these patients using ERCP have shown that changes in the bile ducts occur in 81%-100% of them, although only 5%-30% have symptoms of biliary obstruction<sup>[122-124]</sup>. The left hepatic ducts are always involved, the right ductal system is involved in 56% and there are changes in the common bile duct in 90%. The natural history of portal biliopathy is not known. The majority of patients (70%-95%) do not manifest with any symptoms of biliary obstruction. Cholangiography is useful in the diagnosis and classifying the type of portal biliopathy. Based on the location and extent of cholangiographic abnormalities, a simple classification of portal biliopathy has been proposed<sup>[125]</sup>.

Type I : Involvement of extrahepatic bile duct.

Type II : Involvement of intrahepatic bile ducts only.

Type IIIa : Involvement of extrahepatic bile duct and unilateral intrahepatic bile duct (Left or Right).

Type IIIb : Involvement of extrahepatic bile duct and bilateral intrahepatic bile duct.

The clinical features depend on the location and extent of bile duct obstruction. When bile duct obstruction is partial, patients are asymptomatic; when become complete, patients present with features of ascending cholangitis. Prolonged obstruction often leads to the development of secondary biliary cirrhosis. There is no consensus on the optimal treatment for symptomatic portal biliopathy. Endoscopic treatment is preferred in patients with CBD stones, cholangitis or if shunt surgery is not feasible<sup>[126-129]</sup>. Mechanical lithotripsy may be required for large stones. Endoscopic sphincterotomy with stenting or nasobiliary tube drainage may be necessary in patients with cholangitis<sup>[130-132]</sup>. Balloon dilatation of dominant CBD strictures with stone extraction has also been described by various authors. The major problems with endoscopic management depends on different factors. First filling defects seen on imaging may be due to varices and may lead to bleeding during attempted clearance. Second venous collaterals in the region of the ampulla of Vater may lead to bleeding during papillotomy, so this procedure should only be attempted in experienced centres which have a good surgical backup<sup>[133,134]</sup>. Third balloon dilatation with stenting of dominant strictures may help to relieve biliary obstruction but these stents become blocked frequently requiring multiple changes with their inherent risk of bleeding<sup>[135]</sup>. Finally multiple sessions require the patients to be compliant and have ready access to endoscopic expertise. Therefore, although endoscopic extraction remains the preferred treatment in patients with CBD stones, most centres consider shunt surgery to be the first line of management for biliary obstruction secondary to bile duct strictures, unless complications like cholangitis or absence of a shuntable vein exist. In patients with symptomatic biliary obstruction not amenable to endoscopic therapy, a porto-systemic shunt is indicated to decompress the portal system<sup>136</sup>. While regression of ectopic varices has been noted in most, a proportion of patients continue to have bile duct changes<sup>[137]</sup>. Hepatico-jejunostomy may be beneficial in these non-responders.

## BIODSORBABLE STENT

Self expandable stents made of bioabsorbable material may have several advantages compared to the plastic and self expandable metal stent<sup>[138,139]</sup> because of improved patency for their larger diameter, lower biofilm accumulation, reduced bile duct proliferation changes

and no removable stent. Furthermore can be impregnated with antimicrobial or anti-neoplastic agents. Larger, prospective, well-designed studies must demonstrate long-term efficacy and safety of biodegradable stents for a broad range of benign indications.

## CONCLUSION

Therapeutic endoscopy plays a key role in the treatment of benign biliary strictures.

Despite the lack of randomized controlled trials, endoscopy has become the first line therapy for post-liver transplant anastomotic strictures and post-operative strictures.

Strictures related to chronic pancreatitis have proven more difficult to treat, and endoscopic therapy is reserved for patients, who are not surgical candidates.

At present, according to ESGE guidelines, in compliant patients with benign CBD strictures, the preferred endoscopic approach is aggressive dilation of the stricture and insertion of multiple plastic stents "multistenting".

Placement of uncovered SEMS in these patients is strongly discouraged due to poor long-term result. Covered SEMS can be safely placed in selected patients.

A rendezvous" techniques can be useful in case of failure of ERCP for and in patients with surgically modified anatomy or with non-accessible papilla.

Surgery is a valid option in cases of complete transection or ligation of the CBD, in selected patients with CP-related CBD stricture, and in non-compliant patients.

In any case, endoscopy should be always attempted, because it is safe and repeatable.

### What is already known on this topic

Endoscopic treatment is a safe and efficacy method to treat benign biliary strictures.

Multistenting treatment is the preferred method in case of post-operative and post liver transplantation stricture. In case of failure FC SEMS is a valid option.

Biliary strictures secondary to chronic pancreatitis are best treated by FC SEMS placement in case of contraindication to surgery.

PSC dominant stricture are treated by dilation and eventually by stent.

Autoimmune cholangiopathy is treated by steroid or immunosuppressive agents. Plastic stent could be temporarily useful to relieve the stricture.

Portal hypertensive stricture has been treated by placing a plastic stent and in case of massive bleeding with FC SEMS.

The golden standard of diagnosis in case of malignant suspicious is based on histology.

### What this study adds to our knowledge

Clear approach to benign biliary strictures.

### What we would like to know

Use of fully covered SEMS in benign biliary stricture as first approach.

A more accurate method of differential diagnosis between benign and malignant stricture.

Use of stent in PSC dominant stricture.

Use of bioabsorbable stents.

### Keypoint in Endoscopic management of benign biliary stricture

Biliary cannulation with a sphincterotome pre-loaded with a guidewire reducing the risk of PEP.

Position is paramount.

Use of rectal NSAID or pancreatic stent (3-5 FR x 3 cm length) in patient at risk of PEP or in case of contrast in pancreatic duct to prevent Post ERCP pancreatitis (PEP):

(1) Perform cholangiography and describe the diameter of CBD and stricture morphology.

(2) Perform sphincterotomy and negotiate the stricture with a adequate guidewire (never forced).

(3) Dilate as appropriate with bougie or balloon (4 to 12 mm) advanced over a guidewire and across the stricture under fluoroscopic control maintaining the balloon fully inflated for 30 to 60 seconds. Do biopsy in case of doubt.

(4) Place plastic stent (as many stents as possible) (Rome criteria) (initially 1-2 stents) and increase numbers during each ERCP sessions (elective stent exchange every 3 months for 1 year).

## CONFLICT OF INTERESTS

There are no conflicts of interest with regard to the present study.

## REFERENCES

- Bismuth H. Postoperative strictures of the biliary tract in: Blumgart L: The biliary tract. *Edinburgh Churchill Livingstone* 1982; 209-218
- Warshaw AL, Schapiro RH, Ferrucci JT Jr, Galdabini JJ. Persistent obstructive jaundice, cholangitis, and biliary cirrhosis due to common bile duct stenosis in chronic pancreatitis. *Gastroenterology* 1976; **70**: 562-5675
- Khan SA, Davidson BR, Goldin R, Pereira SP, Rosenberg WM, Taylor-Robinson SD, Thillainayagam AV, Thomas HC, Thursz MR, Wasan H Guideline for diagnosis and treatment of cholangiocarcinoma: consensus document. *GUT* 2002; 51 Suppl VI; VI 1-VI 9
- Bjornsson E, Chari ST, Smyrk T. C, Lindor K. Immunoglobulin G4 associated cholangitis: description of an emerging clinical entity based on review of the literature. *Hepatology* 2007; **45(6)**: 1547-1554,
- Ghazale A, Chari ST, Zhang L, Smyrk TC, Takahashi N, Levy MJ, Topazian MD, Clain JE, Pearson RK, Petersen BT, Vege SS, Lindor K, Farnell MB. Immunoglobulin G4-Associated Cholangitis: clinical Profile and Response to Therapy. *Gastroenterology* 2008; **134(3)**: 706-715
- Park MS, Kim TK, Kim KW, Park SW, Lee JK, Kim JS, Lee JH, Kim KA, Kim AY, Kim PN, Lee MG, Ha HK. Differentiation of extrahepatic bile duct cholangiocarcinoma from benign stricture: findings at MRCP versus ERCP. *Radiology* 2004; **233**: 234-240
- Raute M, Podlech P, Jaschke W, Manegold BC, Trede M, Chir B. Management of bile duct injuries and strictures following cholecystectomy. *World J Surg* 1993; **17**: 553-562
- Frattaroli FM, Reggio D, Guadalaxara A, Illomei G, Pappalardo G. Benign biliary strictures: a review of 21 years of experience. *J Am Coll Surg* 1996; **183**: 506-513
- Tocchi A, Mazzoni G, Liotta G, Costa G, Lepre L, Miccini M, De Masi E, Lamazza MA, Fiori E. Management of benign biliary strictures: biliary enteric anastomosis vs endoscopic stenting. *Arch Surg* 2000; **135**: 153-157
- Kozarek RA. Endoscopic techniques in the management of biliary tract injuries. *Surg Clin North Am* 1994; **74**: 883-893
- Davids PH, Rauws EA, Coene PP, Tytgat GN, Huibregtse K. Endoscopic stenting for postoperative biliary strictures. *Gastrointest. Endosc* 1992; **38**: 12-18
- Isayama H, Nakai Y, Togawa O, Kogure H, Ito Y, Sasaki T, Sashira N, Hirano K, Tsujino T, Tada M, Kawabe T, Omata M. Covered metallic stent in the management of malignant and benign pancreatobiliary strictures. *J Hepatobil Pancreat Surg* 2009; **16**: 624-627
- Shimatami M, Matsushita M, Takaoka M, Koyabu M, Ikeura T, Kato K, Fukui T, Uchida K, Okazaki K. Effective "short" double balloon enteroscope for diagnostic and therapeutic ERCP in patients with altered gastrointestinal anatomy: a large case series. *Endoscopy* 2009; **41**: 849-854
- Judad JR, Draganov PV. Endoscopic therapy of benign biliary strictures. *World J Gastroenterol* 2007; **13**: 3521-3529
- Nelson DB. Infectious disease complications of GI endoscopy: part I, endogenous infections. *Gastrointest. Endosc* 2003; **57**: 546-556
- Motte S, Deviere J, Dumonceau JM, Serruys E, Thys JP, Cremer M. Risk factors for septicemia following endoscopic biliary stenting. *Gastroenterology* 1991; **101**: 1374-1381
- Mehal WZ, Culshaw KD, Tillotson GS, Chapman RW. Antibiotic prophylaxis for ERCP: a randomized clinical trial comparing ciprofloxacin and cefuroxime in 200 patients at high risk of cholangitis. *Eur J Gastroenterol Hepatol* 1995; **7**: 841-845 ;
- Martindale SJ. Anesthetic considerations during endoscopic retrograde cholangiopancreatography. *Anesth Intensive Care* 2006; **34**: 475-80
- Brand B, Thonke F, Obytz S, Binmoeller KF, Rathod V, Seitz U, Bohnacker S, Jäckle S, Soehendra N. Stent retriever for dilation of pancreatic and bile duct strictures. *Endoscopy* 1999; **31**: 142-145
- Hunt JB, Sayer JM, Jacyna M, Crofton M, Summerfield JA. Combined percutaneous transhepatic and endoscopic placement of biliary stents. *Surg Oncol* 1993; **2**: 293-298
- Gane E, Lane M, Hamilton I. Use of an alternative guidewire system in endoscopic placement of biliary endoprosthesis. *Endoscopy* 1991; **23**: 215-217
- McCarthy JH, Miller GL, Laurence BH. Cannulation of the biliary tree, cystic duct and gallbladder using a hydrophilic polymer-coated steerable guide wire. *Gastrointest. Endosc* 1990; **36**: 386-389
- De Bellis M, Sherman S, Fogel EL, Cramer H, Chappo J, McHenry L Jr, Watkins JL, Lehman GA. Tissue sampling at ERCP in suspected malignant biliary strictures (Part 2). *GIE* 2002; **56**: 720-723
- Smith MT, Sherman S, Lehman GA. Endoscopic management of benign strictures of the biliary tree. *Endoscopy* 1995; **27**: 253-266
- Draganov P, Hoffman B, Marsh W, Cotton P, Cunningham J. Long-term outcome in patients with benign biliary strictures treated endoscopically with multiple stents. *Gastrointest. Endosc* 2002; **55**: 680-686
- Smith MT, Sherman S, Lehman GA. Endoscopic management of benign strictures of the biliary tree. *Endoscopy* 1995; **27**: 253-266
- Foutch PG, Sivam KG Jr. Therapeutic endoscopic balloon dilation of the extrahepatic biliary ducts. *Gastroenterology* 1985; **80**: 575-580
- Dumonceau JM, Tringali A, Blero D, Deviere J, Laugier R, Heresbach D, Costamagna G. Biliary stenting: indications, choice of stents and results: European Society of Gastrointestinal Endoscopy (ESGE) clinical guideline. *Endoscopy* 2012; **44**: 277-298
- van Boeckel Petra GA, Vleggar FP, Siersema Peter D. Plastic or metal stents for benign extrahepatic biliary strictures: a systematic review. *BMC Gastroenterology* 2009; **9**: 96
- Silvis SE, Sievert CE Jr, Vennes JA, Abeyta BK, Brennecke LH. Comparison of covered versus uncovered wire mesh stents in the canine biliary tract. *Gastrointest. Endosc* 1994; **40**: 17-21
- Lopez RR, Cosenza CA, Lois J, Hoffman AL, Sher LS, Noguchi H, Pan SH, McMonigle M. Long term results of metallic stents for benign biliary strictures. *Arch Surg* 2001; **136(6)**: 664-669
- Kahaleh M, Behm B, Clarke BW, Behm B, Clarke BW, Brock A, Shami VM, De La Rue SA, Sundaram V, Tokar J, Adams RB,

- Yeaton P. Temporary placement of covered self expandable metal stents in benign biliary strictures: a new paradigm? (with video). *Gastrointest. Endosc* 2008; **67**: 446-454
- 33 Kasher JA, Corasanti JG, Tarnasky PR, McHenry L, Fogel E, Cunningham J. A multicenter analysis of safety and outcome of removal of a fully covered self-expandable metal stent during ERCP. *Gastrointest. Endosc* 2011; **73**: 1292-1297
- 34 Phillips MS, Bonatti H, Sauer BG, Smith L, Javaid M, Kahaleh M, Schmitt T. Elevated stricture rate following the use of fully covered self-expandable metal biliary stents for biliary leaks following liver transplantation. *Endoscopy* 2011; **43**: 512-517
- 35 Cantu P, Hookey LC, Morales A, Le Moine O, Devière J. The treatment of patients with symptomatic common bile duct stenosis secondary to chronic pancreatitis using partially covered metal stents: a pilot study. *Endoscopy* 2005; **37**: 735
- 36 Bakhru MR, Kahaleh M. Expandable metal stents for benign biliary disease. *Gastrointest. Endosc. Clin N Am* 2011; **21**: 447-62, viii.
- 37 Traina M, Tarantino I, Barresi L, Volpes R, Gruttadauria S, Petridis I, Gridelli B. Efficacy and safety of fully covered selfexpandable metallic stents in biliary complications after liver transplantation: a preliminary study. *Liver Transpl* 2009; **15**: 1493-1498
- 38 Mahajan A, Ho H, Sauer B, Phillips MS, Shami VM, Ellen K, Rehan M, Schmitt TM, Kahaleh M. Temporary placement of fully covered selfexpandable metal stents in benign biliary strictures: midterm evaluation (with video). *Gastrointest. Endosc* 2009; **70**: 303-309
- 39 Chaput U, Scatton O, Bichard P, Ponchon T, Chryssostalis A, Gaudric M, Mangialavori L, Duchmann JC, Massault PP, Conti F, Calmus Y, Chaussade S, Soubrane O, Prat F. Temporary placement of partially covered self-expandable metal stents for anastomotic biliary strictures after liver transplantation: a prospective, multicenter study. *Gastrointest. Endosc* 2010; **72**: 1167-1174
- 40 Park DH, Lee SS, Lee TH, Ryu CH, Kim HJ, Seo DW, Park SH, Lee SK, Kim MH, Kim SJ. Anchoring flap versus flared end, fully covered self-expandable metal stents to prevent migration in patients with benign biliary strictures: a multicenter, prospective, comparative pilot study (with videos). *Gastrointest Endosc* 2011; **73**: 64-70
- 41 Deviere J, Reddy N, Puspok A. Preliminary Results From a 187 Patient multicenter prospective trial using metal stents for treatment of benign biliary strictures. *Gastrointest Endosc* 2012; **75** ed:AB123
- 42 Deviere J, Nageshwar Reddy D, Püspök A, Ponchon T, Bruno MJ, Bourke MJ, Neuhaus H, Roy A, González-Huix Lladó F, Barkun AN, Kortan PP, Navarrete C, Peetermans J, Blero D, Lakhtakia S, Dolak W, Lepilliez V, Poley JW, Tringali A, Costamagna G; Benign Biliary Stenoses Working Group. Successful management of benign Biliary Strictures with fully covered self expanded Metal stents. *Gastroenterology* 2014; **147**: 385-395
- 43 Davis PH. Benign biliary strictures: surgery or endoscopy? *Ann Surg* 1993; **217**: 237-243
- 44 Lillemoe KD, Melton GB, Cameron JL, Pitt HA, Campbell KA, Talamini MA, Sauter PA, Coleman J, Yeo CJ. Postoperative bile duct stricture management and outcome in the 1990s. *Ann Surg* 2000; **232**: 430-41
- 45 Dolan JP, Diggs BS, Sheppard BC, Hunter JG. Ten year trend in national volume of bile duct injuries requiring operative repair. *Surg Endosc* 2005; **19**: 967-973
- 46 Peters JH, Ellison EC, Innes JT, Liss JL, Nichols KE, Lomano JM, Roby SR, Front ME, Carey LC. Safety and efficacy of laparoscopic cholecystectomy. A prospective analysis of 100 initial patients. *Ann Surg* 1991; **213**: 3-12
- 47 Costamagna G, Pandolfi M, Mutignani M, Spada C, Perri V. Long-term results of endoscopic management of postoperative bile duct strictures with increasing numbers of stents. *Gastrointest. Endosc* 2001; **54**: 162-168
- 48 Siclick JK, Camp MS, Lillemoe KD, Melton GB, Yeo CJ, Campbell KA, Talamini MA, Pitt HA, Coleman J, Sauter PA, Cameron JL. Surgical management of bile duct injuries sustained during laparoscopic cholecystectomy: perio-operative results in 200 patients. *Ann Surg* 2005; **241**: 786-792
- 49 Sikora SS, Pottakkat B, Srikanth G, Kumar A, Saxena R, Kapoor VK. Post-cholecystectomy benign biliary strictures-long term results. *Dig Surg* 2006; **23**: 304-312
- 50 DeMasi E, Fiori E, Lamazza A, Ansali A, Monardo F, Lutz SE, Recchioni G. Endoscopy in the treatment of benign biliary strictures. *Ital Journal of Gastroenterology and Hepatol* 1998; **30**: 91-95
- 51 Bergman JJ, Burgemeister L, Bruno MJ, Rauws EA, Gouma DJ, Tytgat GN, Huibregtse K. Long-term follow up after biliary stent placement for postoperative bile duct stenosis. *Gastrointest. Endosc* 2001; **54**: 154
- 52 Costamagna G, Pandolfi M, Mutignani M, Spada C, Perri V. Long-term results of endoscopic management of postoperative bile duct strictures with increasing numbers of stents. *Gastrointest. Endosc* 2001; **54**: 162-168
- 53 Tocchi A, Costa G, Lepre L, Liotta G, Mazzoni G, Sita A. The long-term outcome of hepaticojejunostomy in the treatment of benign bile duct strictures. *Ann Surg* 1996; **224**: 162-167
- 54 Mercado MA, Chan C, Orozco H, Villalta JM, Barajas-Olivas A, Eran J. Long-term evaluation of biliary reconstruction after partial resection of segments IV and V in iatrogenic injuries. *J Gastrointest Surg* 2006; **10**: 77-82
- 55 Walsh RM, Henderson JM, Vogt DP, Brown N. Long-term outcome of biliary reconstruction for bile duct injuries from laparoscopic cholecystectomies. *Surgery*. 2007; **142**: 450-6.
- 56 Vandenbroucke F, Plasse M, Dagenais M. Treatment of post liver transplantation bile duct stricture with self-expandable metallic stent. *HPB (Oxford)* 2006; **8**: 202-205
- 57 Garcia-Pajares F, Sanchez-Antolin G, Pelayo SL. Covered metal stents for the treatment of biliary complications after orthotopic liver transplantation. *Transplant Proc* 2010; **42**: 2966-2969
- 58 Hu B, Gao DJ, Yu FH, Wang TT, Pan YM, Yang XM. Endoscopic stenting for post-transplant biliary stricture: Usefulness of a novel removable covered metal stent. *J. HepatobiliaryPancreat. Sci.* 2011; **18**: 640-645
- 59 I. Tarantino, M. Traina, F. Mocciaro, L. Barresi, G. Curcio, M. Di Pisa, A. Granata, R. Volpes, B. Gridelli. Fully covered metallic stents in biliary stenosis after orthotopic liver transplantation. *Endoscopy* 2012; **44(3)**: 246-250
- 60 Carola Haapamäki, Marianne Udd, Jorma Halttunen, Outi Lindström, Heikki Mäkisalo & Leena Kylänpää. Endoscopic treatment of anastomotic biliary complications after liver transplantation using removable, covered, self-expandable metallic stents. *Scand. J Gastroenterol* 2012; **47**: 116-1121
- 61 Poley JW, Cahen DL, Metselaar HJ, van Buuren HR, Kazemier G, van Eijck CH, Haringsma J, Kuipers EJ, Bruno MJ. A prospective group sequential study evaluating a new type of fully covered self-expandable metal stent for the treatment of benign biliary strictures. *Gastrointest Endosc* 2012; **75**: 783
- 62 Sauer P, Chahoud F, Gotthardt D, Stremmel W, Weiss KH, Büchler M, Schemmer P, Weitz J, Schaible A. Temporary placement of fully covered self-expandable metal stents in biliary complications after liver transplantation. *Endoscopy* 2012; **44**: 536-538
- 63 Jorge Cerecedo-Rodriguez, Melissa Phillips, Paola Figueroa-Barojas, Sean C. Kumer, Monica Gaidhane, Timothy Schmitt, Michel Kahaleh. Self Expandable Metal Stents for Anastomotic Stricture Following Liver Transplant. *Dig Dis Sci* 2013; **58(9)**: 2661-2666
- 64 Greif F, Bronsther OL, Van Thiel DH, Casavilla A, Iwatsuki S, Tzakis A, Todo S, Fung JJ, Starzl TE. The incidence, timing, and management of biliary tract complications after orthotopic liver transplantation. *Ann Surg* 1994; **219**: 40-45
- 65 Gondolesi GE, Varotti G, Florman SS, Muñoz L, Fishbein TM,



- Emre SH, Schwartz ME, Miller C. Biliary complications in 96 consecutive right lobe living donor transplant recipients. *Transplantation* 2004; **77**: 1842-1848
- 66 Gunawansa N, McCall JL, Holden A, Plank L, Munn SR. Biliary complications following orthotopic liver transplantation: a 10-year audit. *HPB (Oxford)* 2011; **13**: 391-399
- 67 Pascher A, Nehaus P. Biliary complications after deceased donor orthotopic liver transplantation, *J Hepatobil. Pancreat Surg.* 2006; **13**: 487-496
- 68 Testa G, Malagò M, Broelseh CE. Complications of biliary tract in liver transplantation. *World J Surg* 2001; **25**: 1296-1299
- 69 Koneru B, Sterling MJ, Bahramipour PF. Bile duct strictures after liver transplantation: a changing landscape of the Achilles' heel. *Liver Transpl.* 2006; **12**: 702-704
- 70 Welling TH, Heidt DG, Englesbe MJ, Magee JC, Sung RS, Campbell DA. Biliary complications following liver transplantation in the model for end-stage liver disease era: effect of donor, recipient, and technical factors. *Liver Transpl.* 2008; **14**: 73-80
- 71 Maguire D, Rela M, Heaton ND. Biliary complication after orthotopic liver transplantation. *Transplantation Rev.* 2002; **16**: 220-440, heel. *Liver Transpl.* 2006; **12**: 702-4
- 72 Pascher A, Neuhaus P. Biliary complications after deceased donor orthotopic liver transplantation. *J Hepatobiliary Pancreat Surg.* 2006; **13**: 487-496
- 73 Sanchez-Urdazpal L, Gores GJ, Ward EM, Maus TP, Wahlstrom HE, Moore SB, Wiesner RH, Krom RA. Ischemic-type biliary complications after orthotopic liver transplantation. *Hepatology* 1992; **16**: 49-53
- 74 Kasahara M, Egawa H, Takada Y, Oike F, Sakamoto S, Kiuchi T. Biliary reconstruction in right lobe living-donor liver transplantation: comparison of different techniques in 321 recipients. *Ann Surg* 2006; **243**: 559-566
- 75 Greif F, Bronsther OL, Van Thiel DH, Casavilla A, Iwatsuki S, Tzakis A, Todo S, Fung JJ, Starzl TE. The incidence, timing and management of biliary tract complications after orthotopic liver transplantation. *Ann Surg* 1994; **219**: 40-45
- 76 Guichelaar MM, Benson JT, Malinchoc M, Krom RA, Wiesner RH, Charlton MR. Risk factors for clinical course of non anastomotic biliary strictures after liver transplantation. *Am J Transplant* 2003; **3**: 885-890
- 77 Buis CI, Hoekstra H, Verdonk RC, Porte RJ. Causes and consequences of ischemic-type biliary lesions after liver transplantation. *J Hepatobiliary Pancreat Surg.* 2006; **13**: 517-524
- 78 Guichelaar MM, Benson JT, Malinchoc M, Krom RA, Wiesner RH, Charlton MR. Risk factors for and clinical course of nonanastomotic biliary strictures after liver transplantation. *Am J Transplant* 2003; **3**: 885
- 79 Ito K, Siegelman ES, Stolpen AH, Mitchell DG. MR imaging complications after liver transplantation. *AJR* 2000; **175**: 1145-1149
- 80 Verdonk RC, Buis CI, van der Jagt EJ, Gouw AS, Limburg AJ, Slooff MJ, Peeters PMJG, de Jong KP, Kleibeuker JH, Haagsma EB. Non-anastomotic biliary strictures after liver transplantation, part 2: management, outcome, and risk factors for disease progression. *Liver Transpl.* 2007; **13**: 725-732
- 81 Sharma S, Gurakar A, Jabbour N. Biliary strictures following liver transplantation: past, present and preventive strategies. *Liver Transpl.* 2008; **14**: 759-769
- 82 Tsujino T, Isayama H, Sugawara Y, Sasaki T, Kogure H, Nakai Y, Yamamoto N, Sasahira N, Yamashiki N, Tada M, Yoshida H, Kokudo N, Kawabe T, Makuuchi M, Omata M. Endoscopic management of biliary complications after adult living donor liver transplantation. *Am J Gastroenterol* 2006; **101**: 2230-2236
- 83 Graziadei IW, Schwaighofer H, Koch R, Nachbaur K, Koenigsrainer A, Margreiter R, Vogel W. Long-term outcome of endoscopic treatment of biliary strictures after liver transplantation. *Liver Transpl* 2006; **12**: 718-725
- 84 Verdonk RC, Buis CI, van der Jagt EJ, Gouw AS, Limburg AJ, Slooff MJ, Kleibeuker JH, Porte RJ, Haagsma EB. Non anastomotic biliary strictures after liver transplantation, part 2: management, outcome, and risk factors for disease progression. *Liver Transpl* 2007; **13**: 725-732
- 85 Tada S, Yazumi S, Chiba T. Endoscopic management is an accepted first-line therapy for biliary complications after adult living donor liver transplantation. *Am J Gastroenterol* 2007; **102**: 1331
- 86 Zhao D, Zepeda-Gomez S, Tandon P, Bain VG. Managing the post liver transplantation anastomotic biliary stricture: multiple plastic versus metal stent: a systematic review. *Gastrointest. Endosc* 2013; **77**(5): 679-691
- 87 Adler DG, Lichtenstein D, Baron TH, Davila R, Egan JV, Gan SL, Qureshi WA, Rajan E, Shen B, Zuckerman MJ, Lee KK, VanGuilder T, Fanelli RD. The role of endoscopy in patients with chronic pancreatitis. *Gastrointest. Endosc* 2006; **63**: 933-937
- 88 Aranha GV, Prinz RA, Freeark RJ, Greenlee HB. The spectrum of biliary tract obstruction from chronic pancreatitis. *Arch Surg* 1984; **119**: 595-600
- 89 Cahen DL, van Berkel AM, Oskam D, Rauws EA, Weverling GJ, Huijbregtse K, Bruno MJ. Long term results of endoscopic drainage of common bile duct strictures in chronic pancreatitis. *Eur J Gastroenterol. Hepatol* 2005; **17**: 103-108
- 90 Pozsar J. Medium term results of endoscopic treatment of common bile duct strictures in chronic calcifying pancreatitis with increasing numbers of stents. *J Clin Gastroenterol* 2004; **38**: 118-23
- 91 Stefan Kahl, Sandra Zimmermann, Bernhard Glasbrenner, Matthias Pross, Hans-Ulrich Schulz, Deirdre McNamara, Peter Malfertheiner. Treatment of benign biliary strictures in chronic pancreatitis by self expandable metal stent. *Dig Dis* 2002; **20**(2): 199-203
- 92 van Berkel AM. Self-expanding metal stents in benign biliary strictures due to chronic pancreatitis. *Endoscopy* 2004; **35**: 381-84
- 93 Dumonceau JM. Plastic and metal stents for postoperative benign bile duct strictures: the best and the worst. *Gastrointest. Endosc* 1998; **47**: 8-17
- 94 Catalano MF, Linder JD, George S. Treatment of symptomatic distal common bile duct stenosis secondary to chronic pancreatitis: comparison of single vs. multiple simultaneous stents. *Gastrointest Endosc* 2004; **60**: 945-952
- 95 Siriwardana HPP, Siriwardena AK. Systematic appraisal of the role of metallic endobiliary stents in the treatment of benign bile duct stricture. *Ann Surg* 2005; **242**: 10-19
- 96 Cantù P, Hookey LC, Morales A. The treatment of patients with symptomatic common bile duct stenosis secondary to chronic pancreatitis using partially covered metal stents: a pilot study. *Endoscopy* 2005; **37**: 735-739
- 97 Deviere J, Cremer M, Baize M, Love J, Sugai B, Vandermeeren A. Management of common bile duct stricture caused by chronic pancreatitis with metal mesh self expandable stents. *Gut* 1994; **35**: 122-126.
- 98 van Berkel AM, Cahen DL, van Westerloo DJ. Self-expanding metal stents in benign biliary strictures due to chronic pancreatitis. *Endoscopy* 2004; **36**: 381-384
- 99 Bruno M, Boermeester M, Rauws E. Use of removable covered expandable metal stents (RCEMS) in the treatment of benign distal common bile duct (CBD) strictures: a feasibility study. *Gastrointest. Endosc* 2005; **61**: AB199
- 100 Tringali A, Di Matteo F, Iacopini F. Common bile duct strictures due to chronic pancreatitis managed by self-expandable-metal stents (SEMS): results of a long-term follow-up study. *Gastrointest. Endosc* 2005; **61**: AB220
- 101 Kahaleh M, Behm B, Clarke BW. Temporary placement of covered self-expandable metal stents in benign biliary strictures: a new paradigm? (with video). *Gastrointest. Endosc* 2008; **67**: 446-54; **40**: 697-700
- 102 Behm B, Brock A, Clarke BW, Northup PG, Dumonceau JM,



- Kahaleh M. Partially covered self-expandable metallic stents for benign biliary strictures due to chronic pancreatitis. *Endoscopy* 2009; **41**: 547-551
- 103 Cahen DL, Rauws EA, Gouma DJ, Removable fully covered selfexpandable metal stents in the treatment of common bile duct strictures due to chronic pancreatitis: a case series. *Endoscopy* 2008; **40(8)**: 697-700
- 104 Perri T al I. Boškoski, A. Tringali. Fully covered self-expandable metal stents in biliary strictures caused by chronic pancreatitis not responding to plastic stenting: a prospective study with 2 years of follow-up. *Gastrointestinal Endoscopy* 2012; **75(6)**: 1271-1277
- 105 Tischendorf JJ, Kruger M, Trautwein C. Cholangioscopic characterization of dominant bile duct stenoses in patients with primary sclerosing cholangitis. *Endoscopy* 2006; **38**: 665-669
- 106 Farrant JM, Hayllar KM, Wilkinson ML. Natural history and prognostic variables in primary sclerosing cholangitis. *Gastroenterology* 1991; **100**: 1710-1717
- 107 van Milligen de Wit AW, van Bracht J, Rauws EA. Endoscopic stent therapy for dominant extrahepatic bile duct strictures in primary sclerosing cholangitis. *Gastrointest Endosc* 1996; **44**: 293
- 108 Lee JG, Schutz SM, England RE, et al. Endoscopic therapy of sclerosing cholangitis. *Hepatology* 1995; **21**: 661-667
- 109 Stiehl A, Rudolph G, Sauer P. Efficacy of ursodeoxycholic acid treatment and endoscopic dilation of major duct stenoses in primary sclerosing cholangitis. An 8-year prospective study. *J Hepatol* 1997; **26**: 560-566
- 110 Baluyut AR, Sherman S, Lehman GA. Impact of endoscopic therapy on the survival of patients with primary sclerosing cholangitis. *Gastrointest Endosc* 2001; **53**: 308-312
- 111 Gluck M, Cantone NR, Brandabur JJ. A twenty-year experience with endoscopic therapy for symptomatic primary sclerosing cholangitis. *J Clin Gastroenterol* 2008; **42**: 1032-1039. 123-125
- 112 Muhsin Kaya, Bret T. Petersen, Paul Angulo, Todd H. Baron, James C. Andrews, Christopher J. Gostout, Keith D. Lindor. Balloon dilation compared to stenting of dominant strictures in primary sclerosing cholangitis. *Am J Gastroenterol* 2001; **96**: 1059-1066
- 113 Ponsioen CY, Lam K, van Milligen de Wit AW. Four years experience with short term stenting in primary sclerosing cholangitis. *Am J Gastroenterol* 1999; **94**: 2403-2407
- 114 Zen Y, Nakanuma Y. IgG4 cholangiopathy. *Am J Surg Pathol* 2004; **28**: 1193-203; Björnsson E, Chari ST, Smyrk TC, Lindor K. Immunoglobulin G4 associated cholangitis: description of an emerging clinical. *Hepatology* 2007; **45**: 1547-1554
- 115 Nakazawa T, Ohara H, Sano H. Cholangiography can discriminate sclerosing cholangitis with autoimmune pancreatitis from primary sclerosing cholangitis. *Gastrointest Endosc* 2004; **60**: 937-944
- 116 Nakazawa T, Naitoh I, Hayashi K. Diagnostic criteria for IgG4-related sclerosing cholangitis based on cholangiographic classification. *J Gastroenterol* 2012; **47(1)**: 79-87
- 117 Kalaitzakis E, Levy M, Kamisawa T. Endoscopic retrograde cholangiography does not reliably distinguish IgG4-associated cholangitis from primary sclerosing cholangitis or cholangiocarcinoma. *Clin Gastroenterol Hepatol* 2011; **9**: 800-3 e2.130
- 118 Small AJ, Loftus CG, Smyrk TC, Baron TH. et al. A case of IgG4-associated cholangitis and autoimmune pancreatitis responsive to Nat Clin Pract gastroenterol & hepatol 2008; **5**: 707-12
- 119 Benhamou Y, Caumes E, Gerosa Y. AIDS-related cholangiopathy. Critical analysis of a prospective series of 26 patients. *Dig Dis Sci* 1993; **38**: 1113-1118
- 120 Cello JP, Chan MF. Long-term follow-up of endoscopic retrograde cholangiopancreatography sphincterotomy for patients with acquired immune deficiency syndrome papillary stenosis. *Am J Med* 1995; **99**: 600-603
- 121 Castiella A, Iribarren JA, Lopez P. Ursodeoxycholic acid in the treatment of AIDS-associated cholangiopathy. *Am J Med* 1997; **103**: 170-171
- 122 Khuroo MS, Yattoo GN, Zargar SA, Javid G, Dar MY, Khan BA, Boda MI. Biliary abnormalities associated with extrahepatic portal venous obstruction. *Hepatology* 1993; **17**: 807-813
- 123 Bayraktar Y, Balkanci F, Kayhan B, Ozenç A, Arslan S, Telatar H. Bile duct varices or "pseudo-cholangiocarcinoma sign" in portal hypertension due to cavernous transformation of the portal vein. *Am J Gastroenterol* 1992; **87**: 1801-1806
- 124 Sezgin O, Oguz D, Attintas E, Saritas U, Sahin B. Endoscopic management of biliary obstruction caused by cavernous transformation of the portal vein. *Gastrointest Endosc* 2003; **68**: 602-608
- 125 Sarin SK, Bhatia V, Makwane U. Portal biliopathy in extrahepatic portal vein obstruction. *Indian J Gastroenterol* 1992; **2**: A82
- 126 Bhatia V, Jain AK, Sarin SK. Choledocholithiasis associated with portal biliopathy in patients with extrahepatic portal vein obstruction. Management with endoscopic sphincterotomy. *Gastrointest Endosc* 1995; **42**: 178-181
- 127 Thervet L, Faulques B, Pissas A, Bremond A, Monges B, Salducci J, Grimaud JC. Endoscopic management of obstructive jaundice due to portal cavernoma. *Endoscopy* 1993; **25**: 423-425
- 128 Lopez RR, Cosenza CA, Lois J, Hoffman AL, Sher LS, Noguchi H, Pan SH, McMonigle M. Long-term results of metallic stents for benign biliary strictures. *Arch Surg* 2001; **136**: 664-669
- 129 Dhiman RK, Behera A, Chawla YK, Dilawari JB, Suri S. Portal hypertensive biliopathy. *Gut* 2007; **56**: 1001-1008
- 130 Lohr JM, Kuchenreuter S, Grebmeier H, Hahn EG, Fleig WE. Compression of the common bile duct due to portal vein thrombosis in polycythemia vera. *Hepatology* 1993; **17**: 586-592
- 131 Mercado-Díaz MA, Hinojosa CA, Chan C, Anthon FJ, Podgaetz E, Orozco H. [Portal biliopathy]. *Rev. Gastroenterol Mex* 2004; **69**: 37-41
- 132 Solmi L, Rossi A, Conigliaro R, Sassatelli R, Gandolfi L. Endoscopic treatment of a case of obstructive jaundice secondary to portal cavernoma. *Ital J Gastroenterol Hepatol* 1998; **30**: 202-204
- 133 Tighe M, Jacobson I. Bleeding from bile duct varices as unexpected hazard during therapeutic ERCP. *Gastrointest Endosc* 1996; **43**: 25-252
- 134 Mutignani M, Shah SK, Bruni A, Perri G, Costamagna. Endoscopic treatment of extrahepatic bile duct strictures in patients with portal biliopathy carries a high risk of hemobilia: report of 3 cases. *Dig. Liver Dis* 2002; **34**: 587-591
- 135 Dumortier J, Vaillant E, Boillot O, Poncet G, Henry L, Scoazec J, Partensky C, Valette PJ, Paliard P, Ponchon T. Diagnosis and treatment of biliary obstruction caused by portal cavernoma. *Endoscopy* 2003; **35**: 446-450
- 136 Perlemuter G, Bejanin H, Fritsch J. Biliary obstruction caused by portal cavernoma: a study of 8 cases. *J Hepatol* 1996; **25**: 58-63
- 137 Dhiman RK, Puri P, Chawla Y. Biliary changes in extrahepatic portal venous obstruction: compression by collaterals or ischemic? *Gastrointest Endosc* 1999; **50**: 646-652
- 138 Ginsberg G, Cope C, Shah J, Martin T, Carty A, Habecker P, Kaufmann C, Clerc C, Nuutinen JP, Tormala P. In vivo evaluation of a new bioabsorbable self-expanding biliary stent. *Gastrointest Endosc* 2003; **58**: 777-784
- 139 Meng B, Wang J, Zhu N, Meng QY, Cui FZ, Xu YX. Study of biodegradable and self-expandable PLLA helical biliary stent *in vivo* and *in vitro*. *J Mater Sci Mater Med* 2006; **17**: 611-617

**Peer reviewers:** Hiroshi Yoshida, Director and Professor, Department of Surgery, Nippon Medical School Tama Nagayama Hospital, 1-7-1 Nagayama, Tama-city, Tokyo, 206-8512, Japan; Daniel Neureiter, MD, M.A., ÖÄK-Fortbildungsdiplom, Leitender Oberarzt, Universitätsinstitut für Pathologie, Paracelsus Medizinische Privatuniversität, Gemeinnützige Salzburger Landeskliniken Betriebsgesellschaft mbH, Müllner Hauptstr. 48, A-5020 Salzburg, Austria; Suk Kim, Department of diagnostic radiology, College of Medicine, Pusan National University & Pusan National University Hospital, Busan 602739, South Korea.