

Lithium Disk Battery: The Silent Killer

Alfredo Rossi, Arrigo Barabino, Silvia Vignola, Marta Bini

Alfredo Rossi, Medical Director of the “Società Nazionale di Salvamento”, Genoa, Italy

Arrigo Barabino, Head of Gastroenterology and Digestive Endoscopy Unit, Istituto G. Gaslini (IGG), Genoa, Italy

Silvia Vignola, Gastroenterology and Digestive Endoscopy Unit, Istituto G. Gaslini (IGG), Genoa, Italy

Marta Bini, Interventional Endoscopic Department, Niguarda Ca' Granda Hospital, Milan, Italy

Correspondence to: Alfredo Rossi, Medical Director of the “Società Nazionale di Salvamento”, Genoa, Italy

Email: selika2@libero.it

Telephone: +3394510532

Fax: +390264221892

Received: June 1, 2015

Revised: June 20, 2015

Accepted: June 23, 2015

Published online: July 21, 2015

ABSTRACT

Over the last ten years the ingestion of disk battery have been increasing in children with serious consequences. The severity of injury is mostly related to the growing diffusion of new lithium batteries (LB) that may cause catastrophic damages when lodged in the esophagus. In most cases deaths are direct consequence of high flow fistula which occurs between esophagus and aorta or other major vascular mediastinic vessel. Therefore, the primary goal of the management should be to evaluate the possible vascular (aortic) involvement before to endoscopically remove the battery itself. We propose a new protocol for its management. Treatment of LB ingestion requires a multidisciplinary approach that can be implemented only in a tertiary pediatric hospital. Surgery can play an important role. Advice is provided for primary care physicians to correctly approach this emergent and potentially fatal hazard.

Key words: Lithium battery ingestion; Aorto-esophageal fistula; Children

Rossi A, Barabino A, Vignola S, Bini M. Lithium Disk Battery: The Silent Killer. *Journal of Gastroenterology and Hepatology Research* 2015; 4(7): 1684-1688 Available from: URL: <http://www.ghrnet.org/index.php/joghr/article/view/1304>

INTRODUCTION

Accidental ingestion by children of disk batteries, and particularly of the lithium ones, has been increasingly reported over the last ten years. Consequences, especially in case of children aged from few months to 2-3 years, may be catastrophic: 38 deaths in children have been reported worldwide so far^[1]. Twenty-six of 32 deaths have been related to a high flow fistula between esophagus and aorta (AEF) or other major mediastinic vessels.

The fistula is generated from the esophageal seat where the battery is trapped.

To our knowledge only one survivor of button battery-induced AEF has been described^[2] so that any effort should be done to prevent this rare but fatal consequence.

Children with AEF and bleeding related to other reasons, such as a double aortic arch, have indeed been successfully managed^[3]. In order to stop the continuing rise in life-threatening injuries, a national Button Battery Task Force was recently established in USA, aimed to pursue a comprehensive approach to injury prevention^[4].

In light of the documented and early harmfulness of lithium batteries the main question now seems to be a global change in the cultural attitude and then in the following strategy of the all professional team who is facing such a critical event.

Therefore, the real goal should consist not so much to remove the battery from the esophagus by endoscopists, but to first check for the

possible visceral damage, especially regarding the aortic or vascular involvement.

As a consequence, the documented ingestion of a lithium battery, particularly when esophageal-trapped, should be managed by a multidisciplinary team in a hospital equipped for pediatric emergencies, including the possibility of cardiothoracic surgery.

According to these concepts and with the aim to contribute to reduce the battery-related lethality, we propose a new more severe algorithm for the management of the ingested lithium disk batteries.

THE LITHIUM DISK BATTERY (LB)

LD is an electrical cell usually characterized by two main features (see Figure 1):

- High voltage (3 or more Volts)
- Particular large and thin shape

LB are bigger (>20 mm diameter) and flatter than the alkaline disk batteries (1.5 V). The most common imprint codes of LB are CR2032, CR2025, CR2016, where CR (or DL) stands for lithium. The first two numbers indicate the diameter in millimeters and the other the height in ten-millimeters. Since they do not contain an alkaline electrolyte, leakage is not a cause of injury. In small children the ingestion of such cells increases the risk of esophageal lodgment and significant tissue damage in just two hours^[1,5-7]. Cells that are “dead” or “spent” still retain sufficient residual voltage to generate hydroxide and cause severe,even fatal, tissue damage^[4].

The severity of injury caused by a LB depends on cell type, size, voltage, location and time of tight contact with the mucosa.

The mechanisms by which a disk battery is able to determine tissue damage may be identified as follows:

1. Electrical generation of hydroxide ions at the negative pole causing a tissue damage (like an alkaline burn) that is proportional to the battery voltage. Mucosal secretions are considerable good electrical conductors. This condition allows the generation of a current concentrated to the anodic pole of the battery. It follows rapidly the tissue electrolysis with generation of hydroxides; these strong bases are highly caustic, leading to the colliquative necrosis. Since the LB have a dual voltage in relation to the other button cells and a greater capacitance, they are able to generate a higher current and to produce greater amounts of hydroxide.




Figure 1 Lithium disk battery, front and back.

2. Leakage of alkaline content. This could happen in case of long stay into the gastric cavity, as the acid juice is able to split the battery by dissolving the plastic ring which separates the two poles. However, as stated above, LB do not contain significant amount of alkaline electrolytes.

3. Mechanical pressure, by close contact with a visceral wall, that could be worsened by reactive esophageal contracture.

The LB first determines a deep ulceration of the gut wall and subsequently slow and progressive tissue destruction, starting at the anode site. The destructive process can then pass the visceral layers and involve adjacent structures. Most severe cases concern the involvement of mediastinal vascular structures such as the aorta. It should be noted that the histopathological damage of LB often persists even after removal of the battery itself. Several injuries are documented in relation to ingestion and trapping in the esophagus of LB. The common denominator appears in any case due to the necrotizing potential of LB which, depending on the spatial orientation of the anodic region, can involves time to time various anatomical structures.

Table 1 shows all the possible documented consequences related to esophageal-trapped LB.

Table 1 Pathological consequences of esophageal-trapped LB.
Esophageal perforation with mediastinitis
Aorto-esophageal fistula with severe acute digestive hemorrhage
Esophageal or tracheal stenosis
Tracheomalacia
Vocal cords paralysis by recurrent nerve involvement
Aspiration pneumonia
Empyema and pulmonary abscess
Spondylodiscitis

EPIDEMIOLOGY AND STATE OF ART

92% of batteries involved in fatal cases or with heavy sequelae is represented by LB with a diameter of 20 of more millimeters.

The analysis of the Literature shows indeed the combination of at least two conditions: (1) a relative increase of disk batteries ingestion (all types) by the pediatric population. The trend is confirmed by the survey widely conducted in the US by the NEISS and reported by CDC - Atlanta (Figure 2); (2) the percentage increase in the production and marketing of the LB, in comparison with conventional manganese, silver oxide and cadmium batteries. Consequently, the ingestion of LB has been growing same time, as well as the related mortality^[5,6].

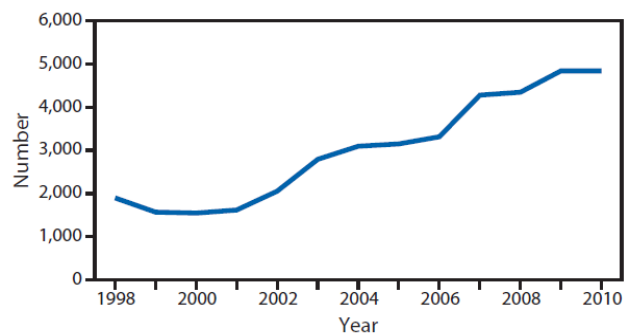


Figure 2 Estimated annual number of emergency department-treated battery injuries involving children aged < 13 years. National Electronic Injury Surveillance System (NEISS), USA, 1998-2010.

The National Capital Poison Center (NCPC, website: www.poison.org) provides a continuous and updated worldwide surveillance of the ingested disk batteries.

At the end of april 2015, the "counter" of the NCPC recorded 39 deaths.

However, it must be emphasized that the register refers only patients with available and published documentation, what is characteristic of the Western world and only in part of the Eastern one. Thus, the real epidemiological data are probably underestimated.

SYMPTOMS AND CLINICAL PRESENTATIONS

Making an early diagnosis is a clinical challenge, that has significant implications on primary care setting^[8]. Battery ingestion is not witnessed in 92% of fatal outcomes and 56% of major complications; 36% of patients with esophageal batteries lodgment are initially asymptomatic^[6]. Clinical presentation can be extremely variable and difficult to recognize if the ingestion is not reported by a witness. The child with a battery located in the GI tract can be symptom-free or may present typical symptoms such as drooling, dysphagia, vomiting, chest pain, or dyspnea. Atypical symptoms are fever, abdominal pain, irritability and feeding refusal.

Sudden fatal exsanguination for a fistula between esophagus or other major mediastinal vessels can also be a dramatic presentation^[4,6,9]. Other possible complications, as summarized in table 1, are: tracheo-esophageal fistula, laryngeal or esophageal stenosis, esophageal perforation, vocal cord paralysis, tracheomalacia, aspiration pneumonia, empyema, lung abscess, and spondylodiscitis^[6].

Complications can be delayed, as the mucosal lesions may worsen also after cell removal. Plain chest and abdomen X-ray investigations have a primary role in addressing the diagnosis and to locate the battery, that may be revealed by the presence of the double ring or "halo" effect (see Figure 3).

Urgent endoscopic removal of the LB depends on the clinical presentation.

A "sentinel bleed", i.e., an isolated hematemesis or melena occurring hours or days before a fatal hemorrhage, is another atypical presenting symptom reported in the 2011^[9]. Exsanguination can occur with the battery still in the GI tract or after its removal. The interval between battery removal and fatal hemorrhage ranges between 2 and 28 days^[1,4]. In stable patients with "sentinel bleeds" there is a time window that allows a successful surgical intervention, as suggested by the protocol developed by Brumbaugh and coworkers^[9].

MANAGEMENT: PROPOSAL OF A NEW MULTISCIPLINARY PROTOCOL

As stated above, clinical guidelines regarding the management of new dangerous foreign bodies ingestion in children, such as button lithium

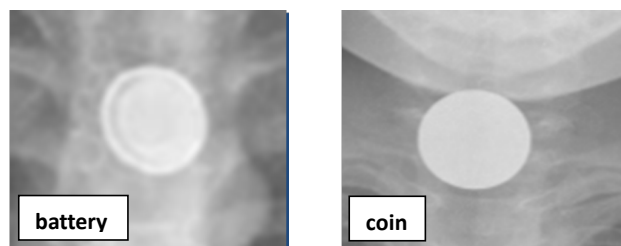


Figure 3 Radiological appearance of a LB and a coin.

battery and high-powered magnet, remain varied and sporadic with little in the way of prospective data to guide their development^[10].

On the other hand the high mortality resulting in the establishment of a high flow esophago-vascular fistula should lead to a radical change of mentality.

In fact, it should not be important the endoscopic removal of the battery rather than the primary documentation of esophageal damage and especially of the aortic involvement.

Otherwise, in many cases, the removal of a deeply inserted battery, like a cap, into the esophageal wall may suddenly accelerate and make active and lethal the underlying vascular fistula, giving rise to a torrential and uncontrollable hemorrhage.

Hence, the need for a multidisciplinary and complex procedure, which in severe cases should include the possibility of a surgical thoraco-vascular access with intraoperative endoscopy in properly equipped hospital.

The indication for such aggressive and emergent intervention is especially recommended if the clinical presentation is made up of bleeding, either active or previous ("sentinel bleeding"), statistically indicator of severe injuries, which could rapidly progress.

The protocol we present in figure 4 has been submitted, with general acceptance, to a wide panel of Italian experts in the field of pediatric emergency: endoscopists, radiologists, surgeons, intensivists (Table 2).

Most of them belonging to the Italian Society for Pediatric Gastroenterology, Hepatology and Nutrition (SIGENP).

As can be seen, it has been emphasized some operating conditions in order to prevent, in most severe patients and particularly in case of esophageal-trapped LB, the rapid progression of the visceral damage towards a lethal outcome: (1) the primary need to exactly document the location of LB in the digestive tract; (2) the need to record any

Table 2 Panel of experts in management of pediatric emergencies.	
Author	Affiliation
Arrigo Vittorio Barabino, MD	Gastroenterology and Digestive Endoscopy Unit, Istituto G. Gaslini (IGG), Genoa, Italy
Filippo Torrioni, MD	Digestive Surgery and Endoscopy Unit, Ospedale Pediatrico Bambino Gesù (OPBG), Rome, Italy
Paolo Gandullia, MD	Gastroenterology and Digestive Endoscopy Unit, Istituto G. Gaslini (IGG), Genoa, Italy
Silvia Vignola, MD	Gastroenterology and Digestive Endoscopy Unit, Istituto G. Gaslini (IGG), Genoa, Italy
Serena Arrigo	Gastroenterology and Digestive Endoscopy Unit, Istituto G. Gaslini (IGG), Genoa, Italy
Angela Calvi, MD	Gastroenterology and Digestive Endoscopy Unit, Istituto G. Gaslini (IGG), Genoa, Italy
Paola De Angelis, MD	Digestive Surgery and Endoscopy Unit, Ospedale Pediatrico Bambino Gesù (OPBG), Rome, Italy
Luigi Dall'Oglio, MD	Digestive Surgery and Endoscopy Unit, Ospedale Pediatrico Bambino Gesù (OPBG), Rome, Italy
Lucio Zannini, MD	Cardiovascular Surgery, Istituto G. Gaslini, Genoa, Italy
Girolamo Mattioli, MD	General Pediatric Surgery, Istituto G. Gaslini, Genoa, Italy
Gianmichele Magnano, MD	Radiology Department, Istituto G. Gaslini, Genoa, Italy
Pietro Tuo, MD	Intensive Care Unit, Istituto G. Gaslini, Genoa, Italy
Pasquale Di Pietro, MD	Emergency Medicine, Istituto G. Gaslini, Genoa, Italy
Marta Bini, MD	Interventional Endoscopy Unit, Ospedale Niguarda Ca'Granda, Milan, Italy
Alfredo Rossi, MD	Società Nazionale di Salvamento, Genoa, Italy

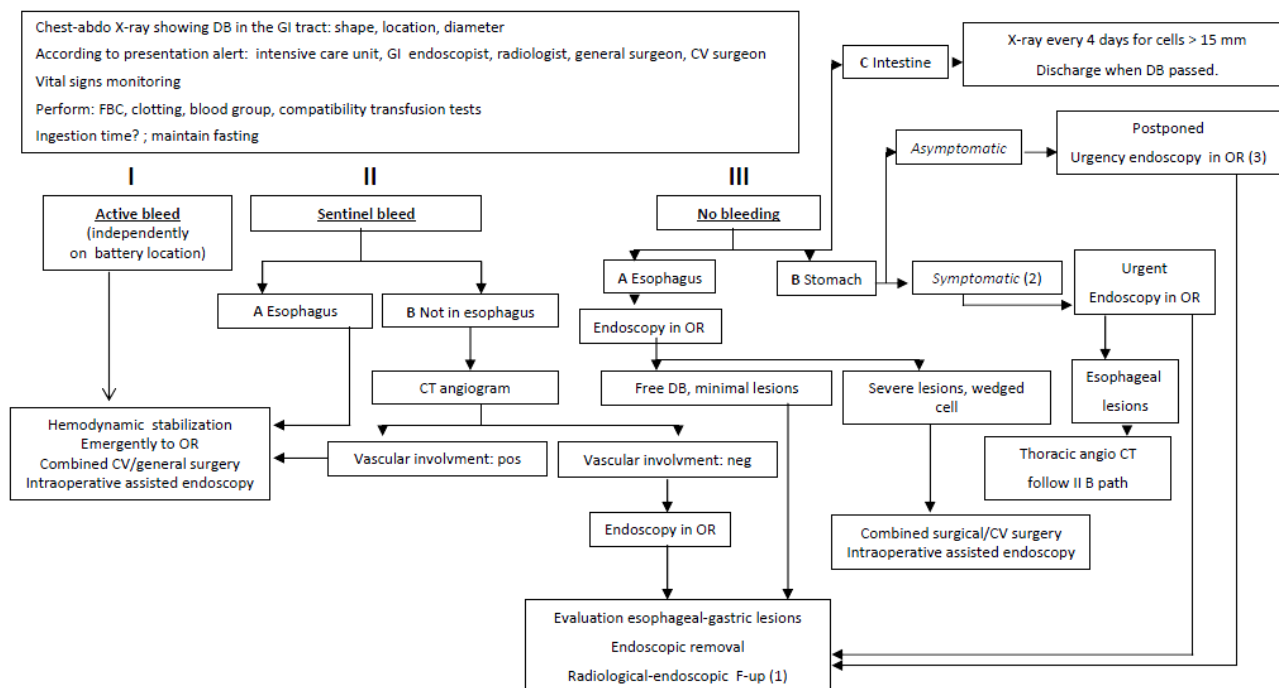


Figure 4 Algorithm for the management of ingested Disk Batteries in children (Lithium Batteries or Alkaline Batteries). 1 The follow-up, above all in case of esophageal lesion, should monitor possible late onset esophageal perforation or vessel fistula. 2 Consider all symptoms, excluding bleeding. 3 Endoscopy can be postponed within 48 hrs in not passed cells; reduce the waiting time in case of alkaline battery, very young age or not witnessed ingestion. DB: disk battery; GI: gastrointestinal; CV: cardio-vascular; FBC: full blood count; OR: operating room equipped for cardio-vascular surgery; CT angiogram: computed tomography angiogram; F-up: follow-up.

involvement of mediastinal vascular structures; (3) the combination of surgical and endoscopic procedure, performed in an operating room equipped for thoraco-vascular interventions.

Given the complexity of this algorithm it is evident that its application could be possible only in general or pediatric hospitals (reference centers), where all the required logistics and professionals can be quickly alerted and collected.

However, since in most cases the access to the First Aid Department can take place in peripheral and so not equipped hospitals, it seems useful to suggest the organization of a wide network connection.

Particularly, some recommendations concerning the behavior to be taken by peripheral hospitals can be summarized as follows: (1) knowledge of the problem and then the potential risk of severe complications and related mortality; (2) identification of the nearest Reference Center: kind of cooperation and channel for rapid transfer of the patient should be already established; (3) documentation of type and location of the battery, by means of thoraco-abdominal X-ray with appropriate projections; (4) transfer with the most appropriate timing, based on clinical presentation and radiological findings; (5) safe transfer by proper staff, in line with this type of emergency: anesthetist and dedicated nurse.

A such complex organization could represent a real challenge and is certainly expensive. However it must be pointed out that, despite the relative rarity of the event, the mortality related to the LB ingestion justifies in our opinion the commitment.

CONCLUSION

DB and particularly LB ingestion has become a rising community hazard that can have fatal evolution. For not witnessed ingestions, misdiagnosis are possible due to nonspecific presenting symptoms. This new proposed protocol produces new concepts about the clinical

management of this risky pediatric emergency. Additional clinical studies may be necessary to clarify aspects based on expert opinion rather than on published prospective data, and these guidelines may be revised as needed to account for new data, changes in clinical practice or availability of new technology^[10].

Among preventive intervention to be considered, public awareness campaigns should be promoted by Scientific Societies, as well as preventive information addressed to parents and caregivers^[4].

Furthermore, product manufacturers should be forced to redesign DB-powered house-hold products to secure the battery compartment. The recent experimental construction of a waterproof, pressure-sensitive coating harnessing a commercially available LB, could be a promise for an efficient prevention^[14].

CONFLICT OF INTERESTS

There are no conflicts of interest with regard to the present study.

REFERENCES

- 1 National Capital Poison Center: <http://www.poisson.org/battery/fatalcases.asp>
- 2 Spiers A, Jamil S, Whan E, Forbes D, Gollow I, Andrews D. Survival of patient after aorto-oesophageal fistula following button battery ingestion. *ANZ Journal of Surgery* 2012; **82**: 186-187
- 3 van Woerkum F, Bont L, Haas F, Freund M, van Gestel S. Aorto-esophageal fistula due to double aortic arch and prolonged nasogastric intubation: case report and review of the literature. *Eur J Pediatr* 2006; **165**: 660-601
- 4 Jatana KR, Litovitz T, Reilly JS, Koltai PG, Rider G, Jacobs IN. Pediatric button battery injuries: 2013 task force update. *International Journal of Pediatric Otorhinolaryngology* 2013; **77**: 1392-1399
- 5 Litovitz T, Whitaker N, Clark L Preventing battery ingestions: an analysis of 8648 cases. *Pediatrics* 2010; **125**: 1178-1183

- 6 Litovitz T, Whitaker N, Clark L, White NC, Marsolek M. Emerging battery ingestion hazard: clinical implications. *Pediatrics* 2010; **125**: 1168-1177
- 7 Tanaka J, Yamashita M, Yamashita M. Esophageal electrochemical burns due to button type lithium batteries in dogs. *Vet Hum Toxicol* 1998; **40**: 193-196
- 8 Shepherd M, Hamill JK, Barker R.J. Button battery injury in children - a primary care issue? *Prim Health Care* 2014; **6**: 69-72
- 9 Brumbaugh DE, Colson SB, Sandoval JA, Karrer FM, Bealer JF, Litovitz T, Kramer RE. Management of button battery-induced hemorrhage in children. *J Pediatr Gastroenterol Nutr* 2011; **52**: 585-589
- 10 Kramer RE, Lerner DG, Lin T, Manfredi M, Shah M, Stephen TC, Gibbons TE, Pall H, Sahn B, McOmber M, Zacur G, Friedlander J, Quiros AJ, Fishman DS, Mamula P. Management of ingested foreign bodies in children: a clinical report of the NASPGHAN endoscopy committee. *J Pediatr Gastroenterol Nutr* 2015 Jan 21. [Epub ahead of print]
- 11 American Society of Gastrointestinal Endoscopy Guidelines. Management of ingested foreign bodies and food impactions. *Gastrointest Endoscopy* 2011; **73**: 1085-1091
- 12 Hill SJ, Zarroug AE, Ricketts RR, Weeraswamy R. Bedside placement of an aortic occlusion balloon to control a ruptured aorto-esophageal fistula in a small child. *Ann Vasc Surg* 2010; **24**: 822.e7-9
- 13 Takagaki K, Perito ER, Jose FA, Heyman MB. Gastric mucosal damage from ingestion of 3 button cell batteries. *J Pediatr Gastroenterol Nutr* 2011; **53**: 222-223
- 14 Laulicht B, Traverso G, Deshpande V, Langer R, Karp JM. Simple battery armor to protect against gastrointestinal injury from accidental ingestion. *Proc Natl Acad Sci* 2014; **111**: 16490-16495

Peer reviewer: Hiroto Kita, Professor and Chair, Department of Gastroenterology, Director of Endoscopy, Saitama Medical University International Medical Center, 1397-1, Yamane, Hidaka, Saitama, Japan.