

## Clinicopathological Study of Minute Gastric Carcinoma in Surgically Resected Multiple Gastric Carcinoma Cases

Hirotaaka Nakashima, Ryuji Nagahama, Yasuo Ohkura, Michiyo Owari, Nobuhiro Sakaki, Misao Yoshida

Hirotaaka Nakashima, Ryuji Nagahama, Michiyo Owari, Nobuhiro Sakaki, Misao Yoshida, Foundation for Detection of Early Gastric Carcinoma, 2-6-12, Kayaba-cho, Nihonbashi, Chuo-ku, Tokyo, 103-8790, Japan

Yasuo Ohkura, Department of Pathology, Kyorin University School of Medicine, Tokyo, Japan

Correspondence to: Hirotaaka Nakashima, Foundation for Detection of Early Gastric Carcinoma, 2-6-12, Kayaba-cho, Nihonbashi, Chuo-ku, Tokyo, 103-8790, Japan. [nakasima@soiken.or.jp](mailto:nakasima@soiken.or.jp)

Telephone: +81-3-3668-7564 Fax: +81-3-3668-7594

Received: March 12, 2012 Revised: May 12, 2012

Accepted: May 18, 2012

Published online: July 21, 2012

### ABSTRACT

**AIM:** Therapeutic endoscopy has been widely adopted, and most of intramucosal gastric carcinomas are commonly treated by endoscopic submucosal dissection (ESD). In order to achieve an appropriate endoscopic treatment, this study is designed to reveal multiple and minute gastric carcinomas, which may be overlooked at preoperative endoscopy.

**METHODS:** We retrospectively examined clinicopathological findings and endoscopic images of 80 carcinoma lesions from 28 multiple gastric carcinoma patients. The entire region of resected stomachs were pathologically examined, after that carcinomas were evaluated clinicopathological findings, i.e., size, histological type, depth of invasion, background mucosa, distribution of the carcinomas, and preoperative diagnosis by endoscopy.

**Results:** The patients with multiple gastric carcinomas were accounted for 26.9% of all surgically treated cases. There were 17 double and 5 triple carcinomas, and 6 quadruple quintuple or sextuple carcinomas. In cases in which the second carcinoma was detected, the probability of a third carcinoma was 39.2%. Lesions after the third carcinoma were likely to be minute gastric carcinoma (less than 5 mm in size) in which preoperative endoscopic detection rate was 25%.

**CONCLUSIONS:** During endoscopic treatment for gastric carcinoma, it needs to pay attention to the residual multiple or minute gastric carcinoma in the stomach, which may lead to a predisposi-

tion for metachronous multiple gastric carcinoma. Careful pretherapeutic examination and follow-up by endoscopy should be performed to achieve an appropriate endoscopic treatment in cases of multiple gastric carcinomas.

© 2012 Thomson research. All rights reserved.

**Key words:** Gastric carcinoma; Multiple carcinoma; Minute carcinoma; Endoscopic diagnosis

Nakashima H, Nagahama R, Ohkura Y, Owari M, Sakaki N, Yoshida M. Clinicopathological Study of Minute Gastric Carcinoma in Surgically Resected Multiple Gastric Carcinoma Cases. *Journal of Gastroenterology and Hepatology Research* 2012; 1(6): 92-96 Available from: URL: <http://www.ghrnet.org/index./joghr/>

### INTRODUCTION

There has been continuing efforts to improve cure rate in the endoscopic resection of early gastric carcinomas. One of the efforts is to raise diagnostic precision of multiple gastric carcinomas. The preoperative endoscopy can be used in search for multiple gastric carcinomas as well as for determination of the range of carcinoma and clinical imaging diagnosis on the depth of invasion. However, it is often difficult to detect a minute carcinoma less than 5 mm in diameter as sub-lesions, before treatment of main carcinoma. Accurate data regarding the incidence and features of multiple carcinoma in surgical cases of gastric carcinoma, are required to determine how best to deal with multiple gastric carcinomas clinically. In the present study, we focused on minute gastric carcinomas less than 5 mm in diameter, which are difficult to diagnose clinically, especially in multiple gastric carcinoma cases, and investigated their clinicopathological and endoscopic findings in detail.

### MATERIALS AND METHODS

#### Subjects

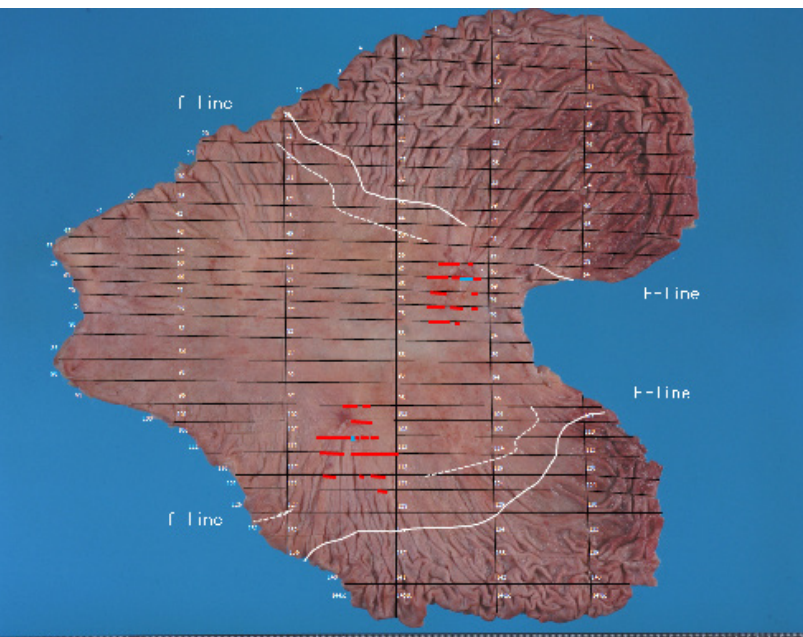
We retrospectively examined clinicopathological findings and endoscopic images of multiple gastric carcinomas. Between 2002 and 2010, we diagnosed 80 carcinoma lesions from 28 multiple gastric carcinoma patients. The patients consisted of 22 men and 6 women, with a mean age of 65.7±8.9 (mean±SD). Fourteen patients underwent total gastrectomy and other 14 patients had subtotal

gastrectomy. During the same period, other 76 solitary gastric carcinoma cases underwent radical gastrectomy. Pathological studies on resected specimens had been carried out at pathology department of Foundation for Detection of Early Gastric Carcinoma. The diagnosis of multiple gastric carcinomas were made in accordance with the criteria of Moertel *et al*<sup>[1]</sup>.

**Method of clinicopathological examination**

All 104 operated stomachs were opened along the greater curvature, stretched symmetrically using forceps and thin pins, and attached to corkboards. The specimens were immersed in 15% formalin solution for 48 h. All of 104 operated stomachs, whole step sections were made at intervals of about 5 mm to obtain pathological specimens as shown in Figure 1. We photographed the specimens both before and after slicing. The sliced specimens were embedded in paraffin, cut into sections 4 μm thick, and then subjected to hematoxylin–eosin staining. The clinicopathological findings of gastric carcinoma were recorded following Japanese classification of gastric carcinoma 3<sup>rd</sup> English edition<sup>[2]</sup>. Furthermore, histological types were classified into two categories: differentiated type, i.e., papillary adenocarcinoma (pap) and tubular adenocarcinoma (tub1, tub2); and undifferentiated type, i.e., signet-ring cell carcinoma (sig), mucinous adenocarcinoma (muc) and adenocarcinoma poorly differentiated type (por1, por2)<sup>[3]</sup>.

In this study, endoscopic examinations were carried out by experienced endoscopist using endoscopes of GIF-Q240, GIF-Q260 and GIF-H260 (Olympus co. Tokyo). All cases of the gastric carcinomas were examined by non-magnifying white light image and chromoendoscopy with indigocarmine.



**Figure 1** A case of multiple gastric carcinoma undergoing pathological examination of the entire gastric region. The red line indicates carcinoma expansion at the mucosal layer. The blue line indicates infiltration of the carcinoma into the submucosal layer; the background mucosa of gastric carcinoma classified into three regions by histological finding. The oral-side region of the F-line (white line) was the gastric fundic gland region without histological intestinal metaplasia (F-area). The f-area was fundic gland with a nest-like appearance. The borderline between f- and IM-area was defined as the histological f-line (white dotted line). The (IM-area) was external to F and F-area.

**Size of the carcinoma lesions**

Multiple gastric carcinoma lesions were numbered in order of the

depth of invasion. When the lesions diagnosed same invasion depth, they were numbered in order of the size. The first carcinoma which meant the deepest and largest cancer was classified as the main lesion. The carcinoma lesions were divided into three categories according to the size of a longer axis: (1) minute carcinoma, equal to or less than 5 mm, (2) the lesions longer than 6 mm and less than 20 mm and (3) group longer than 21 mm.

**Background mucosa and distribution of carcinoma**

The locations of the multiple carcinoma lesions were assessed in relation of the background gastric mucosa which was divided into 3 areas based on histological findings. The fundic gland area without intestinal metaplasia was designated as (F-area). The area where showed a nest-like appearance of fundic gland mucosa was called as (f-area), and areas external to F- and f-areas are named as (IM-area). The (IM-area) is indicated an area with intestinal metaplasia mucosa. When those background mucosa categories are assessed by intestinal metaplasia grade of The Updated Sydney System, (F-area) represents “grade normal or mild”, (f-area) represents “grade moderate”, (IM-area) represents “grade marked”<sup>[4]</sup>. The borderline between F- and f-areas was defined as the histological F-line. And the borderline between f- and IM-areas was defined as the histological f-line<sup>[5]</sup>.

The distance from main carcinoma lesion to other multiple carcinoma lesions were measured by straight line of each carcinoma's central point. The point of inter section with a longer axis and a minor axis was defined as carcinoma's central point.

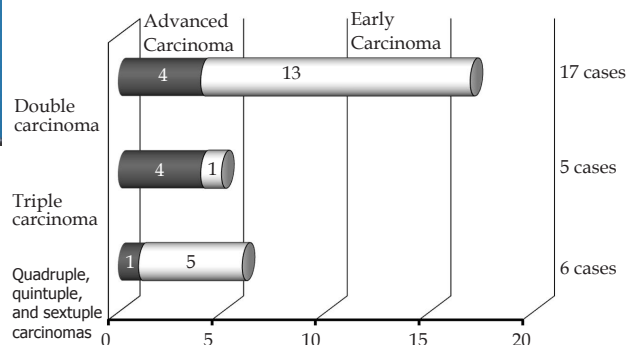
**Statistical analysis**

Statistical analyses were conducted using the Two group t-test (unpaired) and the  $\chi^2$  test.  $p < 0.05$  was considered statistically significant.

**RESULTS**

**Number of multiple gastric carcinoma**

The 28 patients with multiple gastric carcinomas were accounted for 26.9% of all surgically treated 104 cases during the same period. There were 17 double and 5 triple carcinomas, and 6 quadruple, quintuple, or sextuple carcinomas. Figure 2 shows the number of carcinomas in each of 28 cases. The study population included 17 cases of double carcinoma, of which the main lesion was advanced carcinoma in 4 cases. Among the 5 cases of triple carcinoma, the main carcinoma was at an advanced stage in 4 cases. There were 6 cases that had four or more carcinoma lesions, including 1 case in which the main carcinoma was at an advanced stage.



**Figure 2** The number of carcinoma lesions in each case (n=28).

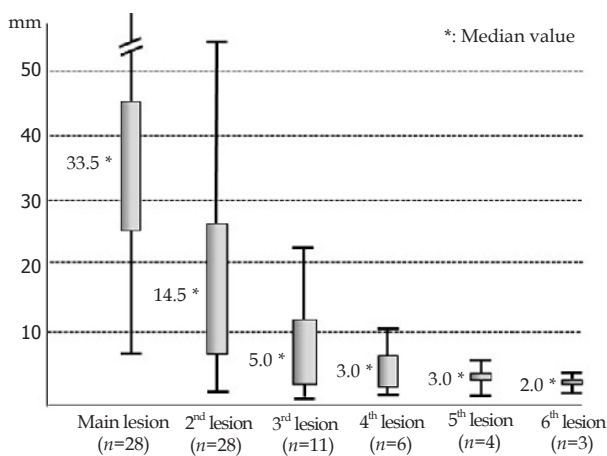
**Size of carcinoma lesions**

Concerning the size of each lesions classified by their depth of invasion, the median value of lesion size was 33.5 mm in 28 main

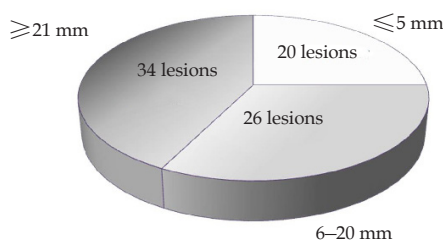
carcinoma lesions, 14.5 mm in 28 second lesions, 5.0 mm in 11 third lesions, 3.0 mm in 6 fourth lesions, 3.0 mm in 4 fifth lesions, and 2.0 mm in 3 sixth lesions, as shown in Figure 3.

The 80 carcinoma lesions classified into three groups according to size; 34 lesions more than 21 mm in diameter, 26 lesions measuring 6–20 mm, and 20 lesions less than 5 mm (Figure 4). The clinicopathological findings, background mucosa determined by histology and preoperative diagnoses of the endoscopy were analyzed in the 80 carcinoma lesions (Table 1). Early carcinoma occupied 100% in the group with lesions less than 20 mm. On the other hand, the early carcinoma occupied 73.5 % of the group with lesions more than 21 mm in diameter. The rate of differentiated carcinoma was 90% in the lesions less than 5 mm in diameter, 73% in those measuring 6–20 mm, and 62% in those more than 21 mm.

The preoperative detection rate by endoscopy was 25% in the group with the lesions  $\leq 5$  mm, 61.5% in those measuring 6–20 mm, and 94.1% in those  $\geq 21$  mm. (\*:  $p < 0.05$ ,  $\chi^2$  test).



**Figure 3** The sizes of multiple gastric carcinomas are shown in cases with each number of lesions ( $n=80$ ). Multiple gastric carcinoma lesions were numbered in order of the depth of invasion, and the first lesion was defined as the main carcinoma.



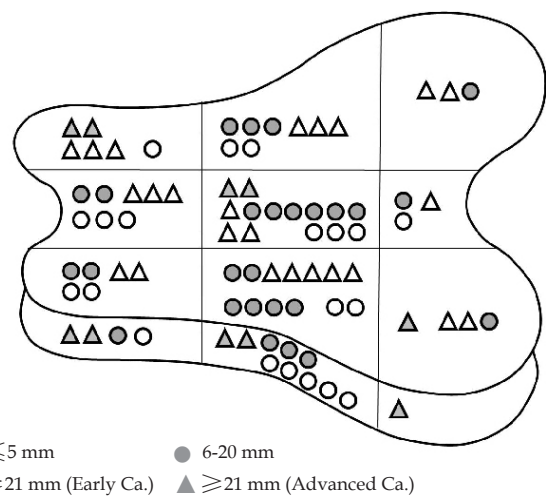
**Figure 4** Based on the size of carcinoma lesions, multiple gastric carcinomas were classified into three groups ( $n=80$ ).

**Distribution of carcinoma**

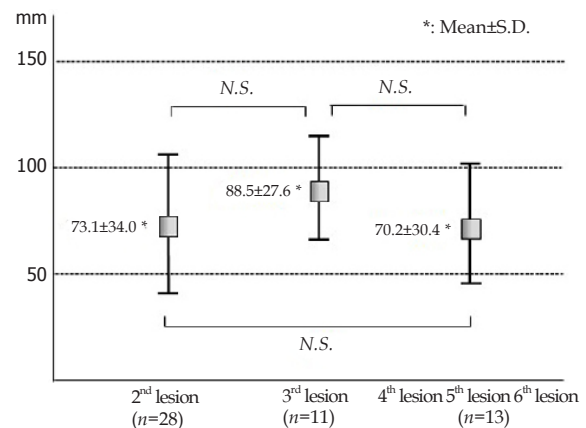
The 80 carcinoma lesions were scattered in all areas of resected stomach (Figure 5). Figure 6 indicated the distance from the main lesion to multiple carcinoma lesions. The mean distance from main lesion to the second lesion was 73.1 mm  $\pm$  34.0 (mean  $\pm$  SD), to the third lesion was 88.5 mm  $\pm$  27.6 (mean  $\pm$  SD), and to the fourth or the fifth or the sixth lesions was 70.2 mm  $\pm$  30.4 (mean  $\pm$  SD). About each distance, the significant differences were not recognized in *t*-test. Figure 7 shows a case of sextuple carcinoma.

**Table 1** Clinicopathological findings and endoscopic diagnostic ability in multiple gastric carcinomas ( $n=80$ ). (\*:  $p < 0.05$ ,  $\chi^2$  test).

	$\leq 5$ mm	6–20 mm	$\geq 21$ mm
<b>The number of lesions</b>	$n=20$	$n=26$	$n=34$
<b>Rate of early carcinoma</b>	100%	100%	73.5%
(invasion depth, number)	(M 20)	(M 20, SM 6)	(M 8, SM 16, MP/SS 10)
<b>Macroscopic type</b>			
Superficial type (0-IIc, 0-IIb)	20	22	16
Superficial type (0-I, 0-IIa)		4	8
Type 2 or 3			7
Type 1			2
Type 5			1
<b>Histology</b>			
Rate of differentiated type	90%	73%	62%
Background mucosa (F, 1; f, 2; IM, 17)	(F, 4; f, 4; IM, 18)	(F, 5; f, 8; IM, 21)	
<b>Preoperative detection rate by endoscopy</b>			
	25%	61.5%	94.1%
	$p < 0.05$		$p < 0.05$



**Figure 5** Distribution of multiple gastric carcinomas ( $n=80$ ).




**Figure 6** The distance from main carcinoma lesion to multiple carcinoma lesions.

**Clinicopathological findings and background mucosa of minute carcinomas**

All of the minute gastric carcinomas investigated in the present study were intramucosal carcinomas, all of which were macroscopically classified as Type 0-IIc or Type 0-IIb. With regard to histological type and background mucosa of the minute gastric carcinomas, 90% of

cases showed differentiated type lesions arising from (IM-area). In this study, only 25% of minute carcinomas in multiple gastric carcinomas were detected by preoperative endoscopy (Table 1).



**Figure 7** Sextuple carcinoma cases in which the whole gastric region was investigated. The red line indicates carcinoma expansion at the mucosal layer. The blue line indicates invasion of the carcinoma into the submucosal layer. Marked intestinal metaplasia was seen, and the F-line could not be defined. Main carcinoma: 0-I type, 18 mm; second carcinoma: 0-IIc type, 12 mm; third carcinoma: 0-IIc type, 10 mm; fourth carcinoma: 0-IIc type, 8 mm; fifth carcinoma: 0-IIb type, 3 mm; sixth carcinoma: 0-IIc type, 2 mm. All lesions were differentiated types.

## DISCUSSION

Advanced endoscopic treatment has enabled us to resect many intramucosal gastric carcinomas by endoscopic submucosal dissection (ESD)<sup>[6-8]</sup>. As the endoscopic treatment resects only gastric carcinoma lesions detected by preoperative endoscopy, it is necessary to conduct accurate diagnosis of multiple gastric carcinomas as well as the main carcinoma to achieve cure. Thus, it is essential to treat multiple gastric carcinomas more carefully with the widespread adoption of endoscopic treatment<sup>[9]</sup>.

On the other hand, new gastric carcinoma lesions were detected in long-term follow-up of the stomach after endoscopic treatment<sup>[10-12]</sup>. Two types of gastric carcinoma are probably detected after endoscopic treatment: i.e., carcinomas that are missed at the first endoscopic treatment and grow after treatment, and the others were new lesions that occur after the first treatment in the residual stomach. Considering metachronous multiple gastric carcinomas after endoscopic treatment, it is very important to determine the incidence of multiple gastric carcinoma lesions that are not detected clinically during treatment of the main carcinoma. Because minute gastric carcinoma is difficult to detect by endoscopy, and may be overlooked. There have been some reports regarding the incidence and diagnostic accuracy of multiple gastric carcinoma<sup>[13-15]</sup>, however minute gastric carcinoma in multiple gastric carcinoma has not been investigated in detail yet. In the present study of multiple gastric carcinomas diagnosed by pathological examination on whole step sections of operated specimens, minute gastric carcinoma was defined as lesions less than 5 mm in diameter<sup>[16-17]</sup>. Clinical diagnosis of such small carcinoma is difficult, therefore the clinicopathological findings and endoscopic diagnostic ability were investigated in this study.

Multiple gastric carcinomas accounted for 26.9% of all resected

gastric carcinomas in the present study. This was the highest group reported to date<sup>[18-21]</sup>, likely because we pathologically examined the entire region of the gastric specimens after surgery. However, it was expected that true incidence of multiple carcinomas was a little higher than our result 26.9%, because half cases of this study were performed subtotal gastrectomy.

As shown in Figure 2, the studied gastric specimens included 11 cases of triple or more carcinoma lesions, corresponding to 39.2% of 28 cases of multiple gastric carcinoma. Besides, multiple carcinoma lesions were numbered in order of their depth of invasion or lesion size, the median value of the size of third carcinomas was 5.0 mm (Figure 3).

Our results suggested the important matters about multiple and minute gastric carcinoma. The first, when a diagnosis of multiple gastric carcinomas was made due to detection of the second carcinoma, it could be predicted that the probability of the presence of the third carcinoma was 39.2%, i.e., (number of cases more than triple carcinoma; 11/all multiple cancer cases: 28×100). Next, the third or subsequent carcinomas were likely to be minute gastric carcinomas less than 5 mm in diameter. Furthermore, Figure 5, 6 and 7 indicated multiple gastric carcinomas, including minute carcinomas, were not distributed in specific gastric site, and that the multiple carcinomas were not next to the main lesion. Taking the diagnostic course by endoscopy into consideration, the results of this study are important to determine efficient diagnostic clues to avoid overlooking multiple gastric carcinomas.

In this study, only 25% of minute carcinomas in multiple gastric carcinomas were detected by preoperative endoscopy. We discuss about this reason from the result of Table 1. The minute gastric carcinomas investigated in the present study were intramucosal carcinomas, all of which were macroscopically classified as Type 0-IIc or Type 0-IIb. In addition, histological type and background mucosa of the minute gastric carcinomas, 90% of cases showed differentiated type arising from (IM-area). With regard to those results suggests that most of the minute and multiple carcinomas are differentiated type adenocarcinoma presenting poor in morphological change and scattered apart against intestinal metaplasia associated by distinct atrophic and granular mucosal surface. It was supposed that such clinicopathological and macroscopically findings of minute carcinoma made preoperative endoscopic diagnosis difficult.

We have to remind difficulties in endoscopic detection of multiple and minute gastric carcinomas before endoscopic treatment of gastric carcinoma. It is necessary to carefully search for the presence of multiple gastric carcinoma lesions, especially minute gastric carcinomas less than 5 mm in diameter, by preoperative endoscopy. However, it is difficult to detect all minute gastric carcinoma lesions before treatment by current endoscopic technology yet. Thus, there is a risk that minute gastric carcinoma lesions may remain after endoscopic treatment. As the stomach after endoscopic treatment may be predisposed to develop metachronous minute gastric carcinomas, long-term endoscopic follow-up is required.

## REFERENCES

- 1 Moertel CG, Barga JA, Soule EH. Multiple gastric cancers; review of the literature and study of 42 cases. *Gastroenterology* 1957; **32**: 1095-1103
- 2 Japanese classification of gastric carcinoma: 3rd English edition. *Gastric Cancer* 2011; **14**: 101-112
- 3 Nakamura K, Sugano H, Takagi K. Carcinoma of the stomach in incipient phase: its histogenesis and histological appearances. *Gann* 1968; **59**: 251-258
- 4 Nakamura K, Sugano H, Kato Y. A boundary line limited to

- the fundic gland mucosa with intestinal metaplasia (in Japanese with English abstract). *Stomach and Intestine* 1980; **15**: 125-136
- 5 Dixon MF, Genta RM, Yardley JH, Correa P. Classification and grading of gastritis. The updated Sydney System. International Workshop on the Histopathology of Gastritis, Houston 1994. *Am J Surg Pathol* 1996; **20**: 1161-1181
  - 6 Ono H, Kondo H, Gotoda T, Shirao K, Yamaguchi H, Saito D, Hosokawa K, Shimoda T, Yoshida S. Endoscopic mucosal resection for treatment of early gastric cancer. *Gut* 2001; **48**: 225-229
  - 7 Oyama T, Kikuchi Y. Aggressive endoscopic mucosal resection in the upper GI tract Hook knife EMR method. *Min Invas Ther Allied Technol* 2002; **11** : 291-295
  - 8 Gotoda T, Yamamoto H, Soetikno RM. Endoscopic submucosal dissection of early gastric cancer. *J Gastroenterol* 2006; **41**: 929-942
  - 9 Lee HL, Eun CS, Lee OY, Han DS, Yoon BC, Choi HS, Hahm JS, Koh DH. When do we miss synchronous gastric neoplasms with endoscopy? *Gastrointest Endosc* 2010; **71**: 1159-1165
  - 10 Nakajima T, Oda I, Gotoda T, Hamanaka H, Eguchi T, Yokoi C, Saito D. Metachronous gastric cancers after endoscopic resection: how effective is annual endoscopic surveillance? *Gastric Cancer* 2006; **9**: 93-98
  - 11 Fukase K, Kato M, Kikuchi S, Inoue K, Uemura N, Okamoto S, Terao S, Amagai K, Hayashi S, Asaka M; Japan Gast Study Group. Effect of eradication of *Helicobacter pylori* on incidence of metachronous gastric carcinoma after endoscopic resection of early gastric cancer: an open-label, randomized controlled trial. *Lancet* 2008; **372**: 392-397
  - 12 Arima N, Adachi K, Katsube T, Amano K, Ishihara S, Watanabe M, Kinoshita Y. Predictive factors for metachronous recurrence of early gastric cancer after endoscopic treatment. *J Clin Gastroenterol* 1999; **29**: 44-47
  - 13 Kosaka T, Miwa K, Yonemura Y, Urade M, Ishida T, Takegawa S, Kamata T, Ooyama S, Maeda K, Sugiyama K, Fujimura T, Hasegawa H, Yamaguchi A, Miyazaki I. A clinicopathologic study on multiple gastric cancers with special reference to distal gastrectomy. *Cancer* 1990; **65**: 2602-2605
  - 14 Kodera Y, Yamamura Y, Torii A, Uesaka K, Hirai T, Yasui K, Morimoto T, Kato T, Kito T. Incidence, diagnosis and significance of multiple gastric cancer. *Br J Surg* 1995; **82**: 1540-1543
  - 15 Brandt D, Muramatsu Y, Ushio K, Mizuguchi Y, Itabashi M, Yoshida S, Moriyama N, Nawano S, Ishikawa T, Yamada T. Synchronous early gastric cancer. *Radiology* 1989; **173**: 649-652
  - 16 Iishi H, Tatsuta M, Okuda S. Endoscopic diagnosis of minute gastric cancer of less than 5 mm in diameter. *Cancer* 1985; **56**: 655-659
  - 17 Arai T, Esaki Y, Inoshita N, Sawabe M, Kasahara I, Kuroiwa K, Honma N, Takubo K. Pathologic characteristics of gastric cancer in the elderly: a retrospective study of 994 surgical patients. *Gastric Cancer* 2004; **7**: 154-159
  - 18 Lee HL, Eun CS, Lee OY, Han DS, Yoon BC, Choi HS, Hahm JS, Koh DH. When do we miss synchronous gastric neoplasms with endoscopy? *Gastrointest Endosc*. 2010; **71**: 1159-65.
  - 19 Otsuji E, Kuriu Y, Ichikawa D, Okamoto K, Hagiwara A, Yamagishi H. Clinicopathologic characteristics and prognosis of synchronous multifocal gastric carcinomas. *Am J Surg* 2005; **189**: 116-119
  - 20 Honmyo U, Misumi A, Murakami A, Haga Y, Akagi M. Clinicopathological analysis of synchronous multiple gastric carcinoma. *Eur J Surg Oncol* 1989; **15**: 316-321
  - 21 Isozaki H, Okajima K, Hu X, Fujii K, Sako S. Multiple early gastric carcinomas. Clinicopathologic features and histogenesis. *Cancer* 1996; **78**: 2078-2086
- Peer reviewer:** Zhan-Ju Liu, MD, PhD, Department of Gastroenterology, Shanghai Tenth People's Hospital, Tongji University, No. 301 Yanchang Road, Shanghai 200072, China.