

Correlation of Epithelial-Mesenchymal Transition and CK19 Expression in Hepatocellular Carcinoma

Onder Peker, Hale Kirimlioglu, Yesim Saglican

Onder Peker, MD, Professor, Aydin University, School of Medicine, Department of Pathology, Istanbul, Turkey

Hale Kirimlioglu, MD, Associate Professor, Acibadem University, School of Medicine, Department of Pathology, Istanbul, Turkey

Yesim Saglican, MD, Assistant Professor, Acibadem University, School of Medicine, Department of Pathology, Istanbul, Turkey.

Correspondence to: Hale Kirimlioglu, Acibadem University, Kerem Aydinlar Campus, Atasehir, Istanbul, Turkey

Email: hkirimlioglu@yahoo.com

Telephone: +5424129232

Received: September 30, 2015 Revised: December 10, 2015

Accepted: December 15, 2015

Published online: March 22, 2016

© 2016 The Authors. Published by ACT Publishing Group Ltd.

Key Words: Hepatocellular carcinoma; Cytokeratin -19; Epithelial; Mesenchymal transition

Peker O, Kirimlioglu H, Saglican Y. Correlation of Epithelial-Mesenchymal Transition and CK19 Expression in Hepatocellular Carcinoma. *Journal of Gastroenterology and Hepatology Research* 2016; 5(2): 1997-2000 Available from: URL: <http://www.ghrnet.org/index.php/joghr/article/view/1390>

ABSTRACT

AIM: Hepatocellular carcinomas are one of the leading cause of death throughout the world with a high recurrence rate and metastatic potential. The relationship between the prognosis and immunoexpression of cytokeratin 19 has been shown in hepatocellular carcinomas. Recently, EMT has been shown to be an important mechanism contributing to cancer invasion and metastasis in epithelial-derived cancers, including Hepatocellular carcinoma. We aimed to investigate the relationship between the CK19 positivity with a poor prognosis in HCC and E-cadherin and vimentin as the EMT indicator proteins.

MATERIALS AND METHODS: The cytokeratin-19, vimentin and E-cadherin expression of 41 HCC tissue samples was examined by immunohistochemical staining.

RESULTS: The E-cadherin expression was negatively and vimentin expression positively correlated with CK19 positivity ($p < 0.05$).

CONCLUSION: Previous studies implicated that both the CK19 positive HCCs and the HCCs having reduced expression of E-cad and gain vimentin expression have poor prognosis with increased risk of recurrence and metastasis. In our study the correlation between the CK19 positivity and EMT may suggest that those tumors are originated from progenitor cells. The tumors originated from progenitor cells may have higher EMT, this may be related with the carcinogenesis of this HCC subtype.

INTRODUCTION

E-cadherin is a calcium-dependent cell adhesion molecule that belongs to a family of transmembrane glycoproteins, is normally expressed at adherent junctions between epithelial cells^[1]. Recently, altered expression and down-regulation of E-cadherin was reported to correlate with occurrence, development, and prognosis of various cancers^[2,3].

A hallmark of epithelial-mesenchymal transition (EMT) is loss of E-cad, which is considered an epithelial differentiation marker in EMT studies^[4]. The characteristic changes that occur during EMT include the downregulation of epithelial differentiation markers E-cadherin (E-cad)^[5,6] and the upregulation of mesenchymal markers such as vimentin (VIM)^[7,8]. Recently, EMT has been shown to be an important mechanism contributing to cancer invasion and metastasis in epithelial-derived cancers^[5,9-11], including Hepatocellular carcinoma (HCC)^[12-15].

HCC is a poor prognostical tumor. Though it is a leading cause of death, the conventional systemic therapy strategies are ineffective and following surgical resection highly recur. One of the key molecular pathways is epidermal growth factor receptor (EGFR) in HCC development. The activation of the EGF-EGFR signaling pathway via phosphorylation of JNK/SAPK may be closely associated with the histogenesis of CK19-positive HCC. EGF increased the abilities of cell growth and invasive properties of HCC cell lines, showing an acquisition of more malignant potential and accounting for the poor prognosis of the patients^[16,17].

In the present study we aimed to investigate the relationship

between the CK19 positivity with a poor prognosis in HCC and these EMT indicator proteins.

METHODS

Patients and Tissue Specimens

The specimens were obtained from forty-one patients who had undergone liver resection for hepatocellular carcinoma and liver transplantation for hepatocellular carcinoma between January 2012 and October 2014 at Acibadem University, Istanbul, Turkey. All patients provided written informed consent to participate in the study. Normal tissue specimens were taken more than 20 mm away from the hepatocellular carcinoma and confirmed as “normal” by subsequent histopathologic analysis. Each tissue sample was immediately fixed in 10% buffered formalin and embedded in paraffin. Sections (4 µm thick) were prepared for hematoxylin and eosin (HE) staining for histological diagnosis and for immunohistochemistry.

Immunohistochemistry

Streptoavidin-biotin method was made for immunohistochemistry in full automatic system Ventana Benchmark XT (Arizona, USA).

Sections were incubated with primary antibody E-cadherin (clone: SPM471, Ready to use, Neomarkers), vimentin (clone: CK19 (clone: A53-B/A2.26, Ready to use, Neomarkers) for 40 minutes at 24°C. Then sections incubated biotinylated secondary antibody (iView DAB Delection Kit, Ventana, USA) for 4 minutes and streptoavidin conjugated to Horseradishperoxidase (iView DAB Delection Kit, Ventana, USA) for 8 minutes. After incubating Diaminobenzidine (DAB, iView DAB Delection Kit, Ventana, USA) for 8 minutes applying Copper (iView DAB Delection Kit, Ventana, USA) for mordanting. All sections were stained hematoxylin II (Ventana, USA) for 12 minutes. After washing with tap water, sections were dehydrated through a graded ethanol series, cleared in xylene, and mounted with embedding agent Consul-Mount (Thermo Scientific, UK). All slides were evaluated by conventional light microscopy (Olympus BX51, Olympus America Inc., USA).

Statistical Analysis

All statistical analyses were performed using SPSS15.0 software (SPSS, Chicago, IL). Continuous data were expressed as the mean±SD. All tests were two sided *P*-values <0.05 were considered statistically significant.

RESULTS

E-cadherin was found in strong pattern in 8 /41 (20%) HCCs, weak and homogenous pattern in 10/41 (24%) tumors, in 17/41 (41%) cases heterogenous pattern was detected, and 6/41 (15%) HCCs were not stained with E-cadherin.

In 14/41 (34%) hepatocellular carcinomas exhibited vimentin expression, in 27/41 (66%) tumors didnot. When hepatocellular carcinomas were grouped according to CK19 expression; 20 (49%) of them were CK19 positive and 21 (51%) were CK19 negative.

None of the HCCs that demonstrated strong staining pattern of E-cadherin were CK19 positive. All E-cadherin negative cases had CK19 expression, the remaining CK19 positive HCCs were either had heterogenous pattern or weak and homogenous pattern of E-cadherin staining, 13 and 1 cases respectively (Table 1) (Figure 1). Twelve of the 14 vimentin exhibiting HCCs were CK19 positive, 7 of the CK19 tumors were vimentin negative (Table 2) (Figure 1). The E-cadherin expression was negatively and vimentin expression positively correlated with CK19 positivity (*p* < 0.05).

Table 1 e-cadherin expression in CK19 positive HCCs.

e-cadherin	CK19 positive HCC
Strong	0/8 (0%)
homogeous	1/10 (10%)
Heterogeous	13/17 (76.5%)
Negative	6/6 (100%)

Table 2 Vimentin expression in CK19 positive HCCs.

Vimetin	CK19 positive HCC
Positive	12/14 (88.7%)
Negative	7/27 (25.9%)

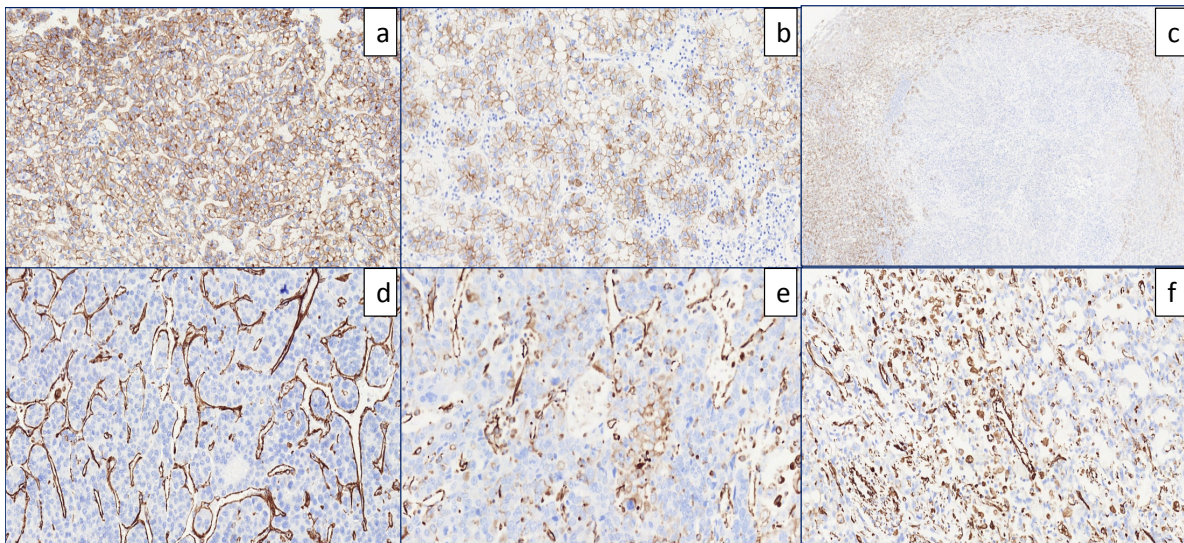


Figure 1 Ecadherin (a,b,c) and vimentin (d,e,f) expressions in HCCs were demonstrated as follows: (a): strong pattern: E-cadherin staining pattern is almost all tumor cells (>95 %); (b): weak and homogenous pattern: all tumor cells are uniformly stained but more weakly expressed than in normal hepatocytes; (c): heterogenous pattern: there is complete loss of Ecadherin in tumor, other tumoral areas where weakly stained; (d): vimentin is negative in tumor cells; (e): vimetin is positive in only few tumor cells; (f): prominent vimentin expression in tumor cells.

DISCUSSION

Hepatocellular carcinoma (HCC) is the third leading cause of cancer mortality worldwide, it is a poor prognostical tumor and the conventional systemic therapy strategies are ineffective and following surgical resection highly recur.

Several studies have demonstrated positive immunoeexpression of cytokeratin (CK) 19 in HCC, and CK19-positive HCC has a high metastatic potential, which is also associated with a poor prognosis^[18,19,20].

Recent studies indicate that, the activation of the EGF-EGFR signaling pathway by inducing CK19 expression, is associated with the development of CK19-positive HCC and the EGF-induced increase in proliferative abilities and invasive properties of HCC, may account for the poor prognosis of the patients^[16,17,21].

The epithelial-derived tumor cells switch their phenotype to a more primitive mesenchymal phenotype and implicated EMT in cancer progression and the loss of E-cad expression and the presence of vimentin are important factors in EMT^[5,9-14]. Recent reports were suggested EMT, the loss expression of E-cad and gain of vimentin, is a critical factor, by playing a key role in the progression of tumor invasion and metastasis, occurrence in early recurrence after surgery in several malignant carcinomas, including HCC^[11,15,22,23,24].

In normal human liver, hepatocytes express CK8 and CK18, while biliary epithelial cells express CK7 and CK19(25). Hepatic progenitor cells, on the other hand, express markers specific for both hepatocytes and biliary epithelial cells. some HCC can express CK19, the marker specific for biliary epithelial cells^[18,19,26,27]. These consistent findings suggested that some HCC may originate from hepatic progenitor cells, instead of hepatocytes directly, but hepatic progenitor cells which express CK19^[14,25,27].

In our study the correlation between the CK19 positivity and EMT may suggest that those tumors are originated from progenitor cells. Previous studies implicated that both the CK19 positive HCCs and the HCCs having reduced expression of E-cad and gain vimentin expression have poor prognosis with increased risk of recurrence and metastasis. Our study suggested that EMT may be related with the origin of the HCCs. The tumors originated from progenitor cells may have higher EMT, this may be related with the carcinogenesis of this HCC subtype.

Although HCC remains a promising target for anti-EGFR therapies, selection criterias are unclear. As the conventional systemic therapy strategies are ineffective in HCC, recent studies are trying to find new medications. Recent studies indicate that the activation of the EGF-EGFR signaling pathway is associated with the development of CK19-positive HCC, and the EGF-induced increase in growth abilities of HCC may account for the poor prognosis of the patients^[28]. E-cadherin is found to be both prognostic and predictive of erlotinib treatment outcomes and a marker that identified a subset of patients different from those who have increased EGFR protein expression and EGFR copy number.

Further studies about the carcinogenesis, in selected group of HCCs probably originated from progenitor cells, EGFR antagonists in therapy may be a promising choice.

CONFLICT OF INTERESTS

The authors declare that they do not have conflict of interests.

REFERENCES

- 1 Wang G, et al. A comparison of Twist and E-cadherin protein ex-

- pression in primary non-small-cell lung carcinoma and corresponding metastases. *Eur J Cardiothorac Surg.* 2011; **39(6)**: 1028-32.
- 2 Kim DY, Joo JK, Park YK, et al. E-cadherin Expression in early gastric carcinoma and correlation with lymph node metastasis. *J Surg Oncol.* 2007; **96**: 429-435.
- 3 van Oort IM, Tomita K, van Bokhoven A, et al. The prognostic value of E-cadherin and the cadherin-associated molecules alpha-, beta-, gamma-catenin and P120ctn in prostate cancer specific survival: A long-term follow-up study. *Prostate.* 2007; **67**: 1432-1438.
- 4 Zheng G, et al. Disruption of E-cadherin by matrix metalloproteinase directly mediates epithelial-mesenchymal transition downstream of transforming growth factor-beta1 in renal tubular epithelial cells. *Am J Pathol.* 2009; **175(2)**: 580-91.
- 5 Soini Y, et al. Transcription factors zeb1, twist and snai1 in breast carcinoma. *BMC Cancer.* 2011; **11**: 73.
- 6 Behrens J, et al. Dissecting tumor cell invasion: epithelial cells acquire invasive properties after the loss of uvomorulin-mediated cell-cell adhesion. *J Cell Biol.* 1989; **108(6)**: 2435-47.
- 7 Thiery JP, et al. Epithelial-mesenchymal transitions in development and disease. *Cell.* 2009; **139(5)**: 871-90.
- 8 Myong NH. Loss of E-cadherin and acquisition of vimentin in epithelial-mesenchymal transition are noble indicators of uterine cervix cancer progression. *Korean J Pathol.* 2012; **46(4)**: 341-8.
- 9 Li LP, et al. Subcellular proteomics revealed the epithelial-mesenchymal transition phenotype in lung cancer. *Proteomics.* 2011; **11(3)**: 429-39.
- 10 Soltermann A, et al. Prognostic significance of epithelial-mesenchymal and mesenchymal-epithelial transition protein expression in non-small cell lung cancer. *Clin Cancer Res.* 2008; **14(22)**: 7430-7.
- 11 Yang Fei, MSc, Xu-Shun Liu, MSc, Feng Wang, MSc, Wei Wang, MSc, Sheng-Li Liu, MSc. E-cadherin Expression in Normal and Abnormal Tissue Specimens From Patients With Pancreatic Carcinoma. *Science.* 2010 August; **41(8)**: 473-77.
- 12 van Zijl F, et al. A human model of epithelial to mesenchymal transition to monitor drug efficacy in hepatocellular carcinoma progression. *Mol Cancer Ther.* 2011; **10(5)**: 850-60.
- 13 Yi ZY, et al. Vascular endothelial growth factor receptor-1 activation mediates epithelial to mesenchymal transition in hepatocellular carcinoma cells. *J Invest Surg.* 2011; **24(2)**: 67-76.
- 14 Kim J, et al. Epithelial-mesenchymal transition gene signature to predict clinical outcome of hepatocellular carcinoma. *Cancer Sci.* 2010; **101(6)**: 1521-8.
- 15 Xiaolu Z, Huijun Z, Wei W, Shu Z, Yixin Z, Guoxin M. Abnormal expression of EMT-related proteins, S100A4, vimentin and E-cadherin, is correlated with clinicopathological features and prognosis in HCC. *Med Oncol* 2014; **31**: 970.
- 16 Yoneda N, Sato Y, Kitao A, Ikeda H, Sawada-Kitamura S, Miyakoshi M, Harada K, Sasaki M, Matsui O, Nakanuma Y. 4,448.indd 2360 2014/8/20 20: 28: 46 Epidermal growth factor induces cytokeratin 19 expression accompanied by increased growth abilities in human hepatocellular carcinoma. *Laboratory Investigation* 2011; **91**: 262- 272.
- 17 Berasain C, Latasa MU, Urtasun R, Goñi S, Elizalde M, Garcia-Irigoyen O, Azcona M, Prieto J, Ávila MA. Epidermal growth factor receptor (EGFR) crosstalks in liver cancer. *Cancers* 2011; **3**: 2444-2461.
- 18 Uenishi T, Kubo S, Yamamoto T, Shuto T, Ogawa M, Tanaka H, Tanaka S, Kaneda K, Hirohashi K. Cytokeratin 19 expression in hepatocellular carcinoma predicts early postoperative recurrence. *Cancer Sci* 2003; **94**: 851-857.
- 19 Wu PC, Fang JW, Lau VK, Lai CL, Lo CK, Lau JY. Classification of hepatocellular carcinoma according to hepatocellular and biliary differentiation markers. *Clinical and biological implications Am J Pathol* 1996; **149**: 1167-1175.
- 20 Ding SJ, Li Y, Tan YX, Jiang MR, Tian B, Liu YK, Shao XX, Ye SL, Wu JR, Zeng R, Wang HY, Tang ZY, Xia QC. From proteomic analysis to clinical significance: overexpression of cytokeratin 19

- correlates with hepatocellular carcinoma metastasis. *Mol Cell Proteomics* 2004; **3**: 73-81.
- 21 Roayaie S, Minguez B, Sole M, Battiston C, van Laarhoven S, Fiel MI, Di Feo A, Hoshida Y, Yea Y, Toffanin S, Ramos A, Martignetti JA, Mazzaferro V, Bruix J, Waxman S, Schwartz M, Meyerson M, Friedman SL, Llovet JM. Pivotal role of mTOR signaling in hepatocellular carcinoma. *Gastroenterology* 2008; **135**: 1972-1983.
- 22 Onder TT, Gupta PB, Mani SA, Yang J, Lander ES, Weinberg RA. Loss of E-cadherin promotes metastasis via multiple downstream transcriptional pathways. *Cancer Res.* 2008; **68(10)**: 3645-54.
- 23 Nakagawaa H, Hikibac Y, Hirataa Y, Font-Burgadab J, Sakamoto K, Hayakawaa Y, Taniguchib K, Umemurab A, Kinoshitaa H, Saki-tania K, Nishikawad Y, Hiranoa K, Ikenouee T, Ijichia H, Dharb D, Shibataf W, Akanumac M, Koikea K, Karinb M, Maedaf S. Loss of liver E-cadherin induces sclerosing cholangitis and promotes carcinogenesis. *Proc Natl Acad Sci USA* 2014; **111(3)**: 1090–1095.
- 24 Yamada S, Okumura N, Wei L, Fuchs BC, Fujii T, Sugimoto H, Nomoto S, Takeda S, Tanabe KK, Kodera Y. *Ann Surg Oncol* 2014; **21**: 3882-3890.
- 25 Libbrecht L, Desmet V, Van Damme B, Roskams T. Epithelial to Mesenchymal Transition is Associated with Shorter Disease-Free Survival in Hepatocellular Carcinoma. The immunohistochemical phenotype of dysplastic foci in human liver: correlation with putative progenitor cells. *J Hepatol.* 2000; **11**: 76-84.
- 26 Yamamoto T, Uenishi T, Ogawa M, Ichikawa T, Hai S, Sakabe K, Tanaka S, Kato H, Mikami S, Ikebe T, Tanaka H, Ito S, Kaneda K, Hirohashi K, Kubo S. Immunohistologic attempt to find carcinogenesis from hepatic progenitor cell in hepatocellular carcinoma. *Dig Surg.* 2005; **11**: 364-370.
- 27 Lee CW, Kuo WL, Yu MC, Chen TC, Tsai CN, Lee WC, Chen MF. The expression of cytokeratin 19 in lymph nodes was a poor prognostic factor for hepatocellular carcinoma after hepatic resection. *World J Surg Oncol.* 2013; **11**: 136.
- 28 Yoneda N, Sato K, Kitao A, Ikeda H, Sawada-Kitamura S, Miyakos M, Harada K, Sasaki M, Matsui O, Nakanuma Y. Epidermal growth factor induces cytokeratin 19 expression accompanied by increased growth abilities in human hepatocellular carcinoma. *Lab Invest* 2011; **91**: 262-272
- Peer reviewer:** Janney Sun, Professor, Executive Editor-In-Chief, Journal of Gastroenterology and Hepatology Research, Unit A1, 7/F, Cheuk Nang Plaza, 250 Hennessy Road, Wanchai, Hong Kong.