

Complicated Esophageal Duplication Cyst in Adult: A Case Report and Review of the Literature

Bassem Nasr, Fethi Derbel, Mohamed Ben Mabrouk, Jaafar Mazhoud, Waad Farhat, Malek Barka, Ben Ltaifa Afef, Mohamed Azzaza, Ben Abdelkader Atef, Youssef Chaker, Ali Ben Ali

Bassem Nasr, Fethi Derbel, Mohamed Ben Mabrouk, Jaafar Mazhoud, Waad Farhat, Malek Barka, Mohamed Azzaza, Ben Abdelkader Atef, Youssef Chaker, Ali Ben Ali, Department of general surgery, University hospital Sahloul, Sousse, Tunisia
Ben Ltaifa Afef, Department of anatomopathology and cytology, University hospital Farhat Hached, Sousse, Tunisia

Correspondence to: Fethi Derbel, Department of general surgery, University hospital Sahloul, Sousse, Tunisia

Email: Fethi.derbel@gmail.com

Telephone: +21624130460

Received: May 21, 2014

Revised: June 10, 2015

Accepted: June 20, 2015

Published online: October 21, 2015

ABSTRACT

Esophageal duplication cysts are rare embryonic malformations usually diagnosed in early childhood. They are often asymptomatic but they can cause dyspnoea, chest pain, or dysphagia or be complicated by intracystic hemorrhage, rupture, pulmonary or esophageal hemorrhage, and infection. Malignant transformation is an extremely rare event occurring within oesophageal cysts, adenocarcinoma being the most common histology. They are treated either surgically or endoscopically. We report a case of squamous cell carcinoma arising within an esophageal duplication cyst in adult complicated by perforation into thorax, treated with surgical resection.

© 2015 ACT. All rights reserved.

Key words: Esophagus; Duplication; Infection; Perforation; Cancer: Endoscopy; Surgery.

Nasr B, Derbel F, Mabrouk MB, Mazhoud J, Farhat W, Barka M, Afef BL, Azzaza M, Atef BA, Chaker Y, Ali AB. Complicated Esophageal Duplication Cyst in Adult: A Case Report and Review of the Literature. *Journal of Gastroenterology and Hepatology Re-*

search 2015; 4(10): 1801-1804 Available from: URL: <http://www.ghrnet.org/index.php/joghr/article/view/1422>

INTRODUCTION

Esophageal duplication cysts (EDCs) encountered within the gastrointestinal duplication cysts (GDCs) are rare embryonic malformations. The incidence of GDCs, which are mostly diagnosed in early childhood, is 1:100,000, with only about 160 cases described in adults. The frequent localizations are the ileum (50%) and esophagus (25%)^[1].

Up to 80% of esophageal duplication cysts are diagnosed in childhood: respiratory distress or nutritional difficulty due to mass effect. The majority of patients develop symptoms in the adolescence period, whereas symptomatic cysts are rarely encountered in adulthood (<7%) and the diagnosis is made most often from an incidental finding on the chest radiograph^[2,3].

In adults, although these cysts are usually asymptomatic, they can cause dysphagia or back pain or be complicated by intracystic hemorrhage, rupture, pulmonary or esophageal hemorrhage, and infection^[2,3].

Malignant trans-formation has also been reported^[2,4,6].

Complete surgical excision is the standard treatment^[7,8]. Most cysts are resected due to active symptoms. However, cysts that are incidentally found and asymptomatic are surgically resected to prevent potential complications from untreated duplication cysts^[9-11].

Treatment of symptomatic esophageal cysts can be either surgical or endoscopic. Surgical resection of the cyst is usually carried out in childhood or in adults, in cases of lesions impossible to treat endoscopically. Surgical treatment is currently moving from thoracotomy to less-invasive procedures, such as video-assisted thoracoscopic surgery and to endoscopic treatments which, however, still remain challenging interventions^[7,11,12].

We report a case of squamous cell carcinoma arising within an esophageal duplication cyst in adult with acute clinical presentation (perforation into thorax), treated with surgical resection.

CASE REPORT

A 30 years old man, without significant past medical history, presented a 7 day history of right sided pleuritic chest pain and fever, he had a vague abdominal pain.

On examination, he was febrile (38.5°C), polypnoeic, and the examination of the chest showed signs of consolidation at the right base.

The white cell count was 21000/ml and the rate of CRP was at 240 mg/L.

A thoracic CT showed an air containing lesion with fluid level associated with pleural effusion (Figure 1) suggesting complicated hydatid cyst of the lung associated with a hiatal hernia. A barium swallow showed 2 posteriors fluid levels which communicate with esophagus (Figure 2) suggesting complicated hiatal hernia containing stomach.

So the patient underwent a surgery. First time, the abdomen was open via medium laparotomy: the stomach and the eso-gastric junction was normal, we didn't found a hiatal hernia. Second time, the chest was open via a right posterolateral thoracotomy and entered through the sixth intercostal space.

A cystic esophageal duplication complicated by perforation and bronchiolar fistulae associated with a pyothorax were found (Figure 3 A, B, C and D).

The duplication was resected, the esophagus and the fistulae were sutured and the pyothorax was drained (Figure 4).

Histological examination of the resected piece showed a squamous cell carcinoma invading the different layers of the esophageal wall (Figure 5).

It's a squamous cell carcinoma of a cystic communicating duplicity of the thoracic esophagus complicated by perforation.

The immediate postoperative period was favorable. The patient was extubated on day 2 postoperatively. Five days after, the patient developed a respiratory distress, so, he was intubated. A chest CT scan showed large pleural effusion abundance. The patient was reoperated. A pyothorax was found and evacuated, and the esophageal sutures were sealed. The patient developed a septic shock and died on day 10 postoperatively.

DISCUSSION

Duplications of the alimentary tract are infrequent anomalies that can affect any portion of the gastrointestinal tract^[9].

Oesophageal duplications are the second most common form of enteric duplication after the ileum ones. They are tubular or cystic structures of variable size, which arise from the posterior mediastinum and lie in a retropleural location^[17,19].

In our case, the duplication of the oesophagus was cystic.

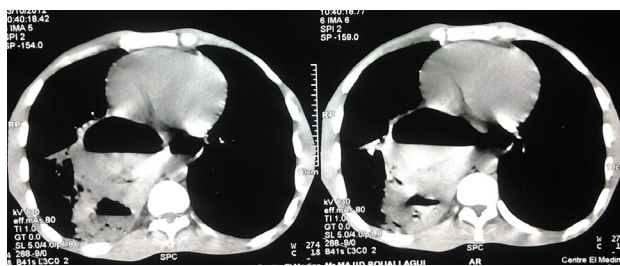


Figure 1 Thoracic CT showed an air containing lesion with fluid level associated with pleural effusion.

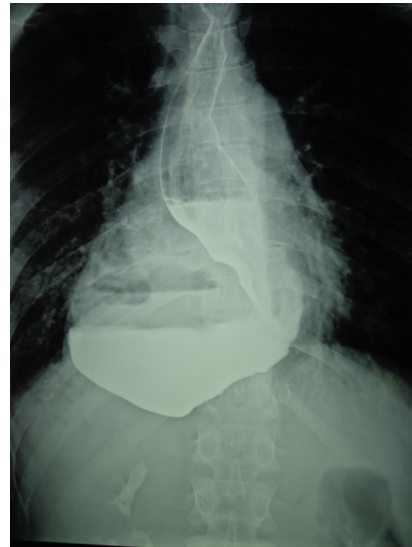

Figure 2 A barium swallow showed 2 fluid levels communicate with esophagus.

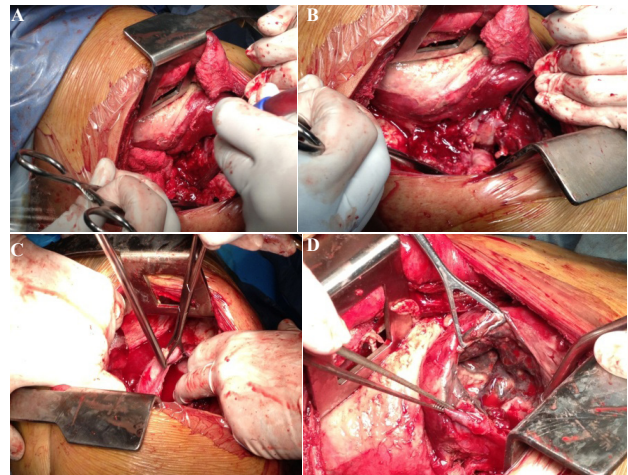


Figure 3 A, B, C: esophageal duplication; D: bronchiolar fistulae.

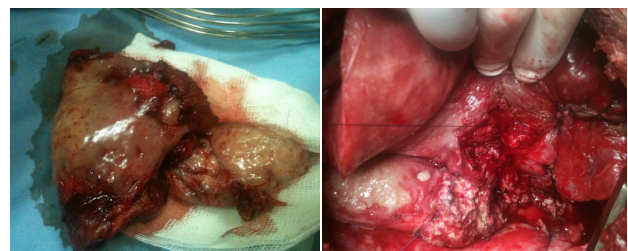


Figure 4 A: the resected duplication; B: suturing of esophagus and bronchiolar fistulae.

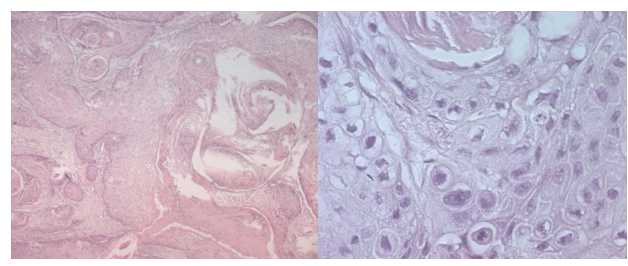


Figure 5 Histological examination: a squamous cell carcinoma invading the different layers of the esophageal wall.

A review of 96 patients with 101 alimentary tract duplications reported by Holcomb *et al.*^[7] showed that twenty-one duplications were confined to the oesophagus and all of these duplications were cystic. Seven of these EDCs contained ectopic gastric tissue.

For an esophageal cyst to be classified as duplication, it must meet the following criteria: (1) The cyst must be within or attached to the esophageal wall, (2) it must be covered by 2 muscle layers, (3) and the lining must be squamous, columnar, cuboidal, pseudostratified, or ciliated epithelium^[7].

Most of the cysts were reported to arise in the lower oesophagus, with only 23% occurring in the upper third^[6].

In this case, the EDC was present in the lower third of the oesophagus.

Clinical presentation varies, with the most common presenting symptoms being dysphagia, epigastric discomfort, and retrosternal pain^[11,13,18].

Karman I *et al.*^[1] reported a rare case of EDC revealed by back pain. Respiratory symptoms (chronic cough, recurrent respiratory infections) or tracheal compression are more common with upper oesophageal cysts and manifest in early childhood^[6,10,15,16,26].

Obasi PC *et al.*^[7] presented 2 pediatric cases with new onset shortness of breath and chest pain.

Acute onset is due to complication by intracystic hemorrhage, perforation, and infection, especially in those with oesophageal communication^[2].

In our case, the patient was completely asymptomatic until the onset of a right sided pleuritic chest pain, fever and a vague abdominal pain. A similar case to ours was reported by Grewal^[19]. Surgical exploration found a cystic esophageal duplication complicated by perforation and bronchiolar fistulae associated with a pyothorax.

Malignant transformation is an extremely rare event within oesophageal cysts. The most common histology is an adenocarcinoma, though squamous cell carcinoma has also been reported to arise within foregut cysts^[6]. In our case, Histological examination of the resected piece showed a squamous cell carcinoma invading the different layers of the esophageal wall.

Diagnosis can be established incidentally from routine chest radiographs or with a barium esophagram showing external compression of the oesophagus. However, computed tomography has the advantage over conventional diagnostic procedures because it demonstrates the cystic nature of the mass and its relationship to adjacent structures in a noninvasive manner. It permits simultaneous imaging and evaluation of the spine, pulmonary parenchyma, airway, and adjacent structures^[17].

Diagnosis may also be obtained via imaging of the lesion, with endoscopic ultrasound (EUS). EUS has a 2-fold advantage; both diagnostic and therapeutic. This is because the cyst content can be aspirated for immediate temporary relief of symptoms and for histological analysis of the cyst content^[20,21].

A case series among adults in Singapore described asymptomatic adults who were diagnosed incidentally from routine chest radiographs^[22].

Wiechowska-Kozłowska A *et al.*^[12] reported four cases of EDCs diagnosed with EUS in asymptomatic patients.

Differential diagnosis of a posterior mediastinal cyst includes degenerated neurogenic tumor, other GDCs and cystic lymphangioma^[13]. In endemic countries, hydatid cyst of lung can be confused with thoracic esophageal duplication and hydatid cyst of liver with those of abdominal esophagus^[27]. So, an indirect hemagglutination (IHA) test in the patient with a suspected hydatid cyst should be performed and it will be negative, but making a

definite diagnosis is still difficult even with radiological methods; therefore, transthoracic excision is crucial for a definitive diagnosis by histopathologic examination and for prevention of complications^[7,13,27], and it is the definitive treatment for esophageal cysts. In the present case, the diagnosis of EDC was established after surgical excision of the lesion. In fact, CT-scan suggested complicated hydatid cyst of the lung associated with a hiatal hernia and the barium swallow suggested complicated hiatal hernia containing stomach.

Open surgical resection via posterolateral thoracotomy incision has been considered the best surgical approach for the excision of the cysts. However, video-assisted thoracoscopic surgery (VATS) has recently become a viable surgical option for the excision of duplication cysts^[7,11].

Compared with the open approach, VATS reduces postoperative pain, leads to earlier recovery and hospital discharge, and has a better cosmetic outcome^[11,14]. In this case, we used an open approach because the patient had a poorly conditions and the duplication was complicated by pyothorax and bronchiolar fistula that the management was very difficult by VATS.

Most recently, some have advocated the use of robotic technology for surgical resection of such lesions. Robotic-assisted thoracoscopic (RATS) surgery is becoming more widely accepted and used^[23-25].

Compared with VATS, RATS has a few advantages: (1) superior visualization of the surgical field, (2) greater range of motion with multi-articulated instruments, and (3) more precise movements with tremor filtration and motion scaling^[23].

Obasi *et al.*^[7] presented 2 pediatric patients who underwent successful surgical resection of esophageal duplication cysts via RATS using the da Vinci surgical system. They had no operative complications but did have excellent postoperative outcomes including decreased pain and early patient discharge.

CONFLICT OF INTERESTS

There are no conflicts of interest with regard to the present study.

REFERENCES

- 1 Karaman I, Gürel D, Ünlü M, Yılmaz E, Karaçam V, Kargı A. Esophageal duplication cyst: a rare cause of back pain. *The Turkish Journal of Gastroenterology* 2012; **23**(5): 610-1
- 2 Pisello F, Geraci G, Arnone E. Acute onset of esophageal duplication cyst in adult. Case report. *G Chir* 2009; **30**: 17-20
- 3 Neumann J, Atkins DJ, Zirngibl H. Esophageal cyst--a rare cause of backache. *Zentralbl Chir* 1998; **123**: 1175-1179
- 4 Lee MY, Jensen E, Kwak S, Larson RA. Metastatic adenocarcinoma arising in a congenital foregut cyst of the esophagus: a case report with review of the literature. *Am J Clin Oncol* 1998; **21**: 64-66
- 5 Javan N G, Debnath J, Kumar A, Das C J. Oesophageal duplication cyst: an unusual cause of retrosternal pain and dysphagia in an adult. *Singapore Med J* 2008; **49**(9): e243
- 6 R Jacob, N D Hawkes, N Dallimore, E G Butchart, G A O Thomas, T S Maughan. Squamous carcinoma in an oesophageal foregut cyst. *The British Journal of Radiology* 2003; **76**: 343-346
- 7 Patrick Chidi Obasi, Andre Hebra, Juan Carlos Varela. Excision of Esophageal Duplication Cysts with Robotic-Assisted Thoracoscopic Surgery. *JSLs* 2011; **15**: 244-247
- 8 Abhishek Agarwal, Sandeep Singla, Meghana Bansal and Aytakin Ozdemir. Infected Esophageal Duplication Cyst Masquerading as Pericarditis. *Intern Med* 2012; **51**: 689-690
- 9 Ringley C, Bochkarev V, Oleynikov D. Esophageal duplication cyst--a guest case in robotic and computer-assisted surgery from the university of Nebraska Medical Center. *Medscape General*

- Medicine* 2006; **8(4)**: 25
- 10 Singh K, Saxena A, Narasimha K, Singh M, Suri S. Esophageal duplication cyst: An unusual case of respiratory distress in infants. *Pediatr Emerg Care* 2005; **21(12)**: 854-856
 - 11 Kang CU, Cho DG, Cho KD, Jo MS. Thoracoscopic stapled resection of multiple esophageal duplication cysts with different pathological findings. *Eur J Cardiothorac Surg* 2008; **34**: 216-218
 - 12 Wiechowska-Kozłowska A. Esophageal duplication cysts: Endosonographic findings in asymptomatic patients. *World J Gastroenterol* 2012 March 21; **18(11)**: 1270-1272
 - 13 Singh K, Naik R. Esophageal cyst--a case report. *Indian J Pathol Microbiol* 2006; **49**: 396-397
 - 14 Hazelrigg SR, Landreneau RJ, Mack MJ, Acuff TE. Thoracoscopic resection of mediastinal cysts. *Ann Thorac Surg* 1993; **56(3)**: 659-660
 - 15 N Aloui, W Douira, I Bellagha et A Hammou. Quel est votre diagnostic ? *J Radiol* 2004; **85**: 1739-1741
 - 16 Bajpai M, Mathur M. Duplication of the alimentary tract: clues to the missing links. *J Pediatr Surg* 1994; **29**: 1361-1365
 - 17 GEORGE W. HOLCOMB III, ALI GHEISSARI, JAMES A. O'NEILL, JR., NICHOLAS A. SHORTER, HARRY C. BISHOP. Surgical Management of Alimentary Tract Duplications. *Ann. Surg.* February 1989; Vol. 209, No. 2
 - 18 Magnus J. Mansard, Upender Rao, Pradeep Rebala, Guduru V. Rao, Duvvuru N. Reddy Esophageal Duplication Cyst Masquerading as a Stromal Tumor in an Adult. *Indian J Surg* (November–December 2011); **73(6)**: 441-443
 - 19 H P GREWAL, J N LEVERMENT. Total oesophageal duplication associated with dextrocardia and situs inversus. *Thorax* 1989; **44**: 1049-1050
 - 20 Lim LL, Ho KY, Goh PM. Preoperative diagnosis of a paraesophageal bronchogenic cyst using endosonography. *Ann Thorac Surg* 2002; **73**: 6335
 - 21 Bhutani MS, Hoffman BJ, Reed C. Endosonographic diagnosis of an esophageal duplication cyst. *Endoscopy* 1996; **28**: 396-397
 - 22 Tan YK, Hui MT, Wong J, Yeo CT, Sng I, Ong YY. Four cases of developmental foregut cysts. *Ann Acad Med Singapore* 1996; **25**: 763-768
 - 23 Bodnes J, Zitt M, Ott H. Robotic-assisted thoracoscopic surgery (RATS) for benign and malignant esophageal tumors. *Ann Thorac Surg* 2005; **80**: 1202-1206
 - 24 Melfi F, Menconi GF, Mariani M, Angeletti CA. early experience with robotic technology for thoracoscopic surgery. *Eur J Cardiothorac Surg* 2002; **21**: 864-868
 - 25 Bodner J, Wykypiel H, Wetscher G, Schmid T. First experiences with the da Vinci operating robot in thoracic surgery. *Eur J Cardiothorac Surg* 2004; **25**: 844-851
 - 26 Ahmad Hammoud, Mohammad Hourani, Mouniat Akoum, Mar-iam Rajab. Foregut Duplication Cyst: An Unusual Presentation During Childhood. *N Am J Med Sci* 2012 June; **4(6)**: 287-289
 - 27 Gümüş M, Önder A, Firat U, Kapan M, Önder H, Gırgın S. Hydatid cyst-like intra-abdominal esophageal duplication cyst in an endemic region. *The Turkish Journal of Gastroenterology* 2011 Oct; **22(5)**: 557-558

Peer reviewers: Lars Grenacher, Professor, Department of Diagnostic and Interventional Radiology, University of Heidelberg, Im Neuenheimer Feld 110, 69120 Heidelberg, Germany.