

## Anal Canal Basaloid Carcinoma Treated with Local Resection and Radiation: A Case Report

Yoshifumi Nakayama, Masaki Akiyama, Yusuke Sawatsubashi, Noritaka Minagawa, Takayuki Torigoe, Yasuhiro Kantake, Keiji Hirata

Yoshifumi Nakayama, Masaki Akiyama, Yusuke Sawatsubashi, Noritaka Minagawa, Takayuki Torigoe, Keiji Hirata, Department of Surgery 1, School of Medicine, University of Occupational and Environmental Health. 1-1 Iseigaoka, Yahata-nishi-ku, Kitakyushu 807-8555, Japan

Yoshifumi Nakayama, Masaki Akiyama, Yusuke Sawatsubashi, Department of Gastroenterological and General Surgery, Wakamatsu Hospital of University of Occupational and Environmental Health, 1-17-1 Hamamachi, Wakamatsu-ku, Kitakyushu 808-0024, Japan

Yasuhiro Kantake, Kantake Proctologic Clinic. 3-1-13 Einomaru, Yahata-nishi-ku, Kitakyushu, 807-0851, Japan

Correspondence to: Yoshifumi Nakayama, Department of Gastroenterological and General Surgery, Wakamatsu Hospital of University of Occupational and Environmental Health, Japan.

Email: [nakayama@med.uoeh-u.ac.jp](mailto:nakayama@med.uoeh-u.ac.jp)

Telephone: +81-93-761-0090 Fax: +81-93-588-3904

Received: October 22, 2015 Revised: November 26, 2015

Accepted: November 28, 2015

Published online: December 21, 2015

### ABSTRACT

We herein report a case of anal canal basaloid carcinoma that received consecutive treatments. A 61-year-old Japanese female suffered from a hemorrhage with prolapse for five years. As this symptom worsened, she underwent hemorrhoidectomy at another clinic. At that time, a little-finger tumor near the hemorrhoid located at 4 o'clock was identified and the patient underwent combined resection. The pathological diagnosis of this tumor was basaloid carcinoma invaded to the submucosal layer, with positive lymphatic invasion and a positive horizontal tumor margin. She was referred to the surgical outpatient clinic for a detailed examination and consecutive treatments. Additional resection was performed at the previous operative scar. This specimen pathologically indicated that a small residuary tumor of basaloid carcinoma was located in the mucosal layer. Radiotherapy

was additionally performed at the pelvic cavity and bilateral inguinal area. The patient has survived without recurrence for approximately 13 years after the consecutive treatments.

© 2015 ACT. All rights reserved.

**Key words:** Anal canal; Basaloid carcinoma; Consecutive treatments; Resection; Radiotherapy

Nakayama Y, Akiyama M, Sawatsubashi Y, Minagawa N, Torigoe T, Kantake Y, Hirata K. Anal Canal Basaloid Carcinoma Treated with Local Resection and Radiation: A Case Report. *Journal of Gastroenterology and Hepatology Research* 2015; 4(12): 1877-1879 Available from: URL: <http://www.ghrnet.org/index.php/joghr/article/view/1440>

### INTRODUCTION

Anal canal carcinomas include several histological types, such as squamous cell carcinoma, basaloid/cloacogenic carcinoma and adenocarcinoma, due to the existence of several types of epithelial cells in the anal canal. The most common subtype is squamous cell carcinoma<sup>[1,2]</sup>, and basaloid carcinoma is considered to be an aggressive variant of squamous cell carcinoma<sup>[3]</sup>.

The incident of anal canal carcinoma in Japan is 2% of all colorectal carcinomas and basaloid carcinoma accounts for 1.6% of all anal canal neoplasms reported to the Japanese Society for Cancer of the Colon and Rectum<sup>[4]</sup>. Therefore, anal canal basaloid carcinoma is a comparatively rare disease.

In the present case, the anal canal basaloid carcinoma was limited to the submucosal layer with lymphatic vessel invasion and a positive horizontal margin in the mucosal layer. Additional resection was performed at the previous operative scar. Moreover, radiotherapy was performed at the pelvic cavity and bilateral inguinal area. This report presents a therapeutic case of anal canal basaloid carcinoma with consecutive treatments.

## CASE REPORT

A 61-year-old Japanese female suffered from a hemorrhage with prolapse for five years. As this symptom worsened, she underwent hemorrhoidectomy at another clinic. At that time, a little-finger tumor nearby the hemorrhoid located at 4 o'clock was identified and the patient underwent combined resection. The pathological diagnosis of this tumor was basaloid carcinoma invaded to the submucosal layer (Figure 1a), with positive lymphatic invasion (Figure 1c) and a positive horizontal tumor margin (Figure 1b).

She was referred to the surgical outpatient clinic for a detailed examination and consecutive treatments. The laboratory data showed that she had a white blood cell count of 6,200/mm<sup>3</sup>, hemoglobin of 13.7 g/dl, hematocrit of 41.0%, platelets count of 234,000/mm<sup>3</sup>, normal electrolytes, as well as normal blood urea nitrogen levels and a normal liver function. The patient's CEA was 1.5 ng/ml and SCC was 1.3 U/ml. Operative scars located at 4-5 o'clock, 7 o'clock and 11 o'clock were identified. No tumor was macroscopically identified in these scars.

An additional resection was performed at the previous operative scar located at 4-5 o'clock (Figure 2a and 2b).

This specimen pathologically indicated a small residuary tumor of basaloid carcinoma in the mucosal layer (Figure 3a and 3b).

Radiotherapy was performed at the pelvic cavity and bilateral inguinal area (1.8 Gy x 28, total 50.4 Gy).

The patient had an uneventful recovery and was discharged from the hospital on the 14th day after the operation. She has been followed up in the outpatient clinic without recurrence for approximately 13 years since undergoing the consecutive treatments.

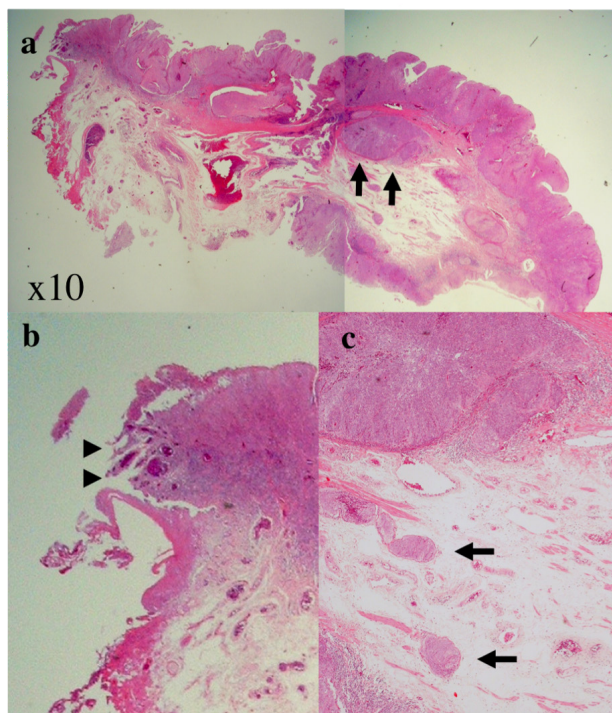
## DISCUSSION

Anal canal basaloid/cloacogenic carcinomas are thought to arise from cloacogenic remnants<sup>[5]</sup>. That is, basaloid carcinoma of the anal canal is considered to be a poorly differentiated variant of the cloacogenic tumors arising in the basal layer of the transitional zone epithelium<sup>[6]</sup>. Basaloid carcinoma currently belongs in the squamous cell carcinoma group as a variant according to the second edition of the WHO classification system of anal carcinomas<sup>[7]</sup>. In this classification system, the variants of anal canal squamous cell carcinoma, including large cell keratinizing, large cell nonkeratinizing (cloacogenic) and basaloid type, are grouped by a similar nature history, response to treatment and prognosis<sup>[8,9]</sup>.

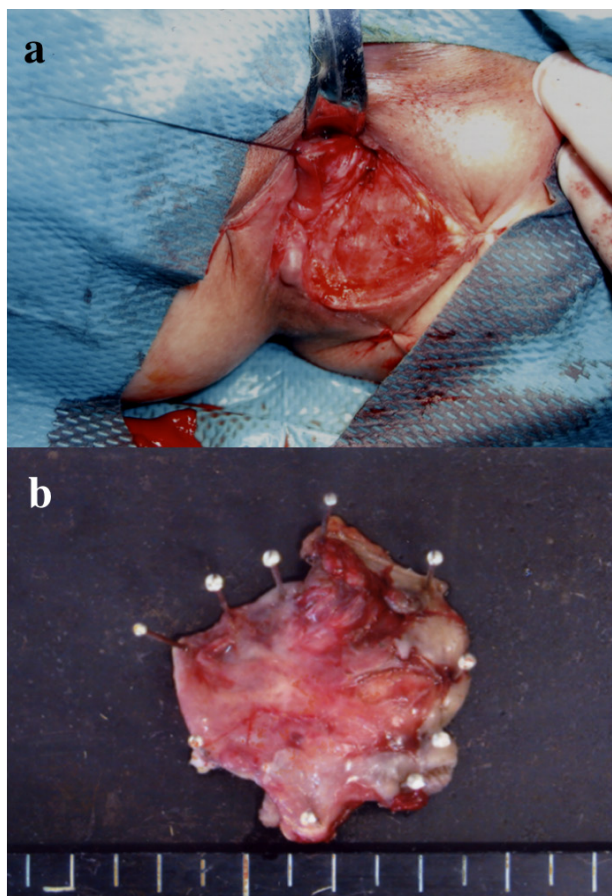
Anal canal basaloid carcinoma exhibits a highly malignant potential<sup>[10]</sup>. The incidence of lymph node metastasis is reportedly 40~52.3% at the diagnosis<sup>[1,2]</sup> and the incidence of inguinal lymph node metastasis was approximately 20%<sup>[2]</sup>. Moreover, the rate of distant metastasis is reportedly 13.3-19.0% at the diagnosis<sup>[1,5]</sup>.

The incidence of anal cancer is increasing due to its risk factors<sup>[11]</sup>, such as anal-genital human papillomavirus (HPV) infection, immunosuppression associated with human immunodeficiency virus or transplantation and smoking<sup>[12,13]</sup>. In the present patient, there was no symptom of anal-genital HPV infection or immunosuppression. Although the result of HTLV-I testing was negative, an HPV examination was not performed.

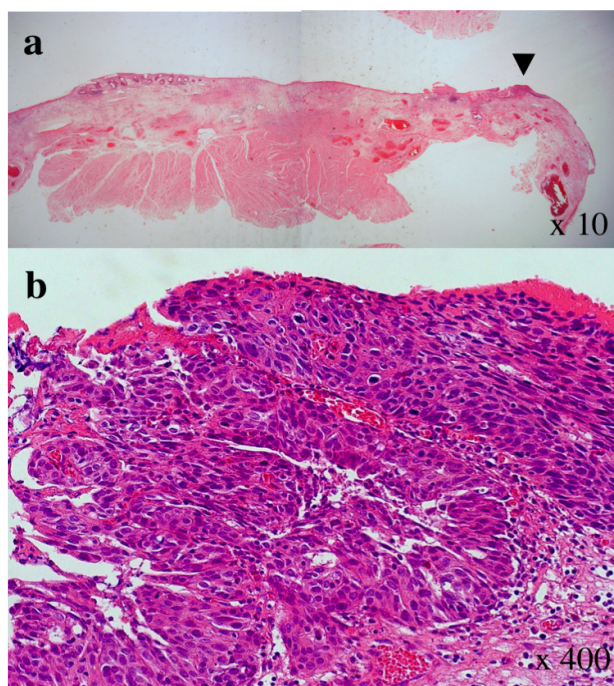
In Japan, abdominoperineal resection (APR) was generally performed for the patients with anal canal basaloid carcinoma until several years ago. Conversely, nearly all patients with anal canal squamous cell carcinoma, including basaloid carcinoma, are initially treated with chemoradiation therapy in Western Countries and



**Figure 1** The initially resected specimen. A histopathological examination revealed basaloid carcinoma invaded to the submucosal layer (arrows) (a). The cut end showed a positive horizontal tumor margin (arrowheads) (b), with positive lymphatic invasion (arrows) (c).



**Figure 2** An additional resection was performed at the previous operative scar located at 4-5 o'clock (a). No tumor was macroscopically identified at the scar on the analysis of the resected specimen (b).



**Figure 3** This specimen pathologically indicated a small residuary tumor of basaloid carcinoma (arrowhead) in the mucosal layer of the additionally resected specimen (a). A histopathological examination with hematoxylin and eosin staining revealed basaloid carcinoma of the residuary tumor (b).

subjected to subsequent APR only if a residual tumor remained at the time of a postradiation biopsy<sup>[14,15]</sup>. The treatment of anal canal basaloid or squamous cell carcinoma in Japan has recently changed to chemoradiation therapy as the first-line treatment due increased the patient's quality of life.

The NCCN guidelines currently indicate that concurrent chemoradiation therapy is the recommended primary treatment for patients with nonmetastatic anal canal cancer<sup>[7]</sup>. The NCCN guidelines also indicate that the primary treatment for patients with T1, N0 and well-differentiated squamous cell carcinoma of anal cancer is local excision with adequate margins<sup>[7]</sup>. Patients with inadequate margins are advised to undergo re-excision or to consider the local radiation therapy with or without 5-FU based chemotherapy<sup>[7]</sup>. In the present case, the patient (T1, N0) with basaloid carcinoma underwent consecutive treatments as recommended by the NCCN guidelines.

## CONCLUSION

This report described a therapeutic case of anal canal basaloid carcinoma with the consecutive treatments. It is important to undergo the suitable treatments for the patients with anal canal basaloid carcinoma depending on the situation.

## CONFLICT OF INTERESTS

There are no conflicts of interest with regard to the present study.

## REFERENCES

- 1 Tokoro T, Okuno K, Hida J, Ishimaru E, Ueda K, Yoshifuji T, Matsuzaki T, Yasutomi M, Shiozaki H; Anal canal basaloid carcinoma showing histological variants: Report of a case and review of the Japanese literature. *Acta Med Kinki Univ* 2006; **31**: 41-45
- 2 Boman BM, Moertel CG, O'Connell MJ, Scott M, Weiland LH, Beart RW, Gunderson LL, Spencer RJ; Carcinoma of the anal canal. A clinical and pathological study of 188 cases. *Cancer* 1984; **54**: 114-125
- 3 Vasudev P, Boutross-Tadross O, Radhi J; Basaloid squamous cell carcinoma: two case reports. *Cases Journal* 2009; **13**: 9351
- 4 Sameshima S, Sawada T, Nagasako K; Squamous cell carcinoma of anus and carcinoma in association with anal fistula in Japan, Multi-institutional registration. *Nippon Daicho Komonbyo Gakkai Zasshi* 2005; **58**: 415-421 (Japanese)
- 5 Klotz RG Jr, Pamukcoglu T, Souillard DH; Transitional cloacogenic carcinoma of the anal canal. Clinicopathologic study of three hundred seventy-three cases. *Cancer* 1967; **20**: 1727-1745.
- 6 Gillespie JJ, MacKay B; Histogenesis of cloacogenic carcinoma. Fine structure of anal transitional epithelium and cloacogenic carcinoma. *Human Pathology* 1978; **9**: 579-587
- 7 Benson AB 3rd, III, Bekaii-Saab T, Chan E, Chen YJ, Choti MA, Cooper HS, Engstrom PF, Enzinger PC, Fakih MG, Fuchs CS, Grem JL, Hunt S, Leong LA, Lin E, Martin MG, May KS, Mulcahy MF, Murphy K, Rohren E, Ryan DP, Saltz L, Sharma S, Shibata D, Skibber JM, Small W, Sofocleous CT, Venook AP, Willett CG (2013) NCCN Clinical Practice Guidelines in Oncology (NCCN Guidelines) Anal Carcinoma. Version 2. NCCN org
- 8 Klas JV, Rothenberger DA, Wong WD, Madoff RD. Malignant tumors of the anal canal: the spectrum of disease, treatment, and outcomes. *Cancer* 1999; **85**: 1686-1693
- 9 Lee WS, Chun HK, Lee WY, Yun SH, Yun H, Cho YB, Kang WK, Park SJ, Ahn C, Park W. Anal canal carcinoma: experience from a single Korean institute. *Yonsei Med J* 2007; **48**: 827-832.
- 10 Cullen PK, Pontius EE, Sanders RJ. Cloacogenic anorectal carcinoma. *Dis Colon Rectum* 1996; **9**: 1-12
- 11 Johnson LG, Madeleine MM, Newcomer LM, Schwartz SM, Daling JR. Anal cancer incidence and survival: the surveillance, epidemiology, and end results experience, 1973-2000. *Cancer* 2004; **101**: 281-288
- 12 Gervaz P, Calmy A, Durmishi Y, Allal AS, Morel P. Squamous cell carcinoma of the anus - an opportunistic cancer in HIV-positive male homosexuals. *World J Gastroenterol* 2011; **17**: 2987-2991
- 13 Shia J. An update on tumors of the anal canal. *Arch Pathol Lab Med* 2010; **134**: 1601-1611
- 14 Doci R, Zucali R, Bombelli L, Montalto F, Lamonica G. Combined chemoradiation therapy for anal cancer. A report of 56 cases. *Ann Surg* 1992; **215**: 150-156
- 15 Leichman L, Nigro N, Vaitkevicius VK, Considine B, Buroker T, Bradley G, Seydel HG, Olchowski S, Cummoms G, Leichman C. Cancer of the anal canal. Model for preoperative adjuvant combined modality therapy. *Am J Med* 1985; **78**: 211-215

**Peer reviewer:** Ilker Etikan, Department of Biostatistics, Faculty