

## Feasibility of Roux-en-Y Loop Enteroscopy in Children with Liver Disease

B Vadamalayan, M Davenport, A Baker, J Hind, A Dhawan

B Vadamalayan, M Davenport, A Baker, J Hind, A Dhawan, Paediatric Liver, GI and Nutrition Centre, King's College Hospital, London SE5 9RS, United Kingdom

Correspondence to: Babu Vadamalayan, Paediatric Liver, GI and Nutrition Centre, King's College Hospital, London SE5 9RS, United Kingdom. [babu.vadamalayan@nhs.net](mailto:babu.vadamalayan@nhs.net)

Telephone: +44-20-3299-1674 Fax: +44-20-3299-4228

Received: March 13, 2012 Revised: April 24, 2012

Accepted: April 28, 2012

Published online: August 21, 2012

### ABSTRACT

**AIM:** The Roux loop is a common technique used in reconstructive biliary surgery, which diverts bile flow into the proximal jejunum. It may be a source of problems postoperatively such as cholangitis due to stenosis or anastomotic bleeding, which can be difficult to diagnose by conventional endoscopic techniques. In adults, the Roux loop has been accessed using balloon enteroscopes and we now report our experience of using the single and double balloon enteroscopes in children with liver disease.

**METHODS:** Retrospectively reviewed the number of children (under the age of 16 years) whom have had Roux-en-Y loop enteroscopy after having reconstructive surgery at King's College Hospital prior to December 2011. All procedures were performed under general anaesthesia under fluoroscopic control. Single balloon enteroscope (Olympus SIF type Q260) and outer tube (Olympus ST-SB1-length 140cm and double balloon enteroscope (EN-450T5) and outer tube TS-13140 (Fujinon) were used in this study.

**RESULTS:** Total of 3 patients, 2 males and 1 female patient were identified. Two procedures were performed using single balloon enteroscope and one was using double balloon enteroscope. Roux-en-Y loop enteroscopy was successful among all three patients using single or double balloon enteroscopy. Procedures were uncomplicated and patients were discharged without any problems.

**CONCLUSIONS:** RNY loop examination is possible after small bowel reconstructive surgery in children and this could be attempted in specialised centres prior to considering surgical intervention; using single or double balloon enteroscope and this could potentially avoid the need for surgery.

**Key words:** Biliary atresia (BA); Kasai portoenterostomy (PE); Roux-en-Y loop (RNY); Double balloon enteroscope (DBE); Single balloon enteroscope (SBE); Hepatobiliary iminodiacetic acid (HIDA)

Vadamalayan B, Davenport M, Baker A, Hind J, Dhawan A. Feasibility of Roux-en-Y Loop Enteroscopy in Children with Liver Disease. *Journal of Gastroenterology and Hepatology Research* 2012; 1(7): 130-133 Available from: URL: <http://www.ghrnet.org/index./joghr/>

### INTRODUCTION

The Roux-en-Y loop is a common technique used in reconstructive biliary surgery that diverts bile flow into the proximal jejunum. In children, the commonest indications are to correct biliary obstruction due to biliary atresia(BA)<sup>[1,2]</sup> and choledochal malformation. Typically the jejuno-jejunostomy is about 20 centimeters beyond the duodenojejunal junction, which makes it almost impossible to access using conventional endoscopes. In 2009, Moreels *et al*<sup>[3]</sup> reported using double balloon enteroscope successfully to access the Roux loop in adults, and thereafter isolated cases have been reported in children using a single<sup>[4]</sup> and double<sup>[5]</sup> balloon enteroscope. We now report our experience of using balloon enteroscopes to access the Roux loop in children with chronic liver disease.

### PATIENTS AND METHODS

From March 2009 until December 2011, a total of 3 patients with previous Roux-en-Y loop entero-enteric anastomosis were referred to King's College Hospital with history of melena, cholestasis and diarrhoea. Informed consent was obtained for the Roux-en-Y loop enteroscopy to assess the potential pathology in the excluded part of the bowel. The male/female ration was 2:1 with mean age of 11.3 years (range 9-13 years). All procedures were performed under general anaesthesia in supine position. Patients were admitted to the hospital prior to the procedure and observed for 24 h after the procedures for potential complications such as infection, bleeding, perforation and pancreatitis. Descriptive statistics were used to assess the indications, success rate and complications.

### RESULTS

All three patients had previous abdominal surgery with Roux-en-Y loop anastomosis. Case 1 and Case 2 details were given below. Case 3

was a 9 years old girl, 8 years after having biliary reconstructive surgery presented with history of intermittent diarrhoea and abdominal bloating needing multiple courses of antibiotics for suspected bacterial over growth. There were no pathology suspected at the level of enterobiliary anastomosis on case 3 and Roux-en-Y loop was accessed to assess for the potential inflammatory pathology at the excluded part of the bowel and this was excluded after using single balloon enteroscope, using same technique similar to case 2.

#### Case 1

A 13 year old boy (weight 35 kg) presented with a short history of severe intermittent melaena requiring blood transfusion. He was born with BA and had undergone a Kasai portoenterostomy at 15 days of age. He had been anicteric but had clinical, laboratory and ultrasound features of chronic liver disease and portal hypertension for few years prior to the presentation. He was followed up regularly in outpatient clinics and the surveillance gastroscopy examinations revealed only grade I-II varices, which did not need any intervention in the past. Laboratory findings during admission for melaena revealed Hb 6.9 (normal value(nv): 13.0-16.5 g/dL), PCV 0.218 (nv: 0.40-0.54 L/L), WCC 3.62 ( nv: 4.00-11.00 $\times 10^9$ /L), platelets 74 (nv:150-450 $\times 10^9$ /L), INR 1.5 (nv: 0.9-1.20 ratio), APTT 1.19 (nv: 0.85-1.13 ratio), fibrinogen 2.3 (nv: 1.5-4.5 g/L) Albumin 25 (nv: 35-50 g/L),total protein 45 (nv: 60-80 g/L), total bilirubin 29 (nv:3-20 umol/L), alkaline phosphatase (ALP) 133 (nv: 178-455 IU/L), aspartate aminotransferase (AST) 107 (nv: 10-50 IU/L),  $\gamma$ -glutamyl-transpeptidase (GGT) 140 (nv: 1-55 IU/L). Clinical, laboratory and ultrasound examination confirmed features of portal hypertension due to chronic liver disease again during this admission. Conventional upper gastrointestinal endoscopy to 3<sup>rd</sup> part of duodenum showed grade II oesophageal varices although without stigmata and no evidence of recent or current bleeding. Small bowel capsule endoscopy (Given imaging) to caecum and colonoscopy to terminal ileum were all normal. He also had negative Meckel's scan and red blood cell labelled nuclear scan which did not reveal active bleeding site. He was treated with vitamin K injection, blood transfusion and octreotide infusion but he continued to have intermittent episodes of melaena.

Under general anaesthesia, total antegrade enteroscopy including the Roux loop was then performed using a single balloon enteroscope (Olympus SIF type Q260-length 200 cm, outer diameter 8.5 mm and inner diameter 2.8 mm) and outer tube (Olympus ST-SB1-length 140 cm and the outer diameter 13.2 mm.) Enteroscope was passed through the outer tube initially and then advanced beyond the 2<sup>nd</sup> part of duodenum, subsequently over tube balloon was inflated and the scope was withdrawn along with over tube. Scope was inserted further deep into the small bowel, followed by the outer tube and inflation of the balloon. Push and pull method was repeated until the small bowel was visualised as far as the caecum. The enteroscope was then withdrawn and the origin of the Roux loop identified at about 50 cm from the duodenum-jejunal flexure (Figure 1). Scope was advanced to about 20 cm into the afferent limb and then with a combination of balloon inflation/deflation until the site of the portoenterostomy reached. Although there was obvious biliary drainage no site of bleeding was identified. No complications or difficulties were encountered during this procedure.

#### Case 2

A 12-year-old boy (weight 32 kg) presented with jaundice, having been otherwise well. He was born with BA and underwent portoenterostomy at 25 days of age, clearing his jaundice completely. There was no previous history of cholangitis or gastrointestinal bleeding. On

examination he was afebrile and appeared well. Laboratory findings showed conjugated jaundice [106  $\mu$ mol/L (nv 3-20)], and an elevated liver enzyme profile (ALP 2366 IU/L, GGT 1106 IU/L, AST 233 IU/L). Liver ultrasound showed features of chronic liver disease but there were no dilated biliary radicals. There was normal portal and arterial flow and the spleen size was 16.5 cm. Hepatobiliary radioisotope scan using (HIDA-hepatobiliary iminodiacetic acid) showed normal extraction fraction with reduced hepatocyte function but with demonstrable excretion delay, with hold up, presumable at the Roux loop level (Extraction fraction=96 ( 92-100%), Excretion T 1/2=26 ( 11-31 min). Roux loop enteroscopy was performed using a double balloon enteroscope system by the ante-grade approach under general anaesthesia. For this case we used Fujinon double balloon enteroscope (EN-450T5) and outer tube TS-13140 (Fujinon). Total length of the double balloon scope was 230 cm and inner diameter was 2.8 mm in size. Fujinon's outer tube's length was 145 cm and the diameter was 13.2 mm. By inflating and deflating the balloon at the distal end of endoscope and over tube advanced enteroscope advanced deep into the small bowel. There was no apparent obstruction in the Roux loop and the portoenterostomy could be seen (see Figures 2 and 3). Total duration of the procedure was 100 min and there were no post procedural complications reported.

In the absence of a mechanical problem, he was treated with broad spectrum antibiotics and observed. His bilirubin gradually returned to normal within four weeks of treatment and liver enzymes gradually improved except GGT (bilirubin 6 umol/L, ALP 382 IU/L, AST 44 IU/L, GGT119 IU/L and AST 58 IU/L). He continues to be well 10 months after the procedure.

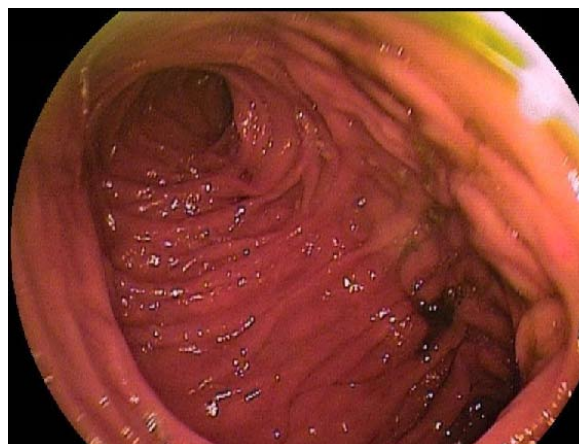


Figure 1 RNY loop (showing afferent and efferent limb).

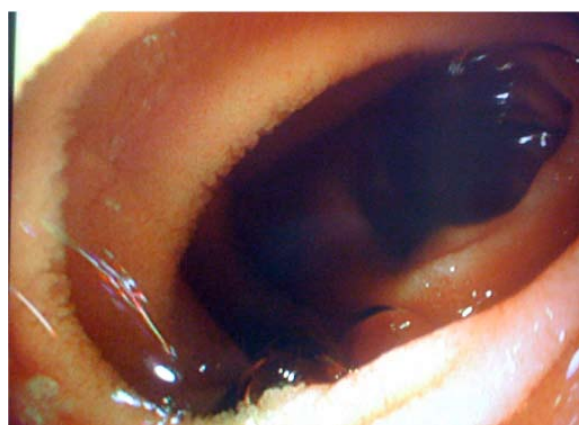


Figure 2 Bile flow in excluded part of jejunum.

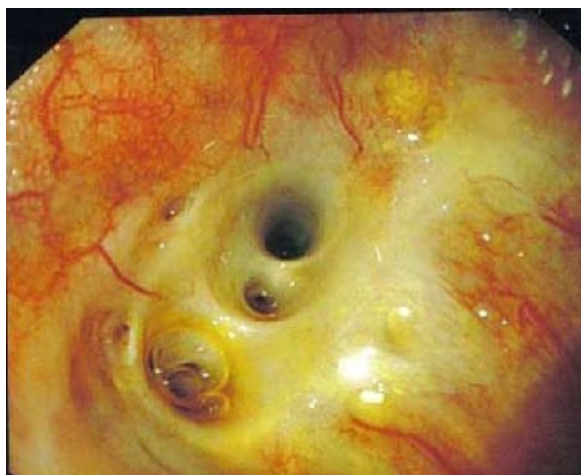

Figure 3 Portoenterostomy site.

## DISCUSSION

Yamamoto *et al* have first introduced the concept of double balloon enteroscope to examine the entire small bowel. Recently, in addition single balloon enteroscopy and spiral enteroscopy have been introduced to examine the small bowel and proven to be invaluable in the management of small bowel diseases<sup>[4-7]</sup>. In adults balloon enteroscopes have been used not only for the diagnosis and management of small bowel disease but also used for difficult colonoscopy and to access the Roux-en-Y loop after small bowel reconstructive surgery such as bariatric surgery for obesity and for biliary drainage.

Biliary atresia (BA) is an important surgically remediable cause of neonatal cholestasis. It is caused by an ill-understood progressive inflammatory destruction of the initially normal fetal or neonatal extra hepatic and intrahepatic biliary system, characterized by a profound cholestasis with reduced, or ultimately absent pigment in stools rendering them pale. Hepatportoenterostomy, also known as the Kasai procedure, remains the standard surgical procedure used to treat infants with biliary atresia<sup>[8]</sup>. In this procedure a portion of the small intestine is attached to the underside of the liver to drain the bile directly into the intestine. Examination of RNY loop after the surgery has been difficult prior to the introduction of balloon enteroscopes. Problems such as infection, ulcer, inflammation, bleeding, stricture and bacterial overgrowth continues to be a problem in this excluded part of the small bowel<sup>[9]</sup>. Surgical, percutaneous transhepatic or laparoscopic approach was the only option in the past, which has high morbidity and the risk if adhesions following surgery. Attempts to reach the afferent limb endoscopically have been made with paediatric colonoscopes, push enteroscopes and side viewing duodenoscopes in the past but recently this part of the bowel has been successfully accessed using balloon enteroscopes<sup>[5,6]</sup>.

In our unit balloon enteroscope procedures for children are performed under general anesthesia. Patients were placed in left lateral or supine position and the enteroscope followed by the over tube was passed into the small bowel. Identifying afferent and efferent limb of the RNY loop can be difficult but observing intra luminal foamy bile flow from the afferent limb and anti peristaltic contractions in the afferent limb could be useful. Fluoroscopy could also be used to identify the correct limb, as afferent limb often orient towards the upper abdomen. If efferent limb was entered by mistake, India ink could be used to mark the efferent limb to avoid making the same mistake again. Therapeutic and diagnostic

procedures including cholangiogram and ERCP are possible with the availability of appropriate accessories but currently this is limited<sup>[6]</sup>. Moreels *et al* and others have reported the feasibility of ERCP (Endoscopic Retrograde Cholangio Pancreatography) after RNY reconstructive surgery using single<sup>[11,12]</sup> and double<sup>[10,13]</sup> balloon enteroscope in adults and this could avoid the need for surgical intervention. Nishimura *et al*<sup>[5]</sup> have reported the same in children using double balloon enteroscope and to our knowledge were no reports of using single balloon enteroscope successfully for this purpose in children.

Standard endoscopic procedure complications including infection, bleeding perforation and pancreatitis are a possibility during balloon enteroscopy especially after therapeutic procedures. Mensink *et al*<sup>[14]</sup> have reported 0.8% risk of complications following diagnostic and 4.3% following therapeutic double balloon enteroscopy and aktas *et al* have reported 4.8% complications following therapeutic single balloon enteroscopy but none after diagnostic procedures<sup>[15]</sup>. Nishimura *et al* have reported 92 procedures in 48 pediatric patients using double balloon enteroscope and reported no perforation or pancreatitis.

## CONCLUSIONS

Single or double balloon enteroscopy can be used safely and successfully after biliary atresia surgery in children to examine the entire small bowel including the previously inaccessible RNY loop. Unexplained bleeding and cholestasis due to obstructions or narrowing at the level of RNY loop are potential indications for this procedure. RNY loop examination is possible after small bowel reconstructive surgery in children and could be attempted in specialised centres prior to considering surgical intervention. Therapeutic procedures such as dilatation of the stricture and haemostasis techniques are possible at RNY loop level with the availability of appropriate enteroscopic accessories recently and this could avoid the need for surgical intervention.

## REFERENCES

- Hartley JL, Davenport M, Kelly DA. Biliary atresia. *Lancet* 2009; **374**: 1704-1713
- Davenport M. Biliary atresia. *Semin Pediatr Surg* 2005; **14**: 42-48
- Moreels TG, Hubens GJ, Ysebaert DK, Op de Beeck B, Pelckmans PA. Diagnostic and therapeutic double-balloon enteroscopy after small bowel Roux-en-Y reconstructive surgery. *Digestion* 2009; **80**: 141-147
- Barth BA, Channabasappa N. Single-balloon enteroscopy in children: initial experience at a pediatric center. *J Pediatr Gastroenterol Nutr* 2010; **51**: 680-684
- Nishimura N, Yamamoto H, Yano T, Hayashi Y, Arashiro M, Miyata T, Sunada K, Sugano K. Safety and efficacy of double-balloon enteroscopy in pediatric patients. *Gastrointest Endosc* 2010; **71**: 287-294
- Yamamoto H, Kita H, Sunada K, Hayashi Y, Sato H, Yano T, Iwamoto M, Sekine Y, Miyata T, Kuno A, Ajibe H, Ido K, Sugano K. Clinical outcomes of double-balloon endoscopy for the diagnosis and treatment of small-intestinal diseases. *Clin Gastroenterol Hepatol* 2004; **2**: 1010-1016
- Thomson M, Venkatesh K, Elmalik K, van der Veer W, Jacobs M. Double balloon enteroscopy in children: diagnosis, treatment, and safety. *World J Gastroenterol* 2010; **16**: 56-62
- Hadzic N, Davenport M, Tizzard S, Singer J, Howard ER, Mieli-Vergani G. Long-term survival following Kasai portoenterostomy: is chronic liver disease inevitable? *J Pediatr Gastroenterol Nutr* 2003; **37**: 430-433
- Houben C, Phelan S, Davenport M. Late-presenting cholan-

- gitis and Roux loop obstruction after Kasai portoenterostomy for biliary atresia. *J Pediatr Surg* 2006; **41**: 1159-1164
- 10 Emmett DS, Mallat DB. Double-balloon ERCP in patients who have undergone Roux-en-Y surgery: a case series. *Gastrointest Endosc* 2007; **66**: 1038-1041
  - 11 Mönkemüller K, Fry LC, Bellutti M, Neumann H, Malfertheiner P. ERCP using single-balloon instead of double-balloon enteroscopy in patients with Roux-en-Y anastomosis. *Endoscopy* 2008; **40** Suppl 2: E19-E20
  - 12 Dellon ES, Kohn GP, Morgan DR, Grimm IS. Endoscopic retrograde cholangiopancreatography with single-balloon enteroscopy is feasible in patients with a prior Roux-en-Y anastomosis. *Dig Dis Sci* 2009; **54**: 1798-1803
  - 13 Koornstra JJ. Double balloon enteroscopy for endoscopic retrograde cholangiopancreatography after Roux-en-Y reconstruction: case series and review of the literature. *Neth J Med* 2008; **66**: 275-279
  - 14 Mensink PB, Haringsma J, Kucharzik T, Cellier C, Pérez-Cuadrado E, Mönkemüller K, Gasbarrini A, Kaffes AJ, Nakamura K, Yen HH, Yamamoto H. Complications of double balloon enteroscopy: a multicenter survey. *Endoscopy* 2007; **39**: 613-615
  - 15 Aktas H, de Ridder L, Haringsma J, Kuipers EJ, Mensink PB. Complications of single-balloon enteroscopy: a prospective evaluation of 166 procedures. *Endoscopy* 2010; **42**: 365-368

**Peer reviewers:** Natthawut Kaewpitoon, PhD, Assistant Professor, Head of Parasitic Disease Research Center, Institute of Medicine, Suranaree University of Technology, Nakhon Ratchasima, Thailand; Hamdy Sliem, professor of internal medicine, faculty of medicine, Suez canal university, Ismailia, Egypt.