

Adjusted Multidisciplinary Treatment Against Multiple Colorectal Liver Metastasis May Expand Indication of Intensive Treatment to Previously Excluded Elderly Patients

Takahisa Fujikawa, Akira Tanaka

Takahisa Fujikawa, Akira Tanaka, Department of Surgery, Kokura Memorial Hospital, Kitakyushu, Fukuoka, Japan

Correspondence to: Takahisa Fujikawa, MD, PhD, FACS, Department of Surgery, 3-2-1 Asano, Kokurakita-ku, Kitakyushu, Fukuoka 802-8555, Japan.

Email: fujikawa-t@kokurakinen.or.jp

Telephone: +81-93-511-2000

Fax: +81-93-511-3240

Received: December 3, 2015

Revised: January 8, 2016

Accepted: January 11, 2016

Published online: January 19, 2016

ABSTRACT

Recent development of various less invasive therapeutic approach against advanced colorectal carcinoma (CRC), including laparoscopic operative procedures, radiofrequency ablation, and modified chemotherapy regimen not only improve the patients' quality of life and survival, but also expand indication of intensive treatment to previously excluded elderly patients with reduced performance status. We experienced a case of an elderly woman with reduced performance status due to decreased physical activity, who received dose/interval-adjusted chemotherapy for multiple bilobar liver metastases from CRC and subsequently underwent curative laparoscopic limited liver resection and radiofrequency ablation. We focused on the feasibility of an adjusted multidisciplinary approach to multiple CRC liver metastases in patients with reduced performance status like the present case.

© 2016 ACT. All rights reserved.

Key Words: Colorectal liver metastasis; Elderly patient; Laparoscopic liver resection; Radiofrequency ablation

Fujikawa T, Tanaka A. Adjusted Multidisciplinary Treatment Against Multiple Colorectal Liver Metastasis May Expand Indication of

Intensive Treatment to Previously Excluded Elderly Patients. *Journal of Gastroenterology and Hepatology Research* 2016; 5(1): 1944-1946 Available from: URL: <http://www.ghrnet.org/index.php/joghr/article/view/1467>

LETTER TO THE EDITOR

Colorectal carcinoma (CRC) is one of the most common causes of cancer-related mortalities, and liver metastases comprise the most frequently encountered distant metastases, which generally occur synchronously and metachronously with the rate of 10% and 15%, respectively. Liver resection for liver metastases from CRC is considered to be the standard of care and the only potentially curative therapy. Although the prognosis clearly improves as a result of liver resection, surgery is indicated in only around 20-40% of patients with colorectal liver metastases^[1,2]. However, recent reports demonstrated that various procedures aimed at improving the rate of surgical resection, including preoperative portal embolization, two-stage liver resection, and resection following chemotherapy^[3,4]. Especially, the role of systemic preoperative chemotherapy has been gradually recognized, and standard chemotherapy regimens such as FOLFOX or FOLFIRI in combination with molecular targeted drugs have been reported to facilitate a resection rate of up to 40% among patients with initially unresectable liver metastases^[4]. These multidisciplinary approaches may give us a chance to not only improve patients' long-term quality of life, but also expand indication of intensive treatment to previously excluded elderly patients.

On the other hand, with the advent of minimally invasive surgery and its expected benefits, many surgical procedures are now being performed or attempted laparoscopically. Laparoscopic advantages over open liver resection include reduced postoperative pain, less operative morbidity, shorter hospital stay, and faster recovery period^[5]. Recent advances in surgical technique and laparoscopic devices allowed us to expand indication of laparoscopic liver resection (LLR) to malignant lesions, with acceptable short-term and long-

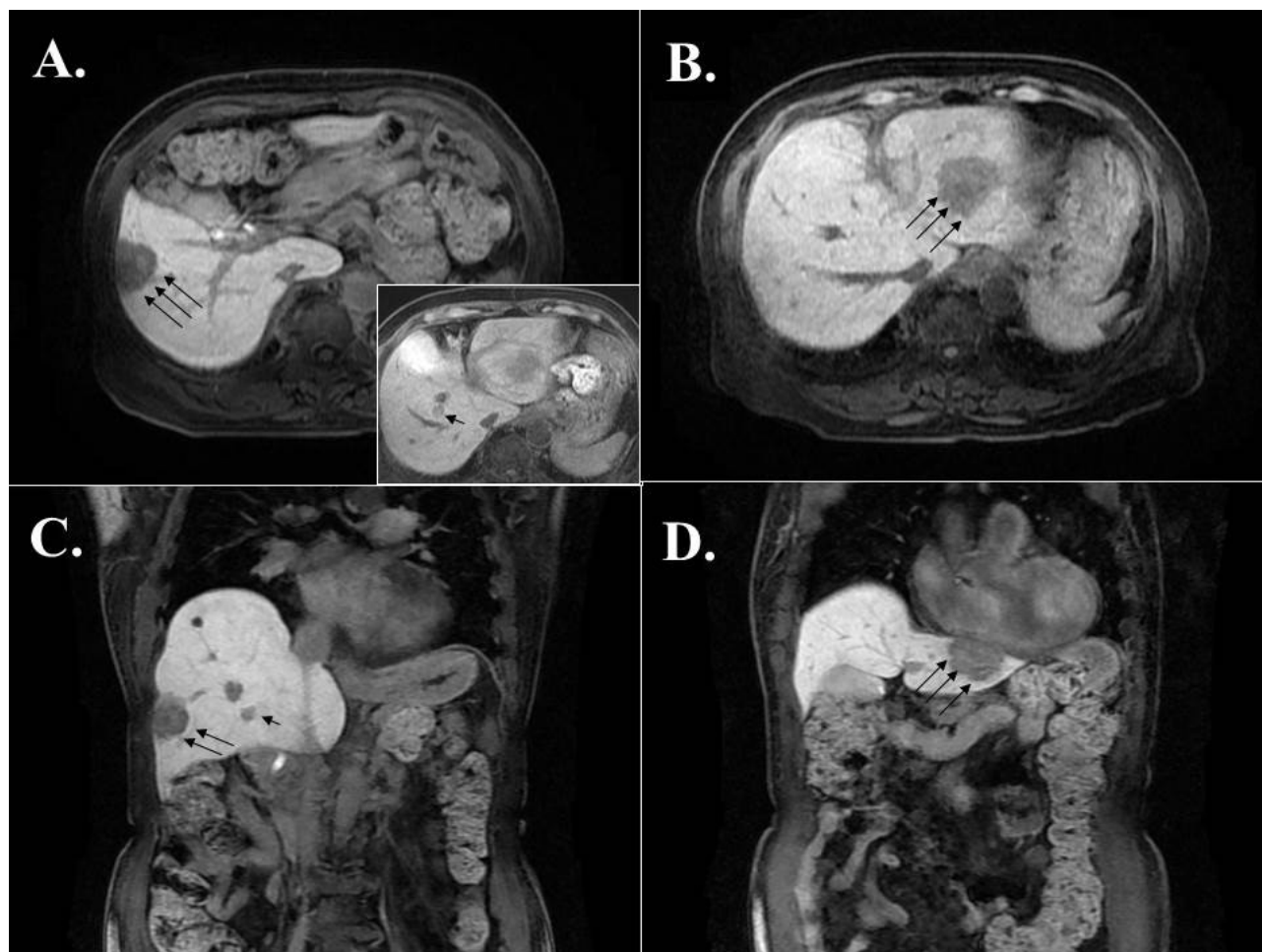


Figure 1 Magnetic resonance images demonstrated multiple bilobar liver masses indicating multiple liver metastases from colon cancer. (A, C) A 3.5cm-sized mass in S6 (long arrows) and a 1.5cm-sized mass in S5 (a short arrow) were shown. (B, D) A large 4.5cm-sized mass in the left lobe was shown (arrows). A,B: axial images, C,D: coronal images.

term results^[5]. Additionally, radiofrequency ablation (RFA) is recently available and offers a novel modality to deal with lesions that otherwise would be left behind by resection only^[6]. Although long-term disease-free survival of patients with multiple colorectal liver metastases after combination of RFA and liver resection has not been well documented, it is presumably beneficial that ablating identifiable lesions which are difficult to resect due to patients' condition or background liver status increases the chance of curative management even in an elderly patient with poor performance status.

Herein we describe a case of elderly woman with reduced performance status, undergoing curative LLR combined with neoadjuvant chemotherapy and RFA for multiple bilobar liver metastases from CRC, and achieving long-term cancer-free survival. A 77-year-old Japanese woman with reduced performance status due to decreased physical activity was diagnosed with advanced colon cancer and concomitant multiple liver metastases (Figure 1). Due to impending obstruction of the colon, sigmoidectomy with regional lymph node dissection was performed first and the patient recovered soon postoperatively. Because of the patient's strong wish in spite of high age and reduced performance status, it was decided to introduce chemotherapy with modified dose and interval. Chemotherapy regimen consisted of 70-80% dose of FOLFOX in every 3 weeks, in combination with 80% dose of bevacizumab. After 7 cycles were carried out without any significant adverse drug events, the patient's physical activity improved thanks to rigorous nutritional support and

intensive rehabilitation. The tumor response was assessed as partial response at that time and the patient decided to undergo curative-intent therapy. RFA was first applied to the small S5 tumour in order to conserve liver parenchyme (other two lesions were excluded due to its location adjacent to surface), and the patient subsequently underwent successful laparoscopic limited liver resection (LLR) to the residual lesions. The patient recovered soon postoperatively with minimal pain, and remained asymptomatic and free of any signs of recurrence for 64 months since her initial operation. The current case highlights combination of LLR and RFA after adjusted chemotherapy as one of the promising options to not only improve patients' long-term survival, but also expand indication of intensive treatment to previously excluded patients with reduced performance status.

CONFLICT OF INTERESTS

The authors declare that they do not have conflict of interests.

REFERENCES

- 1 Sugihara K, Uetake H. Therapeutic strategies for hepatic metastasis of colorectal cancer: overview. *J Hepatobiliary Pancreat Sci* 2012; **19**: 523-7.
- 2 Wang CC, Li J. An update on chemotherapy of colorectal liver metastases. *World J Gastroenterol* 2012; **18**: 25-33.
- 3 Adam R, Delvart V, Pascal G, Valeanu A, Castaing D, Azoulay D,

- Giacchetti S, Paule B, Kunstlinger F, Ghémard O, Levi F, Bismuth H. Rescue surgery for unresectable colorectal liver metastases downstaged by chemotherapy: a model to predict long-term survival. *Ann Surg* 2004; **240**: 644-57.
4. Nordlinger B, Sorbye H, Glimelius B, Poston GJ, Schlag PM, Rougier P, Bechstein WO, Primrose JN, Walpole ET, Finch-Jones M, Jaeck D, Mirza D, Parks RW, Mauer M, Tanis E, Van Cutsem E, Scheithauer W, Gruenberger T. Perioperative chemotherapy with FOLFOX4 and surgery versus surgery alone for resectable liver metastases from colorectal cancer (EORTC Intergroup trial 40983): a randomised controlled trial. *Lancet* 2008; **371**: 1007-16.
 5. Nguyen KT, Laurent A, Dagher I, Geller DA, Steel J, Thomas MT, Marvin M, Ravindra KV, Mejia A, Lainas P, Franco D, Cherqui D, Buell JF, Gamblin TC. Minimally invasive liver resection for metastatic colorectal cancer: a multi-institutional, international report of safety, feasibility, and early outcomes. *Ann Surg* 2009; **250**: 842-8.
 6. Abdalla EK, Vauthey JN, Ellis LM, Ellis V, Pollock R, Broglio KR, Hess K, Curley SA. Recurrence and outcomes following hepatic resection, radiofrequency ablation, and combined resection/ablation for colorectal liver metastases. *Ann Surg* 2004; **239**: 818-25.

Peer reviewer: Alejandro Serrablo MD PhD, Associate Professor of Surgery, Hepatopancreatic biliary Surgical Unit, Miguel Servet University Hospital, Zaragoza 50009, Spain.