

Jejunojejunal Adult Intussusception Presented with Rectal Bleeding

Iakovos Avramidis, Georgios Nalmpantidis, Nikolaos Giatas, Nikolaos Daleras, Ioanna Tsantila, Christina Nikolaidou, Stavros Giantikidis, Diamantis Zisis

Iakovos Avramidis, Endoscopy and Gastroenterology unit, Internal Medicine Clinic, general hospital of Katerini, Katerini, Greece

Georgios Nalmpantidis, Gastroenterology Clinic, "Georgios Papanikolaou" general hospital, Thessaloniki, Greece

Nikolaos Giatas, Department of General Surgery, general hospital of Katerini, Katerini, Greece

Nikolaos Daleras, Department of Radiology, general hospital of Katerini, Katerini, Greece

Ioanna Tsantila, Christina Nikolaidou, Department of Pathology, "Hippokratio" general hospital, Thessaloniki, Greece

Stavros Giantikidis, Diamantis Zisis, Internal Medicine Clinic, general hospital of Katerini, Katerini, Greece

Correspondence to: Georgios Nalmpantidis, MD, 24 Fanariou Street, Kalamaria, Thessaloniki, 55 133, Greece. geonalba@yahoo.gr
Telephone: +30-2310-444-693 Fax: +30-2310-359-217

Received: March 18, 2012 Revised: April 28, 2012

Accepted: May 6, 2012

Published online: August 21, 2012

ABSTRACT

Jejunojejunal adult intussusception is a rare disease. Secondary small intestine intussusception is even rarer and may result from intraluminal or extraluminal lesions. Adenocarcinoma may be found in up to 30% of small-intestine intussusception cases. We present a case of a 65 year old woman, who presented in the accident and emergency department of a rural hospital with lower gastrointestinal bleeding and abdominal pain. The patient underwent emergent gastroenterology and surgical consultation, imaging studies, urgent surgical therapy. Diagnosis of small-bowel adenocarcinoma was made on the basis of histologic examination. The patient had no risk factors for small-bowel adenocarcinoma. She did not receive chemotherapy after surgical therapy. She has been on a regular follow-up, without evidence of locoregional relapse or metastases. The probability for a given adult in Greece to present with rectal bleeding because of small bowel intussusception is estimated to be 1 to 2 cases annually in a 10 000 000 population. The probability that the cause of intussusception is primary adenocarcinoma is even smaller. The disease has no specific symptoms or signs. High degree of clinical suspicion is needed in order a diagnosis will not

be missed.

© 2012 Thomson research. All rights reserved.

Key words: Jejunal adenocarcinoma; Lower gastrointestinal bleeding; Surgical therapy

Avramidis I, Nalmpantidis G, Giatas N, Daleras N, Tsantila I, Nikolaidou C, Giantikidis S, Zisis D. Jejunojejunal Adult Intussusception Presented with Rectal Bleeding. *Journal of Gastroenterology and Hepatology Research* 2012; 1(7): 134-138 Available from: URL: <http://www.ghrnet.org/index./joghr/>

INTRODUCTION

Intussusception occurs when one segment of the small intestine, constricted by a wave of peristalsis, becomes telescoped into the immediately distal segment of bowel. Once trapped, the invaginated segment is propelled by peristalsis farther, into the distal segment, pulling its mesentery along behind it. Trapping of mesentery vessels leads to infarction^[1]. In contrast to childhood intussusception, the adult type of the disease represents a rare cause of intestinal obstruction and is attributed to various pathologic lesions. Cross-sectional studies have estimated the annual incidence of the disease to be 2-3 cases/10⁶ population (accounts for <0.1% of hospital admissions)^[2]. Adult intussusception (AI) accounts for 5% of all intussusception cases and 1 to 5% for all adult intestinal obstructions^[3]. In a 17-year period, 10 adults with intussusception were recorded in three hospitals in Switzerland^[4]. Primary (idiopathic) bowel intussusception accounts for up to 20% of all cases and is more frequent in small intestine. Secondary small intestine intussusception may result from intraluminal or extraluminal lesions. Adenocarcinoma may be found in up to 30% of small intestine intussusception cases^[5]. In a recently published case-report from Nigeria, a 31-year old man presented with symptoms and signs of intestinal obstruction. The diagnosis of intussusception and volvulus secondary to jejunal adenocarcinoma was made. However, there is a paucity of reports of intussusception with jejunal adenocarcinoma as the lead point in the literature^[6].

CASE REPORT

We present a 65 year old woman, who was admitted to a rural

general hospital because of acute lower gastrointestinal bleeding (hematochezia) and lower left quadrant abdominal pain. The patient first noticed symptoms 24 h ago. One year before the admission, she underwent screening colonoscopy and diverticular disease of the sigmoid colon was diagnosed. Her past medical history included arterial hypertension (she had been receiving ramipril 5 mg plus hydrochlorothiazide 25 mg/d and atenolol 50 mg/d). The patient had no history of Crohn's disease, Peutz-Jeghers syndrome, familial adenomatous polyposis or colorectal cancer. Moreover, she had no first or second-degree relatives with the aforementioned diseases and was neither smoker nor alcohol abuser.

On physical examination, the patient appeared tired. Vital signs were within normal range, except arterial pressure, which was 150/70 mmHg. The oxygen saturation was 97% while the patient was breathing ambient air. The abdomen was soft, moderate distended, with mild tenderness in left lower quadrant and epigastrium on deep palpation. The digital rectal examination revealed normal sphincter tone and fresh blood. The remainder of the examination was normal.

Initial laboratory studies of the patient are presented in table 1. Chest and abdomen X-rays showed no abnormal signs. The patient underwent abdominal ultrasound (Figure 1) and CT studies with contrast material (Figure 2). Ultrasound study revealed one edematous enteric mass with intussusception characteristics in the left lower quadrant of the abdomen, whereas CT study showed jejunojejunal intussusception and mild distension of the duodenum.

Table 1 Laboratory studies of the patient.

Parameter	On admission	Day 1	Normal range
White blood count/ μ L	11 280	8 100	4.9-10.8
Granulocytes (%)	88.6	89.3	40-75
Lymphocytes (%)	1.8	5.5	20-40
Haematocrit (%)	38.8	36.3	37.7-47.9
Hemoglobin (g/dL)	13.0	12.0	11.8-17.8
Platelet count/ μ L	239 000	270 000	150-350
AST (IU/L)	36	21	5-35
ALT (IU/L)	14	12	5-40
Urea (mg/dL)	26	19	15-45
Creatinine (mg/dL)	0.9	0.8	0.66-1.10
Na ⁺ (mEq/L)	140	141	135-150
K ⁺ (mEq/L)	4.2	3.0	3.50-5.50
Serum Amylase (U/L)	77	50	22-80
LD (U/L)	394	193	120-248
CK (U/L)	102	54	24-145
Total bilirubin (mg/dL)	0.30	0.60	0.30-1.20
Direct bilirubin (mg/dL)	0.06		0.00-0.20
ESR		17	
C-reaction protein (mg/dL)		1.25	0.00-0.70
Alkaline Phosphatase (U/L)		40	30-120
GGT (U/L)		9	10-40
Serum Glucose (mg/dL) ¹	164		70-110
Total Protein levels (g/L)		6.4	6.0-8.4
INR		1.1	0.850-1.150
aPTT (sec)		27.1	25.0-35.0

AST: Aspartate aminotransferase, ALT: Alanine aminotransferase, LDH: Lactate dehydrogenase, CK: Creatinine kinase, INR: International Normalized ratio, aPTT: activated Part thromboplastin time, ESR: Erythrocyte sedimentation rate in 1 h; GGT: gamma-Glutamyl-transferase; ¹Two h after meal.

Surgical consultation took place in the same hospital. Urgent surgical excision of 10.5 cm of the jejunum (10 cm beyond the ligament of Treitz) and end-lateral jejunojejunal anastomosis were undertaken. A mass of 3.5×2.5×1.0 cm was identified within the removed part of the small intestine. Pathologic diagnosis of small bowel adenocarcinoma (moderate differentiated) was made (Figure 3). The adenocarcinoma cells infiltrated the submucosa and the inner half of the muscular layer of the small intestine. No lymph nodes were

identified within the removed part of mesentery fatty tissue. No other primary or secondary neoplasms were identified (T2NxM0). The patient had a smooth recovery and she was referred to a tertiary oncology center for further evaluation and follow-up. She did not receive chemotherapy and since then she has been on a regular follow-up, without evidence of locoregional relapse or metastases.

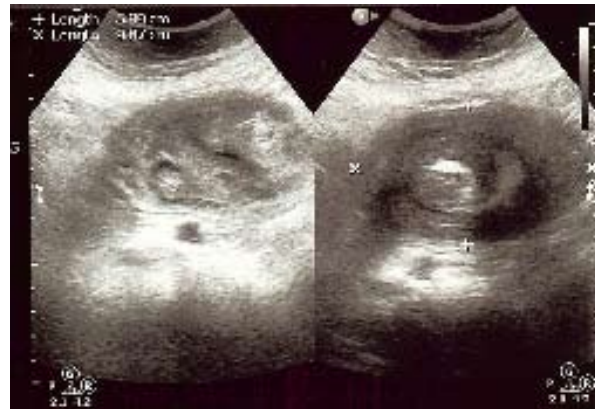

Figure 1 Transabdominal ultrasound study of the patient.

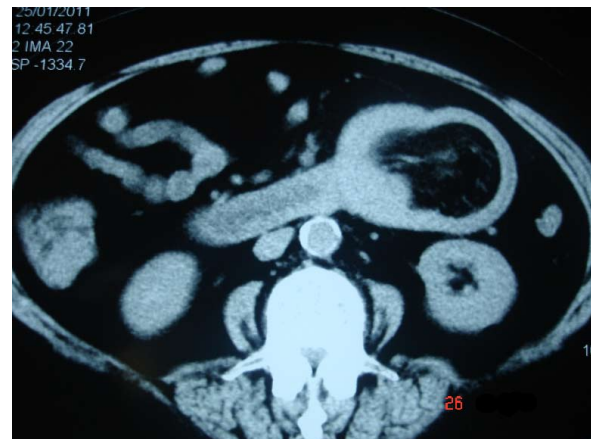

Figure 2 Computerised tomography study of the patient's abdomen. Thickening of the small bowel wall, with narrowing and polypoid mass (intussusception).

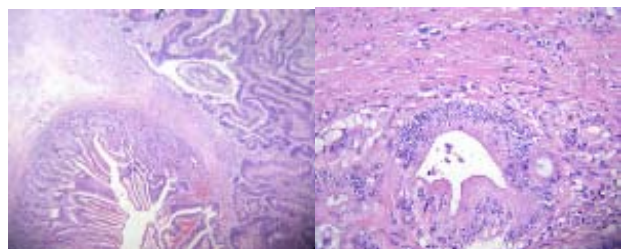


Figure 3 Histologic characteristics of the removed small intestine tumor. A. Small intestine normal mucosa (left) and adjacent invasive, adenocarcinoma (right) (HE×50). B. Invasive adenocarcinoma. Detail of the tumor (HE×400).

DISCUSSION

Cases of intussusception have been reported in adults, since the first report of by Barbette of Amsterdam in 1674, the first detailed presentation by John Hunter in 1789 and the first surgical therapy of a child in 1871 by Sir Jonathan Hutchinson^[5].

In a recent, multicenter, retrospective study, over a 17 year-period in Switzerland, 6 cases out of 10 with AI were malignant and no one was small-bowel adenocarcinoma^[4]. In another retrospective study of 20 adult patients from Turkey (over a 8-year period) 5 cases of jejunojejunal intussusception were identified, most of them due to Peutz-Jeghers hamartomatous polyps and none of them due to jejunal adenocarcinoma. In the same case-series study, rectal bleeding was reported in 1 patient (5%) and acute symptoms (<4 d) in 6 patients (30%)^[7]. A recently published study from South India reviewed the records of all adult patients who were admitted to a tertiary referral hospital from 2004 to 2010. A total of 15 patients with intussusception were identified. Pain, nausea and vomiting were the most frequent symptoms, whereas the least frequent (15%) was bleeding per rectum. The mean age at diagnosis was 44.5 years. Jejuno-jejunal intussusception was diagnosed in 3 cases. Of interest, jejunal adenocarcinoma was not diagnosed in any of the 3 patients^[8]. In 2 case reports from Italy and the Netherlands, patients with intussusception due to small bowel adenocarcinoma were anemic and the presenting symptoms and signs were those of small bowel obstruction. None of them had lower gastrointestinal bleeding^[9,10].

The patient in our case-report firstly presented with acute symptoms of lower gastrointestinal bleeding and finally a diagnosis of jejunal adenocarcinoma was made. It should be mentioned that the patient had no risk factors for the disease. The patient did not undergo endoscopy because a preoperative diagnosis of small bowel intussusception was made (a disease frequently related to malignant lesions). Supposing that data from Greek population do not significantly differ from that of other European countries, the probability for a randomly chosen adult from Greek general population to suffer from small bowel intussusception is similar to the frequency of the disease in this population (2-3 per 1 000 000)². The probability for an adult patient with small bowel intussusception to present with symptoms of lower gastrointestinal bleeding is similar to the frequency of the symptom in the small-bowel-intussusception population (that is 5×10^{-2})⁷. Thus, the overall estimated probability for a randomly chosen adult from Greek general population to present with symptoms of lower gastrointestinal bleeding due to small bowel intussusception is $(2-3 \times 10^{-6}) \times (5 \times 10^{-2}) = 1$ to 2 cases annually in a 10 000 000 population. The probability that the cause is primary adenocarcinoma is even smaller.

Despite its length and large mucosal surface, the small intestine is rarely the origin of primary adenocarcinoma. Many theories have been proposed to explain the low frequency of small bowel malignancies: the short contact time with carcinogens, reduced intestinal concentrations of inherited carcinogens, high concentrations of biliary-pancreatic secretions, low bacteria concentration and locally developed immune system^[11]. According to an analysis from the SEER (Surveillance, Epidemiology and End-Results) program, 4500 new cases of small bowel carcinoma were estimated to be diagnosed for the year 1998 in the US^[12] and 6100 new cases, with 1110 deaths secondary to small intestine carcinomas, in 2008^[13]. The new cases and deaths for the year 2010 were 6960 and 1100 respectively^[14]. Data from Europe and the GLOBOCAN 2008 study, did not include small bowel malignancies^[15,16]. In the period 1975-2000, the frequency rates increased by almost 50%^[17,18].

Small bowel cancer has 4 major histologic subtypes: adenocarcinoma is the most common (40-50%), followed by neuroendocrine tumors (20-40%, mainly ileum carcinoids), lymphomas (14%) and gastrointestinal stromal tumors (11-13%). Small bowel adenocarcinoma is twice as common in African Americans^[19]. In a retrospective US study, small intestine adenocarcinomas were found in the duodenum in 52% and in the jejunum in 25% of all cases^[20]. A recent multi-

center study from S. Korea showed that adenocarcinomas of the small intestine were primarily found in the duodenum (55%), following by jejunum (30%). The mean age at diagnosis in this study was 59 years and the male-to-female ratio 1.7:1.0. Lymph node metastasis and distal location (jejunum, ileum) of the primary tumor were the most important independent predictors for a worse prognosis^[21]. In another retrospective study from the Connecticut tumor registry (US) 1260 cases of small bowel tumors were identified from 1980 to 2000. Adenocarcinomas accounted for 27% of all cases and were more prevalent in duodenum. The mean age at diagnosis was 65.2 years^[22]. Certain risk factors for the disease have been identified and are presented in table 2.

Small intestine adenocarcinomas grow in a napkin ring encircling pattern or as polypoid fungating masses, in a manner similar to colonic cancers. Tumors in the duodenum, particularly involving the ampulla of Vater, may present with obstructive jaundice. As with adenomas, fatigue from occult blood loss may be the only sign. At the time of diagnosis, most tumors have already penetrated the bowel wall, invaded the mesentery or other segments of the gut, spread to regional nodes and sometimes metastasized to the liver and more widely^[1].

Table 2 Risk factors for small bowel adenocarcinoma.

Risk Factor	Comments
Sex	Men are slightly more affected ^[19,21] .
Race	African Americans have almost twice the incidence compared to Caucasians ^[19] .
Crohn's disease	Most of the carcinomas are found in the ileum ^[23] .
Celiac disease	Most of the carcinomas are located in the jejunum and develop more as an adenoma-carcinoma sequence than as dysplasia in flat mucosa ^[24] . The overall risk is still very low ^[25] .
Adenomas of the small intestine	Up to one third of all small intestine adenomas may have malignant features ^[26] .
Familial adenomatous polyposis syndrome (FAP)	Most of the carcinomas are found in the periampullary duodenum. Polyps in FAP may follow different genetic pathways from that of colorectal cancer. Bile may be synergistic with genetic mutations ^[27] .
Hereditary nonpolyposis colorectal cancer syndrome	Patients may have small bowel adenocarcinomas as the first tumor ^[28] .
Hamartomatous polyposis syndromes	Peutz-Jeghers syndrome and juvenile polyposis syndrome ^[27] .
Eponymous syndromes	Cronkhite-Canada syndrome ^[27,29] Cowden's syndrome, Devon family syndrome and Bannayan-Ruvalcaba-Riley syndrome ^[27] .
Diet and environmental factors	High intake of sugar, red meat, smoked foods and radiation therapies have been associated with increased risk for small bowel carcinomas ^[30] . The protective role of a diet high in fish, fruits and vegetables ^[30] has not been confirmed ^[31] . Alcohol and smoking have not been confirmed as risk factors ^[31] .

Radical surgical resection is the cornerstone therapy for locoregional disease. The extent of the resection and the optimal surgical technique are controversial^[32]. Laparoscopic techniques have been described for the surgical treatment of the disease^[33,34]. The role of adjuvant chemotherapy in small bowel adenocarcinomas is ambiguous. Chemotherapy regimens based on 5-fluorouracil may offer clinical benefit. However, there is lack of properly designed randomised clinical trials^[35]. A recent, phase II, trial assessed the efficacy and safety of biweekly oxaliplatin in combination with continuous infusional 5-fluorouracil and leucovorin (modified FOLFOX regimen) in 33 patients with advanced small bowel adenocarcinoma. Results of this study showed that a modified FOLFOX regimen had promising activity and was well tolerated, as first-line chemotherapy^[36]. Although randomized studies may never be conducted for this rare disease, this study supported that standard "colorectal" regimens may be used in small-bowel adenocarcinomas.

Chemotherapy with newer regimens may provide some benefit in metastatic disease. Therapies targeting the vascular endothelial growth factor receptor (VEGFR) or epidermal growth factor receptor (EGFR) have not been evaluated^[37]. Neoadjuvant chemoradiotherapy may also play a role, but it has been studied only in a small number of patients^[38]. Finally, the 5-year disease survival depends on the stage of the disease: in stage I is 65%, stage II 48%, stage III (node-positive disease) 35% and stage IV 4%^[39].

Better evidence from randomized clinical trials is needed in order the best available treatment strategy to be determined. However, the question of the cost and sponsorship of such trials remains. Some ideas for the sponsorship of rare-diseases trials have been recently published^[40].

CONCLUSIONS

The case-report patient had the unique combination of a rare disease and rare first clinical manifestation, without risk factors for small bowel adenocarcinoma. To our knowledge there have been no case-series of small bowel adenocarcinoma from Greece. The disease lacks specific symptoms and signs. High degree of clinical suspicion is needed in order a diagnosis not to be missed.

REFERENCES

- Crawford JM. The Gastrointestinal Tract. In Cotran RS, Kumar V, Collins T (eds). Robbins Pathological Basis Of Disease, 6th edition. Philadelphia: WB Saunders 1999; 826-827
- Carter C, Morton AL. Adult intussusception in Glasgow, UK. *Br J Surg* 1989; **76**: 727
- Azar T, Berger DL. Adult intussusception. *Ann Surg* 1997; **226**: 134-138
- Toso C, Erne M, Lenzlinger PM, Schmid JF, Büchel H, Melcher G, Morel P. Intussusception as a cause of bowel obstruction in adults. *Swiss Med Wkly* 2005; **135**: 87-90
- Marinis A, Yiallourou A, Samanides L, Dafnios N, Anastasopoulos G, Vassiliou I, Theodosopoulos T. Intussusception of the bowel in adults: A review. *World J Gastroenterol* 2009; **15**: 407-411
- Okolo CA, Afolabi AO, Sahabi SM. Intussusception and volvulus secondary to jejunal adenocarcinoma in an adult Nigerian male: a case report. *Nigerian Journal of Clinical Practice* 2010; **13**: 470-472
- Yakan S, Caliskan C, Makay O, Denecli AG, Korkut MA. Intussusception in adults: Clinical characteristics, diagnosis and operative strategy. *World J Gastroenterol* 2009; **15**: 1985-1989
- Sarma D, Prabhu R, Rodrigues G. Adult intussusception: a six-year experience at a single center. *Annals of Gastroenterology* 2012; **25**: 128-132
- Caruso S, Marrelli D, Pedrazzani C, Neri A, Mazzei MA, Onorati M, Corso G, Cerullo G, Roviello F. A rare case of primary small bowel adenocarcinoma with intussusception. *Tumori* 2010; **96**: 355-357
- Andriessen MJG, Govaert MJPM, de Waard JWD. Jejunojejunal intussusception by a known jejunal adenocarcinoma. *Can J Surg* 2008; **E83-E84**
- Neugut AL, Jacobson JS, Suh S, Mukherjee R, Arber N. The epidemiology of cancer of the small bowel. *Cancer Epidemiol Biomarkers Prev* 1998; **7**: 243-251
- Landis SH, Murray T, Bolden S, Wingo PA. Cancer statistics 1999; *CA Cancer J Clin* 1999; **49**: 8-31
- Jemal A, Siegel R, Ward E, Hao Y, Xu J, Murray T, Thun MJ. Cancer statistics, 2008. *CA Cancer J Clin* 2008; **58**: 71-96
- Jemal A, Siegel R, Xu J, Ward E. Cancer Statistics, 2010. *CA Cancer J Clin* 2010; **60**: 277-300
- Ferlay J, Parkin DM, Steliarova-Foucher E. Estimates of cancer incidence and mortality in Europe in 2008. *Eur J Cancer* 2010; **46**: 765-781
- Ferlay J, Shin H-R, Bray F, Forman D, Mathers C, Parkin DM. Estimates of worldwide burden of cancer In 2008: GLOBOCAN 2008. *Int J Cancer* 2010; **127**: 2893-2917
- Chow JS, Chem OC, Ahsan H, Neugut AI. A population-based study of the incidence of malignant small bowel tumors: SEER, 1973-1990. *Int J Epidemiol* 1996; **25**: 722-728
- Schottenfeld D, Beebe-Dimmer JL, Vigneau F. The Epidemiology and Pathogenesis of Neoplasia in the Small Intestine. *Ann Epidemiol* 2009; **19**: 58-69
- Arber N, Moshkowitz M. Small Bowel Tumors. In Talley NJ, Kane SV, Wallace MB (eds). Practical Gastroenterology and Hepatology. Small and Large Intestine and Pancreas. Oxford: Wiley-Blackwell 2010; 237-238
- Dabaja BS, Suki D, Pro B, Bonnen M, Ajani J. Adenocarcinoma of the Small Bowel - Presentation, Prognostic Factors and Outcome of 217 Patients. *Cancer* 2004; **101**: 518-526
- Chang H-K, Yu E, Kim J, Bae YK, Jang K-T, Jung ES, Yoon GS, Kim JM, Oh YH, Bae HI, Kim GI, Jung SJ, Gu MJ, Kim JY, Jang KY, Jun SY, Eom DW, Kwon KW, Kang GH, Park JB, Hong S, Lee JS, Park JY, Hong SM; Korean Small Intestinal Cancer Study Group. Adenocarcinoma of the small intestine: a multi-institutional study of 197 surgically resected cases. *Human Pathology* 2010; **41**: 1087-1096
- Hatzaras I, Palesty A, Abir F, Sullivan P, Kozol RA, Dudrick SJ, Longo WE. Small-bowel tumors. Epidemiologic and Clinical Characteristics of 1260 Cases From the Connecticut Tumor Registry. *Arch Surg* 2007; **142**: 229-235
- Michellasi F, Testa G, Pomidor WJ, Lashner BJ, Block GE. Adenocarcinoma complicating Crohn's disease. *Dis Colon Rectum* 1993; **36**: 654-661
- Green PH, Rampertab SD. Small bowel carcinoma and celiac disease. *Gut* 2004; **53**: 774
- Green PHR, Cellier C. Celiac Disease. *N Engl J Med* 2007; **357**: 1731-1743
- Rose DM, Hochwald SN, Klimstra DS, Brennan MF. Primary duodenal adenocarcinoma: a ten-year experience with 79 patients. *J Am Coll Surg* 1996; **182**: 89-96
- Ludwig E, Kurtz RC. Tumors of the Small Intestine. In Feldman M, Friedman LS, Brandt LJ (eds). Sleisenger and Fordtran's Gastrointestinal and Liver Disease. 9th edition. Pathophysiology/Diagnosis/Management. Philadelphia: Saunders Elsevier 2010; 2145-2153
- Park JG, Kim DW, Hong CW, Nam BH, Shin YK, Hong SH, Kim IJ, Lim SB, Aronson M, Bisgaard ML, Brown GJ, Burn J, Chow E, Conrad P, Douglas F, Dunlop M, Ford J, Greenblatt MS, Heikki J, Heinimann K, Lynch EL, Macrae F, McKinnon WC, Möeslein G, Rossi BM, Rozen P, Schofield L, Vaccaro C, Vasen H, Velthuisen M, Viel A, Wijnen J; International Society for Gastrointestinal Hereditary Tumours. Germ line mutations of mismatch repair genes in hereditary nonpolyposis colorectal patients with small bowel cancer: International Society for Gastrointestinal Hereditary Tumours Collaborative Study. *Clin Cancer Res* 2006; **12**: 3389-3393
- Goo YS, Lee YC, Shin MS, Kim WH, Kim H, Park IS. A case of Cronkhite-Canada syndrome involving the entire gastrointestinal tract. *Endoscopy* 2001; **33**: 385
- Negri E, Bosetti C, La Vecchia C, Fioretti F, Conti E, Franceschi S. Risk factors for adenocarcinoma of the small intestine. *Int J Cancer* 1999; **82**: 171-174
- Chow WH, Linet MS, McLaughlin JK, Hsing AW, Chien HT, Blot WJ. Risk factors for small intestine cancer. *Cancer Causes Control* 1993; **4**: 163-169
- Begos DG, Sandor A, Modlin IM. The diagnosis and management of adult intussusception. *Am J Surg* 1997; **173**: 88-94
- McKay R. Ileocecal intussusception in an adult: the laparoscopic approach. *JSLs* 2006; **10**: 250-253
- Renzulli P, Candinas D. Idiopathic small-bowel intussus-

- ception in an adult. *CMAJ* 2010; **182**: E148
- 35 Singhal N, Singhal D. Adjuvant chemotherapy for small intestine adenocarcinoma. *Cochrane Database of Systematic Reviews* 2007; **3**: CD005202
- 36 Xiang XJ, Liu YW, Zhang L, Qiu F, Yu F, Zhan ZY, Feng M, Yan J, Zhao JG, Xiong JP. A phase II study of modified FOLFOX as first-line chemotherapy in advanced small bowel adenocarcinoma. *Anticancer Drugs* 2012; **23**: 561-566
- 37 Speranza G, Doroshov GH, Kummar S. Adenocarcinoma of the small bowel: changes in the landscape? *Curr Opin Oncol* 2010; **22**: 387-393
- 38 Kelsey CR, Nelson JW, Willett CG, Chino GP, Clough RW, Bendell JC, Tyler DS, Hurwitz HI, Morse MA, Clary BM, Pappas TN, Czito BG. Duodenal adenocarcinoma: Patterns of failure after resection and the role of chemoradiotherapy. *Int J Radiation Oncology Biol Phys* 2007; **69**: 1436-1441
- 39 Howe JR, Karnell LH, Menck HR, Scott-Conner C. The American College of Surgeons Commission on Cancer and the American Cancer Society Adenocarcinoma of the small bowel: review of the National Cancer Data Base, 1985-1995. *Cancer* 1999; **86**: 2693-2706
- 40 Ingelfinger JR, Drazen JM. Patient Organizations and Research on Rare Diseases. *N Engl J Med* 2011; **364**: 1670-1671
- Peer reviewer:** Lesley Ann Anderson, Centre for Public Health, Institute of Clinical Sciences, Block B, Grosvenor Road, Belfast, BT12 6BA, Northern Ireland.