

Clinical Course Following Partial External Biliary Diversion for Progressive Familial Intrahepatic Cholestasis 1: A Report of Two Patients

Akihiko Kimura, Daiki Abukawa, Takayuki Hoshina, Hajime Takei, Kenji Ihara, Tsuyoshi Murai, Tatsuki Mizuochi, Hiroshi Nittono

Akihiko Kimura, Department of Pediatrics and Child Health, Kurume University School of Medicine, 67 Asahi-machi, Kurume-shi, Fukuoka 830-0011, Japan

Daiki Abukawa, Department of General Pediatrics, Miyagi Children's Hospital, 4-3-17 Ochiai, Aoba-ku, Sendai-shi, Miyagi 989-3126, Japan

Takayuki Hoshina, Department of Pediatrics, University of Occupational and Environmental Health, 1-1 Iseigaoka, Yahatanishi-ku, Kitakyushu-shi, Fukuoka 807-8555, Japan

Hajime Takei, Junshin Clinic Bile Acid Institute, 2-1-22 Hara-machi, Meguro-ku, Tokyo 152-0011, Japan

Kenji Ihara, Department of Pediatrics, Oita University Faculty of Medicine Graduate School of Medicine, 1-1 Idaigaoka, Hazama-machi, Yufu-shi, Oita 879-5593, Japan

Tsuyoshi Murai, School of Pharmaceutical Science, Health Science University of Hokkaido, 1757 Kanazawa, Ishikari-Tobetsu, Hokkaido 061-0293, Japan

Tatsuki Mizuochi, Department of Pediatrics and Child Health, Kurume University School of Medicine, 67 Asahi-machi, Kurume-shi, Fukuoka 830-0011, Japan

Hiroshi Nittono, Junshin Clinic Bile Acid Institute, 2-1-22 Hara-machi, Meguro-ku, Tokyo 152-0011, Japan

Correspondence to: Akihiko Kimura, MD, PhD, Department of Pediatrics and Child Health, Kurume University School of Medicine, 67 Asahi-machi, Kurume-shi 830-0011, Japan

Email: ashikita-aki@water.ocn.ne.jp

Telephone: +81-942-31-7565

Fax: +81-942-38-1792

Received: November 28, 2015

Revised: January 15, 2016

Accepted: January 18, 2016

Published online: March 22, 2016

ABSTRACT

AIM: To better understand the effect of partial external biliary diversion (PEBD) in patients with progressive familial intrahepatic cholestasis 1 (PFIC1).

MATERIALS AND METHODS: We analyzed quantitative changes in the concentrations of individual bile acids in serum, urine, and biliary bile, and concomitant changes in symptoms such as pruritus, in 2 patients whose PFIC1 clinically evolved to resemble the course of benign recurrent intrahepatic cholestasis (BRIC) upon treatment with PEBD.

RESULTS: Patient 1 showed good therapeutic effect after PEBD including improved liver function test results and decreased total bile acids in serum, as well as decreased pruritus. The cholic acid (CA)/chenodeoxycholic acid (CDCA) ratio in biliary bile also decreased. Patient 2, however, experienced little decrease in pruritus after PEBD, and showed no clear change in the CA/CDCA ratio. Nonetheless, this patient's course did not rapidly worsen.

CONCLUSION: In PFIC1, increased bile secretion and a decreased CA/CDCA ratio in biliary bile may be the most important responses after PEBD. Relief of pruritus is also an important sign of therapeutic effect. Moreover, progression of symptoms in PFIC1 sometimes can be delayed by PEBD, resulting in a relatively mild BRIC-like course, even when the CA/CDCA ratio and pruritus show little change. However, mechanisms underlying clinical benefits remain obscure.

Abbreviations

PFIC1: progressive familial intrahepatic cholestasis 1;

GGT: γ -glutamyltransferase;

FIC1: familial intrahepatic cholestasis 1 gene;
 UDCA: ursodeoxycholic acid;
 PEBD: partial external biliary diversion;
 T Bil: total bilirubin;
 ALT: alanine aminotransferase;
 TBA: total bile acids;
 GC-MS: gas chromatography-mass spectrometry;
 Cr: creatinine;
 BRIC: benign recurrent intrahepatic cholestasis;
 CDCA: chenodeoxycholic acid;
 CA: cholic acid;
 HCA: hyocholic acid;
 BSEP: bile salt export pump.

© 2016 The Authors. Published by ACT Publishing Group Ltd.

Key Words: Progressive familial intrahepatic cholestasis 1; Partial external biliary diversion; Benign recurrent intrahepatic cholestasis; FIC1; ATP8B1

Kimura A, Abukawa D, Hoshina T, Takei H, Ihara K, Murai T, Mizuochi T, Nittono H. Clinical Course Following Partial External Biliary Diversion for Progressive Familial Intrahepatic Cholestasis 1: A Report of Two Patients. *Journal of Gastroenterology and Hepatology Research* 2016; 5(2): 1970-1976 Available from: URL: <http://www.ghrnet.org/index.php/joghr/article/view/1528>

INTRODUCTION

Progressive familial intrahepatic cholestasis 1 (PFIC1) is a liver disease characterized by progressive intrahepatic cholestasis, pruritus, diarrhea, failure to thrive, generally elevated serum concentrations of transaminases, low or normal serum concentrations of γ -glutamyltransferase (GGT), normal serum cholesterol concentrations, fat-soluble vitamin deficiencies, and the characteristic electron microscopic finding of Byler bile^[1-3]. PFIC1 shows autosomal recessive inheritance and is linked to chromosomal region 18q21-q22. The responsible gene, the familial intrahepatic cholestasis 1 gene (FIC1), is officially designated ATP8B1.

Although patients with PFIC1 may benefit from ursodeoxycholic acid (UDCA) therapy^[4], most patients require liver transplantation. However improvement may occur in patients with PFIC1 after partial external biliary diversion (PEBD), as first reported nearly 30 years ago in 1988^[5]. Recently, such surgery has shown promising relief of jaundice, pruritus, and failure to thrive, in some patients with PFIC1, and even has improved hepatic histopathologic findings^[3,6]. A success rate of 75% has been reported for patients who did not have cirrhosis at the time of surgery^[5].

Here we report our experience with PEBD in 2 children with PFIC1. We also describe bile acid profiles and clinical features before and during PEBD treatment in these 2 patients.

METHODS

Patients

Laboratory data, including total bilirubin (T Bil), alanine aminotransferase (ALT), and total bile acids (TBA) at the time of hospitalization, as well as the gene mutations identified in the patients, are shown in Table 1.

We previously have reported Patient 1^[7], a 7.8-year-old

Japanese girl who manifested mild direct hyperbilirubinemia (9.9 mg/dL) at the age of 2 months. At that time she showed a high serum concentration of TBA (133.9 μ mol/L), and normal serum concentrations of GGT (41 IU/L) and total cholesterol (191 mg/dL). Cholescintigraphy detected no technetium excretion 24 hr after intravenous injection, but laparoscopic cholangiography displayed no obstruction of common or intrahepatic bile ducts. She was given medium-chain triglyceride milk formula and was treated with UDCA and fat-soluble vitamin supplements. At 5 months, the biliary TBA content was extremely low (0.32 mmol/L). At 20 months she had intense pruritus and prominent developmental delay, showing particularly slow maturation of gait. At 28 months, her height was 72.5 cm (-4.40 SD) and her weight was 9400 g (-1.85 SD). She was found to be a compound heterozygote for mutations of ATP8B1 (Table 1), and thus was definitively diagnosed with PFIC1. At 3.5 years, she underwent PEBD. Pruritus resolved, height and weight improved, and manifestations of rickets abated. However, cholestasis recurred suddenly about 2 years after the operation. Cholestasis became less evident after 10 months, but a later recurrence persisted for 1 year (Figure 1; Supplemental Table 1).

Patient 2, a 3.5-year-old Japanese girl, had a normal gestation and delivery, and showed no clinical abnormalities at birth. However, elevation of serum thyroid-stimulating hormone was detected by neonatal metabolic screening using gas chromatography-mass spectrometry (GC-MS). She was diagnosed with hypothyroidism and treated with levothyroxine. At 2 months, persistent jaundice became evident (T Bil, 7.6 mg/dL; direct bilirubin, 5.4 mg/dL). A duodenal sonde examination performed to rule out biliary atresia detected bilirubin in the duodenal fluid. UDCA treatment was started, but jaundice did not improve. Serum aspartate aminotransferases and ALT as well as TBA were elevated, while GGT was normal (Figure 2, Supplemental Table 2). No amino acid abnormalities were detected. As we suspected PFIC1 or 2, the patient was admitted to Kyushu University Hospital at 4 months of age. On admission, she showed hepatomegaly (liver edge palpable 5 cm below the costal margin). Abrasions reflecting pruritus were evident, mainly over the head and limbs. No family history of liver disease was present. Accordingly, we diagnosed the patient with PFIC1 and carried out PEBD when she was 1.5 years old. Diagnosis was confirmed when genetic analysis identified compound heterozygous mutations of ATP8B1 (Table 1). ALT and T Bil roughly paralleled one another in fluctuations occurring over 3 years (Figure 2). Postoperative values were lower than those seen in patient 1, but some TBA in the bile was removed by the diversion. Urinary and serum TBA still have not decreased to the normal range (Supplemental Table 2).

Pruritus scale

Pruritus was semi quantitated according to a scale where 0 meant none; 1+, rubbing or mild scratching when undistracted; 2+, active scratching without evident skin abrasions; 3+, abrasions present; and 4+, cutaneous mutilation, hemorrhage, or scarring evident^[5].

Bile acid analysis

Serum, urine, and biliary samples were obtained from the patients with PFIC1 before and during PEBD treatment. Samples were stored at -25°C until analysis. Concentrations of individual bile acids in urine were corrected for creatinine concentration (Cr) in each subject, and are expressed as micromoles per millimole of Cr. The samples of human biologic fluids were prepared routinely for GC-MS analysis as described previously^[8].

Table 1 Laboratory data from patients with progressive familial intrahepatic cholestasis type 1.

Patient No.	Age†	Gender	T Bil† 0.2-1.0 (mg/dL)	ALT† 5-42 (U/L)	GGT† 5-72 (U/L)	TBA† <5 (μmol/L)	Age at PEBD	Mutation of ATP8B1
1	5 mo	F	13.7	48	24	131.8	3 yr 6 mo	c.1371del (p.Thr458Hisfs*7) c.2941G>A (p.Glu981Lys)
2	4 mo	F	17.7	64	17	190.3	1 yr 8 mo	c.2124_2125insGAGCTACAGCTATTGAAGGC (p.Ala703AlafsX46) c.1799G>A (p.Arg600Gln)‡

†, at admission; T Bil, total bilirubin; ALT, alanine aminotransferase; GGT, γ -glutamyltransferase; TBA, total bile acids; PEBD, partial external biliary diversion; fs, frameshift. ‡ This mutation has been reported in benign recurrent intrahepatic cholestasis 1^[24].

Table 2 TBA analyses of body fluids and pruritus scale ratings from 2 patients with PFIC1.

	Pre PEBD	At PEBD	2 wks	1 mo	2 mo	4 mo	6 mo	12 mo	18 mo	24 mo	36 mo	48 mo
Patient 1												
Biliary TBA (mmol/L)	0.3	63.2	1.5	13.4	26.5	35.0	57.5	39.3	n.d.	0.9	35.9	32.9
Serum TBA (μmol/L)	72.7	n.d.	22.8	2.4	0.0	0.0	0.0	0.6	n.d.	144.7	3.9	204.9
Urinary TBA (μmol/mmol Cr)	78.5	n.d.	73.7	4.4	0.8	1.4	0.9	0.3	n.d.	40.0	10.3	161.9
Pruritus scale	1+	4+	2+	1+	1+	0	0	0	3+	3+	0	2+
Patient 2												
Biliary TBA (mmol/L)	n.d.	18.9	0.7	2.1	2.8	1.9	1.6	3.1	7.8	0.1		
Serum TBA (μmol/L)	143.6	95.3	40.8	124.3	43.0	71.7	87.3	28.5	5.0	407.9		
Urinary TBA (μmol/mmol Cr)	130.0	n.d.	118.6	102.5	87.4	170.0	239.6	176.3	60.7	222.2		
Pruritus scale	4+	4+	3+	3+	3+	2+	2+	2+	2+	3+		

TBA, total bile acids; PFIC1, progressive familial intrahepatic cholestasis 1; PEBD, partial external biliary diversion; n.d., not done; Pruritus scale ratings^[5] are described in the Subjects and Methods section.

RESULTS

Changes in ALT, T Bil, and pruritus severity during the clinical course of our 2 patients with PFIC1 are shown in Figures 1 and 2. Additionally, changes in bile acids concentrations and pruritus severity at time points before and after PEBD are presented in Table 2. Decreases in pruritus severity were greater in patient 1, changing from 4+ to 0 after PEBD until 18 months postoperatively. Patient 2 showed less marked decreases in pruritus severity, changing only from 4+ to 3+ or 2+ after PEBD. The patients also differed in their clinical courses after PEBD. In patient 1, cholestasis worsened at 17 months postoperatively after initially showing prompt decrease. Subsequently, cholestasis has shown both decreases and exacerbations. In patient 2, much less early clinical improvement followed PEBD. Showing little correlation with clinical course, TBA patterns in these patients showed repeated improvement or worsening, as well as resemblances to the course of benign recurrent intrahepatic cholestasis (BRIC; Table 2 and Supplemental Tables 1 and 2).

Results of bile acid analysis in these patients appeared to show a therapeutic effect from increased bile flow after PEBD, with increases in biliary TBA and decreases in serum and urine TBA (Table 2; Supplemental Tables 1 and 2). Further, chenodeoxycholic acid (CDCA) increased among biliary bile acids while the cholic acid (CA)/CDCA ratio decreased in patient 1. In patient 2, no clear change in the CA/CDCA ratio was apparent after PEBD. When serum bile acids reflected cholestasis (elevated TBA in serum), serum hyocholic acid (HCA) was increased (Supplemental Tables 1 and 2). When TBA were elevated in urine, both urine and serum HCA increased. In addition, in the presence of cholestasis, percentages of 1 β -hydroxylated bile acids and ketonic bile acids among TBA rose in the urine (Supplemental Tables 1 and 2).

Laboratory values such as ALT, T Bil, and TBA did not necessarily change in parallel (Table 2; Figures 1 and 2).

DISCUSSION

Previous reports^[3,5,7,9-13] have noted therapeutic effect from PEBD

in patients with PFIC1. However, such benefits are not seen in all PFIC1 patients. In general, cholestasis is considered likely to improve with reduction of the bile acid pool, but the true mechanism is unknown. Patient 1 improved immediately after surgery, while, patient 2 did not. Even in patient 1, episodes of jaundice recurred during long-term observation (Figure 1); this pattern resembles the course of patients with BRIC. Importantly, TBA and ALT elevations did not necessarily parallel episodes of jaundice in these patients (Table 2; Figures 1 and 2). We believe that the course of cholestasis in PFIC1 may change to resemble that of BRIC after PEBD. Our patient 2 showed fluctuations in jaundice, ALT, and TBA during cholestasis, as are seen in BRIC.

In patient 1, a liver biopsy specimen obtained at the age of 2 months showed slight sinusoidal fibrosis, cholestasis, lymphocytic infiltration in portal regions, and poor development of interlobular bile ducts. By electron microscopy, the bile lacked normal particulate or granular features, a finding designated “Byler bile.” At 3 years after PEBD, we performed a second liver biopsy. The specimen showed no fibrosis or cholestasis, although fatty degeneration was evident near central veins (at zone 3). In patient 2, a liver biopsy specimen obtained at the age of 4 months showed cholestasis and giant cell transformation resembling that seen in progressive familial intrahepatic cholestasis 2; however no fibrosis was demonstrated. Immunostaining demonstrated expression of the bile salt export pump (BSEP) protein. A limited response of PEBD sometimes is attributed to advanced liver fibrosis already present before PEBD^[11,14]. However, pre-existing fibrosis clearly could not be blamed for Patient 2’s disappointing response.

Based upon our results, relief of pruritus may represent an indication of PEBD success. In patient 1, pruritus decreased sharply soon after PEBD, while patient 2 obtained much less relief. Accordingly, serial pruritus scale ratings may be very helpful in judging success of PEBD^[11,14].

In PFIC1, CDCA is not secreted via bile canaliculi^[14,15]. The BSEP readily secretes monovalent bile acids, including unconjugated CA, glycine-conjugated CA, taurine-conjugated CA, and taurine-conjugated deoxycholic acid. We believe that this preferential transport takes on greater importance in PFIC1.

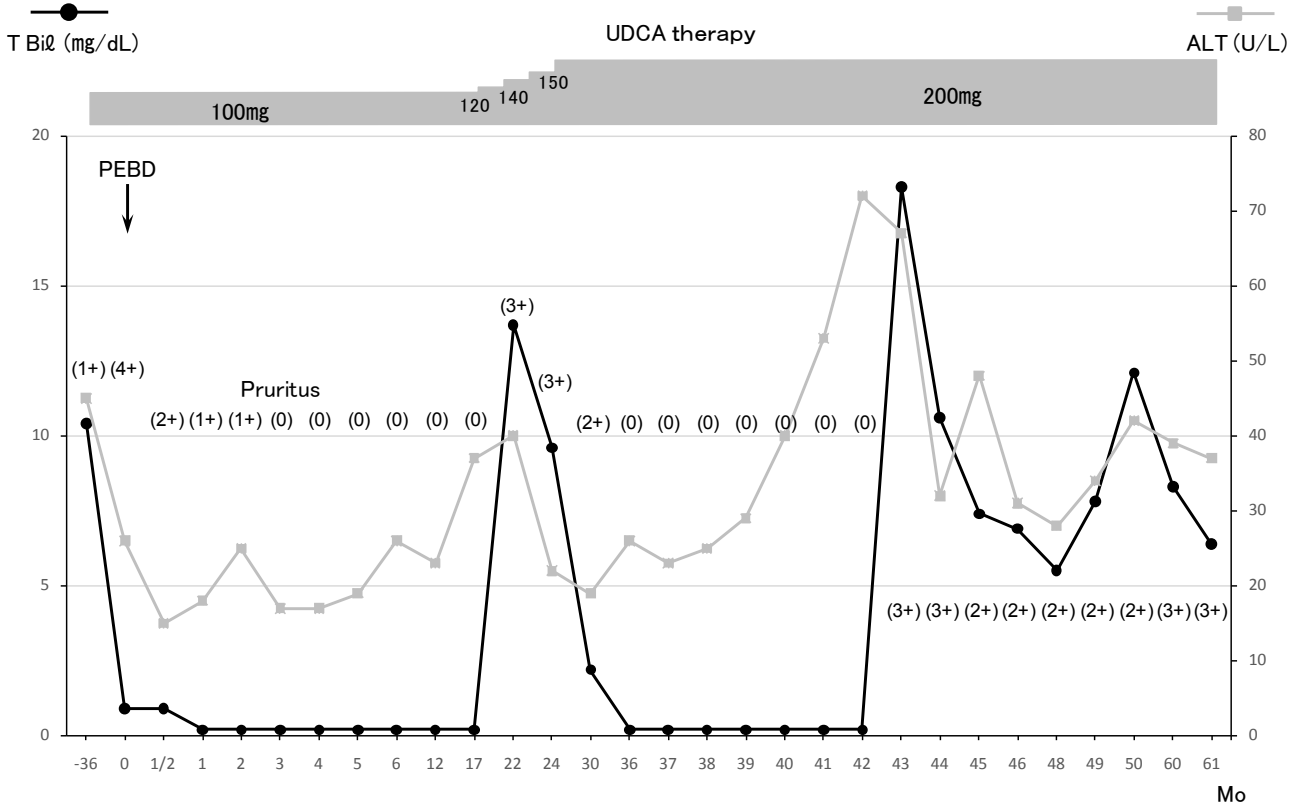


Figure 1 Clinical course of patient 1. Patient 1 experienced recurrence 17 months after PEBD, although cholestasis had improved immediately after the procedure. Subsequently cholestasis improved or worsened at least twice. This course resembles that of benign recurrent intrahepatic cholestasis. PEBD, partial external biliary diversion; T Bil, total bilirubin; ALT, alanine aminotransferase. Normal ranges of T Bil and ALT are 0.2 to 1 mg/dL and 5 to 42 U/L, respectively. Numbers in parentheses indicate pruritus scale ratings^[5], as described in the Subjects and Methods section.

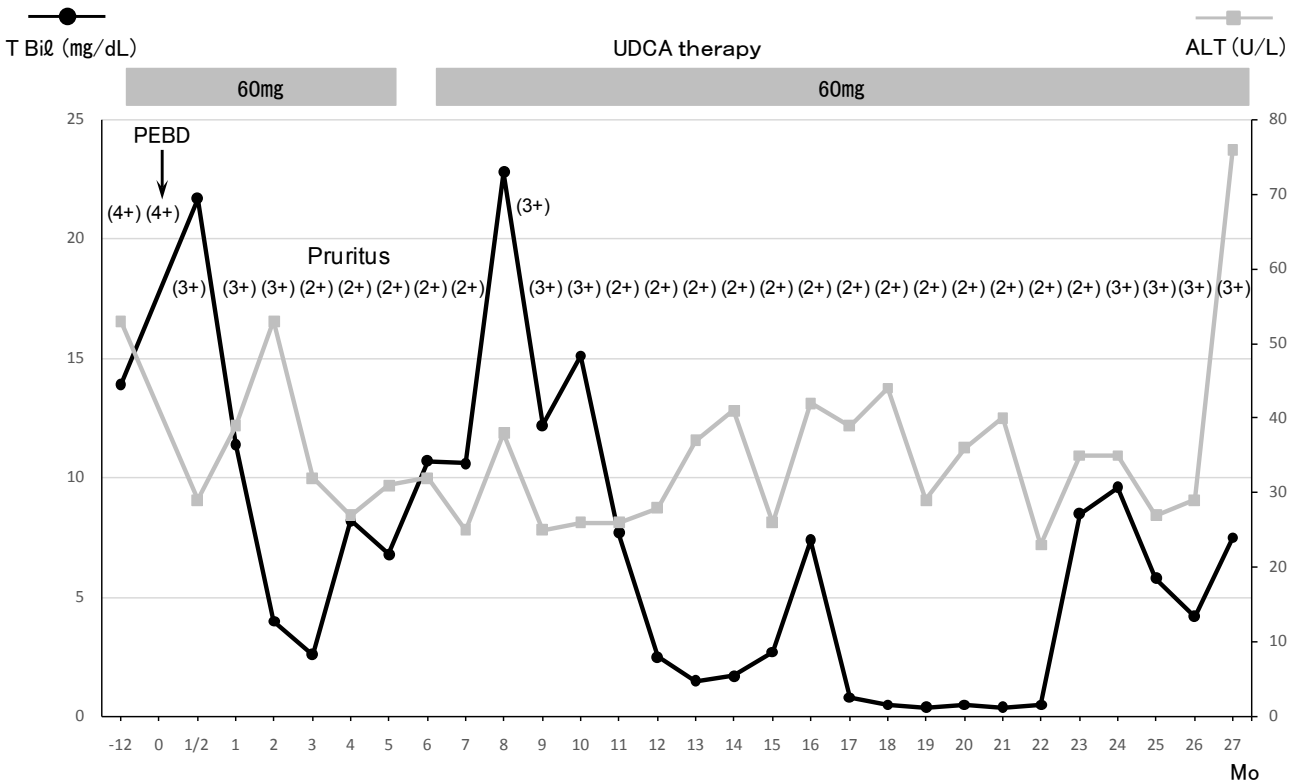


Figure 2 Clinical course of patient 2. No clinical improvement was evident after PEBD in patient 2. During cholestasis, serum concentrations of T Bil and ALT varied in a manner resembling the course of benign recurrent intrahepatic cholestasis. PEBD, partial external biliary diversion; T Bil, total bilirubin; ALT, alanine aminotransferase. Normal ranges of T Bil and ALT are 0.2 to 1 mg/dL and 5 to 42 U/L, respectively. Numbers in parentheses indicate pruritus scale ratings^[5], as described in the Subjects and Methods section.

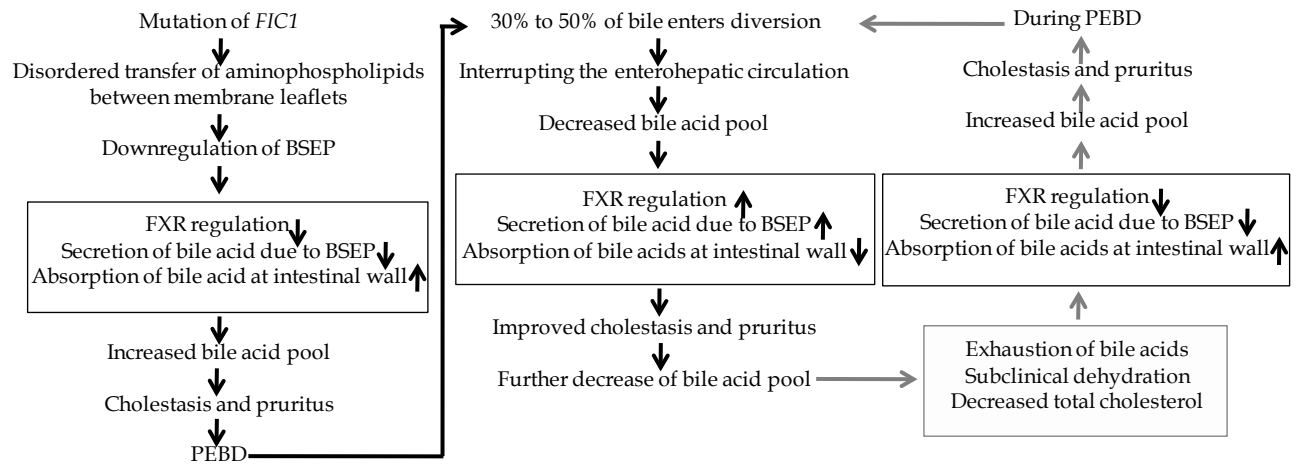


Figure 3 Proposed mechanisms underlying clinical evolution of PFIC1 symptoms to BRIC-like disease following PEBD. We believe that differences between individual patients' symptoms such as duration, rapidity of development, or improvement of cholestasis may be influenced by bile acid pool size. Important laboratory tests for patient monitoring include total cholesterol and TBA in serum. Dehydration from loss of bile via PEBD could contribute to cholestasis, as could changes in pressure within the bile duct. BRIC, benign recurrent intrahepatic cholestasis; PFIC1, progressive familial intrahepatic cholestasis 1; PEBD, partial external biliary diversion; TBA, total bile acids; FIC1, familial intrahepatic cholestasis 1 gene; BSEP, bile salt export pump; FXR, farnesoid X receptor.

In addition, when cholestasis is severe in PFIC1, the relative amount of HCA increases among urine and serum TBA^[15]. This increase also occurs during cholestasis resulting from biliary atresia. In the urine of infants with biliary atresia, the proportion of 1 β -hydroxylated bile acids among TBA increases as cholestasis persists^[8,16]. However, as liver function deteriorates, the proportion of 1 β -hydroxylated bile acids is reduced while the proportion of ketonic bile acids increases^[17].

Importantly, Jericho *et al* compared the therapeutic effect between PEBD and liver transplantation in PFIC patients with low GGT^[18]. They found that bile acid fractional turnover rates were excellent in PEBD, and that bile acid pool sizes have similar between these treatments, but hydrophilic bile acids were more prevalent with PEBD. Their findings suggest that the bile acid pool is not greatly altered after PEBD, and that a increased CA/CDCA ratio could account for improvement of PFIC1 patients after PEBD. However, the bile acid pool size and composition of biliary bile was not compared in detail between samples obtained before and after PEBD. In patients obtaining relief after PEBD, the change in bile acid pool size resulting from the treatment is unknown. We suggest that bile acid pool size most likely is decreased, because cholestasis is eliminated after successful PEBD. Moreover, Jericho *et al* did not compare CA/CDCA ratios in samples obtained before and after PEBD. Kurbegov *et al* have reported, increased total bile acids concentrations and a decrease in the CA/CDCA ratio in biliary bile from patients benefiting from PEBD^[3].

When the 2 patients in our study exhibited cholestasis, as evident from jaundice and increased TBA in serum, we administered UDCA therapy (Figures 1 and 2). The most abundant bile acid in the "other" category becomes UDCA during UDCA therapy, with bile acids are such as CA, CDCA, HCA, 1 β -hydroxylated bile acids, and ketonic bile acids becoming relatively less abundant.

We underwent the conjugated bile acid analysis in biliary bile at the time before and during PEBD. The main conjugated bile acids of CA and CDCA during PEBD were changed to glycine-conjugated type (Supplemental Table 3). This change might depend on the age. In general, at neonatal and infantile period, main conjugated bile acids are taurine-conjugated bile acids. Thereafter, glycine-conjugated bile acids gradually increase.

Cholestasis in PFIC1 is believed to have the following mechanism. Normal FIC1 protein function involves transfer of aminophospholipids such as phosphatidylserine from the outer membrane leaflet to the cytoplasmic leaflet, maintaining the normal asymmetry of phospholipids and normal bile secretion via the BSEP. When ATP8B1 function is lost, as in PFIC1 patients, the membrane becomes more symmetric, interfering with function of the BSEP. Consequently, bile acid secretion is inhibited and cholestasis develops. Concomitant with loss of canalicular bile secretion, cholestatic bile acid uptake increases and the bile acid pool increases across the intestinal wall because of reduced in farnesoid X receptor expression^[19-22].

When the course of PFIC1 comes to resemble BRIC after PEBD (Figure 3), the most important cause appears to involve the size of the bile acid pool. Variability of the pool could contribute to individual patient differences in symptom patterns such as duration, development, and abatement of cholestasis. Careful observation of T Bil, ALT, and TBA in serum is needed to appreciate this variability between patients and over time. Relative dehydration from loss of bile via PEBD also may trigger cholestasis^[12], as could changes in pressure within the bile duct. However, mechanisms favoring decreased cholestasis remain elusive.

Our study limitation is that it might be a small number of patients to mention the effect of PEBD for PFIC1.

In conclusion, increased bile secretion and a decreased CA/CDCA ratio in biliary bile may be the most important findings after PEBD. Pruritus relief was found to be an important sign of therapeutic effect. Moreover, PFIC1 may evolve to resemble BRIC following treatment of PFIC1 by PEBD. Bile acid pool size is likely to contribute to this change. Cholestasis and dehydration require close monitoring. Despite limitations, PEBD may be the best non-transplantation therapy for PFIC1 patients. Interestingly BRIC sometimes can evolve to resemble PFIC^[23]. In such patients, PEBD also might conceivably delay progression of symptoms. In addition, it might need to accumulate further data in the future.

CONFLICT OF INTERESTS

The authors declare that they do not have conflict of interests.

Supplemental Table 1 Results of bile acid analysis in patient 1.

	Pre PEBD	At PEBD	2 wks	1 mo	2 mo	4 mo	6 mo	12 mo	24 mo	36 mo	48 mo
Biliary bile (mmol/L)											
Cholic acid	0.3	47.2	1.2	6.1	13.6	16.3	26.3	21.3	0.8	22.8	18.5
Chenodeoxycholic acid	--	9.4	0.3	7.2	12.5	14.5	27.5	11.2	--	9.8	5.8
1 β -Hydroxylated bile acids	--	0.2	--	--	--	--	--	--	--	--	--
Hyochohic acid	--	2.1	--	--	--	1.6	0.7	--	--	0.1	1.4
Ketonic bile acids	--	--	--	--	--	--	--	--	--	--	--
Other bile acids	--	4.3	--	0.1	0.4	2.6	3.0	6.8	0.1	3.2	7.2
Total bile acids	0.3	63.2	1.5	13.4	26.5	35.0	57.5	39.3	0.9	35.9	32.9
Serum (μmol/L)											
Cholic acid	34.0	n.d.	7.2	0.6	--	--	--	--	77.5	1.5	43.1
Chenodeoxycholic acid	27.7	n.d.	12.2	1.6	--	--	--	--	35.6	1.7	46.3
1 β -Hydroxylated bile acids	--	n.d.	--	--	--	--	--	--	0.4	--	0.6
Hyochohic acid	6.3	n.d.	1.8	--	--	--	--	--	9.5	0.1	18.9
Ketonic bile acids	--	n.d.	--	--	--	--	--	--	--	--	0.7
Other bile acids	4.7	n.d.	1.6	0.2	--	--	--	0.6	21.7	0.6	95.3
Total bile acids	72.7	n.d.	22.8	2.4	--	--	--	0.6	144.7	3.9	204.9
Urine (μmol/mmol Cr)											
Cholic acid	21.7	n.d.	8.3	0.4	--	0.1	0.1	--	6.0	0.4	12.8
Chenodeoxycholic acid	2.8	n.d.	3.2	0.1	--	--	--	--	4.6	0.5	17.8
1 β -Hydroxylated bile acids	10.7	n.d.	18.6	--	--	--	--	--	--	0.4	6.8
Hyochohic acid	9.1	n.d.	7.1	--	--	--	--	--	7.4	0.1	7.8
Ketonic bile acids	5.9	n.d.	13.5	3.8	0.6	0.9	0.4	0.1	0.1	4.5	9.0
Other bile acids	28.3	n.d.	23.0	0.1	0.2	0.4	0.4	0.2	21.9	4.4	107.7
Total bile acids	78.5	n.d.	73.7	4.4	0.8	1.4	0.9	0.3	40.0	10.3	161.9

PFIC1, progressive familial intrahepatic cholestasis 1; PEBD, partial external biliary diversion; --, not detected; n.d., not done; 1 β -Hydroxylated bile acids, included 1 β -hydroxycholic acid and 1 β -hydroxychenodeoxycholic acid; ketonic bile acids, included 7 α , 12 α -dihydroxy-3-oxo-4-cholenoic acid and 12 α -dihydroxy-3-oxo-4-cholenoic acid; other bile acids, included ursodeoxycholic acid, deoxycholic acid, lithocholic acid, and 3 β -hydroxy-5-cholenoic acid.

Supplemental Table 2 Results of bile acid analysis in patient 2.

	Pre PEBD	At PEBD	2 wks	1 mo	2 mo	4 mo	6 mo	12 mo	18 mo	24 mo
Biliary bile (mmol/L)										
Cholic acid	n.d.	16.0	0.6	1.8	2.4	1.7	1.3	2.3	4.8	0.1
Chenodeoxycholic acid	n.d.	1.7	0.1	0.2	0.3	0.1	0.2	0.4	2.4	--
1 β -Hydroxylated bile acids	n.d.	--	--	--	--	--	--	--	--	--
Hyochohic acid	n.d.	0.2	--	--	--	--	--	--	--	--
Ketonic bile acids	n.d.	--	--	--	--	--	--	--	--	--
Other bile acids	n.d.	1.0	--	0.1	0.1	0.1	0.1	0.4	0.6	--
Total bile acids	n.d.	18.9	0.7	2.1	2.8	1.9	1.6	3.1	7.8	0.1
Serum (μmol/L)										
Cholic acid	87.3	50.7	20.6	63.7	19.6	37.0	32.7	12.3	2.1	156.8
Chenodeoxycholic acid	36.9	26.5	10.5	39.7	12.4	18.4	40.2	8.6	1.6	81.7
1 β -Hydroxylated bile acids	0.1	0.3	0.2	0.1	0.2	0.2	0.1	--	--	0.3
Hyochohic acid	1.9	2.7	1.2	1.9	1.0	2.0	1.9	0.6	--	12.5
Ketonic bile acids	--	--	--	--	--	--	1.8	--	--	0.4
Other bile acids	17.4	15.1	8.3	18.9	9.8	14.1	10.6	7.0	1.3	156.2
Total bile acids	143.6	95.3	40.8	124.3	43.0	71.7	87.3	28.5	5.0	407.9
Urine (μmol/mmol Cr)										
Cholic acid	36.9	n.d.	31.7	36.0	32.9	87.1	137.0	64.8	8.0	61.1
Chenodeoxycholic acid	18.3	n.d.	8.7	16.1	12.8	12.1	26.0	21.3	8.1	24.3
1 β -Hydroxylated bile acids	4.4	n.d.	5.0	1.6	2.9	8.9	4.2	4.3	0.9	6.9
Hyochohic acid	3.6	n.d.	2.1	1.0	1.0	2.2	2.7	1.1	--	9.6
Ketonic bile acids	6.7	n.d.	34.9	11.3	7.1	10.8	17.7	10.0	28.5	7.3
Other bile acids	60.1	n.d.	36.2	36.5	30.7	48.9	52.0	74.8	15.2	113.0
Total bile acids	130.0	n.d.	118.6	102.5	87.4	170.0	239.6	176.3	60.7	222.2

PFIC1, progressive familial intrahepatic cholestasis 1; PEBD, partial external biliary diversion; --, not detected; n.d., not done; 1 β -Hydroxylated bile acids, included 1 β -hydroxycholic acid and 1 β -hydroxychenodeoxycholic acid; ketonic bile acids, included 7 α , 12 α -dihydroxy-3-oxo-4-cholenoic acid and 12 α -dihydroxy-3-oxo-4-cholenoic acid; other bile acids, included ursodeoxycholic acid, deoxycholic acid, lithocholic acid, and 3 β -hydroxy-5-cholenoic acid.

Supplemental Table 3 Analysis of conjugated cholic and chenodeoxycholic acids in biliary bile.

	Pre-PEBD	At PEBD operation	Post-PEBD
Patient 1	taurine (%) / glycine (%)	taurine (%) / glycine (%)	taurine (%) / glycine (%)
Cholic acid	53.7 / 42.6	20.9 / 63.7	5.3 / 51.8
Chenodeoxycholic acid	1.6 / 2.2	3.1 / 7.5	4.5 / 35.9
Patient 2	taurine (%) / glycine (%)not	taurine (%) / glycine (%)	taurine (%) / glycine (%)
Cholic acid	done	51.6 / 36.5	23.2 / 71.2
Chenodeoxycholic acid	not done	7.2 / 4.4	0 / 5.5

PEBD, partial external biliary diversion; taurine, taurine-conjugated; glycine, glycine-conjugated; %, percentage of each bile acid in total bile acids. Age at PEBD operation of patient 1 is 3 years 6 months old. Age at PEBD operation of patient 2 is 1 year 8 months old.

REFERENCES

- 1 Schneider BL. Genetic cholestasis syndromes. *J Pediatr Gastroenterol Nutr* 1999; **28**: 124-131.
- 2 Colombo C, Okolicsanyi L, Strazzabosco M. Advances in familial and congenital cholestatic disease. Clinical and diagnostic implications. *Dig Liver Dis* 2000; **32**: 152-159.
- 3 Kurbegov AC, Setchell KDR, Haas JE, Mierau GW, Narkewicz M, Bancroft JD, Karrer F, Sokol RJ. Biliary diversion for progressive familial intrahepatic cholestasis: improved liver morphology and bile acid profile. *Gastroenterology* 2003; **126**: 1227-1234.
- 4 Jacquemin E, Hermans D, Myara A, Habes D, Debray D, Hadchouel M, Sokal EM, Bernard O. Ursodeoxycholic acid therapy in pediatric patients with progressive familial intrahepatic cholestasis. *Hepatology* 1997; **25**: 519-523.
- 5 Whittington PF, Whittington CL. Partial external diversion of bile for the treatment of intractable pruritus associated with intrahepatic cholestasis. *Gastroenterology* 1988; **95**: 130-136.
- 6 Emond JC, Whittington PF. Selective surgical management of progressive familial intrahepatic cholestasis (Byler's disease). *J Pediatr Surg* 1995; **30**: 1635-1641.
- 7 Numakura C, Abukawa D, Kimura T, Tanabe S, Hayasaka K. A case of progressive familial intrahepatic cholestasis type 1 with compound heterozygous mutations of ATP8B1. *Pediatr Int* 2011; **53**: 107-110.
- 8 Kimura A, Mahara R, Inoue T, Momura Y, Murai T, Kurosawa T, Tohma M, Noguchi K, Hoshiyama K, Fujisawa T, Kato H. Profile of urinary bile acids in infants and children: developmental pattern of excretion of unsaturated ketonic bile acids and 7 β -hydroxylated bile acids. *Pediatr Res* 1999; **45**: 603-609.
- 9 Ismail H, Kalicinski P, Markiewicz M, Jankowska I, Pawlowska J, Kluge P, Eliadou E, Kaminski A, Szymczak M, Drewniak T, Revillon Y. Treatment of progressive familial intrahepatic cholestasis: Liver transplantation or partial external biliary diversion. *Pediatr Transplantation* 1999; **3**: 219-224.
- 10 Arnell H, Bergdahl S, Papadogiannakis N, Nemeth A, Fischler B. Preoperative observations and short-term outcome after partial external biliary diversion in 13 patients with progressive familial intrahepatic cholestasis. *J Pediatr Surg* 2008; **43**: 1312-1320.
- 11 Yang H, Porte RJ, Verkade HJ, De Langen ZJ, Hulscher JBF. Partial external biliary diversion in children with progressive familial intrahepatic cholestasis and Alagille disease. *J Pediatr Gastroenterol Nutr* 2009; **49**: 216-221.
- 12 Stapelbroek JM, van Erpecum KJ, Klomp LW, Houwen RH. Liver disease associated with canalicular transport defects: Current and future therapies. *J Hepatol* 2010; **52**: 258-271.
- 13 Schukfeh N, Metzelder ML, Petersen C, Reismann M, Pfister ED, Ure BM, Kuebler JF. Normalization of serum bile acids after partial external biliary diversion indicates an excellent long-term outcome in children with progressive familial intrahepatic cholestasis. *J Pediatr Surg* 2014; **47**: 501-505.
- 14 Tazawa Y, Yamada M, Nakagawa M, Konno T, Tada K. Bile acid profiles in siblings with progressive intrahepatic cholestasis: absence of biliary chenodeoxycholate. *J Pediatr Gastroenterol Nutr* 1985; **4**: 32-37.
- 15 Jacquemin E, Dumont M, Bernard O, Erlinger S, Hadchouel M. Evidence for defective primary bile acid secretion in children with progressive familial intrahepatic cholestasis (Byler disease). *Eur J Pediatr* 1994; **153**: 424-428.
- 16 Kimura A, Yamakawa R, Ushijima K, Fujisawa T, Kuriya N, Kato H, Inokuchi T, Mahara R, Kurosawa T, Tohma M. Fetal bile acid metabolism during infancy: analysis of 1 β -hydroxylated bile acids in urine, meconium and feces. *Hepatology* 1994; **20**: 819-824.
- 17 Kimura A, Ushijima K, Suzuki M, Tohma M, Inokuchi T, Kato H. Profile of urinary bile acids in familial intrahepatic cholestasis with Coombs' negative haemolytic anaemia. *Acta Paediatr* 1995; **84**: 1119-1124.
- 18 Jericho HS, Kaurs E, Boverhof R, Knisely A, Shneider BL, Verkade HJ, Whittington PF. Bile acid pool dynamics in progressive familial intrahepatic cholestasis with partial external bile diversion. *J Pediatr Gastroenterol Nutr* 2015; **60**: 368-374.
- 19 Harris MJ, Le Couteur DG, Arias IM. Progressive familial intrahepatic cholestasis: genetic disorders of biliary transporters. *J Gastroenterol Hepatol* 2005; **20**: 807-817.
- 20 Frankenberg T, Miloh T, Chen FY, Anathanarayanan M, Sun A-Q, Balasubramanian N, Arias I, Setchell KDR, Suchy FJ, Shneider BL. The membrane protein ATPase class I type 8B member 1 signals through protein kinase C zeta to activate the farnesoid X receptor. *Hepatology* 2008; **48**: 1896-1905.
- 21 Cai SY, Gautam S, Nguyen T, Soroka CJ, Rahner C, Boyer JL. ATP8B1 deficiency disrupts the bile canalicular membrane bilayer structure in hepatocytes, but FXR expression and activity are maintained. *Gastroenterology* 2009; **136**: 1060-1069.
- 22 Paulusma CC, de Waart DR, Kunne C, Mok KS, Oude Elferink RPJ. Activity of the bile salt export pump (ABCB11) is critically dependent on canalicular membrane cholesterol content. *J Biol Chem* 2009; **284**: 9947-9954.
- 23 van Ooteghem NA, Klomp LWJ, van Berge-Henegouwen GP, Houwen RHJ. Benign recurrent intrahepatic cholestasis progressing to progressive familial intrahepatic cholestasis: low GGT cholestasis is a clinical continuum. *J Hepatol* 2002; **36**: 439-443.
- 24 Klomp LWJ, Vergas JC, von Mil SWC, Pawlikowska L, Strautnieks SS, van Eijk MJ, Juijn JA, Pabon-Pena C, Smith LB, DeYoung JA, Byrne JA, Gombert J, van der Brugge G, Berger R, Jankowska I, Pawlowska J, Villa E, Knisely AS, Thompson RJ, Frelmer NB, Houwen RH, Bull LN. Characterization of mutations in ATP8B1 associated with hereditary cholestasis. *Hepatology* 2004; **40**: 27-38.

Peer reviewers: Hartmut Jaeschke, PhD, Professor, Dept. of Pharmacology, Toxicology & Therapeutics, University of Kansas Medical Center, 3901 Rainbow Blvd, MS 1018, Kansas City, KS 66160, USA; Seyed Mohsen Dehghani, MD, Associate Professor of Pediatric Gastroenterology, Gastroenterohepatology Research Center, Shiraz Transplant Research Center, Nemazee Hospital, Shiraz University of Medical Sciences, Shiraz, 71937-11351, Iran.