

The Difference Between EUS & CT Scan in Diagnosing and Staging Peri Ampullary Tumours: An evidence-based approach

Al-Taan Omer Saad, Gravante Gianpiero, Stephenson James Andrew, Seok Ling Ong, Dennison Ashley Robert, Metcalfe Matthew Stephen

Al-Taan Omer Saad, Gravante Gianpiero, Stephenson James Andrew, Seok Ling Ong, Dennison Ashley Robert, Metcalfe Matthew Stephen, Department of Hepatobiliary and Pancreatic Surgery, Leicester General Hospital, Leicester, United Kingdom
Correspondence to: Omer Al-Taan, Leicester General Hospital, Gwendolen Road, Leicester, United Kingdom.

Email: amorialtaan@yahoo.com

Telephone: 44-116-258-8110

Fax: +44-116-258-4708

Received: June 28, 2015

Revised: July 24, 2015

Accepted: July 29, 2015

Published online: December 21, 2015

ABSTRACT

Periampullary carcinoma has a better prognosis than pancreatic adenocarcinoma. Hence accurate pre – operative staging is essential for avoiding surgical exploration for unresectable tumours. At the same time, operable cases should not be denied curative surgery based on false positive imaging. Hence it is essential that the imaging should have a high positive predictive value. This article makes a case for the utility of EUS in the accurate diagnosis of periampullary cancer, the detection of lymph node metastases and invasion of the Portal/Superior Mesenteric vein as compared to CT scanning. Electronic search of the PubMed, Embase and Cochrane Central Register of Controlled Trials databases was performed from 1982 to May 2009 to identify relevant studies. Articles meeting the criteria were retrieved and studied according to a standard proforma. Data were extracted from the articles into an Excel database and compared. The search revealed 211 published articles. Twenty-one papers matched the selection criteria. Sixteen articles were prospective and five retrospective. The data compared included local staging of the tumour, lymph node and venous involvement. CT scanning remains the initial investigation of choice in the diagnosis and staging of periampullary tumours but EUS might be superior for overall detection of lesions, especially

those smaller than 2 cm. Although CT remains the investigation of choice, it is essential that EUS is performed by experienced operators and used when the clinical suspicion is high and CT fails to demonstrate a mass. This could increase the number of early lesions detected and improve the overall prognosis.

© 2015 ACT. All rights reserved.

Key Words: Ultrasonography; Peri ampullary Neoplasms; Neoplasm Staging

Al-Taan OS, Gianpiero G, Andrew SJ, Ong SL, Robert DA, Stephen MM. The Difference Between EUS & CT Scan in Diagnosing and Staging Peri Ampullary Tumours: An evidence-based approach. *Journal of Gastroenterology and Hepatology Research* 2015; 4(12): 1830-1837 Available from: URL: <http://www.ghrnet.org/index.php/joghr/article/view/1530>

INTRODUCTION

By definition, periampullary cancers arise within 2 cm of the major papilla in the duodenum. They encompass four different types of cancers: ampullary (ampulla of Vater), biliary (intrapancreatic distal bile duct), pancreatic (head–uncinate process), and duodenal (mainly from the second portion). Although these tumours have different origins, the complex regional anatomy and their proximation within that confined region generally dictate a common operative approach^[1]. Periampullary carcinoma has a better prognosis than pancreatic adenocarcinoma because of the earlier onset of symptoms and the reduced frequency of lymph node metastases^[2]. For this reason, accurate staging is imperative to select cases for curative resections or avoid surgical exploration for unresectable tumours. A number of different imaging modalities have been employed alone or together for this purpose including ultrasound (US), angiography, endoscopic ultrasonography (EUS), computed tomography (CT),

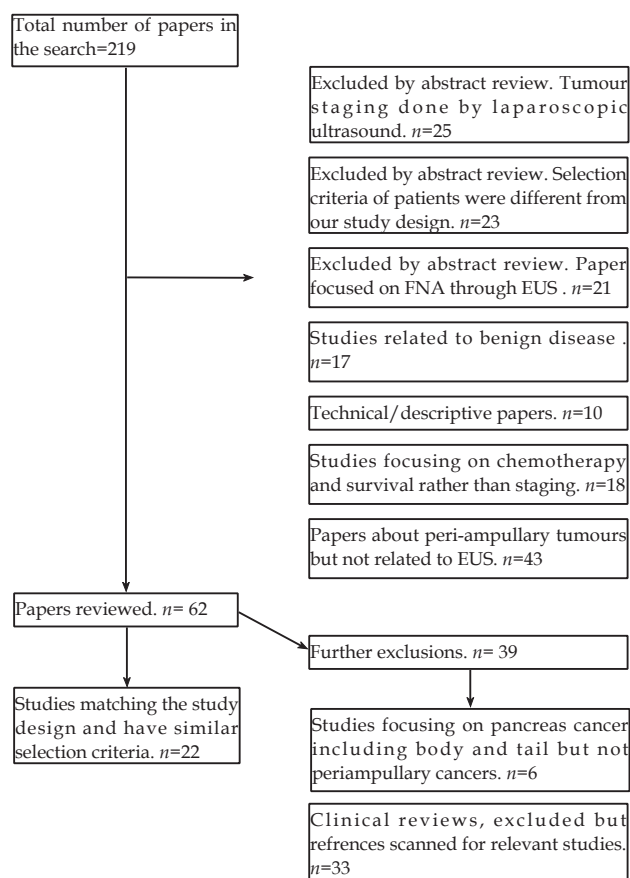


Figure 1 Selection process of the study examined.

magnetic resonance imaging (MRI) and endoscopic retrograde cholangiopancreatography (ERCP). Although results have improved dramatically over the last two decades, particularly with combinations of cross sectional imaging and endoscopic techniques, the relatively recent availability of EUS has allowed direct access to the ampulla combined with high quality ultrasound images.

EUS was introduced for the staging of periampullary carcinomas by DiMagna *et al*^[31] in 1980. The potential advantage of this modality lies in the avoidance of gas and fat that are usually present between the US probe and the lesion, allowing more accurate and less compromised pictures. Similar to other more common US applications, EUS involves no radiation but is highly operator dependant. Despite these potential limitations EUS was shown to be an effective tool for staging of pancreatic and periampullary cancers and it was predicted that it would supersede other imaging techniques. Nevertheless CT scanning still remains the first-choice for staging of patients with obstructive jaundice where it is suspected that the cause may be a periampullary carcinoma and only relatively few centres perform EUS selectively when CT findings are inconclusive. This is due to the wide availability of CT scanning, which is non-invasive, not operator dependant, takes only a short time to perform and may also be used to assess the liver and the lungs.

A number of studies have compared EUS to CT scanning for the staging of periampullary cancers but there remains no clear consensus about the relative merits. The aim of this review is to examine the presently available evidence comparing EUS to other commonly used modalities to determine whether there are clear advantages and to suggest guidelines for its use. To the best of our knowledge this is the first systematic review that analyses data concerning the staging of periampullary cancers with EUS.

MATERIALS AND METHODS

All types of studies that focused on EUS for the staging of periampullary cancers and that compared results to the final histopathology examination or to the CT scan were included in the review. For the purpose of the review periampullary cancers were defined as those involving the ampulla, the distal biliary tract, the head of the pancreas, the uncinete process and the second portion of the duodenum. No language restrictions were employed and no selection was conducted according to the tumour histology. Studies that did not specify what portion of the pancreas was investigated, those focusing on the body or tail of the pancreas, the proximal bile duct or other portions of the duodenum were excluded.

Articles were selected from the MEDLINE, EMBASE and Cochrane Central Register of Controlled Trials (CENTRAL) databases up to March 2011. The search was conducted using three different sets of key words: one for imaging modalities, one for periampullary tumours and one for outcome measures. Key words used for imaging modalities were: endoscopic, ultrasound, EUS. Key words used for periampullary tumours were periampullary, ampullary, pancreas, papilla, duodenum, bile duct, carcinoma, tumour, lymph node, metastasis, invasion, and staging. Key words used for outcome measures were sensitivity, specificity, positive predictive value (the proportion of patients with positive test result and correctly diagnosed), negative predictive value (the proportion of patients who are correctly diagnosed with negative test result), accuracy.

Potentially relevant articles were identified by the title and the abstract and full papers were obtained and assessed in detail by two of the authors (OA and GG) prior to their inclusion in the review. The reference list for each article (including copies of previously published reviews on the topic and presentation to congresses) was also screened to identify further relevant publications, which were obtained and assessed. Finally, the Current Controlled Trials (www.controlled-trials.com) database was also screened for randomized trials currently ongoing.

Data collection and analysis was carried out independently by two researchers (OA and GG). Data were extracted from the articles into an Excel database (Microsoft, Redmond, Washington – United States) and compared. The main outcomes were sensitivity, specificity, positive predictive value, negative predictive value and accuracy of EUS for diagnosis and staging of periampullary masses, lymph nodes and extension of the tumour into the surrounding venous system (portal vein – PV - and superior mesenteric vein - SMV). When possible, these results were compared with those of concomitant CT scans. The accuracy of the EUS for overall resectability was also compared to CT and with final histopathology wherever reported. Finally, overall sensitivity, specificity, positive predictive value, negative predictive value were calculated from the sum of individual raw data for each article when the absolute numbers were reported.

RESULTS

The search revealed 219 articles published between 1982 and 2011 (190 articles and 29 reviews) (Figure 1). Twenty-two papers (10%) matched the selection criteria while the remainder (197, 90%) were excluded^[2,4-23]. Seventeen articles were prospective^[2,4-6,9-15,18,20-24] and five retrospective^[7,8,16,17,19]. In all studies radiological findings were compared with both intraoperative findings and final histopathological analysis that were considered gold-standards of comparison. More specifically, considering lymph node involvement all studies compared

Table 1 Characteristics of studies analysed in the review.

Study	Recruitment period	Type of study	Site of tumour	Number of patients included	Type of EUS probe	EUS probe frequency (MHz)	Sex (Male/Female)	Age (years)
Rivadeneira DE ^[16]	1996-2000	Retrospective	Periampullary	48	Linear	12	28/20	62 +/- 4.9
Midwinter MJ ^[13]	1996-1998	Prospective	Ampullary/Pancreas	34	Radial	7.5 / 12	16/18	57 (32-75)
Shoup M ^[19]	1996-1998	Retrospective	Periampullary	37	Radial	7.5-12	-	-
Maluf-Filho F ^[11]	1997-1999	Prospective	Ampullary/Pancreas	56	Radial	7.5-12	-	57 (14-100)
Cannon ME ^[5]	1994-1997	Prospective	Ampullary	50	47 Radial/3Linear	7.5-12	32/18	62 (21-86)
Mukai H ^[15]	1984-1991	Prospective	Ampullary	23	Radial	7.5-10 & 7.5-12	-	-
Mukai H ^[15]	1984-1991	Prospective	CBD	16	Radial	7.5-10 & 7.5-12	-	-
Schwarz M ^[18]	1996-1997	Prospective	Periampullary	103	Radial	7.5-12	-	-
Skordilis P ^[20]	1993-2000	Prospective	Ampullary	20	Radial	7.5-12	13/7	66 (40-87)
Mansfield SD ^[12]	2002-2004	Prospective	Periampullary	84	Radial/Linear	5-7.5-, 10-12	39/45	67 (median)
Chen CH ^[6]	1996-1999	Prospective	Periampullary	74	-	7.5-12	36/38	63 (25-88)
Tomazic A ^[21]	-	Prospective	Periampullary	43	-	7.5-12	-	-
Chen CH ^[7]	1998-2006	Retrospective	Ampullary	41	Radial	7.5-12	20/21	67 (42-86)
Brugge WR ^[4]	-	Prospective	Pancreas	28	Radial	7.5-12	31/14	62 (mean)
Ho JM ^[8]	1996-2007	Retrospective	Periampullary	81	-	-	-	-
Howard TJ ^[9]	1993-1996	Prospective	Periampullary	21	Radial	7.5	16/5	54 (49-76)
Tio TL ^[2]	1987-1988	Prospective	Ampullary	24	Radial	7.5-10 & 7.5-12	17/7	59 (41-72)
Zhang QL ^[23]	1989-1992	Prospective	Ampullary	22	Radial	-	15/7	50 (18-72)
Zhang QL ^[23]	1989-1992	Prospective	CBD	18	Radial	-	10/8	61 (36-72)
Rosch T ^[17]	1991-1995	Retrospective	HOP	75	-	-	45/30	60 (42-76)
Mitake M ^[14]	1985-1988	Prospective	Ampullary	28	Radial	7.5	15/13	64 (42-83)
Kubo H ^[10]	1988-1997	Prospective	Ampullary	35	Radial	7.5-12	19/16	65 (46-83)
Yasuda K ^[22]	1982-1987	Prospective	Ampullary	13	Radial	-	7/6	-
Tierney WM ^[24]	1996-1999	Prospective	Ampullary/pancreas	29	Radial	-	-	64 (41-86)

Mukai^[15] and Zhang^[23] present results for ampullary cancers and common bile duct cancers separated, for this reason they are reported in two separated rows each.

Table 2 Tumour detection rate.

Study	Imaging	Patients with tumour	Correct diagnosis	Sensitivity %	Specificity %	PPV %	NPV %	Accuracy %
Yasuda K ^[22]	EUS	13	12	92	-	-	-	-
Mukai H (Ampullary) ^[15]	EUS	23	22	96	-	-	-	96
Mukai H (CBD) ^[15]	EUS	16	16	100	-	-	-	-
Tio TL ^[2]	EUS	-	-	-	-	-	-	87
Kubo H ^[10]	EUS	35	35	100	-	-	-	74
Zhang QL (Ampullary) ^[23]	EUS	-	-	-	-	-	-	82
Zhang QL (CBD) ^[23]	EUS	-	-	-	-	-	-	72
Brugge WR ^[4]	EUS	45	42	93	-	-	-	-
Howard TJ ^[9]	EUS	21	21	100	-	-	-	-
Skordilis P ^[20]	EUS	-	-	-	-	-	-	100
Cannon ME ^[5]	EUS	-	-	-	-	-	-	78
Schwarz M ^[18]	EUS	37	36	97	93	-	-	85
Midwinter MJ ^[13]	EUS	34	33	97	-	94	-	-
Shoup M ^[19]	EUS	34	33	97	33	94	50	-
Chen CH ^[6]	EUS	38	37	97	-	-	-	-
Rivadeneira DE ^[16]	EUS	44	44	100	75	98	100	-
Maluf-Filho F ^[11]	EUS	47	46	98	67	94	86	-
Chen CH ^[7]	EUS	41	40	98	-	-	-	-
Mansfield SD ^[12]	EUS	60	57	95	52	84	79	-
Yasuda K ^[22]	CT	12	3	25	-	-	-	-
Mukai H (Ampullary) ^[15]	CT	23	5	22	-	-	-	-
Mukai H (CBD) ^[15]	CT	16	8	50	-	-	-	-
Brugge WR ^[4]	CT	44	24	55	-	-	-	-
Howard TJ ^[9]	CT	21	14	67	-	-	-	-
Schwarz M ^[18]	CT	34	31	90	76	-	-	-
Midwinter MJ ^[13]	CT	34	26	76	-	-	-	-
Shoup M ^[19]	CT	34	28	82	66	97	25	-
Chen CH (2001) ^[6]	CT	36	8	39	-	-	-	-
Rivadeneira DE ^[16]	CT	44	30	68	50	94	13	-
Maluf-Filho F ^[11]	CT	-	-	86	87	86	88	-
Chen CH ^[7]	CT	28	8	29	-	-	-	-
Mansfield SD ^[12]	CT	60	58	97	87	95	91	-

Mukai^[15] and Zhang^[23] present results for ampullary cancers and common bile duct cancers separated, for this reason they are reported in two separated rows each. PPV = Positive Predictive Value. NPV = Negative Predictive Value. CBD = data on Common Bile Duct cancers. Ampullary: data on ampullary cancer. EUS = Endoscopic Ultrasound. CT = Computed Tomography.

preoperative results with proven pathology of those lymph nodes while for portal vein involvement studies compared preoperative results with intraoperative findings.

Table 1 describes the characteristics of the studies which were analysed. Two studies specifically investigated tumours of the head of pancreas^[4,17], two ampullary and distal common bile duct

tumours^[15,23], three ampullary and pancreatic tumours^[11,13,24], seven ampullary neoplasms only^[2,5,7,10,14,20,22]. The remainder did not specify the anatomical location of the tumour^[6,8,9,12,16,18,19,21].

Tumour diagnosis: EUS

The sensitivity of EUS for diagnosing the primary tumour has been

Table 3 Lymph nodes staging.

Study	Imaging	Involved lymph nodes	Correct diagnosis	Sensitivity %	Specificity %	PPV	NPV	Accuracy %
Yasuda K ^[22]	EUS	6	5	83	100	100	88	-
Mukai H (Ampullary) ^[15]	EUS	-	10	-	-	-	-	83
Mukai H (CBD) ^[15]	EUS	-	10	-	-	-	-	81
Mitake M ^[14]	EUS	13	9	69	-	-	-	-
Tio TL ^[2]	EUS	10	8	80	36	47	71	54
Kubo H ^[10]	EUS	10	4	40	75	44	71	63
Zhang QL (Ampullary) ^[23]	EUS	10	5	50	67	56	62	59
Zhang QL (CBD) ^[23]	EUS	6	3	50	100	100	50	67
Skordilid P ^[20]	EUS	-	-	-	-	-	-	71
Cannon ME ^[5]	EUS	-	-	50	-	-	-	68
Midwinter MJ ^[13]	EUS	9	4	44	93	80	72	-
Shoup M ^[19]	EUS	19	4	21	80	57	44	-
Chen CH ^[6]	EUS	35	26	47	-	-	-	74
Rivadeneira DE ^[16]	EUS	-	-	61	100	100	79	-
Chen CH ^[7]	EUS	15	7	47	83	70	65	67
Mansfield SD ^[12]	EUS	-	-	30	90	75	56	-
Mitake M ^[14]	CT	-	-	0	-	-	-	-
Cannon ME ^[5]	CT	-	-	23	-	-	-	-
Midwinter MJ ^[13]	CT	-	-	33	86	60	67	-
Shoup M ^[19]	CT	-	-	42	73	67	50	-
Chen CH ^[6]	CT	-	-	33	-	-	-	-
Rivadeneira DE ^[16]	CT	-	-	33	92	75	67	-
Chen CH ^[7]	CT	-	-	0	-	-	-	-
Mansfield SD ^[12]	CT	-	-	40	100	100	64	-

Mukai^[15] and Zhang^[23] present results for ampullary cancers and common bile duct cancers separated, for this reason they are reported in two separated rows each. PPV = Positive Predictive Value. NPV = Negative Predictive Value. CBD = data on Common Bile Duct cancers. Ampullary: data on ampullary cancer. EUS = Endoscopic Ultrasound. CT = Computed Tomography.

Table 4 Veins invasion staging.

Study	Imaging	Involved vessels	Correct diagnosis	Sensitivity	Specificity	PPV	NPV
Rosch T ^[17]	EUS	-	-	62	79	79	62
Cannon ME ^[5]	EUS	2	1	50	100	100	89
Schwarz M ^[18]	EUS	-	-	50	100	-	-
Midwinter MJ ^[13]	EUS	16	13	81	86	87	80
Shoup M ^[19]	EUS	5	1	20	100	100	89
Chen CH ^[6]	EUS	-	-	100	-	-	-
Rivadeneira DE ^[16]	EUS	9	9	100	100	100	100
Maluf-Filho F ^[11]	EUS	18	17	94	78	90	88
Mansfield SD ^[12]	EUS	-	-	50	83	50	83
Tierney WM ^[24]	EUS	6	6	100	93	-	-
Schwarz M ^[18]	CT	-	-	64	50	-	-
Midwinter MJ ^[13]	CT	16	9	56	100	100	67
Shoup M ^[19]	CT	5	4	80	84	44	96
Chen CH ^[6]	CT	-	-	33	-	-	-
Rivadeneira DE ^[16]	CT	9	4	45	100	100	88
Maluf-Filho F ^[11]	CT	18	10	56	78	83	47
Mansfield SD ^[12]	CT	-	-	88	92	78	96
Tierney WM ^[24]	CT	9	6	67	33	-	-

PPV = Positive Predictive Value. NPV = Negative Predictive Value. EUS = Endoscopic Ultrasound. CT = Computed Tomography.

reported in thirteen studies (Table 2)^[4,6,7,9-13,15,16,18,19,22] and the range varied between 92% and 100%^[9,10,15,16,22]. The overall sensitivity estimated by the sum of the total true positives / total number of patients was 97% (474/488) (Table 6)^[4,6,7,9-13,15,16,18,19,22]. Specificity was reported by five studies with a range from 33 to 93% (Table 2)^[11,12,16,18,19]. Of these, the highest value (93%) came from the largest series (103 patients)^[18], and the lowest value (33%) from the smallest series (37 patients)^[19]. The overall specificity could not be calculated due to the lack of raw data (Table 6).

Positive predictive value was reported by five studies and ranged from 84% to 98% (Table 2)^[11-13,16,19] with an overall rate of 93% (213/240) (Table 6)^[11-13,16,19]. The lowest positive predictive value was reported by Mansfield et al. who studied a large number of patients (n=84) using both radial and linear EUS^[12]. The negative predictive value was present in four articles and ranged from 50% to 100% (Table 2)^[11,12,16,19]. The lowest value (50%) was reported by the same retrospective study that demonstrated the lowest specificity^[19]. Only

Table 5 Accuracy for local Resectability.

Study	Imaging	Sensitivity %	Specificity %	PPV	NPV	Accuracy
Schwarz ^[18]	EUS	39	100	-	-	93
Mansfield SD ^[12]	EUS	81	43	85	38	-
Tomazic A ^[21]	EUS	97	71	56	98	81
Ho JM ^[8]	EUS	93	55	86	73	84
Howard TJ ^[9]	EUS	75	77	67	76	83
Schwarz ^[18]	CT	89	91	-	-	90
Mansfield SD ^[12]	CT	96	50	89	75	-
Tomazic A ^[21]	CT	95	46	41	96	70
Howard TJ ^[9]	CT	63	100	100	80	86

PPV = Positive Predictive Value. NPV = Negative Predictive Value. EUS = Endoscopic Ultrasound. CT = Computed Tomography.

three studies included sufficient data enough to calculate the overall negative predictive value, which was 83% (10/12) (Table 6)^[11,16,19]. The accuracy of the EUS in assessing the primary tumour was reported by seven studies and ranged from 72% to 100% (Table 2)^[2,5,10,15,18,20,23].

Table 6 Overall sensitivity, specificity, positive and negative predictive value calculated from the raw data of the single studies.

	EUS / CT			
	Sensitivity %	Specificity %	PPV %	NPV %
Tumour diagnosis	97% (474/488) / 63% (243/386)	- / -	93% (213/240) / -	83% (10/12) / -
Lymph nodes detection	56% (75/133) / -	76% (78/103) / -	62% (40/65) / -	- / -
Tumour extension into the veins	83.9% (47/56) / -	97% (101/104) / -	91% (41/45) / -	91% (89/98) / -

Tumour diagnosis: CT scan

Sensitivity was reported by twelve studies and ranged from 22% to 97% (Table 2)^[4,6,7,9,11-13,15,16,18,19,22]. The overall sensitivity was calculated from available data from 12 series and was 63% (243/386) (Table 6)^[4,6,7,9,12,13,15,16,18,19,22]. The lowest value was reported by a study on ampullary carcinomas which started in 1984 and used an early model CT scanner^[15]. The second lowest sensitivity (29%) was reported by a retrospective study that used a dual-slice CT scanner^[7]. The highest sensitivities (90% and 97%) came from the largest prospective studies^[12,18]. The exclusion of the two studies with the lowest sensitivities^[7,15] raised the overall sensitivity to 69% (230/335).

Specificity was reported by five studies and ranged between 50% and 87% (Table 2)^[11,12,16,18,19] with the lowest value of 50% being reported by a retrospective study which also reported a low sensitivity (68%)^[16]. Contrasting with this the highest specificity (87%) was reported by Mansfield *et al.* who also had the highest sensitivity (97%) and this was the only study using a multi-slice CT scanner^[12]. It was not possible to calculate overall specificity due to lack of data (Table 6). The positive predictive value reported by four studies ranged between 86% to 97% (Table 2)^[11,12,16,19] and the negative predictive value reported by the same studies ranged from 13% to 91% (Table 2)^[11,12,16,19]. It is interesting to note that two of these studies were retrospective and reported a very low negative predictive value^[16,19], whereas the prospective studies reported high values^[11,12].

Lymph nodes detection: EUS

Different studies commented on the ability of the different modalities to detect lymph nodes as part of the tumour staging. The papers that reported on lymph node staging used pre-defined criteria to indicate malignant involvement. These were size (greater than 5 mm^[5,9,16], or greater than 10 mm^[7,11,19] and morphological criteria including a smooth, round, discrete shape with either a hypoechoic echotexture or similar echogenicity to the mass. Sensitivity was reported by twelve studies with a wide range from 21% to 83% (Table 3)^[2,5-7,10,12-14,16,19,22,23]. The overall sensitivity of 56% (75/133) was calculated from the true positive / total positive of nine studies where data was available (Table 6)^[2,6,7,10,13,14,19,22,23]. Yasuda *et al.* reported the highest sensitivity (83%) even though this study was the oldest and included only thirteen patients^[22]. One retrospective study was far below the overall estimation of sensitivity (21%)^[19]. However only lymph nodes greater than 1 cm were counted as positive 19, while the cut-off values of the other studies were 0.5 cm. Excluding this study 19 from the calculation would raise the total sensitivity to 62% (71/114)^[2,6,7,10,13,14,19,22,23].

Nine studies reported the specificity for lymph nodes detection with a range from 36% and 100% (Table 3)^[2,7,10,12,13,16,19,22,23]. The overall specificity was calculated from seven studies where the individual data were available (Table 6). This corresponded to 76% (78/103)^[2,7,10,12,13,16,19,22,23]. Three series reported specificities of 100%^[16,22,23] and another six between 67% and 93%^[7,10,12,13,19,23]. One study reported a very low specificity (36%) and there was no clear reason for this difference apart from the fact that the authors used

four different types of EUS probe during the study period^[2]. The exclusion of the study of Tio *et al.* 2 from this calculation raised the overall specificity to 82% (73/89) (Table 6)^[2,7,10,13,19,22,23].

Positive predictive value was reported by nine studies with a range from 44% to 100% (Table 3)^[2,7,10,12,13,16,19,22,23]. The overall positive predictive value was calculated from the data from seven studies and corresponded to 62% (40/65) (Table 6)^[2,7,10,13,19,22,23]. The negative predictive value reported by nine studies ranged from 44% to 87% (Table 3)^[2,7,10,12,13,16,19,22,23]. The lowest value (44%) was reported by the same study that reported the lowest sensitivity^[20]. Overall negative predictive value could not be calculated because of lack of data (Table 6). Eight studies commented on the accuracy of the lymph nodes staging and the range was 54% to 83% (Table 3)^[2,5-7,10,15,20,23].

Lymph nodes detection: CT scan

The sensitivity of CT scanning for lymph nodes involvement was reported in eight studies (Table 3)^[5-7,12-14,16,19]. Results ranged from 0% to 42%. The earliest series and one retrospective study were the ones reporting that no involvement could be demonstrated^[7,14]. The overall sensitivity could not be calculated due to the lack of data (Table 6). The specificity was only reported in four studies with a range from 73% to 100% (Table 3)^[12,13,16,19]. The highest, 100%, was reported by the most recent study^[12]. Four studies reported the positive predictive value and the range was 60% to 100% (Table 3)^[12,13,16,19]. The same studies also reported the negative predictive value with a range of 50% to 67% (Table 3).

Tumour extension into the surrounding venous system: EUS

Extension of the tumour into the surrounding veins was assessed with EUS as part of the staging process. A similar approach to that for lymph node involvement was generally adopted with predefined criteria to indicate involvement. In the series reported the following criteria were accepted as indicating venous involvement. Visible tumour in the lumen, loss of hyperechoic interface between the tumour and adjacent vessel, abnormal vessel contour, presence of collateral vessels when the main vein could not be demonstrated. Ten studies reported on the sensitivity of EUS to diagnose venous invasion with a range from 20% to 100% (Table 4)^[5,6,11-13,16-19,24]. The overall sensitivity calculated from the five studies that reported on individual data was 83.9% (47/56) (Table 6)^[5,11,13,16,19,24]. The lowest sensitivity was reported by Shoup *et al.* in a retrospective study where only one in five demonstrated positive invasion (20%)^[19]. The exclusion of the lowest value reported by Shoup *et al.*^[19] resulted in an overall sensitivity of 90% (46/51) (Table 6).

Specificity was assessed by nine studies (Table 4)^[5,11-13,16-19,24], four of which reported values of 100%^[5,16,18,19] with the remainder between 78% and 93%^[11-13,17,24]. The overall specificity of 98% was calculated using available data from five studies (101/104) (Table 6)^[5,13,16,19,24]. Positive predictive value was reported in seven studies with a range from 50% to 100% (Table 4)^[5,11-13,16,17,19]. The overall positive predictive value calculated from the individual data available in five studies was 91% (41/45) (Table 6)^[5,11,13,16,19] and the same studies that reported on the positive predictive value also reported on the negative

predictive value with a range of 62% to 100% (Table 4)^[5,11-13,16,17,19]. The overall negative predictive value calculated from the individual data from five studies was 91% (89/98) (Table 6)^[5,11,13,16,19] with the lowest negative predictive value reported in a retrospective study that reviewed old EUS video tapes^[17].

Tumour extension into the surrounding venous system: CT scan

Involvement of the SMV and PV was assessed using CT scanning in eight studies^[6,11-13,16,18,19,24]. Sensitivity was reported by all of them with a wide range between 33% and 88% (Table 4). The highest value was reported by the most recent study^[12] while the lowest value came from a study that reported a very low sensitivity of CT for the primary tumour (39%) and for lymph node involvement (33%)^[6]. Specificity was reported by seven studies with a range of 33% to 100% (Table 4)^[11-13,16,18,19,24]. Shoup^[19] and Tierney^[24] reported the lowest values (20% and 33% respectively) followed by Schwarz et al (50%)^[18] while all the other studies ranged between 78%^[11] and 100%^[13,16]. Positive predictive value was reported by five studies that ranged between 44% and 100% (Table 4)^[11-13,16,19] with the lowest value being found in a retrospective study^[19]. The same five studies reported the negative predictive value between 47% and 96% (Table 4)^[11-13,16,19] and the highest value was reported by the most recent study^[12]. The overall sensitivity, specificity, positive predictive value and negative predictive value for the CT scan were not possible to calculate because of lack of data (Table 6).

Other findings

Five studies reported the accuracy of EUS and CT scan in assessing the resectability of the tumour (Table 5)^[8,9,12,18,21]. The studies correlated this assessment with the intraoperative findings and definitive histological analysis. Non-resectability was either due to the extension of the tumour in the pancreas, which signifies increased likelihood of lymph nodes involvement, or extension of the tumour into the surrounding lymph nodes or structures.

Some studies examined the sensitivity of the EUS in respect of the tumour size and found that EUS was very sensitive for small tumours (defined as less than 2cm) when compared to CT scanning^[15,18,19]. However, one study reported similar sensitivities for EUS and CT scan for small tumours (100%) but very high specificity for CT (100%) compared to EUS (29%)^[12].

DISCUSSION

Surgical resection remains the best treatment for patients with periampullary carcinomas and will produce long term survival in a significant number of patients. Improvements in morbidity and mortality rates achieved after surgery for periampullary and pancreatic cancers over the last two decades have expanded the potential indications and highlighted the importance of pre-operative assessment. Accurate pre-operative staging of these tumours is essential to avoid exploring inoperable tumours but also to ensure that operable cases are not denied surgery on the basis of false positive imaging. Historically several methods have been used for staging these tumours, but only CT scan and more recently EUS have withstood the test of time to become a regular part of the staging process. It was the initial purpose of the Authors to estimate from the single studies the overall sensitivity, specificity, positive and negative predictive values calculated from the raw data in order to provide values derived from large overall series and compare them among the techniques. However, it was possible to calculate the overall data for most EUS parameters (Table 6) but not for CT scan. Consequently,

a direct comparison in this sense was not possible. Still, the careful analysis allowed us to draw some general considerations among the techniques.

EUS has a high sensitivity for the diagnosis of primary periampullary tumours which is reported consistently in all studies and this includes small tumours (less than 2cm), which normally represent a challenge for CT scan. However, the study that reported the high sensitivity of CT scanning for tumour detection (including small lesions)^[12] was performed with an up to date multi-slice scanner, the speed of which minimises the breathing artefact. Three studies reported a relatively high sensitivity (82%-90%) and specificity (66%-87%) for CT and they all recruited patient in the late 1990s^[11,18,19] while the other studies generally reported poor sensitivities as low as 22%^[15]. The specificity for the diagnosis of the primary tumour was comparable for EUS and CT, apart from one retrospective study which reported lower values (33%) for EUS^[19]. The overall positive predictive value of EUS for detecting the primary tumour was again consistently high with a value of 93%. A few studies also reported a high positive predictive value for CT that explains its routine use in all patients suspected of having a periampullary carcinoma. However, this is not true when applied to the negative predictive value as the range is very wide (13%-91%) for CT while the EUS had a range of (50%-100%) and an overall negative predictive value of 83%. This might be in part due to small tumours that produce clinical symptoms but are hard to identify on the CT scanning. Further evidence for the superiority of EUS over CT scan in identifying the primary tumour is the overall accuracy identified in the majority of the studies.

Accurate lymph node staging is difficult but essential in patients where a potentially curative resection is planned. In this situation EUS appears less consistent with a wide range of sensitivities (21% to 83%) but an overall sensitivity of 56%. However, these results are still superior to CT which had low sensitivity (0%-40%) with the highest value being reported in the most recent study^[12]. Specificity was generally comparable for EUS and CT with both reporting relatively high values in most of the studies. Positive predictive value and negative predictive value are also comparable but the number of articles that reported positive predictive value is limited so results might not accurately reflect the true situation.

For the assessment of venous invasion EUS appears more accurate than CT with sensitivities of 50%-100% with only the single study of Shoup et al reporting significantly worse results (20%). These authors also reported the lowest sensitivity for lymph nodes and specificity for tumours detection^[19]. CT scan results were variable with a range of 33% to 88%. Specificity, however, was generally higher for EUS (78%-100%) compared to CT (50%-100%). A recent meta-analysis by Puli et al. analysed data from studies about vascular invasion as assessed by EUS in pancreas and periampullary carcinomas showed similar results for diagnosing stage IV disease (where vascular invasion limits respectability) reported EUS sensitivity to be 73% and specificity of 90.2%^[25].

According to Mansfield et al, for portal vein/superior mesenteric vein invasion, MDCT was superior ($P = 0.017$) and agreement was moderate (72 per cent, kappa = 0.42); the sensitivity and specificity were 88 and 92 per cent for MDCT, and 50 and 83 per cent for EUS. For resectability, there was no significant difference and agreement was good (78 per cent, kappa = 0.51)^[12].

Five studies presented the correlation with intraoperative findings, four of which involved pancreatic cancers only. For these reasons data presented on resectability need further assessment in future studies involving the other periampullary cancers.

Juana Gonzalo – Marin et al reported that EUS is better at

peripancreatic and periceliac lymphadenopathy detection (87.5%), and vascular infiltration (90%), especially for mesenteric vessels that also has a higher ability to correctly predict surgical resectability. EUS has shown a good ability to detect vascular invasion, showing low sensitivity in the superior mesenteric artery (17%) and celiac artery (50%), although the portal venous system was correctly assessed by EUS in 95% of cases, compared with angiography (85%) and CT (75%)^[26].

Heterogeneity is a limitation in this article. There is a mix of prospective & retrospective studies (most are prospective but few also retrospective^[7,8,16,17,19] and the exact location of the periampullary tumours is also not mentioned in some of the studies, which makes interpretation of data difficult.

Future studies shall now recruit patients focusing on specific subtypes of tumours to achieve more homogeneous results. This would eventually find specific subgroups of patients or neoplasms in which EUS, or CT scanning, is more advantageous than the other staging modalities or where their combined use is necessary. Examples of such clinical situations in which a more detailed analysis would be useful is in the detection of small vs. large tumours, the use of EUS at follow-up after surgery or in the evaluation of the tumour response to chemotherapy.

Another potential limitation is the data presented is over a long period starting in 1982^[22] and latest starting in 1996 and finished in 2007^[8], when high resolution CT scanning was not available and expertise was evolving. This cannot be said now, with availability of the present day CT scanning techniques. This progress has been addressed in the results and is more evident in the most recent paper^[12]. MDCT is the imaging method of choice for pancreatic and periampullary tumours. Routine EUS should be reserved for those with borderline resectability on MDCT.

We could have selected only the most recent studies for the analysis, however all but two were conducted before 2004^[8,12]. For these reasons the overall CT detection rate of tumour and lymph nodes may have been underestimated and only future investigations based on newer generations CT devices might solve this issue.

CONCLUSIONS

With all limitations presented, the article shows that no definitive conclusions can be drawn at the moment regarding the superiority of EUS or CT for the staging of periampullary tumours. With the rapid advances in the fields of imaging, a high-quality pancreatic protocol computed tomography (CT) is the primary imaging modality for diagnosing and staging pancreatic malignancy. The main limitation of CT is the lack of sensitivity for early pancreatic lesions. Endoscopic ultrasound (EUS) provides an excellent complement to CT for both diagnosis and staging of pancreatic and other peri-ampullary cancers^[27]. The role of EUS is important role in those situations where the findings from conventional images, US/CT are not concordant with the clinical symptoms, or are not sufficient to confirm or rule out the presence of a tumor, or in situations where CT fails to detect a mass despite a very high suspicion^[28]. EUS is useful in the investigation of ampullary and periampullary pathologies because of its capacity to identify small lesions (< 2cm.) more effectively than other imaging technologies^[7,28,29]. However, with the present day MDCT & Pancreatic protocol based CT scanning, few periampullary tumours will be missed out, even if small in size.

ACKNOWLEDGMENTS

Author contributions: Al-Ta'an OS, Gravante G, Dennison AR and

Metcalf MS designed the research; Al-Ta'an OS, Gravante G, Stephenson JA and Ong SL gathered the articles and extracted data; Al-Ta'an OS and Gravante G analyzed data; Al-Ta'an OS, Gravante G, Dennison AR and Metcalfe MS wrote the paper.

Disclosures: Mr OS Al-Ta'an, Dr G Gravante, Mr JA Stephenson, Ms SL Ong, MR AR Dennison and MR MS Metcalfe do not have any conflict of interest or any financial ties to any relevant company to disclose.

REFERENCES

- Sarmiento JM, Nagomey DM, Sarr MG, Farnell MB, Nagorney DM, Farnell MB. Periampullary cancers: are there differences? *Surg Clin North Am* 2001; **81(3)**: 543-555
- Tio TL, Tytgat GNJ, Cirot RJLM, Houtfoff HJ, Sars RA. Ampullopancreatic carcinoma: preoperative TNM classification with endosonography. *Radiology* 1990; **175**: 455-461
- DiMagna EP, Buxton JL, Regan PT, Hattery RR, Wilson DA, Suarez JR GP. Ultrasonic endoscope. *Lancet* 1980; **22(1)**: 629-631
- Brugge WR, Lee MJ, Kelsey PB, Schapiro RH, Warshaw A L. The use of EUS to diagnose malignant portal venous system invasion by pancreatic cancer. *Gastrointest Endosc* 1996; **43(6)**: 561-567
- Cannon ME, Carpenter SL, Elta GH, Nostrant TT, Kochman ML, Ginsberg GG, Stotland B, Rosato EF, Morris JB, Eckhauser F, Scheiman JM. EUS compared with CT, magnetic resonance imaging, and angiography and the influence of biliary stenting on staging accuracy of ampullary neoplasms. *Gastrointest Endosc* 1999; **50(1)**: 27-33
- Chen CH, Tseng LJ, Yang CC, Yeh YH. Preoperative evaluation of periampullary tumors by endoscopic sonography, transabdominal sonography, and computed tomography. *J Clin Ultrasound* 2001; **29(6)**: 313-321
- Chen C-H, Yang C-C, Yeh Y-H, Chou D-A, Nien C-K. Reappraisal of endosonography of ampullary tumors: correlation with transabdominal sonography, CT, and MRI. *J Clin Ultrasound* 2009; **37(1)**: 18-25
- Ho JM, Eysselein VE SB. The value of endoscopic ultrasonography in predicting resectability and margins of resection for periampullary tumors. *Ann Surg* 2008; **74(10)**: 1026-1029
- Howard TJ, Chin A C, Streib EW, Kopecky KK, Wiebke E a. Value of helical computed tomography, angiography, and endoscopic ultrasound in determining resectability of periampullary carcinoma. *Am J Surg* 1997; **174(3)**: 237-241
- Kubo H, Chijiwa Y, Akahoshi K, Hamada S, Matsui N, Nawata H. Pre-operative staging of ampullary tumours by endoscopic ultrasound. *Br J Radiol* 1999; **72(July 1998)**: 443-447
- Maluf-Filho F, Sakai P, Cunha JE, Garrido T, Rocha M, Machado MC, Ishioka S. Radial endoscopic ultrasound and spiral computed tomography in the diagnosis and staging of periampullary tumors. *Pancreatol* 2004; **4(2)**: 122-128
- Mansfield SD, Scott J, Oppong K, Richardson DL, Sen G, Jaques BC, Manas DM, Charnley RM. Comparison of multislice computed tomography and endoscopic ultrasonography with operative and histological findings in suspected pancreatic and periampullary malignancy. *Br J Surg* 2008; **95(12)**: 1512-1520
- Midwinter MJ, Beveridge CJ, Wilsdon JB, Bennett MK, Baudouin CJ, Charnley RM. Correlation between spiral computed tomography, endoscopic ultrasonography and findings at operation in pancreatic and ampullary tumours. *Br J Surg* 1999; **86**: 189-193
- Mitake M, Nakazawa S, Tsukamoto Y, Naitoh Y, Kimoto E HY. Endoscopic ultrasonography in the diagnosis of depth invasion and lymph node metastasis of carcinoma of the papilla of Vater. *J Ultrasound Med* 1990; **9(11)**: 645-650
- Mukai H, Nakajima M, Yasuda K, Mizuno S KK. Evaluation of endoscopic ultrasonography in the pre-operative staging of carcinoma of the ampulla of Vater and common bile duct. *Gastrointest Endosc*

- 1992; **38(6)**: 676-683
- 16 Rivadeneira DE, Pochapin M, Grobmyer SR, Lieberman MD, Christos PJ, Jacobson I, Daly JM. Comparison of linear array endoscopic ultrasound and helical computed tomography for the staging of periampullary malignancies. *Ann Surg Oncol* 2003; **10(8)**: 890-897
 - 17 Rösch T, Braig C, Gain T, Feuerbach S, Siewert JR, Schusdziarra V, Classen M. Staging of pancreatic and ampullary carcinoma by endoscopic ultrasonography. Comparison with conventional sonography, computed tomography, and angiography. *Gastroenterology* 1992; **102(1)**: 188-199
 - 18 Schwarz M, Pauls S, Sokiranski R, Brambs HJ, Glasbrenner B, Adler G, Diederichs CG, Reske SN, Möller P, Beger HG. Is a preoperative multidagnostic approach to predict surgical resectability of periampullary tumors still effective? *Am J Surg* 2001; **182**: 243-249
 - 19 Shoup M, Hodul P, Aranha GV, Choe D, Olson M, Leya J, Losurdo J. Defining a role for endoscopic ultrasound in staging periampullary tumors. *Am J Surg* 2000; **179(6)**: 453-456
 - 20 Skordilis P, Mouzas I a, Dimoulios PD, Alexandrakis G, Moschandra J, Kouroumalis E. Is endosonography an effective method for detection and local staging of the ampullary carcinoma? A prospective study. *BMC Surg* 2002; **2**: 1
 - 21 Tomazic A, Pegan V. Preoperative staging of periampullary cancer with US, CT, EUS and CA 19-9. *Hepatogastroenterology* 2000; **47(34)**: 1135-1137
 - 22 Yasuda K, Mukai H, Cho E, Nakajima M, Kawai K. The use of endoscopic ultrasonography in the diagnosis and staging of carcinoma of the papilla of Vater. *Endoscopy* 1988; **20 Suppl 1**: 218-222
 - 23 Zhang QL, Nian WD, Zhang LP, Liang JY. Endoscopic ultrasonography assessment for ampullary and bile duct malignancy. *Diagn Ther Endosc* 1996; **3(1)**: 35-40
 - 24 Tierney WM, Francis IR, Eckhauser F, Elta G, Nostrant TT, Scheiman JM. The accuracy of EUS and helical CT in the assessment of vascular invasion by peripapillary malignancy. *Gastrointest Endosc* 2001; **53(2)**: 182-188
 - 25 Puli SR, Singh S, Hagedorn CH, Reddy J, Olyae M. Diagnostic accuracy of EUS for vascular invasion in pancreatic and periampullary cancers: a meta-analysis and systematic review {A figure is presented}. *Gastrointest Endosc* 2007; **65(6)**: 788-797
 - 26 Gonzalo-Marin J, Vila JJ, Perez-Miranda M. Role of endoscopic ultrasound in the diagnosis of pancreatic cancer. *World J Gastrointest Oncol* 2014; **6(9)**: 360-368
 - 27 Kinney T. Evidence-based imaging of pancreatic malignancies. *Surg Clin North Am* 2010; **90(2)**: 235-249
 - 28 Castillo C. Endoscopic ultrasound in the papilla and the periampullary region. *World J Gastrointest Endosc* 2010; **2(8)**: 278-287
 - 29 Adler DG, Qureshi W, Davila R, Gan SI, Lichtenstein D, Rajan E, Shen B, Zuckerman MJ, Fanelli RD, Van Guilder T, Baron TH. The role of endoscopy in ampullary and duodenal adenomas. *Gastrointest Endosc* 2006; **64(6)**: 849-854

Peer reviewers: Akira Yagi, Ph.D. Professor Emeritus, Fukuyama University, Hiroshima, Japan; Premashish Halder, Head Of Department Of Gastrointestinal Surgery, Jagjivanram Hospital, Maratha Mandir Lane, Mumbai Central, Mumbai, India.