

Cystic Echinococcosis in the Liver: Evaluation of Percutaneous Treatment

António Menezes Silva, Henrique Vasconcelos Dias, Isabel Iria, Marco Aurélio Fonseca, Morais Valente

António Menezes Silva, Head of the Department of Surgery; Member of the Directive Council of the Portuguese College of General Surgery; Ex- president of the World Association of Echinococcosis, Portugal

Henrique Vasconcelos Dias, Isabel Iria, Department of Surgery, Pulido Valente Hospital, Lisbon, Portugal

Marco Aurélio Fonseca, Morais Valente, Department of Radiology, Pulido Valente Hospital, Lisbon, Portugal

Correspondence to: António Menezes Silva, Head of the Department of Surgery; Member of the Directive Council of the Portuguese College of General Surgery; Ex- president of the World Association of Echinococcosis, Portugal.

Email: mensilvapt@yahoo.com

Telephone: +351919851695

Received: November 16, 2015 Revised: December 12, 2015

Accepted: December 15, 2015

Published online: December 21, 2015

ABSTRACT

AIM: The objective of this manuscript is to demonstrate the efficacy of PAIR in the treatment of liver echinococcal cysts, and to present the method to define the cysts inactivity after therapy, based on US images of the cyst during the post intervention evaluation.

METHODS: We report the results of 62 liver cysts, type 1, 2 and 3a (WHO-IWGE US classification) treated by PAIR combined with Albendazole therapy, between 2003 and 2008, in the General Surgery Department and Radiology Department of the Pulido Valente Hospital (Lisbon-Portugal). All cysts were submitted to a final evaluation at five years follow-up. To evaluate the therapeutic efficacy we based in the US images. The US criteria for the therapeutic efficacy evaluation are: the parasite's layers detachment immediately after PAIR; the diminution of the liquid area and its substitution by a solid pattern giving the cyst a pseudotumoral aspect; the modification of the US pattern of the cyst with the progressive solidification of the cyst content; and, sometimes, the

cyst vanishing or observation of a linear echoic scare (vestiges). The percentage of the solidified area was determined by Computer Assisted Design (CAD) program. The cyst inactivity was defined if the cyst content solidification was total or almost total (> 90%).

RESULTS: The final evaluation of the 62 cysts showed a therapeutic efficacy of 87.1% (54 cysts), from which 48 (77.4%) reached a solidified pattern greater than 90% and six (9.7%) vanished. From the remaining nine cysts, three (4.8%) were referred to surgery in the second and third evaluations due to no alteration of its pattern (all cysts type 2); two (3.2%) reached solidification lower than 90%; and three (4.8%) relapsed (cysts type 2). No major complications or mortality were observed, neither secondary echinococcosis after PAIR.

CONCLUSION: PAIR is an effective and safe method to treat cysts type 1 and 3a of the WHO-IWGE US classification. The efficacy was 96.2% in cysts type 1 and 95.8% in cysts type 3a. It is not indicated in multivesicular cysts (type 2), in which the therapeutic failure was 50%.

© 2015 ACT. All rights reserved.

Key Words: Cystic Echinococcosis; Multivesicular cysts; PAIR; Cyst solidification; Inactive cyst

Silva AM, Dias HV, Iria I, Fonseca MA, Valente M. Cystic Echinococcosis in the Liver: Evaluation of Percutaneous Treatment. *Journal of Gastroenterology and Hepatology Research* 2015; 4(12): 1865-1872 Available from: URL: <http://www.ghrnet.org/index.php/joghr/article/view/1533>

INTRODUCTION

The annual incidence of Cystic Echinococcosis (CE) can range from less than 1 to 200 per 100,000 inhabitants in various endemic areas^[1]. In China and Central Asia the number of population risk is more than 20 million people^[2]. The mortality rate (about 2-4%)

from CE is lower than that from Alveolar Echinococcosis but it may increase considerably if medical treatment and care is inadequate^[1]. This is a very serious problem, which deserves our attention, particularly in the control and treatment. Nowadays in Portugal the incidence of the disease in Portuguese natives is very low, but there are patients from countries where the disease is endemic, seeking medical care.

The aim of the hydatid cyst treatment is the death of the parasite and consequently the cure of the disease. It has to be done with a minimal risk and maximum comfort for the patient. We must choose the therapeutic modality less expensive, and always avoiding complications, secondary echinococcosis and relapses. For many years surgery has been the only treatment available, but nowadays we have two methods more: the medical treatment with anti-infective drugs orally taken and the percutaneous puncture. The percutaneous puncture consists in the sterilization of the cyst content, using scolicial agents injected in the cystic cavity^[3-10], which is responsible for the hydatid germinal layer degeneration and destruction of the viable elements of the hydatid fluid.

Percutaneous puncture is known as PAIR (Puncture, Aspiration, Injection of the scolicide and Re-aspiration). It is a minimal invasive technique, less painful to the patient, less expensive with earlier discharge and activity resumption, as well as it has an inferior complication rate^[11-13]. PAIR is considered the Gold Standard for simple (univesicular) cysts^[6,8-15]. According to the World Health Organization Informal Working Group on Echinococcosis (WHO-IWGE) ultrasound classification^[16], the cysts are classified in active, transitional and inactive. Active stage include cysts type 1 (univesicular) and type 2 (multivesicular); in transitional stage was referred only cysts type 3 in the former publication, but these cysts were further classified into type 3a (detached layers) and 3b (predominantly solid with single or several daughter vesicles)^[8,14] (Figure 1); and inactive stage corresponding to cysts type 4 and type 5.

The ideal cysts to be treated by PAIR are cysts type 1 and 3a, and some cysts of type 2, if they have few daughter vesicles. But we also need to treat patients with relapses after surgery, which were referred to our department, because the technical difficulties and potential complications, if another surgical procedure were carried out.

MATERIALS

We studied 58 patients with liver echinococcal cysts, ages between

19 and 77 years: 34 male (58.6%) and 24 (41.4%) female, treated in the General Surgery Department and Radiology Department of the Pulido Valente Hospital in Lisbon, between 2003 and 2008. All patients were informed about the therapeutic method and approaches, which were carried out in accordance with the approved guidelines and regulations. Informed consent was obtained from all patients participating in this study.

The 58 patients had 62 liver cysts: 58 cysts (93.5%) were located in the right lobe and four (6.5%) in the left lobe. The cyst was unique in 54 patients (93.1%) and four patients (6.9%) had two cysts each. Seventeen patients (29.3%) were migrants from east European countries, and in 26 patients (44.8%) the cyst was relapsed after surgery realized some years ago.

Diagnosis was obtained by US in all patients, and cysts were classified according to the WHO-IWGE US classification. In 43 patients (74.1%) we used CT scan to confirm or to clarify the cyst location and characteristics.

All patients were serologically tested: indirect hemagglutination (IHA) or/and enzyme-linked immunosorbent assay (ELISA).

All cysts were uncomplicated cysts. According the WHO US classification its distribution was: 26 cysts type 1 (41.9%); 12 cysts type 2 (19.4%), and 24 cysts type 3a (38.7%). Cysts type 3b, 4 and 5 were excluded of this study.

The cysts size was between 2.1 cm diameter, the smaller, and 11.9 cm (diameter) the greater: 16 cysts had a diameter lower than 5 cm; 37 had a diameter between 5.1 and 10 cm, and nine cysts had a diameter larger than 10.1 cm. All cysts type 2 had a little number of daughter vesicles.

The cysts liquid volume was between 4.8 ml, the smaller (diameter 2.1 cm), and 882.3 ml the largest (diameter 11.9 cm). The cysts size and liquid volume according each type are presented in table 1.

RESULTS

All patients received Albendazole (ABZ) 400 mg four hours before PAIR and continue this drug after PAIR, 400 mg twice a day, during at least one month. All patients with a cyst content predominantly liquid one year after PAIR received ABZ, in the same dose, during at least 3 month. Some of these patients need to be re-punctured.

The patients were treated under Ambulatory Surgery modality, except those with cysts larger than 9 cm diameter with a liquid content greater than 350 ml, in which a catheter was left.


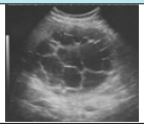



Stage	Type and cyst characteristics		Type and cyst characteristics	
Active	1 Univesicular anechoic cystic lesion with double line sign, with hydatid fluid, viable protoscolices and scolices		2 Multivesicular cyst multiseptated ("rosette-like"/"honeycomb" sign); multiple daughter vesicles with hydatid fluid; viable protoscolices and scolices	
	Transitional	3 a) Univesicular cystic with detached layers ("water lily-sign"), with hydatid fluid, viable protoscolices and scolices	3 b) Cyst with daughter vesicles in solid matrix. The liquid areas may contain viable protoscolices and scolices	
Inactive	4 Old cyst with heterogeneous content (hypo echoic / hyper echoic). No daughter vesicles. The liquid areas may contain viable protoscolices and scolices		5 Old cyst with solid content, plus calcified wall (cone-shaped shadow). No viable scolices	

Figure 1 CE US classification (WHO-IWGE).

WHO US Classification		Diameter		Nr.	Liquid volume	
			Average			Average
Type 1	26 (43.5%)	2.1-5 cm	3.7 cm	10	4.8-65.4 mL	32.5 mL
		5.2-9 cm	6.6 cm	13	73.6-381.7 mL	141.2 mL
		10.1-11.4 cm	10.7 cm	3	539.1-775.7 mL	640.2 mL
Type 2	12 (16.1%)	< 5 cm	-	-	-	-
		5.1-9.1 cm	7.4 cm	9	69.5-394.4 mL	220.6 mL
		10.1-11.9 cm	11 cm	3	539.5-882.3	706.2
Type 3a	24 (40.3%)	3.7-5 cm	4.6 cm	6	26.5-65.5 mL	51.2 mL
		5.2-8.8 cm	6.8 cm	15	73.6-356.8 mL	177.3 mL
		10.1-10.7 cm	10.3 cm	3	555.6-641.1 mL	578.8 mL
Total				62		

All cysts were punctured with a Chiba needle (18 G), under local anaesthesia and US guidance (Figure 2-A). The puncture was transhepatic in order to prevent peritoneal secondary echinococcosis in case of eventual spillage. In the cysts with a liquid content greater than 350 ml we used a catheter (Figure 2-C), for an adequate drainage of all content, which was removed when it was not necessary anymore.

We confirmed the presence of the needle inside the cyst cavity (Figure 2-B), and we aspirate a portion of the cyst content in order to create a space for injection of the scolicide. To detect any communication of the cyst with the biliary tract, the aspirated liquid colour was observed before the injection of the scolicial agent, and a fast dipstick test was carrying out to detect the presence of bilirubin. In doubtful cases a cystography (Figure 3) was carried out to detect communication of the cyst into the biliary tract.

The scolicial solution injected was 95% alcohol which was left inside the cyst during at least 10 minutes. Only after this time the liquid was re-aspirated. This liquid was observed in order to confirm the scolices destruction (Figure 4). Immediately after PAIR a US was realized to confirm the cyst reduction and the detachment of the parasite layers (Figure 5B), and a blood sample was taken to alcohol detection.

After hospital discharge the patients were evaluated one week later, so as in the first and third month, and each sixth month until the cyst reach the inactive stage. The patient evaluation includes: (a) One week, one month, three month after PAIR: US imaging; (b) Six month after the PAIR: US imaging and hepatic functional tests; (c) One year after PAIR: US imaging, hepatic functional tests, and serology.

In each observation the US images were evaluated and compared to the previous one. The criterion to accept the therapeutic efficacy was the progressive diminution of the liquid area and its substitution by a solid pattern giving the cyst a pseudotumoral aspect (Figure 6 B and C). If there weren't alterations, to the previous images, or if we found a persistent liquid image, the treatment was not considered effective, and PAIR was repeated, or the patient was referred to surgery.

We consider the cyst inactive when its content was total or almost total (more than 90%) solidified (Figure 7A), or the existence of vestiges only, like an echoic scare (Figure 7B), or the cyst vanishing.

Once the cyst content solidification is a criterion to evaluate the therapeutic efficacy, we quantified the percentage of the solidified area as follows: (1) Digitalisation of the US images and selection of the cystic area (A image of the figure 8); (2) Filter application, by Adobe Photoshop programme, to select the liquid and solid areas of the cyst (B image of the Figure 8); (3) Image "vectorization" by a Computer Assisted Design (CAD) program for calculation of the percentage of the solidified area (in B image of the figure 6 is 93%).

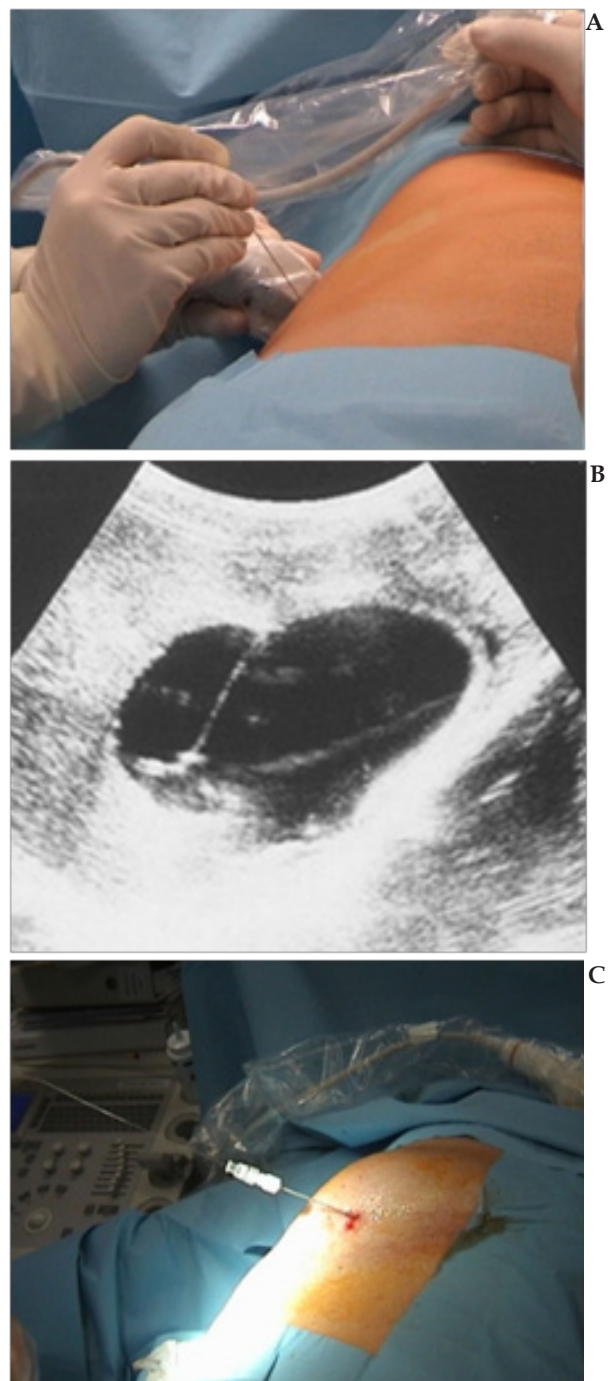


Figure 2 Puncture of the cyst guided by US; B: Needle inside the cyst; C: Cyst catheterization

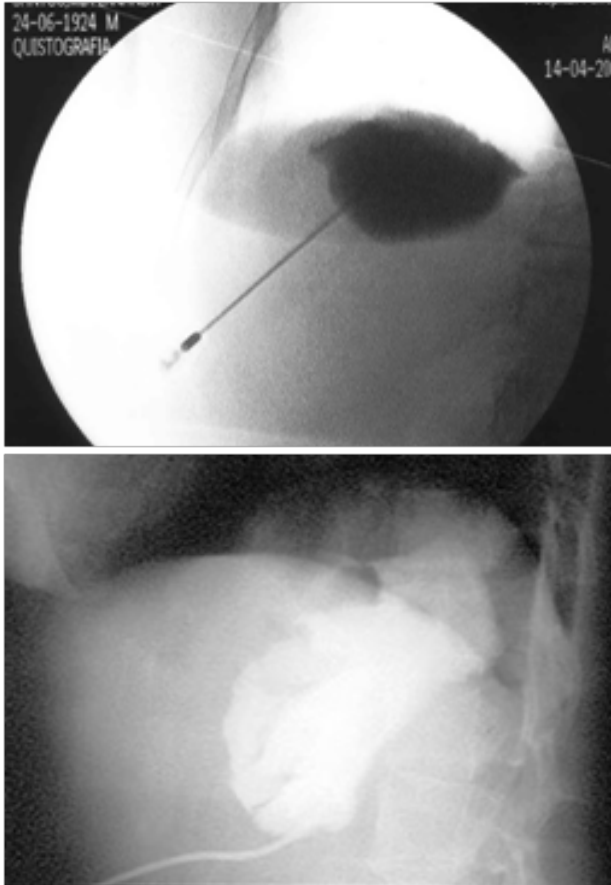


Figure 3 Cystography proving no existence of communication of the cyst into the biliary tract.

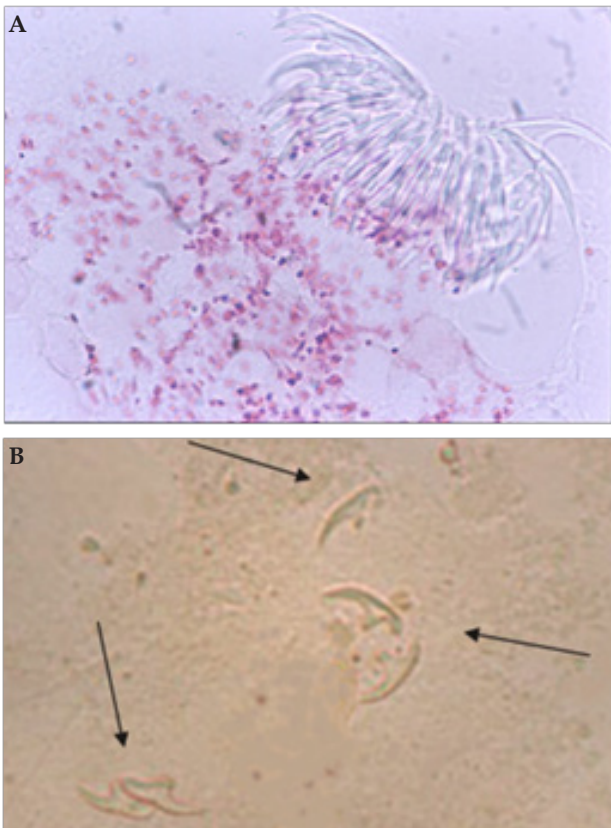


Figure 4 A: Scolex destroyed; B - Hooks free.

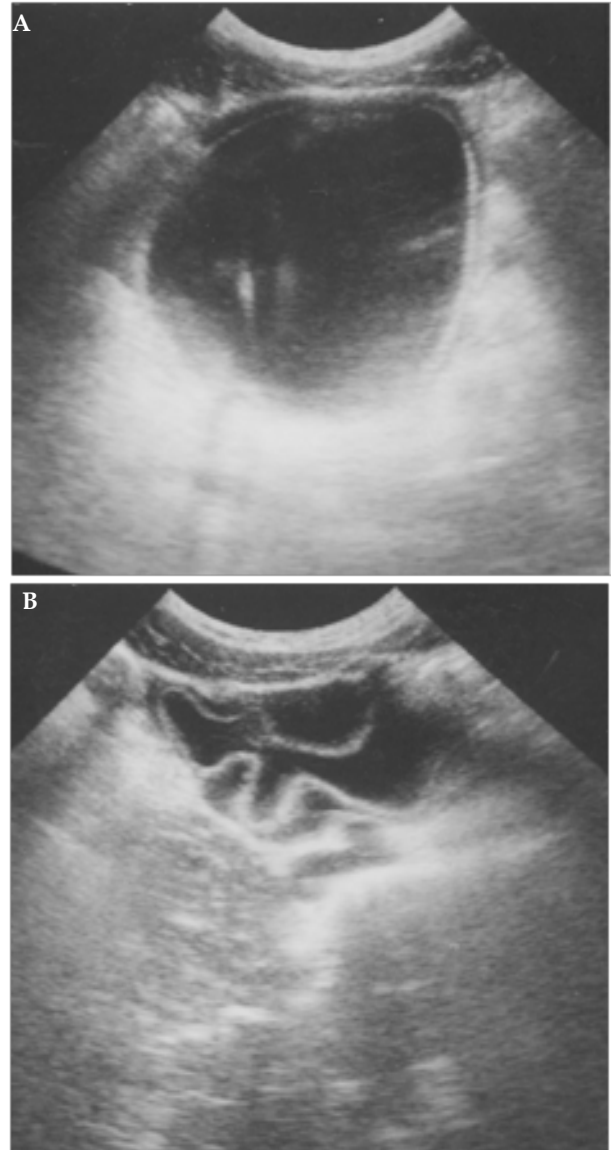


Figure 5 A: Before injection of scolicide; B: Immediately after re-aspiration.

Once the cysts reached the inactive stage they were evaluated each year until five years after PAIR. So, all cysts had, at least, five years follow-up, but some were even evaluated five years after reaching the inactive stage (cysts treated in 2003) which means ten years after PAIR.

RESULTS

During the PAIR and in the immediate post-PAIR there were no major complications, namely anaphylactic shock and haemorrhage, or mortality. Minor complications were registered in four patients (6.9%): (1) Urticaria and high temperature (38°C) in one patient; (2) Tachycardia, tachypnea and itching in three patients.

During the procedure cystography was carried out in seven patients (12.1%), to detect communication of the cyst into the biliary tract, which was not confirmed.

In the 13 cysts (21%) where a catheter for drainage was left (cyst with more than 350 ml), the average period of hospital stay was 4.3 days (range 3 – 6 days).

After PAIR the immunologic parameters increased in 43 patients (74.1%), namely in two patients in which the test was negative before the puncture. Six month after PAIR the immunologic parameters decreased in 18 patients (31%), however they maintained positive. One year later 47 patients (81%) maintained high immunologic

parameters. When the cysts were inactive, 41 of those patients (70.7%) maintained high immunologic values.

Abnormalities of laboratory tests (leucocytosis and eosinophilia; elevated liver tests (aspartate aminotransferase, alanine aminotransferase, alkaline phosphatase, gamma glutamil transpeptidase)) were observed in seven patients (12.1%). No disease related to the alcohol injection has been detected during the follow-up.

In what concerns the cysts we studied the reduction of the dimension and liquid volume, and the cyst content solidification, after PAIR.

Cysts type 1:

All cysts, but one, reached solidification greater than 90%. From the 26 cysts, four (diameter smaller than 3.5 cm) reached the inactive stage three month after PAIR; eleven cysts sixth month after PAIR; five cysts one year after PAIR; the remaining three cysts with diameter between 5.1 and 10 cm reached the inactive stage 18 month after PAIR, but two patients received ABZ during three month; from the three cysts with diameter between 10.1 and 11.4 cm, in two was necessary to repeat the puncture one year after PAIR and the patients received ABZ during three month. These cysts reached the inactive stage 18 month after the second puncture (30 month after the first PAIR); the remainder cyst (diameter 11.4 cm) maintained a solidification lesser than 90 %, five years after PAIR.

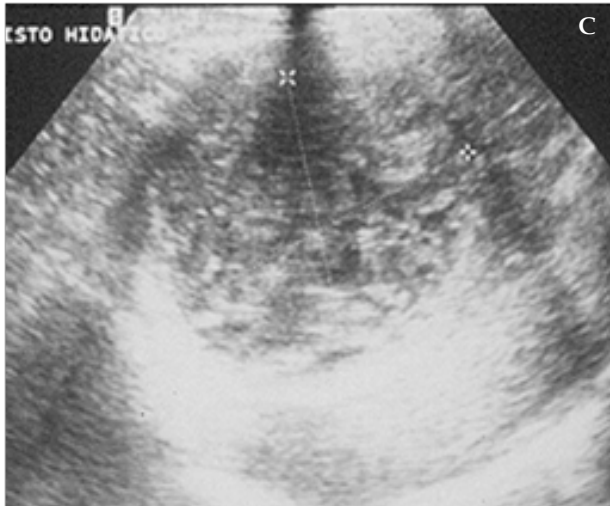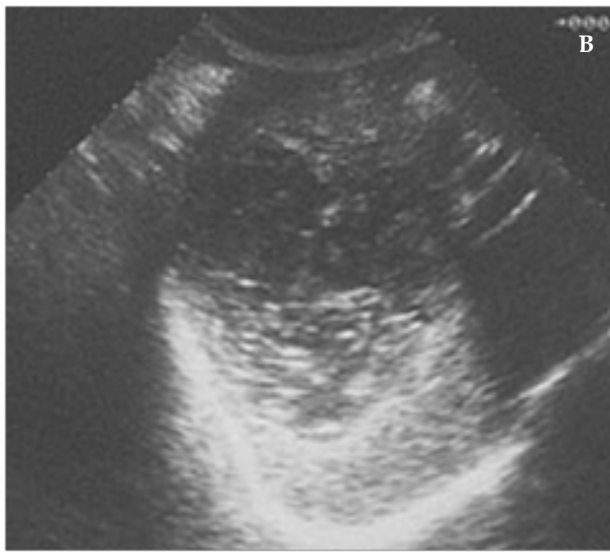

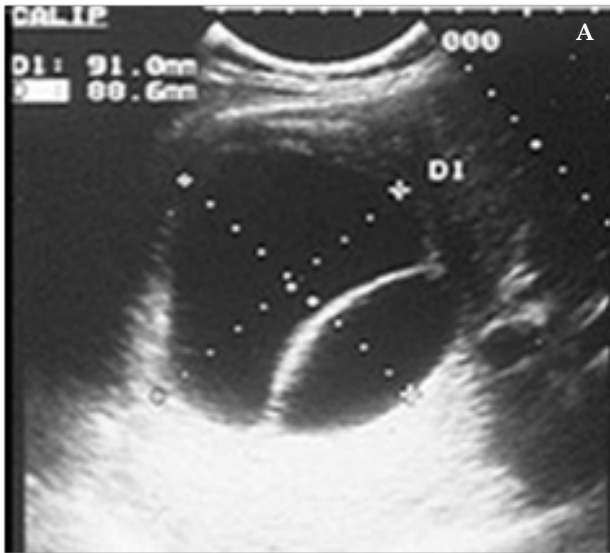
Figure 6 A: Liver cyst before PAIR; B: the same cyst one week after PAIR; C: the same cyst three month later.

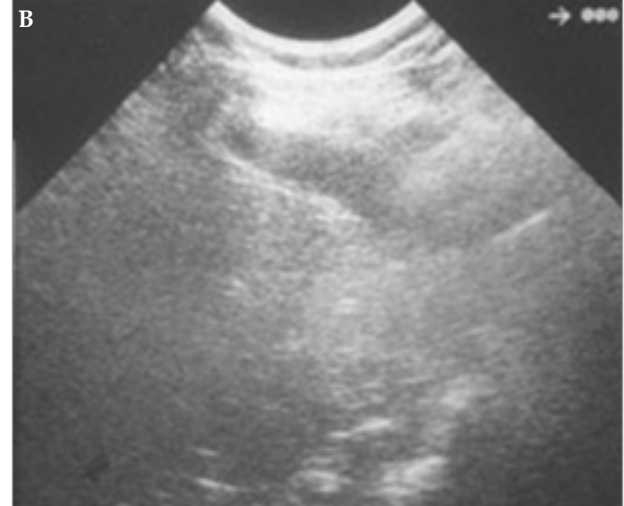
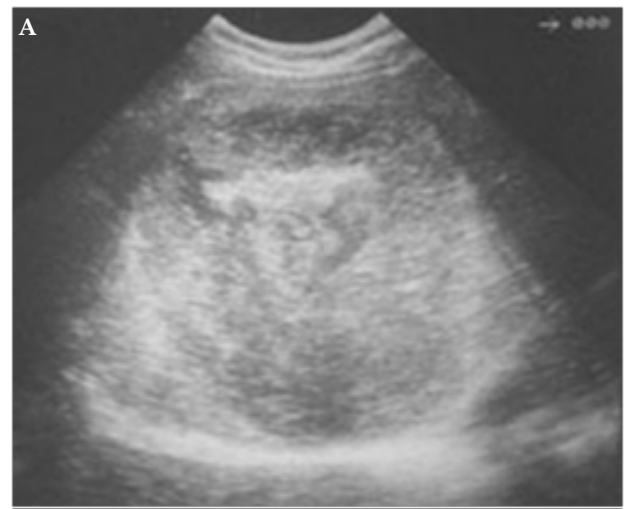

Figure 7 A: Cyst of figure 5-A, one year after PAIR (solidification > 90%); B: Cyst vestiges.

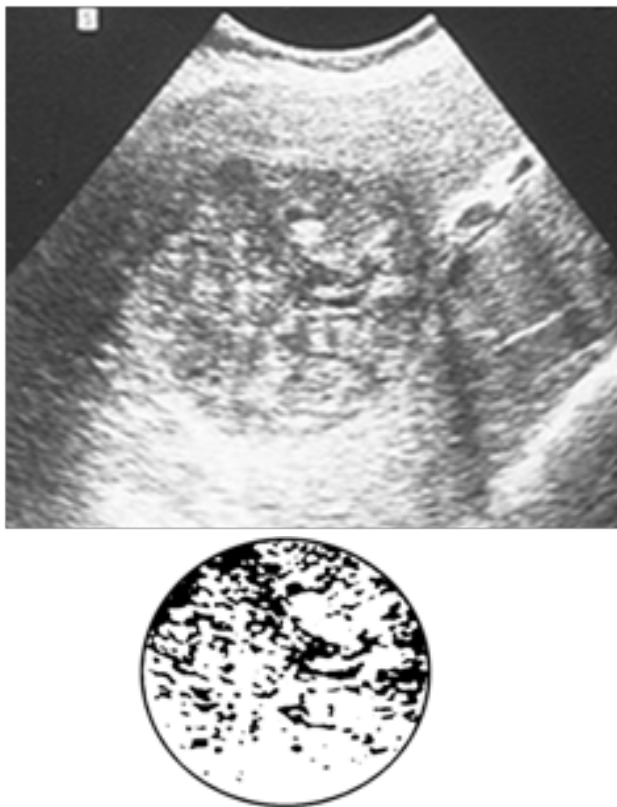


Figure 8 Liver cyst one year after PAIR (solidification > 90%).

We also observed a reduction of the cyst diameter in all cysts, but not significant (lesser than 20%). The average reduction of liquid volume was 92.5%. In short, the evaluation of the cysts type 1 five years after PAIR shows: four cysts (14.8%) vanished (cysts smaller than 3.5 cm); 21 cysts (81.5%) maintained a solidification greater than 90%; and one cyst (3.7%) had solidification lesser than 90% (cyst with diameter 11.4 cm). So, this means that the therapeutic success in cysts type 1 was 96.2%.

Cysts type 2:

The cysts type 2 reached the inactive stage later than cysts type 1, but in three cases (diameter greater than 10.1 cm), were not observed alterations of the cyst content pattern, six month and one year after PAIR. These three patients were referred to surgery, and included in the group of therapeutic failure. From the remaining nine cysts, two cysts reached an almost total solidification (> 90%) one year after PAIR: one cyst had diameter 5.1 cm and the other 9.1 cm (this with only two daughter vesicles); two cysts (diameter 6.8 and 6.9 cm), need to be re-punctured at one year of follow-up and the patients received ABZ during three month. From these cysts one reached the inactive stage six month later (18 month after the first puncture), and the other, one year later (two years after the first PAIR). From the remaining five cysts, two cysts (diameter 6 and 6.1 cm) reached a solidified pattern greater than 90% two years and 30 month after PAIR respectively; the others three cysts (diameter between 8.1 and 9 cm) had a pattern predominant liquid, reason why were re-punctured two years after PAIR and the patients received ABZ during three month. These cysts had a great number of daughter vesicles and reached an almost total solidified pattern, but lesser than 90%, two years later. In the fifth year evaluation they had a liquid pattern predominant, which was considered a relapse. In this group we also

observed a reduction of the diameter in all cysts that reached the inactive stage, like in cysts type 1, but lesser than 15%. The average reduction of liquid volume was 72.4%. The evaluation of the cysts type 2 five years after PAIR revealed: almost total solidification (> 90%) in six cysts (50%); and three relapses (25%) – cysts with a diameter greater than 8.1 cm. So, we can affirm the therapeutic success of PAIR in cysts type 2 was 50%. In this group we don't observed vanishing of any cyst.

Cysts type 3a:

All cysts type 3a reached the inactive stage except one: two cysts (diameter 3.7 and 4 cm) three month after PAIR; the remaining four cysts with a diameter less than 5 cm reached the inactive stage six month after PAIR, so as five cysts with a diameter between 5.2 and 6 cm; three cysts with a diameter between 6.3 and 7 cm reached the inactive stage one year after PAIR and five cysts 18 month after PAIR; from the remaining two cysts, one need to be re-punctured with 18 month follow-up, and reached the inactive stage 6 month later (two years after the first PAIR) and the other reached the inactive stage at the same time (two years after PAIR); from the three cysts with a diameter greater than 10.1 cm one need to be re-punctured at the second year evaluation and did not reach the inactive stage; the other two cysts had a content solidification lower than 90% at the second year evaluation, but one year later these cysts reached the inactive stage (3 years after PAIR). We observed a reduction of 31.5% on the cyst diameter, and a significant reduction on the liquid volume. The average reduction of liquid volume was 94%. The evaluation of the cysts type 3a five years after PAIR revealed: two cysts (8.3%) vanished (cysts smaller than 4 cm); 21 cysts (81.5%) reached solidification almost total (greater than 90%); and one cyst (3.7%) reached solidification lesser than 90% (cyst with diameter 10.7 cm). So, this means that the therapeutic success in cysts type 3a was 95.8%.

The final result considering all cysts was: (1) Therapeutic success in 54 cysts (87.1%): six cysts (9.7%) vanished (four type 1 and two type 3a and 48 cysts (77.4%) reached the inactive stage (21 type 1, six type 2 and 21 type 3a); (2) Partial success in two cysts (3.2%) – solidified pattern lower than 90% (one type 1 and one type 3a); (3) Therapeutic failure in six cysts (9.7%) all type 2; three of them were considered relapses (4.8%);

DISCUSSION

The percutaneous puncture is one option of treatment for liver cystic echinococcosis. The method is safe and has advantages for the patients^[11-15], and shall be used in strict compliance with the rules. Is indicated in uncomplicated cysts type 1 and 3a of the WHO US classification^[9-16], associated to Albendazole as adjunctive therapy^[8-10,14,15]. Cysts type 2 and 3b don't have indication for this approach^[8,14,15], because they are multivesicular cysts, particularly if they have many daughter vesicles. The method consists on puncture of the cyst, guided by US and aspiration of part of the content, in order to create a space for introduction of the scolicide. The puncture shall be transhepatic in order to prevent secondary echinococcosis in case of the hydatid liquid spillage^[5,8,17]. To prevent secondary echinococcosis Albendazole should be given before the intervention and after PAIR, at least during one to three month^[18,19].

The aspired liquid colour shall be observed in order to discard the presence of bile. In case of doubt a test to determine the presence of bilirubin shall be carried out^[5,10,17]. Sometimes a cystography is necessary to confirm the absence of fistula to the biliary tract. If a communication of the cyst with the biliary is found, the scolicide do

not shall be injected, because the risk of a chemical cholangitis. The aspirated liquid shall be observed microscopically to confirm the presence of scolices and protoscolices, and the scolicedal solution (alcohol 95%, or other) will be injected in the cyst cavity, where shall stay at least 10 minutes^[5,10,17]. After this, all content will be aspirated (re-aspiration) and a microscopic observation of the liquid carried out to confirm the presence of destroyed scolices, which demonstrate the efficacy of the scolicide^[5,10,17]. The other signal of the therapeutic efficacy is the detachment of the parasite layers observed in the US realized immediately after the PAIR^[5,10,15,17,20-22]. After this step the US images obtained during the patient's follow-up are very important to show the cysts content characteristics, in order to affirm the death of the parasite and the inactivation of the cyst. We don't have other means, namely immunological, to evaluate it, once the long-term survival of the hydatid indicates the existence of protection mechanisms against immunity response of the host. The hydatid fluid is the main responsible for the antigenic stimulation, but the germinal layer of the cyst is a barrier against immune competent cells of the host. So, it is necessary to have damages in the germinal layer, like fissures or rupture, to get an antigenic stimulation. When this antigenic stimulation occurs, there is a continuous elevation of the immunologic values for an indeterminate time. This elevation also happens after the cyst manipulation (surgery, puncture etc.)^[23,24]. Todorov *et al.* in 1976 have shown that the values of the indirect hemagglutination remained elevated in 80% of patients, four years after resection of the cyst^[25].

However Ortona *et al* and Siracusano *et al*^[26,27] reported on an "immunoblot" analysis revealed anti-HSP20 (Heat Shock Protein 20) antibodies in a statistically significant higher percentage of sera from patients with active disease than in sera from patients with inactive disease. This antibody seems to be a potential marker of active CE. The antibody levels significantly decreased over the course of anti-parasitic therapy in sera from patients with cured disease, when compared to sera from patients with progressive disease. Petrone *et al*^[28] found that interleukin-4 levels were significantly increased in patients with active cysts compared to those with inactive cysts.

Once we don't have an immunological method to confirm the cyst inactivity and guarantee the cure of this disease, we only can evaluate the therapeutic efficacy by imaging methods. From these, US has a relevant role in the evaluation of the percutaneous puncture approach^[17,20-22]. US is the mean that permits controlling the cyst evolution after the treatment, showing the progressive degeneration of its content until the parasite's death. The interpretation of the US images is very important to clarify the parasite activity stage, in order to evaluate the successful of treatment.

To evaluate the therapeutic efficacy we need to observe the subsequent US images and the alterations in cyst content, such as the diminution of the liquid area^[3,13,17] and its substitution by a solid pattern giving the cyst a pseudotumoral aspect, and also the cyst diameter reduction. The reduction of the cysts diameter was not significant, but occurred in all cysts: around 20% in cysts type 1; 15% in cysts type 2 and 31.5% in cysts type 3a. We observed a reduction more significant in small cysts. Concerning the liquid content we observed a reduction after PAIR, in all types: between 91 and 94% in cysts type 1, 72.4% in cysts type 2; and between 92 and 97% in cysts type 3a. We also observed that the fluid reduction was higher in smaller cysts. Gargouri *et al.* consider three classes: A – more than 50% reduction (success); B – less than 50% (partial success); and C – no alteration of the liquid content (failure)^[3]. We think that a 50% reduction of the liquid content is not enough to affirm the success of the treatment. Another point is related to the number of daughter

vesicles in cysts type 2. If the cyst have many daughter vesicles the puncture was more difficult and more time-consuming, and, moreover, the solidification was slower. The three cases of relapses in this study are related to these factors. The US criteria for evaluation of the therapeutic efficacy are: (a) Parasite's layers detachment immediately after PAIR; (b) Diminution of the liquid area and its substitution by a solid pattern giving the cyst a pseudotumoral aspect; (c) Modification of the US pattern of the cyst with the progressive solidification of the cyst content; (d) Cyst vanishing or observation of a linear echoic scare (vestiges).

If there aren't any significant alterations, to the previous images, or if we find a persistent liquid image, PAIR shall be repeated, or, in type 2 cysts, the patient referred to surgery. To consider successful treatment the cyst content solidification must continue until total or almost total solidification (more than 90%). That means the cyst reached the inactive stage. We can also observe the cyst vanishing or the existence of vestiges only, like a linear echoic scare. Both are the proof of the therapeutic efficacy^[10,15,17]. But to affirm the cyst inactivity we need to define what percentage of solidified area is necessary. On the other hand we need to quantify, so precisely as possible, this percentage of solidification.

The calculation of the solidified percentage by a Computer Assisted Design (CAD) program, as proposed, allow to know the exact moment at which a cyst reach the inactive stage and, according the same criteria, to know if the therapeutic is successful or not. This method is very simple and the information is achieved by US, which has a relevant role to evaluate the treatment efficacy in the liver hydatid cysts submitted to percutaneous puncture or treated by anti-infective drugs^[29]. The US images shall be carefully evaluated and compared to the previous one. The cyst content shall be calculated, in order to prove its reduction or not; the solidified area shall be calculated for the same reason. This process allows controlling the cyst evolution after the treatment, showing the progressive degeneration of its content until it ranges an almost total or total solidification, which proofs its inactivity and consequently the parasite's death.

CONCLUSION

PAIR is an effective and safe method to treat liver cystic echinococcosis. The indications are the cysts type 1 and 3a of the WHO classification, with a diameter lesser than 10 cm. Cysts type 2 and 3b have no indication for this therapeutic approach, because they are multivesicular cysts. These cysts may be treated also by percutaneous approach, but, in addition to PAIR, they require a cutting device or prolonged catheterization. The therapeutic efficacy can only be evaluated by imaging methods once it is not yet available by immunological means. According the criteria to establish the cyst inactivity, and consequently the death of the parasite, the point is to define cyst inactivity. The proposed method referred above, is a contribution for it. This imaging method that permits to establish the percentage of solidified area, and the cyst inactivity, is the only way that allows us to affirm the success of the treatment and the cure of the disease.

CONFLICT OF INTEREST

The authors declare that they have no conflict of interest.

REFERENCES

- 1 Eckert J, Gemmell MA, Meslin FX, Pawlowski ZS. Echinococcosis in humans: clinical aspects, diagnosis and treatment,

- in WHO/OIE Manual on Echinococcosis in Humans and Animals: A Public Health Problem of Global Concern. *World Organisation for Animal Health, Paris, France*, 2001; 20-66.
- 2 Craig P, McManus D, Lightowers M, Chabalgoity J, Garcia H, Gavidia C, Gilman R, Gonzalez A, Lorca M, Naquira C, Nieto A, Schantz P. Prevention and Control of Cystic Echinococcosis. *Lancet Infectious Diseases*, 2007; **7** (6): 385-94.
 - 3 Gargouri M, Ben-Amor N, Ben-Chehida F, Hammou A, Gharbi HA, Ben-Cheikh M, Kchouk H, Ayachi K, Golvan JY. Percutaneous treatment of hydatid cysts (*Echinococcus granulosus*). *Cardiovasc Intervent Radiol* 1990; **13** (3): 169-73.
 - 4 Wen H, New R, Craig P. Diagnosis and treatment of human hydatidosis. *Br J Clin Pharmacol* 1993; **35**: 565-74.
 - 5 Filice C, Brunetti E, Crippa F, Bruno R. Treatment of Echinococcal Abdominal Cysts. *Ultrasound quarterly* 1999; **15** (4): 223-33.
 - 6 Sayek I, Onat D. Diagnosis and treatment of uncomplicated hydatid cyst of the liver. *World J Surg* 2001; **25**: 21-27.
 - 7 Menezes-Silva A. Hydatid cyst of the liver – criteria for the selection of appropriate treatment. *Acta Tropica* 2003; **85**: 237-42.
 - 8 Junghanss T, da Silva A, Horton J, Chiodini P, Brunetti E. Clinical Management of Cystic Echinococcosis: State of the Art, Problems and Perspectives. *Am. J. Trop. Med. Hyg.* 2008; **79** (3): 301-11.
 - 9 Smego RA, Bhatti S, Khaliq AA, Beg MA. Percutaneous aspiration-injection-reaspiration drainage plus albendazole or mebendazole for hepatic cystic echinococcosis: a meta-analysis. *Clin Infect Dis* 2003; **37** (8): 1073-83.
 - 10 Brunetti E, Troia G, Garlaschelli AL, Gulizia R, Filice C. Twenty years of percutaneous treatments for cystic echinococcosis: a preliminary assessment of their use and safety. *Parassitologia* 2004; **46** (4): 367-70.
 - 11 Khuroo M, Wani N, Gul Javid G, Khan B, Yattoo G, Shah A, Jeelani S. Percutaneous drainage compared with surgery for hepatic hydatid cysts. *The New England Journal of Medicine* 1997; **337** (13): 881-87.
 - 12 Men S, Hekimoolu B, Yücesoy C, Serdar A, Baran I. Percutaneous treatment of hepatic hydatid cysts: an alternative to surgery. *AJR* 1999; **172**: 83-89.
 - 13 Yagci G, Ustunsoz B, Kaymakcioglu N, Bozlar U, Gorgulu S, Simsek A, Akdeniz A, Cetiner S, Tufan T: Results of surgical, laparoscopic, and percutaneous treatment for hydatid disease of the liver: 10 years experience with 355 patients. *World J Surg* 2005; **29** (12): 1670-79.
 - 14 Brunetti E, Junghanss T. Update on cystic hydatid disease. *Current Opinion in Infectious Diseases* 2009; **22**: 497-02.
 - 15 Brunetti E, Kern P, Vuitton DA, Writing Panel for the WHO-IWGE. Expert consensus for the diagnosis and treatment of cystic and alveolar echinococcosis in humans. *Acta Trop* 2010; **114**: 1-16.
 - 16 WHO Informal Working Group on Echinococcosis. International classification of ultrasound images in cystic echinococcosis for application in clinical and field epidemiological settings. *Acta Trop* 2003; **85**: 253-61.
 - 17 Golemanov B, Grigorov N, Mitova R, Genov J, Vuchev D, Tamarozzi F, Brunetti E. Efficacy and Safety of PAIR for Cystic Echinococcosis: Experience on a Large Series of Patients from Bulgaria. *Am J Trop Med Hyg* 2011; Jan 5; **84**(1): 48-51.
 - 18 Erzurumlu K, Hokelek M, Gonlusen L, Tas K, Amanvermez R. The effect of albendazole on the prevention of secondary hydatidosis. *Hepato-gastroenterology* 2000; **47** (31): 247-50.
 - 19 Morris D. Pre-operative Albendazole therapy for hydatid cyst. *Br J Surgery* 1987; **74**: 805-06
 - 20 Gharbi HA, Hassine W, Brauner MW, Dupuch K. Ultrasound examination of the hydatid liver. *Radiology* 1981; **139** (2): 459-63.
 - 21 Ben-Amor N, Gargouri M, Gharbi H, Golvan Y, Ayachi K, Kclouck H. Essai de traitement par ponction des kystes hydatiques abdominaux inopérables. *Ann Parasitol Hum Comp* 1986; **61** (6): 689-92.
 - 22 Giorgio A, Tarantino L, de Stefano G, Francica G, Mariniello N, Farella N, Perrotta A, Aloisio V, Esposito F. Hydatid liver cyst: an 11-year experience of treatment with percutaneous aspiration and ethanol injection. *J Ultrasound Med* 2001; **20** (7): 729-38.
 - 23 Ângelo H, Ralha F, Ferreira I, Gomes S, David de Morais J. Padrões de resposta humoral na hidatidose tratada. *Acta Parasitológica Portuguesa* 2003; **10** (1): 56-57.
 - 24 Refik M, Mehmet N, Durmaz R. Postoperative changes in serum cytokines profile and nitric oxide levels in patients with cystic echinococcosis. *Parasite* 2005; **12**: 265-69.
 - 25 Todorov T, Stojanov G, Rohov L, Rasev R, Alova N. Antibody persistence after surgical treatment of Echinococcosis. *Bull World Health Organization* 1976; **53**: 407-15.
 - 26 Ortona E, Rigano R, Buttari B, Delunardo F, Ioppolo S, Margutti P, Profumo E, Teggi A, Vaccari S, Siracusano A. An update on immunodiagnosis of cystic echinococcosis. *Acta Tropica* 2003; **85**: 165-71.
 - 27 Siracusano A, Delunardo F, Teggi A, Ortona E. Cystic echinococcosis: aspects of immune response, immunopathogenesis and immune evasion from the human host. *Endocr Metab Immune Disord Drug Targets* 2012; **12** (1): 16-23.
 - 28 Petrone L, Vanini V, Petruccioli E, Ettore GM, Busi Rizzi E, Schininà V, Girardi E, Ludovisi A, Gómez-Morales M, Pozio E, Teggi A, Goletti D. IL-4 specific-response in whole blood associates with human Cystic Echinococcosis and cyst activity. *J Infect.* 2015; **70** (3): 299-306
 - 29 Da Silva AM: Hydatid cyst/cystic echinococcosis: anatomical and surgical nomenclature and method to quantify the cyst content solidification. *Chin Med J (Engl)* 2011; **124** (18): 2806-12.

Peer reviewers: Isidoro Di Carlo, MD, PhD, Associate Professor of Surgery, Dpt of Surgical Sciences, Organ Transplantation and Advanced Technologies, Cannizzaro Hospital, University of Catania, Catania, Italy; Zaza Demetrasvili, MD, PhD, Assistant Professor of Surgical, Department of Tbilisi State Medical University, Tbilisi, Georgia.