

Difficulty of Delayed Laparoscopic Cholecystectomy After Endoscopic Retrograde Cholangiography Management of Choledocholithiasis

Shawkat S Gerges, Kamal A El-Atrebi

Shawkat S Gerges, Kamal A El-Atrebi, Departments of 1surgery, and 2internal medicine and hepatology, National Hepatology and Tropical Medicine Research Institute (NHTMRI), Cairo, Egypt
Correspondence to: Shawkat S. Gerges, 35 Ainshams St. Cairo, Egypt.

Email: shawkatgerges@gmail.com

Telephone: 201007904929

Received: June 28, 2015

Revised: July 24, 2015

Accepted: July 29, 2015

Published online: December 21, 2015

ABSTRACT

AIM: Cost effectively diagnosis of common bile duct stones (CBDS) and timing of management remains a topic of argument for the proper management of such condition. CBD clearance can be done by surgery (open or laparoscopic), endoscopy and lithotripsy. Moreover, the gallbladder which is mostly the source of the stones is indicated for cholecystectomy. This retrospective study is aimed to evaluate the difficulty of laparoscopic cholecystectomy (LC) done after more than 2 weeks period for patients underwent ERC to manage CBDS.

METHODS: The present study enrolled 99 (69 males and 30 females) patients, whom suffered from CBD stones. The patients were revised and the clinical records were presented at the National Hepatology and Tropical Medicine Research Institute (NHTMRI) - at surgery department, from May 2012 to November 2014.

RESULTS: Preoperative jaundice was positive in 33 patients (total serum bilirubin > 2 mg/dL), ERC was done to all patients and stent was placed in 24 patients. Surgery (LC) was delayed more than 2 weeks due to unfit for surgery 24, patient reluctance 27, and long waiting list 48 patients. During LC different grades of adhesions at Callot's triangle were reported as; grade I in 27, grade II in 42, grade III in 18, and grade IV in 12. Conversion to open surgery occurred in 33 patients. Mortality occurred in 3 patients and morbidity in 30 patients.

CONCLUSION: Concomitant or early LC (within 1 week) after ERC for CBDS is strongly recommended, otherwise, a high surgical expertise is advised to perform the procedure after that period.

© 2015 ACT. All rights reserved.

Key Words: CBD stones; ERC; Laparoscopic cholecystectomy

Gerges SS, El-Atrebi KA. Difficulty of Delayed Laparoscopic Cholecystectomy After Endoscopic Retrograde Cholangiography Management of Choledocholithiasis. *Journal of Gastroenterology and Hepatology Research* 2015; 4(12): 1873-1876 Available from: URL: <http://www.ghrnet.org/index.php/joghr/article/view/1534>

INTRODUCTION

Up to 20% of the general population are affected by biliary stones worldwide^[1,2]. 11 to 21% of patients are associated with common bile duct stones^[3-5]. Cost effectively diagnosis of common bile duct stones (CBDS) and timing of management remain a topic of argument for the proper management of such condition^[6-8]. CBD clearance can be done by surgery (open or laparoscopic), endoscopy and lithotripsy. Moreover, the gallbladder which is mostly the source of the stones is indicated for cholecystectomy. Several ways can accomplish this mission, as a one-step or two-step procedure, variously associating the above reported techniques^[9,10].

The present retrospective study is aimed to evaluate the difficulty of LC done after more than 2 weeks period for patients underwent ERC to manage CBDS.

PATIENTS AND METHODS

Between May 2012 and November 2014, clinical records of 99 patients presented to the National Hepatology and Tropical Medicine Research Institute (NHTMRI) - at surgery department unit B - who suffered from CBD stones, were revised. CBD stones diagnosis was

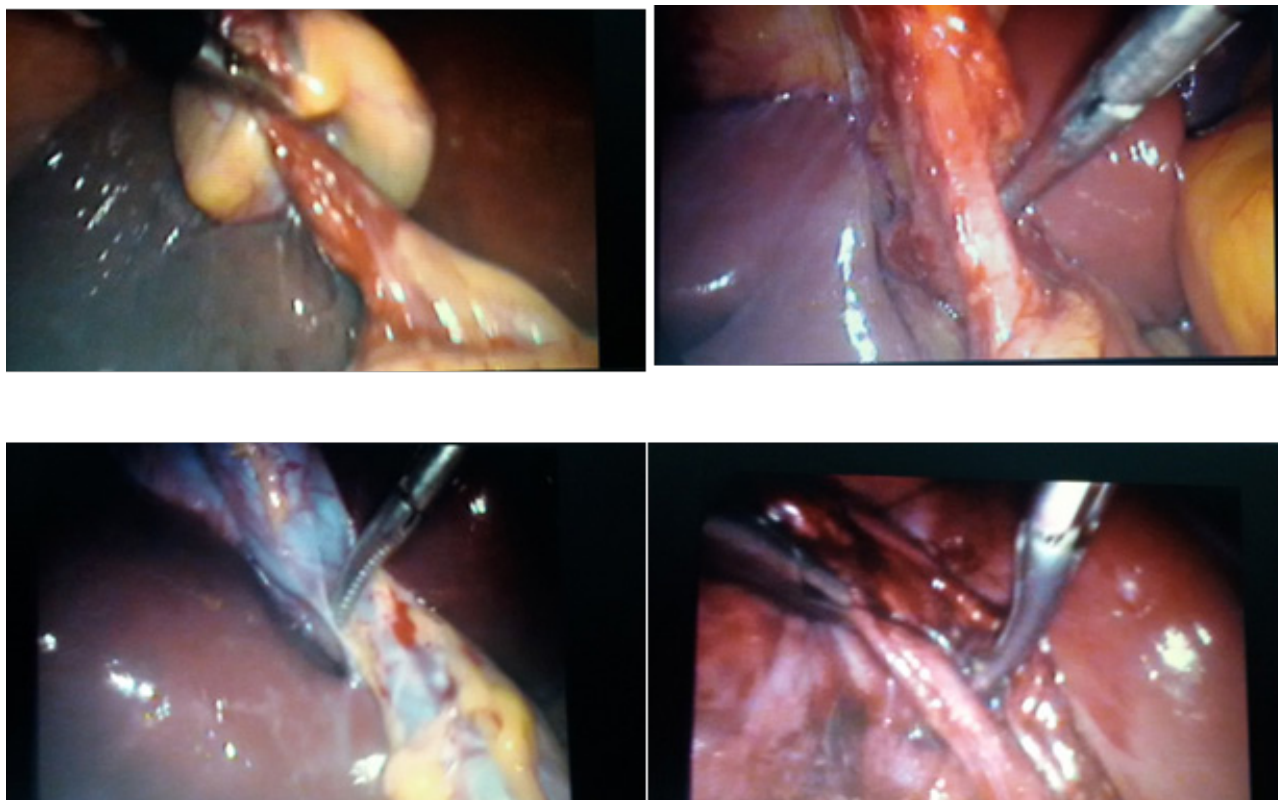


Figure 1 variable degrees of adhesions found at Calot's triangle during laparoscopic cholecystectomy.

approached by clinical symptoms (colicky pain, jaundice, cholangitis, and pancreatitis), serology (liver/pancreas enzymes) and ultrasound (CBD stones, CBD diameter > 6mm). All patients were referred to endoscopy department for ERC to confirm the diagnosis and deal with the CBD stones by papillosphincterotomy and stone extraction with or without stenting. All patients returned back to surgery department and had LC after more than 2 weeks period. LC was performed and/or supervised by senior staff surgeons of the unit.

Operations were carried out under general anesthesia, and standard laparoscopic procedure with the "critical view" dissection at the Calot's triangle was applied in all patients. Difficulty of safe dissection and degree of adhesions with or without presence of Mirizzi syndrome necessitating conversion to open surgery was judged by a senior surgeon according to the following staging classification shown in table 1.

RESULTS

The study included 99 patients with a median age of 59 years (range=38 to 75 years). They were 69 males and 30 females. Thirty three patients (33.3%) presented with obstructive jaundice. Calculus type (CBDS) was confirmed by abdominal ultrasound and/or CT scan. The remaining 66 patients (66.7%) presented with calculus cholecystitis without jaundice, however CBDS were suspected and diagnosed as previously mentioned in methods. All patients were subjected to ERC and PST, where CBDS were successfully removed using dormia basket or balloon extraction, and stents were placed in the CBD in 24 patients (24.2%). All patients were scheduled for LC; however the timing of operation was delayed more than 2 weeks. Causes of surgery delay were; unfitness for surgery and demand of medical preoperative preparation (24 cases 24.2%), patient reluctance due to social commitments (27 cases 27.3%), and long waiting list (48 cases

48.5%) (Table 2).

During surgery: Operative time ranged between 45 and 70 minutes with a mean of 60 minutes. Grades of adhesions encountered at Calot's triangle according to the previous classification were as follows; grade I (27 cases 27.3%), grade II (42 cases 42.4%), grade III (18 cases 18.2%), and grade IV (12 case 12.1%). Conversion to open surgery was necessary in 33 cases (33.3%); 12 with grade II, 9 with grade III, and all cases (12) with grade IV (Figure1). Indications for conversion to open surgery were, (1) unsuccessful dissection to identify anatomical features at Calot's triangle after more than 30 minutes (18 cases), (2) occurrence of complications bleeding (6 cases), CBD injury (9 cases), and both (6 cases).

Postoperative follow up: Mortality was encountered in 3 cases (3.03%), where CBD injury and bleeding occurred, and at open surgery bleeding was controlled and CBD was repaired on a T- tube. However, the cause of death-6 weeks later- was due to hepatic failure due to hepatic ischemia caused by massive hemorrhage occurred during surgery. Morbidity was encountered in 30 cases (30.3%) and ranged between: Biliary leak in 15 cases, 3 after conversion to open surgery, and 12 after LC. 9 cases resolved spontaneously, and the other 6 needed ERC and stent placement followed by resolving of leak, Subphrenic collection (abscess and/or hematoma) in 9 cases which were treated by sonar guided aspiration and pig tail drainage, and Wound infection occurred in 6 cases of the conversion group (Table 3).

DISCUSSION

CBD clearance can be done by surgery, endoscopy and lithotripsy. Moreover, the gallbladder which is mostly the source of the stones is indicated for cholecystectomy. Several ways can accomplish this mission, as a one-step or two-step procedure, variously associating the above reported techniques^[9,10].

Endoscopy		Management of synchronous gallbladder and CBD stones	
ERC	CBD clearance by endoscopic PST and/or Oddi sphincter dilation	Two steps	ERC followed by LC LC followed by ERC
		One step	“Rendez-vous” technique (synchronous ERC & LC)
Surgery			
Laparoscopy	Laparoscopic CBD clearance by trans-cystic/trans-CBD access	One step	
Open surgery	CBD clearance by PST through duodenotomy bilio-digestive anastomosis	One step	
Lithotripsy			
	Endoscopic mechanical Extracorporeal shock-wave Electrohydraulic Laser	Two steps	

Figure 2 algorithm for management options for common bile duct stones^[11]. CBD: Common bile duct; ERC: Endoscopic retrograde cholangiography; LC: Laparoscopic cholecystectomy; PST: Papillosphincterotomy.

Costi *et al*^[11], proposed an algorithm for management options for CBDS (figure 2).

In spite of the encouragement for laparoscopic CBD clearance by the British Society of Gastroenterology guidelines for the management of biliary stones^[12], the common practice shows that only 20% of American surgeons regularly perform laparoscopic CBD exploration^[13,14], and the vast majority prefer pre-operative ERC^[14]. The reasons for the previous limitation are the necessary learning curve for such infrequent procedure, and the non reproducibility of results in elective patients by referral centres^[15].

ERC followed by endoscopic sphincterotomy has become the most widely used method for CBD stones treatment^[16,17].

Timing for ERC is a matter of debate, whether to be performed before, after, or even during cholecystectomy, according to the so-called “rendez-vous technique”.

Preoperative ERC^[8,9,18,19] has a drawback of needing a second surgical procedure to treat gallstones (cholecystectomy), however it gives the advantage for strategy update if endoscopic sphincterotomy is successful, thus cholecystectomy will complete the management of CBDS, if not, a second step of surgical procedure aimed at cholecystectomy and CBD clearance will be needed.

Performing ERC after cholecystectomy^[20-23] is also a “two step management” of CBDS, with the advantage of performing ERC in highly suspected patients, thus reducing to a minimum any possible ERC-related complications and costs. However, a great disadvantage of needing third surgical procedure in case postoperative ERC fails still exists.

The rendez-vous technique^[9,19,24,25] involves CBDS diagnosis and the synchronous management of both gallstones and CBDS during the same procedure (“one step”), although it needs the systematic availability of dedicated instrumentation and a second team to perform intra-operative ERC whenever IOC/laparoscopic US shows CBDS.

Table 1 grade of adhesions at Calot’s triangle.

Grade I:	contracted gallbladder but still well defined Calot’s triangle
Grade II:	contracted gallbladder with adhesions obscuring Calot’s triangle
Grade III:	adhesions between the gallbladder and common hepatic duct (CHD) but still dissectible from each other (Mirizzi type I, II)
Grade IV:	contracted gallbladder non separable from CHD (Mirizzi type III, IV)

Table 2 Patients preoperative characteristics.

Median age range	59 years (38-75 years)
Sex:	Male, 69 (69.7%) Female, 30 (30.3%)
Preoperative clinical presentation:	Jaundiced, 33(33.3%) Non-jaundiced, 66 (66.7%)
Preoperative ERC	Stone extraction, 99(100%) Stent placement, 24(24.2%)
Causes of surgery delay >2weeks	Unfitness for surgery, 24(24.2%) Patient reluctance, 27(27.3%) Long waiting list, 48(48.5%)

Table 3 Patients operative and postoperative data.

Operative time (minutes)	60 (45 - 70)
Adhesions at Calot’s triangle	
Grade I	27(27.3%)
Grade II	42 (42.4%)
Grade III	18(18.2%)
Grade IV	12(12.1%)
Conversion to open Cholecystectomy	33 (33.3%)
Mortality	3 (3.03%)
Morbidity	30(30.3%)
Biliary leak	15(15.15%)
Subphrenic collection	9(9.09%)
Wound infection	6(6.06%)

In this study we reviewed the medical records of 99 patients who presented to our institute with CBDS. All patients were managed according to a fixed protocol, where suspicion of diagnosis by laboratory investigations and abdominal sonar was followed by referral to the endoscopy unit to perform ERC. The role of ERC was dual, first to confirm the presence of CBDS and second to deal with it by stone extraction (using dormia basket or balloon extraction) and PST with or without stent placement.

All patients returned back to surgery department to have LC. Timing of operation was noticeably delayed for more than 2 weeks in this series of patients. Cause of the delay was multi-factorial either related to the patient due to improper medical fitness for surgery necessitating long preparation or long waiting list in the surgery department.

At operation, operative details were analyzed where the difficulty of the procedure (LC) was judged according to degree of adhesions encountered during Calot’s triangle dissection to ensure a safe critical view technique. Adhesions were classified into 4 grades as mentioned in Table 1. Operative time was noticed to be longer. Also, the rate of conversion to open surgery in this group of patients was 33.3% which is relatively higher than the regular rate in ordinary circumstances.

Post operative follow up revealed higher rates of morbidity especially concerning biliary leakage and subphrenic collection. Mortality was also encountered in 3 cases due to acute hepatic failure secondary to intra-operative hepatic ischemia- which is relatively a rare complication after LC.

CONCLUSION

Delayed LC after ERC management of CBDS is associated with a higher rate of complications due to development of adhesions around

the CBD. Concomitant or early LC (within 1 week) after ERC for CBDS is strongly recommended, otherwise, a high surgical expertise is advised to perform the procedure in case of delay.

REFERENCES

1. Everhart JE, Khare M, Hill M, Maurer KR. Prevalence and ethnic differences in gallbladder disease in the United States. *Gastroenterology* 1999; **117**(3): 632–639.
2. Aerts R, Penninckx F. The burden of gallstone disease in Europe. *Aliment Pharmacol Ther* 2003; **18 Suppl 3**: 49–53.
3. Menezes N, Marson LP, debeaux AC, Muir IM, Auld CD. Prospective analysis of a scoring system to predict choledocholithiasis. *Br J Surg* 2000; **87**(9): 1176–1181.
4. Videhult P, Sandblom G, Rasmussen IC. How reliable is intraoperative cholangiography as a method for detecting common bile duct stones?: A prospective population-based study on 1171 patients. *Surg Endosc* 2009; **23**(2): 304–312.
5. Borzellino G, Rodella L, Saladino E, Catalano F, Politi L, Minicozzi A, Cordiano C. Treatment for retained [corrected] common bile duct stones during laparoscopic cholecystectomy: the rendezvous technique. *Arch Surg* 2010; **145**(12): 1145–1149.
6. ASGE Standards of Practice Committee, Maple JT, Ben-Menachem T, Anderson MA, Appalaneni V, Banerjee S, Cash BD, Fisher L, Harrison ME, Fanelli RD, Fukami N, Ikenberry SO, Jain R, Khan K, Krinsky ML, Strohmeyer L, Dominitz JA. The role of endoscopy in the evaluation of suspected choledocholithiasis. *Gastrointest Endosc* 2010; **71**(1): 1–9.
7. Prat F, Meduri B, Ducot B, Chiche R, Salimbeni-Bartolini R, Pelletier G. Prediction of common bile duct stones by noninvasive tests. *Ann Surg* 1999; **229**(3): 362–368.
8. Sarli L, Costi R, Gobbi S, Iusco D, Sgobba G, Roncoroni L. Scoring system to predict asymptomatic choledocholithiasis before laparoscopic cholecystectomy. A matched case-control study. *Surg Endosc* 2003; **17**(9): 1396–1403.
9. Morino M, Baracchi F, Miglietta C, Furlan N, Ragona R, Garbarini A. Preoperative endoscopic sphincterotomy versus laparoendoscopic rendezvous in patients with gallbladder and bile duct stones. *Ann Surg* 2006; **244**(6): 889–893; discussion 893–896.
10. Chang WH, Chu CH, Wang TE, Chen MJ, Lin CC. Outcome of simple use of mechanical lithotripsy of difficult common bile duct stones. *World J Gastroenterol* 2005; **11**(4): 593–596.
11. Renato Costi, Alessandro Gnocchi, Francesco Di Mario, and Leopoldo Sarli. Diagnosis and management of cholidocholithiasis in the golden age of imaging, endoscopy and laparoscopy. *World J Gastroenterol* 2014; **20**(37): 13382–13401.
12. Williams EJ, Green J, Beckingham I, Parks R, Martin D, Lombard M. Guidelines on the management of common bile duct stones (CBDS) Gut. 2008; **57**(7): 1004–1021.
13. Poulouse BK, Arbogast PG, Holzman MD. National analysis of in-hospital resource utilization in choledocholithiasis management using propensity scores. *Surg Endosc* 2006; **20**(2): 186–190.
14. Bingener J, Schwesinger WH. Management of common bile duct stones in a rural area of the United States: results of a survey. *Surg Endosc* 2006; **20**(4): 577–579.
15. De Palma GD. Minimally invasive treatment of cholecystocholedochal lithiasis: The point of view of the surgical endoscopist. *World J Gastrointest Surg* 2013; **5**(6): 161–166.
16. Barwood NT, Valinsky LJ, Hobbs MS, Fletcher DR, Knuiman MW, Ridout SC. Changing methods of imaging the common bile duct in the laparoscopic cholecystectomy era in Western Australia: implications for surgical practice. *Ann Surg* 2002; **235**(1): 41–50.
17. Ghazi A, McSherry CK. Endoscopic retrograde cholangiopancreatography and sphincterotomy. *Ann Surg* 1984; **199**(1): 21–27.
18. Tzovaras G, Baloyiannis I, Zachari E, Symeonidis D, Zacharoulis D, Kapsoritakis A, Paroutoglou G, Potamianos S. Laparoendoscopic rendezvous versus preoperative ERCP and laparoscopic cholecystectomy for the management of cholecysto-choledocholithiasis: interim analysis of a controlled randomized trial. *Ann Surg* 2012; **255**(3): 435–439.
19. Clayton ES, Connor S, Alexakis N, Leandros E. Meta-analysis of endoscopy and surgery versus surgery alone for common bile duct stones with the gallbladder in situ. *Br J Surg* 2006; **93**(10): 1185–1191.
20. Nathanson LK, O'Rourke NA, Martin IJ, Fielding GA, Cowen AE, Roberts RK, Kendall BJ, Kerlin P, Devereux BM. Postoperative ERCP versus laparoscopic choledochotomy for clearance of selected bile duct calculi: a randomized trial. *Ann Surg* 2005; **242**(2): 188–192.
21. Ammori BJ, Birbas K, Davides D, Vezakis A, Larvin M, McMahon MJ. Routine vs “on demand” postoperative ERCP for small bile duct calculi detected at intraoperative cholangiography. Clinical evaluation and cost analysis. *Surg Endosc* 2000; **14**(12): 1123–1126.
22. Rhodes M, Sussman L, Cohen L, Lewis MP. Randomised trial of laparoscopic exploration of common bile duct versus postoperative endoscopic retrograde cholangiography for common bile duct stones. *Lancet* 1998; **351**(9097): 159–161.
23. Erickson RA, Carlson B. The role of endoscopic retrograde cholangiopancreatography in patients with laparoscopic cholecystectomies. *Gastroenterology* 1995; **109**(1): 252–263.
24. Zang JF, Zhang C, Gao JY. Endoscopic retrograde cholangiopancreatography and laparoscopic cholecystectomy during the same session: feasibility and safety. *World J Gastroenterol* 2013; **19**(36): 6093–6097.
25. Di Mauro D, Faraci R, Mariani L, Cudazzo E, Costi R. Rendezvous technique for cholecystocholedochal lithiasis in octogenarians: is it as effective as in younger patients, or should endoscopic sphincterotomy followed by laparoscopic cholecystectomy be preferred? *J Laparoendosc Adv Surg Tech A* 2014; **24**(1): 13–21.

Peer reviewers: Jeng Kuo-Shyang, Professor of Surgery, Vice President of Far Eastern Memorial Hospital, New Taipei City, Taiwan; Yuedong Wang, MD, PhD, FACS, Department of Laparoscopic and Gastrointestinal Surgery, Second Affiliated Hospital of Zhejiang University School of Medicine, Hangzhou, China.