

# Surgical Treatment of Pancreatic Head Cancer and Perioperative Management in High Thromboembolic Risk Patients With Recent Drug-Eluting Coronary Stent Implantation

Takahisa Fujikawa, Yasunori Yoshimoto, Akira Tanaka

Takahisa Fujikawa, Yasunori Yoshimoto, Akira Tanaka, Department of Surgery, Kokura Memorial Hospital, Kitakyushu, Fukuoka 802-8555, Japan

Correspondence to: Takahisa Fujikawa, MD, PhD, FACS, Department of Surgery, 3-2-1 Asano, Kokurakita-ku, Kitakyushu, Fukuoka 802-8555, Japan

Email: [fujikawa-t@kokurakinen.or.jp](mailto:fujikawa-t@kokurakinen.or.jp)

Telephone: +81-93-511-2000 Fax: +81-93-511-3240

Received: January 3, 2016 Revised: March 6, 2016

Accepted: March 9, 2016

Published online: April 21, 2016

## ABSTRACT

Patients with multiple coronary artery diseases, especially with recent implantation of a drug-eluting coronary stent (DES), require strong dual antiplatelet therapy and regarded as those with very high thromboembolic risks. When these patients undergo major abdominal surgery for malignancy, perioperative risks including bleeding and thromboembolic risks have to be balanced against oncological radicality. We performed successful management of 81-year-old man suffering locally advanced pancreatic head cancer detected just after recent DES implantation. Curative-intent pancreaticoduodenectomy under preoperative continuation of aspirin monotherapy is safe and feasible, and is considered to be one of the promising options for the treatment of such complicated patients.

© 2016 The Authors. Published by ACT Publishing Group Ltd.

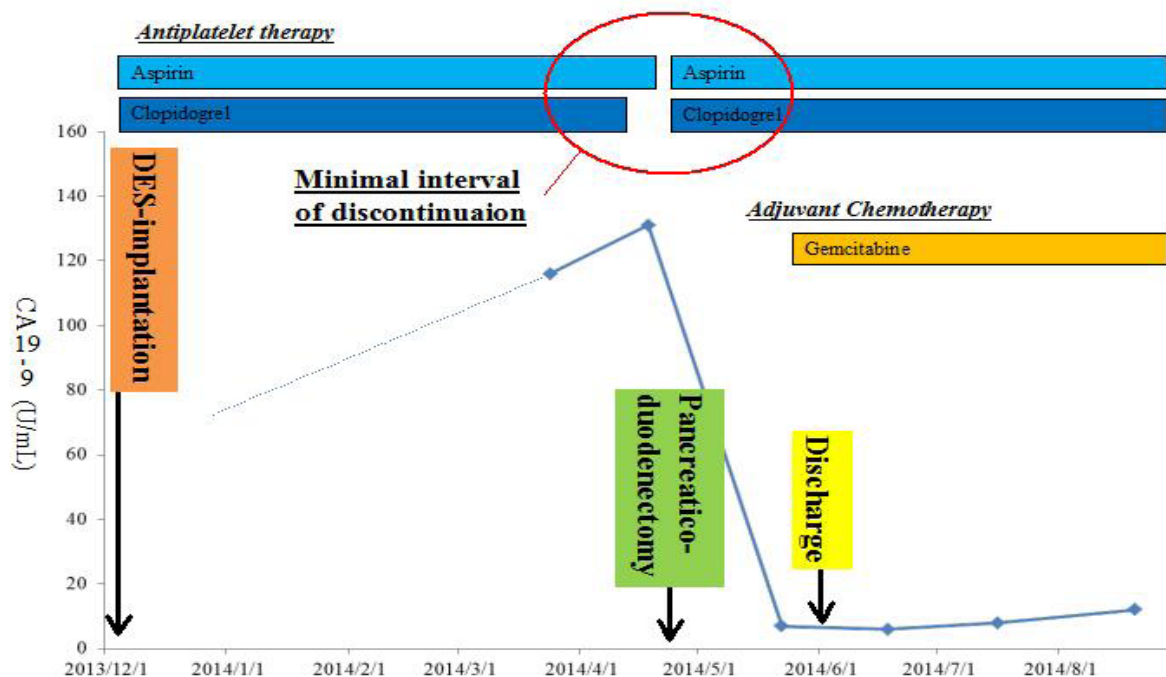
**Key Words:** Pancreatic head cancer; High thromboembolic risk; drug-eluting coronary stent implantation; Dual antiplatelet therapy; Perioperative management

Fujikawa T, Yoshimoto Y, Tanaka A. Surgical Treatment of Pancreatic Head Cancer and Perioperative Management in High

Thromboembolic Risk Patients With Recent Drug-Eluting Coronary Stent Implantation. *Journal of Gastroenterology and Hepatology Research* 2016; 5(2): 2041-2042 Available from: URL: <http://www.ghrnet.org/index.php/joghr/article/view/1554>

## LETTER TO THE EDITOR

An 81-year-old man with a long-term history of diabetes mellitus, grade 4 chronic kidney disease and repeated stent placement of coronary artery disease, underwent another implantation of drug-eluting coronary stent (DES) and received dual antiplatelet therapy (APT) with aspirin and clopidogrel. Four months later, he was admitted to our hospital for progressive jaundice and was diagnosed with pancreatic head cancer invading the duodenum and bile duct without any distant metastasis. Endoscopic placement of internal biliary stent was performed without any complications. Surgeons and cardiologists discussed how best to manage this extremely high thromboembolic risk patient having locally advanced pancreatic head cancer. Considering the balance between perioperative bleeding and thromboembolic risks, a curative surgical intervention under continuation of preoperative single antiplatelet therapy with aspirin was considered to be the most preferred strategy to avoid critical coronary stent thrombosis. After informing benefits and risks of the scheduled therapy, the patient agreed with the strategy. Preoperative antithrombotic management consisted of discontinuation of clopidogrel 7 days prior to surgery and continuation of aspirin monotherapy until surgery (Figure 1). During the operation, meticulous dissection and hemostasis were performed using coagulating shears and monopolar dissecting sealers due to possible antiplatelet-induced bleeding tendency. Subtotal stomach-preserving pancreaticoduodenectomy with regional lymph node dissection was carried out without experiencing any intractable bleeding requiring platelet transfusion. His dual APT was reinstated on postoperative day 2, and the patient recovered soon postoperatively without any thromboembolic or bleeding complications (Figure 1).



**Figure 1** Perioperative clinical course of the current patient with serial changes in serum CA19-9 values. Surgical intervention was successfully performed under preoperative continuation of aspirin monotherapy, without any severe bleeding or thromboembolic complications. A red circle showed minimal interval of antiplatelet discontinuation during the surgical intervention.

Pancreaticoduodenectomy for pancreatic head cancer is one of the most difficult abdominal procedures and is associated with major intraoperative and postoperative bleeding and thromboembolic complications<sup>[1,2]</sup>. Although several months after DES implantation have passed in the current case and the timing of the operation was relatively lower risk category for stent thrombosis, it is favourable to delay such highly invasive surgery for at least 6 months after DES implantation but oncologically the surgery should not be delayed<sup>[3,4]</sup>. In this situation, a dilemma of how to manage two difficult conditions occurs perioperatively like the current case; management of intraoperative and postoperative bleeding during surgical treatment of locally advanced pancreatic head cancer, and perioperative prevention of coronary stent thrombosis<sup>[1,5]</sup>. Perioperative antithrombotic management in APT-burdened patients with high thromboembolic risks who undergo pancreaticoduodenectomy is always challenging; the potential risk of thromboembolic complications may increase when APT is halted during the operation, but intraoperative haemorrhage or postoperative bleeding might occur more frequently when preoperative APT is continued<sup>[1,6]</sup>. Rigorous perioperative antithrombotic management, as well as meticulous intraoperative dissection and hemostases using a variety of vessel-sealing devices, is required in such a troublesome situation. Recently, we showed feasibility and safety of abdominal surgery, either open or laparoscopic, under preoperative continuation of single APT with aspirin in case of patients with high thromboembolic risks<sup>[1,6]</sup>. In the present case, pancreaticoduodenectomy with regional lymph node dissection was also safely performed with neither bleeding nor thromboembolic complications under continuation of preoperative aspirin monotherapy. Thus, this strategy is one of the preferred options for compromised patients like our case.

## CONFLICT OF INTERESTS

There are no conflicts of interest with regard to the present study.

## REFERENCES

1. Fujikawa T, Tanaka A, Abe T, et al. Effect of antiplatelet therapy on patients undergoing gastroenterological surgery: Thromboembolic risks versus bleeding risks during its perioperative withdrawal. *World J Surg* 2015;39:39-149.
2. Fujikawa T, Tanaka A. Successful multidisciplinary treatment of hilar cholangiocarcinoma in a patient with complicated new-onset coronary artery disease. *BMJ Case Rep* 2014. doi:10.1136/bcr-2014-203941.
3. Grines CL, Bonow RO, Casey DE Jr, et al. Prevention of premature discontinuation of dual antiplatelet therapy in patients with coronary artery stents. *Circulation* 2007;115:813-818.
4. Iakovou I, Schmidt T, Bonizzi E, et al. Incidence, predictors, and outcome of thrombosis after successful implantation of drug-eluting stents. *JAMA* 2005;293:2126-30.
5. Thachil J, Gatt A, Martlew V. Management of surgical patients receiving anticoagulation and antiplatelet agents. *Br J Surg* 2008;95:1437-1448.
6. Fujikawa T, Tanaka A, Abe T, Yoshimoto Y, Tada S, Maekawa H, Shimoike N. Does antiplatelet therapy affect outcomes of patients receiving abdominal laparoscopic surgery? Lessons from more than 1,000 laparoscopic operations in a single tertiary referral hospital. *J Am Coll Surg* 2013;217:1044-1053.

**Peer reviewer:** Premashish Halder, Professor, Head Of Department Of Gastrointestinal Surgery, Jagjivanram Hospital, Maratha Mandir Lane, Mumbai Central, Mumbai - 400 008. India.