

## Ascites Due to Subserosal Type of Eosinophilic Gastroenteritis: A Case Report

Hasan S. Mahmoud

Hasan S. Mahmoud, Department of Tropical Medicine and Gastroenterology, Qena Faculty of Medicine, South Valley University, Egypt

Correspondence to: Hasan S. Mahmoud, Department of Tropical Medicine and Gastroenterology, Qena Faculty of Medicine, South Valley University, Egypt.

Email: [hasan\\_sedeek@yahoo.com](mailto:hasan_sedeek@yahoo.com)

Telephone: +201061648665

Received: November 15, 2015      Revised: January 4, 2016

Accepted: January 8, 2016

Published online: January 19, 2016

*Hepatology Research* 2016; 5(1): 1941-1943 Available from: URL: <http://www.ghrnet.org/index.php/joghr/article/view/1574>

### INTRODUCTION

Eosinophilic gastroenteritis (EGE) is a rare condition, it is defined as a disorder primarily affecting the gastrointestinal tract with eosinophil-rich inflammation, in the absence of known causes of eosinophilia (e.g. drug reactions, parasitic infections or malignancy)<sup>[1]</sup>. Three different forms of EGE can be distinguished: mucosal disease, muscle layer disease and subserosal disease. The symptoms of EGE are related to the layer involved. Mucosal disease is the most common form and presents with nonspecific symptoms such as abdominal pain, nausea, vomiting, diarrhea or malabsorption. The second form, muscle layer disease, is a more serious form that presents with symptoms due to intestinal obstruction. The third form, subserosal disease, is uncommon and presents with ascites<sup>[2-3]</sup>.

### CASE REPORT

51 years old male patient presented by abdominal pain, mainly central and upper abdominal, of gradual onset and intermittent course of two weeks duration. It was colicky in nature not referred or radiated, moderate in severity, not related to meal. No other upper gastro-intestinal symptoms. Also patient suffered from diarrhea of gradual onset and intermittent course of the same duration, five time per day, yellow offensive in odour, no blood or tenismus with little mucous. No other lower GI symptoms or fever. Stool analysis showed presence of pus cell 15-20, RBC 25-30, mucous (+), bacteria (+++); G -ve enterococci and E. Histolytica cyst so patient received ciprofloxacin and tinidazole and diloxanide furoate followed by complete improvement of diarrhea with normal follow up stool analysis. Patient suffered previously from diarrhea twice; 2 and 1.5 years ago, relieved also by ciprofloxacin. Examination showed that general, head and neck, upper and lower limbs, chest and heart and neurological examination were clinically free. Abdominal examination

### ABSTRACT

Eosinophilic gastroenteritis (EGE) is an uncommon disease characterized by eosinophilic infiltration of the gastrointestinal tract. It is most often a component of systemic eosinophilia. EGE may involve more than one layer of the gastrointestinal tract (mucosa, muscle layer or serosa). Clinical manifestations depend on the layer and location of infiltration. Mucosal involvement leads to protein-losing enteropathy and malabsorption. Involvement of the muscle layer typically produces intestinal obstruction. Subserosal infiltration causes eosinophilic ascites. I present a 51 year old male patient with progressive ascites due to subserosal type of EGE which was diagnosed after complete history, examinations and investigation. Patient was treated with prednisolone with marvellous response. Ascites disappeared completely with steroid therapy.

© 2016 ACT. All rights reserved.

**Key Words:** Ascites; Subserosal; Eosinophilic gastroenteritis; Eosinophilia; Steroid

Mahmoud HS. Ascites Due to Subserosal Type of Eosinophilic Gastroenteritis: A Case Report. *Journal of Gastroenterology and*

by inspection it showed just diffuse abdominal enlargement with full flanks. No organomegaly and positive shifting dullness indicating moderate amount of free ascites. Investigations including complete blood count and serum IgE level showed leucocytosis and eosinophilia with marked elevation of serum Ig E level; this is illustrated in table 1. Chemical laboratory investigation showed that total serum protein 5.63 g/dL, serum albumin 3.44 g/dL, serum creatinine 1.1 mg/dL and blood urea 22 mg/dL. Total serum bilirubin was 0.3 mg/dl and normal liver enzymes. Abdominal US and CT scan showed marked amount of free ascites; this is shown in figure 1, otherwise normal findings were detected. Diagnostic aspiration was done for peritoneal fluid study, cytological and pathological examination. Ascitic fluid study showed that it was turbid and yellow in color. Its protein level was 5.6 g/dl, ascitic albumin was 3.24 g/dl and total WBC was 13100 cell/ml with differential count showed that eosinophils represent 88%, Macrophages 5%, lymphocytes 5% and polymorphs 2%. Z.N. stained film for T.B was negative. Serum ascitic albumin gradient was 0.2 g/dL indicating non-portal hypertension cause. Pathological and cytological examination of the films and sections from the block prepared from the centrifugate of the fluid revealed scattered red cells and lymphocytes, few mesothelial cells and eosinophilic proteinaceous material. No evidence of cytological atypia or malignancy; this is shown in figure 2. Patient refused to do endoscopic examination at all. Patient treated with prednisolone 40 mg/ day for two weeks and follow up abdominal US was done with complete disappearance of ascites; this is shown in figure 3. Then we started gradual withdrawal of corticosteroid with no appearance of ascites again. Peripheral eosinophil counts reached normal value, 2%, and Serum Ig E also showed normal level, 89 IU/ml, after one month of therapy.

## DISCUSSION

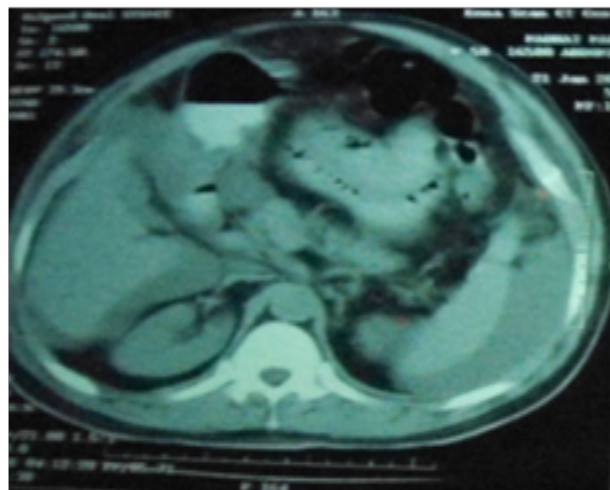
EGE is an uncommon disease characterized by eosinophilic infiltration in the gastrointestinal tract. The infiltration may involve one or more layers of the gastrointestinal wall and other abdominal organs<sup>[2-3]</sup>.

The pathogenesis of this disease is poorly understood, but speculation has focused on the selective release of eosinophil major proteins leading to the intestinal epithelial damage. Keshavarzian et al. demonstrated that the number of activated granulated eosinophils in the mucosa correlated with the severity of EGE<sup>[4]</sup>. Several reports have pointed to a possible role of allergies to food and other allergens<sup>[5-6]</sup>, while other investigators have refuted an allergic reaction as the etiology of this disease<sup>[6-7]</sup>. In the current case, Ig E level was markedly elevated and decreased to normal value after therapy, supporting the allergic theory.

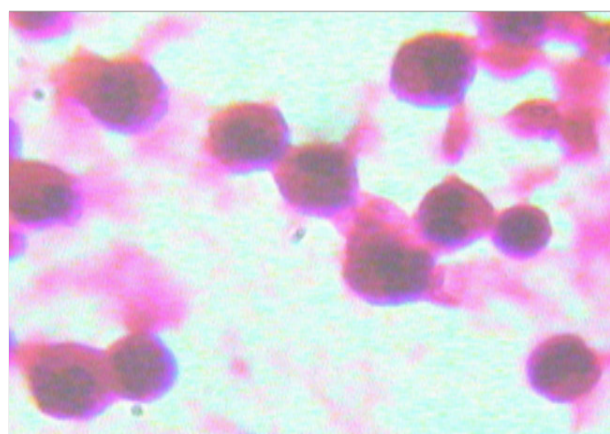
In a retrospective study of 40 patients, the most common symptoms were abdominal pain, nausea, vomiting, and diarrhea. In that study, the percentage of involving mucosal layer, muscle layer and subserosal disease were 58%, 30% and 12% respectively<sup>[8]</sup>.

**Table 1** Complete blood count and Ig E level before treatment.

Parameter	Value
RBC	$6.5 \times 10^6$ /uL
HGB	16 g/dL
PLT	$436 \times 10^3$ /uL
WBC	$29.2 \times 10^3$ /uL
eosinophils	27%
neutrophils	65%
lymphocytes	8%
Serum Ig E	2,805 IU/mL

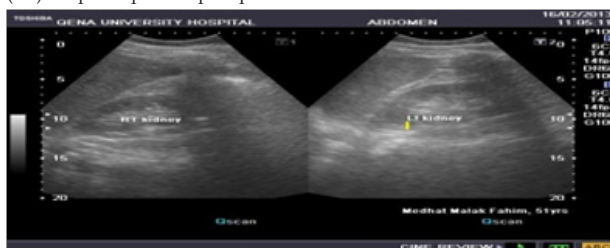


**Figure 1** CT scan showing the presence of ascites.

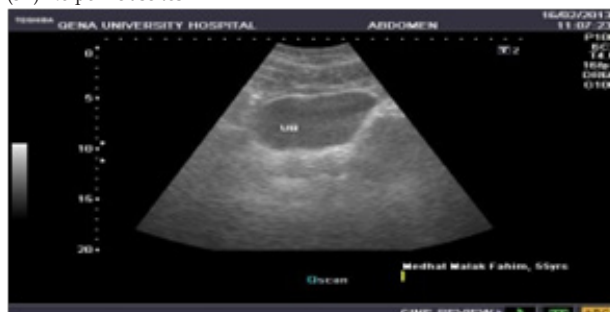

**Figure 2** Sections for cytological examination of the centrifugated ascitic fluid revealed scattered red cells and lymphocytes, few mesothelial cells and eosinophilic proteinaceous material. No evidence of cytological atypia or malignancy.

(3A) No perihepatic or perisplenic ascites



(3B) No pelvic ascites



**Figure 3** (A, B). Abdominal US was done after 2 wks of treatment with complete disappearance of ascites.

Talley *et al* reported that the patients with subserosal disease could be distinguished from the other two groups by clinical symptoms (abdominal bloating, ascites), higher eosinophils counts, and their dramatic responses to steroid therapy<sup>[8]</sup>. The diagnostic feature of subserosal disease is a marked eosinophilia, up to 88 percent, in the ascitic fluid<sup>[5]</sup>. In the current case report, patient presented with moderate ascites and high eosinophilic count in the ascetic fluid. This picture may be confused with cirrhotic ascites or abdominal carcinomatosis. Fortunately, marked eosinophilia in the ascites is an important clue to get the diagnosis of subserosal EGE.

Hypereosinophilia in peripheral blood is present in 20-90% of patients with EGE<sup>[8]</sup>. Thus, the absence of peripheral hypereosinophilia should not exclude the diagnosis of EGE in patients with unexplained gastrointestinal symptoms. Radiologically, the hallmark of EGE is the thickening of mucosal folds demonstrated by barium study<sup>[5,7,9]</sup>, computerized tomography<sup>[10,11]</sup>, or ultrasound<sup>[10,12]</sup>, depending on the severity and layer(s) involved<sup>[9]</sup>. However, similar thickening may also be seen in Menetrier's disease, lymphoma, Crohn's disease, and granulomatous disease. Thus, the thickening of bowel wall is not specific for EGE.

The endoscopic appearance in EGE is also nonspecific, including erythematous, friable, nodular, and occasional ulcerative changes. The definite diagnosis of EGE must fulfill the following criteria: (1) the presence of gastrointestinal symptoms; (2) demonstration of eosinophilic infiltration of one or more areas of the GI tract on biopsy; (3) no evidence of parasitic or extraintestinal disease (4). So the diagnosis of this case was established by symptoms, eosinophilic proteinaceous material infiltration; detected by pathological examination of the ascitic fluid, and marked elevation of the eosinophilic count in the ascitic fluid. So decision for treatment was taken and patient started steroid therapy.

In this case, patient was treated with steroid therapy for two weeks and ascites disappeared completely, then gradual withdrawal of the drug was taken. Follow up abdominal US after one and two month of stoppage of treatment revealed no ascites. In general, the clinical response of EGE to steroid treatment is usually dramatic<sup>[5,8,14,15]</sup>. The appropriate duration of steroid treatment remains unknown, but improvement usually occurs within two weeks regardless of the layer of bowel involved<sup>[9]</sup>. But some patients require more prolonged therapy (up to several months) to induce resolution of symptoms<sup>[13]</sup>. Patients with refractory relapsing disease may require long-term low-dose steroids or immunosuppressive therapy.

In conclusion, subserosal type of EGE presenting as ascites is a rare disease. High eosinophilic count in ascitic fluid study is helpful in the diagnosis of EGE with subserosal involvement. Response to steroid therapy is marvellous.

## CONFLICT OF INTERESTS

The authors declare that they do not have conflict of interests.

## REFERENCES

- 1 Rothenberg ME. Eosinophilic gastrointestinal disorders (EGEID). *J Allergy Clin Immunol* 2004; **113**(1): 11-28.
- 2 Naylor AR. Eosinophilic gastroenteritis. *Scot Med J* 1990; **35**: 163-5.
- 3 Cello JP. Eosinophilic gastroenteritis: A complex disease entity. *Am J Med* 1979; **67**: 1097-104.
- 4 Keshavarzian A, Savarymattu S, Tai PC, et al. Activated eosinophils in familial eosinophils in familial eosinophilic gastroenteritis. *Gastroenterology* 1985; **88**: 1041-9.
- 5 Klein NC, Hargrove RL, Sleisenger MH, Jeffries GH. Eosinophilic gastroenteritis. *Medicine* 1970; **40**: 299-319.
- 6 Caldwell JH, Sharma HM, Hurtubise PE, Colwell DL. Eosinophilic gastroenteritis in extreme allergy. Immunopathological comparison with nonallergic gastrointestinal disease. *Gastroenterology* 1979; **77**: 560-4.
- 7 Leinbach GE, Rubin CE. Eosinophilic gastroenteritis: A simple reaction to food allergens? *Gastroenterology* 1970; **59**: 874-89.
- 8 Talley MJ, Shorter RG, Phillips SF, Zinsmeister AR. Eosinophilic gastroenteritis: a clinicopathological study of patients with disease of the mucosa, muscle layer, and subserosal tissues. *Gut* 1990; **31**: 45-58.
- 9 MacCarty RL, Talley NJ. Barium studies in diffuse eosinophilic gastroenteritis. *Gastrointest Radiol* 1990; **15**: 183-7.
- 10 Rumans MC, Leiberman DA. Eosinophilic gastroenteritis presenting with biliary and duodenal obstruction. *Am J Gastroenterol* 1987; **82**: 775-8.
- 11 Tai YG, Liu JD, Lin KY, et al. Eosinophilic gastroenteritis with eosinophilic ascites: Report of a case. *J Formosan Med Assoc* 1990; **89**: 901-4.
- 12 Farahvash MJ, Bastani B, Farahvash MR, Irvanlou G. Eosinophilic gastroenteritis presenting with biliary and partial duodenal obstruction. *Am J Gastroenterol* 1990; **85**: 1022-4.
- 13 Lee CM, Changchien CS, Chen PC, et al. Eosinophilic gastroenteritis: 10 years experience. *Am J Gastroenterol* 1993; **88**: 70-4.
- 14 Malagarnera M, Restuccia N, Pistone G, et al. Eosinophilic gastroenteritis. *Eur J Gastroenterol Hepatol* 1997; **9**: 533-7.
- 15 Liacouras CA, Wenner WJ, Brown K, Ruchelli E. Primary eosinophilic esophagitis in children: successful treatment with oral corticosteroids. *J Pediatr Gastroenterol Nutr* 1998; **26**: 380-5.

**Peer reviewers:** Andrew Stewart Day, Department of Paediatrics University of Otago, Christchurch, Christchurch, New Zealand; Nasser hamed Mousa, Associate Professor, Tropical Medicine and Hepatology, Mansoura University, Mansoura City, Egypt.