

Hepatocellular Carcinoma with Recurrent Extrahepatic Metastases: A Case of Long-term Survival

Masayuki Nakanowatari, Takahiro Sato, Takashi Hasegawa, Tomohiro Arakawa, Yasuaki Kuwata, Takumi Ohmura, Yoshiyasu Karino

Masayuki Nakanowatari, Department of Palliative Care Medicine, Sapporo Kosei General Hospital, Sapporo, Japan

Takahiro Sato, Tomohiro Arakawa, Yasuaki Kuwata, Takumi Ohmura, Yoshiyasu Karino, Department of Gastroenterology, Sapporo Kosei General Hospital, Sapporo, Japan

Takashi Hasegawa, Department of Radiology, Sapporo Kosei General Hospital, Sapporo, Japan

Correspondence to: Masayuki Nakanowatari, Department of Palliative Care Medicine, Sapporo Kosei General Hospital, Kita3 Higashi 8-5, Chuo-ku, Sapporo, Hokkaido 060-0033, Japan.

E-mail: m.nakanowatari@ja-hokkaidoukouseiren.or.jp

Telephone: +81-11-261-5331 Fax: +81-11-271-5320

Received: February 6, 2016 Revised: March 18, 2016

Accepted: March 22, 2016

Published online: April 21, 2016

and lymph node metastases, but received multidisciplinary treatment, including TACE, PEI, and RFA, and survived for 12 years.

© 2016 The Authors. Published by ACT Publishing Group Ltd.

Key Words: Hepatocellular carcinoma; Extrahepatic metastasis; Adrenal metastasis; Lymph node metastasis; Survival

Nakanowatari M, Sato T, Hasegawa T, Arakawa T, Kuwata Y, Ohmura T, Karino Y. Hepatocellular Carcinoma with Recurrent Extrahepatic Metastases: A Case of Long-term Survival. *Journal of Gastroenterology and Hepatology Research* 2016; 5(2): 2033-2037 Available from: URL: <http://www.ghrnet.org/index.php/joghr/article/view/1594>

ABSTRACT

A 61-year-old man had been followed-up for chronic hepatitis since 1982. In 1995, he was diagnosed with primary hepatocellular carcinoma (HCC) and liver cirrhosis and was admitted to our hospital with a Child-Pugh score of 6 (class A). A right hepatic arteriogram revealed two tumors: one measured 23 × 21 mm in size and was located in segment 6 of the liver, while the other measured 16 × 14 mm in size and was located in segment 4. The tumors were treated with transarterial chemoembolization (TACE) and percutaneous ethanol injection (PEI). In 1996, a new HCC in segment 8, a recurrent HCC in segment 4, and a right adrenal metastasis were detected, all of which were treated with TACE. In 1997, the right adrenal metastasis recurred, and TACE was performed again. In 1999, TACE was used to treat metastases in a lymph node along the lesser curvature of the stomach and a lymph node along the left gastric artery. In 2002, a recurrent metastatic lesion developed in the lymph node along the lesser curvature of the stomach and was subjected to TACE. In 2005, a recurrent HCC lesion, measuring 18 mm in diameter, was detected in segment 4, and radiofrequency ablation (RFA) was performed. The patient experienced repeated HCC recurrences, as well as adrenal

INTRODUCTION

Few clinical reports exist concerning long - term survival in patients with hepatocellular carcinoma (HCC) and recurrent extrahepatic metastases for a period exceeding 10 years. HCC treatment has advanced markedly over the past 40 years, and the prognosis of HCC has significantly improved due to the development of various diagnostic imaging techniques and treatments. However, the prognosis of patients with extrahepatic metastasis from advanced HCC continues to be extremely poor^[1-4], with the median survival time of such patients being 4.9 months^[1].

Here, we report a rare case of HCC involving a patient who survived for 12 years after multidisciplinary treatment (which did not include surgery), even though he developed recurrent HCC and right adrenal and lymph node metastases.

CASE REPORT

A 61-year-old man with chronic hepatitis had been followed-up as an outpatient by a local clinic since 1982. He was found to have two hepatic tumors and liver cirrhosis in August 1995 and was subsequently admitted to our hospital. At the time of his

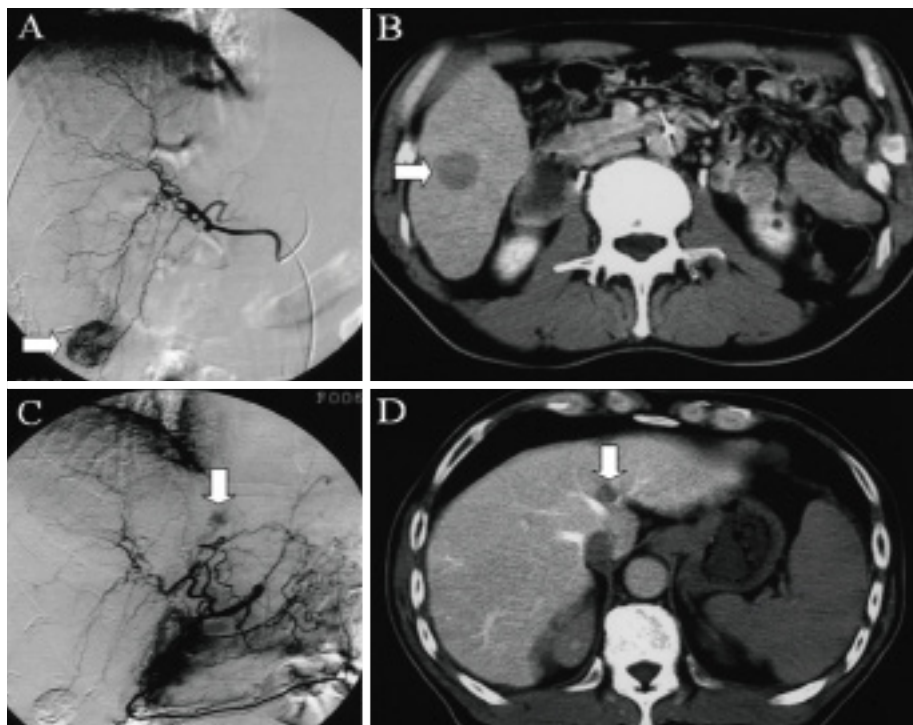


Figure 1 A: A tumor (arrow) detected in segment 6 of the liver on a right hepatic arteriogram; B: A focal perfusion defect (arrow), measuring 23 × 21 mm in size, revealed by computed tomography during arterial portography; C: A tumor (arrow) seen in segment 4 of the liver on a common hepatic arteriogram; D: A focal perfusion defect (arrow), measuring 16 × 14 mm in size, observed on computed tomography during arterial portography.

admission, he was 166.5 cm tall; weighed 66.8 kg; and exhibited blood pressure of 122/90 mmHg, a regular pulse, a pulse rate of 60 beats/min, and a body temperature of 36.0°C. An examination of the palpebral conjunctiva did not detect anemia, and no scleral icterus was observed. The patient's abdomen was not distended. A physical examination revealed splenomegaly, but no masses or hepatomegaly. The patient's laboratory findings were as follows: red blood cell count: $363 \times 10^4/\text{mm}^3$ (normal: $387\text{-}525 \times 10^4/\text{mm}^3$), hemoglobin level: 12.4 g/dL (12.6-16.5 g/dL), white blood cell count: $2200/\text{mm}^3$ ($3600\text{-}9000/\text{mm}^3$), platelet count: $3.1 \times 10^4/\text{mm}^3$ ($13.8\text{-}30.9 \times 10^4/\text{mm}^3$), serum albumin level: 3.2 g/mL (4.0-5.2 g/mL), total bilirubin level: 0.8 mg/mL (0.2-1.2 mg/mL), aspartate transaminase level: 36 IU/L (8-38 IU/L), alanine transaminase level: 31 IU/L (4-44 IU/L), γ -glutamyltransferase level: 224 IU/L (6-85 IU/L), prothrombin time: 73% (70-120%), indocyanine green retention rate at 15 min (ICG R15): 18.3% (0-10%), and serum alpha-fetoprotein (AFP) level: 143.9 ng/mL (0-20 ng/mL). A serological assay for hepatitis C virus antibodies (HCV-Ab) was positive, but a test for hepatitis B surface antigen (HBs-Ag) was negative. The patient's Child-Pugh score was 6 (class A). An arteriogram revealed two tumors. The first tumor was located in segment 6 of the liver and was detected on a right hepatic arteriogram (Figure 1A). Computed tomography during arterial portography (CTAP) showed a focal perfusion defect measuring 23 × 21 mm in size (Figure 1B) and so the tumor was diagnosed as a HCC. Transcatheter arterial chemoembolization (TACE) was carried out via the right hepatic artery, and then percutaneous ethanol injection (PEI) was performed. The other tumor was located in segment 4 and was detected on a common hepatic arteriogram (Figure 1C). On CTAP, a focal perfusion defect, measuring 16 × 14 mm, was seen in segment 4 (Figure 1D), and the tumor was subsequently diagnosed as a HCC. TACE was performed via the left hepatic artery. No regional lymph node or distant metastases

were detected.

In December 1996, the patient's serum AFP level was elevated (216.8 ng/mL). The early phase of contrast-enhanced dynamic computed tomography (CT) revealed a metastatic HCC lesion in the right adrenal gland (Figure 2A), which was also seen on right and common hepatic arteriograms (Figures 2B and C). This tumor was located in the peripheral regions of A4, 7, and 8 on right and left hepatic arteriograms, the right inferior phrenic artery and the right 10th and 12th intercostal arteries. The tumor-feeding vessels were subjected to TACE. In addition, faint tumors (metastatic HCC lesions) were seen in segments 4 and 8 on a common hepatic arteriogram (Figures 2C and D, respectively). The tumor in segment 4 was a recurrent HCC lesion. The tumor-feeding vessels were treated with TACE, and the patient's serum AFP level subsequently decreased.

In September 1997, CT revealed a low-density area in the inferior vena cava, which was confirmed to be a thrombus (Figure 3A). A filter was placed into the inferior vena cava (Figure 3B). A faint tumor was detected in the right adrenal gland on a right middle adrenal arteriogram (Figure 3C), as well as right superior adrenal and right inferior adrenal arteriograms. This tumor was diagnosed as a recurrence of the metastasis that formed in the right adrenal gland, and the tumor-feeding vessels were subsequently treated with TACE.

In September 1999, a tumor measuring 18 mm in size was seen in a lymph node along the lesser curvature of the stomach on an arteriogram of the feeding vessel from the left gastric artery (Figure 4A). Another tumor, which measured 15 mm in size, was detected in a lymph node along the left gastric artery on an arteriogram of another feeding vessel from the left gastric artery (Figure 4B). CT during a hepatic arteriogram (CTHA) of the celiac artery showed enlarged lymph nodes along the lesser curvature of the stomach and along the left gastric artery, which were diagnosed as metastases

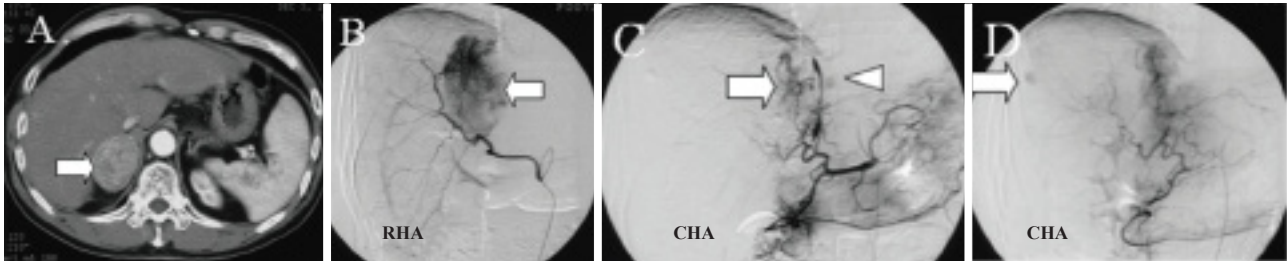


Figure 2 A: A metastatic hepatocellular carcinoma lesion (arrow) seen in the right adrenal gland during the early phase of contrast-enhanced dynamic computed tomography; B: A tumor (arrow) detected in the right adrenal gland on a right hepatic arteriogram (RHA); C: A tumor (arrow) noted in the right adrenal gland, and a faint tumor (arrowhead) observed in segment 4 of the liver on a common hepatic arteriogram (CHA); D: A faint tumor (arrow) seen in segment 8 of the liver on a CHA.

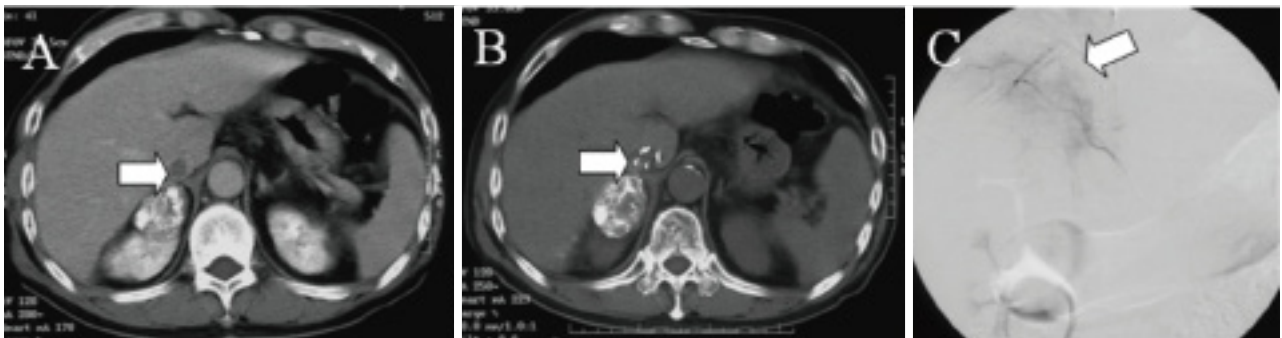


Figure 3 A: An inferior vena cava thrombus (arrow) detected during computed tomography; B: A filter (arrow) placed into the inferior vena cava; C: A faint tumor (arrow) seen in the right adrenal gland on a right middle adrenal arteriogram.

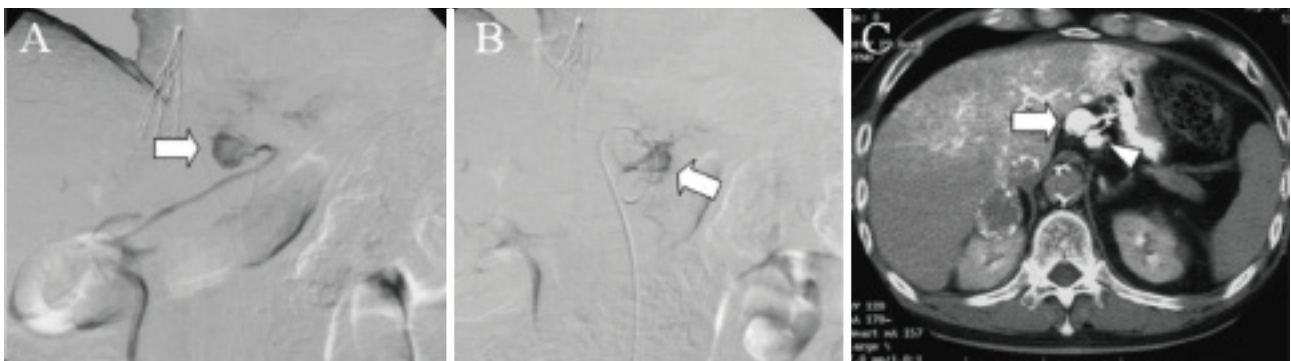


Figure 4 A: A tumor (arrow) detected in a lymph node along the lesser curvature of the stomach on an arteriogram of a feeding vessel from the left gastric artery; B: A tumor (arrow) seen in a lymph node along the left gastric artery on an arteriogram of another feeding vessel from the left gastric artery; C: Enlarged lymph nodes detected along the lesser curvature of the stomach (arrow) and along the left gastric artery (arrowhead) on computed tomography during a hepatic arteriogram of the celiac artery.

from HCC (Figure 4C). The tumor-feeding vessels were subjected to TACE.

In July 2000, the patient's serum AFP level had increased to 325.2 ng/mL, and a recurrent HCC was detected in segment 6. TACE was performed, and the patient's serum AFP level subsequently decreased.

In July 2002, a tumor measuring 10 mm in size was seen in a lymph node along the lesser curvature of the stomach on an arteriogram of a feeding vessel from the left gastric artery (Figure 5A). CTHA of the common hepatic artery showed an enlarged lymph node, which was diagnosed as a recurrent metastatic lesion (Figure 5B). The cardiac branch of the left gastric artery was subjected to TACE.

In December 2005, a faint tumor, measuring 18 mm in size, was observed in segment 4 on a common hepatic arteriogram (Figure 6A). CTHA showed a contrast-enhanced lesion in segment 4, which was diagnosed as a recurrent HCC (Figure 6B), and radiofrequency

ablation (RFA) was performed.

In August 2006, multiple HCC were detected, and all of them were treated with TACE.

In 2007, the patient's serum AFP level increased rapidly, and his hepatic reserve deteriorated. In May of the same year, low-dose cisplatin and 5-fluorouracil (the FP regimen) was started to suppress cancer growth, but the patient died of hepatic and renal failure in the following November. He had survived for 12 years after first being diagnosed with HCC, and for 11 and 8 years after being diagnosed with adrenal and lymph node metastases, respectively.

DISCUSSION

Extrahepatic metastases in patients with HCC are becoming more common due to improved diagnostic methods and prolonged survival^[1,2]. Uka *et al* and Natsuzaka *et al* reported that the

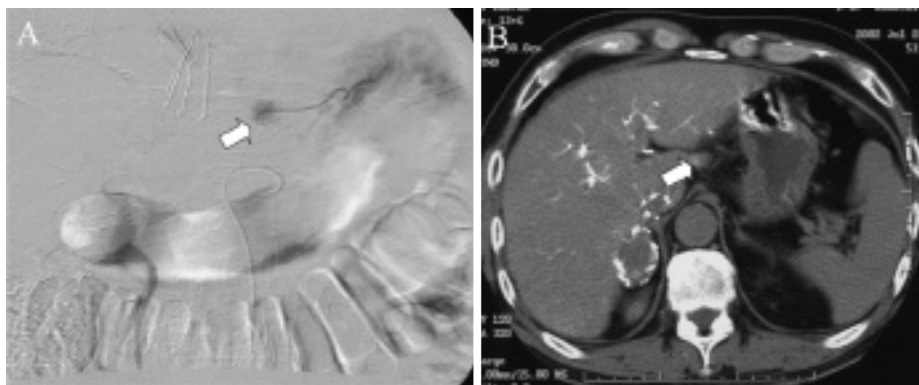


Figure 5 A: A tumor (arrow) seen in a lymph node along the lesser curvature of the stomach on an arteriogram of a feeding vessel from the left gastric artery; B: An enlarged lymph node (arrow) observed along the lesser curvature of the stomach on computed tomography during a hepatic arteriogram of the common hepatic artery.

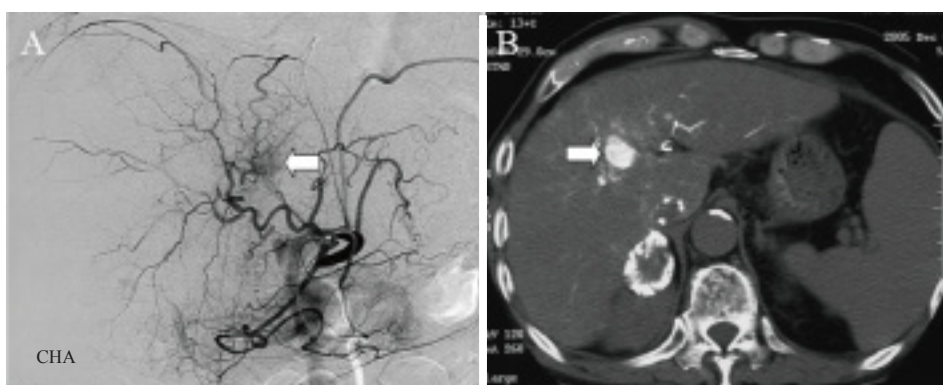

Figure 6 A: A faint tumor (arrow) seen in segment 4 of the liver on a common hepatic arteriogram; B: A contrast-enhanced lesion (arrow) observed in segment 4 of the liver on computed tomography during a hepatic arteriogram.

incidence of extrahepatic metastases in HCC patients is 15.2% and 13.5%, respectively^[1,2]. Uka *et al* stated that extrahepatic metastases from HCC most commonly occur in the lungs (47%), lymph nodes (45%), bones (37%), and adrenal glands (12%)^[1], while Natsuzaka *et al* reported that they tend to arise in the lungs (53.8%), bones (38.5%), lymph nodes (33.8%), and adrenal glands (16.9%)^[2]. In addition, Jung *et al* found that most metastases occurred in the lungs (55%), lymph nodes (46.7%), bones (20.4%), and adrenal glands (7.5%)^[3].

The prognosis of HCC patients with nodal metastasis is generally poor^[5-9]. Sun *et al*, Hasegawa *et al* and Kobayashi *et al* reported 3-year survival rates for HCC patients with lymph node metastasis of 31.0% ($n = 49$), 38.9% ($n = 112$), and 42.0% ($n = 18$), respectively^[7-9].

Few studies have examined adrenal metastases in HCC patients. According to Momoi *et al*, HCC patients that do and do not undergo adrenalectomy after the initial treatment for adrenal metastasis exhibit survival rates of 51.3% and 42.0% at 1 year, respectively, and 25% and 0%, respectively, at both 3 and 5 years^[10]. Hasegawa *et al* indicated that extrahepatic spread to sites other than the lymph nodes is associated with an even worse prognosis than spread to the lymph nodes alone^[8].

Uka *et al* identified the following four variables as significant and independent determinants of survival after an initial diagnosis of extrahepatic metastasis: performance status (PS), portal vein invasion, treatment for extrahepatic metastases, and Child-Pugh class^[1]. Jung *et al* reported that Child-Pugh class A, a smaller hepatic tumor, the absence of portal vein invasion, metastasis to a

single organ, and the detection of an objective treatment response for the intrahepatic tumor are favorable prognostic factors for survival in HCC patients with extrahepatic metastases^[3].

We will now examine the reasons why the patient in the present study survived for so long. Firstly, TACE was employed appropriately for two HCC, and one tumor was effectively cured using a combination of TACE and PEI. Secondly, while catheterization of the adrenal artery and complete embolization of the adrenal gland are anatomically difficult^[10], in the current case TACE was performed carefully for an adrenal metastasis with a complex series of feeding vessels. Furthermore, the recurrence of this lesion was diagnosed rapidly and controlled using a second TACE procedure. Thirdly, tests for the tumor marker AFP resulted in the early detection of recurrent HCC lesions and appropriate and timely treatment, resulting in a good prognosis (Figure 7). Lastly, it was possible to continue treating the patient for a long time because he was classified as Child-Pugh class A, and he maintained a sufficient hepatic reserve until 2005 (except during a short period at the beginning of treatment) (Figure 7). Thus, the underlying hepatic reserve has a critical influence on treatment selection for HCC. In cases involving a poor hepatic reserve, a treatment that is designed to suppress cancer growth should be selected rather than an aggressive treatment. There was no pathological diagnosis as HCC could be diagnosed on contrast-enhanced dynamic CT or an arteriogram.

In conclusion, the present patient's long-term survival can be explained by the following three points: (1) the patient maintained a relatively good hepatic reserve over a long period of time; (2)

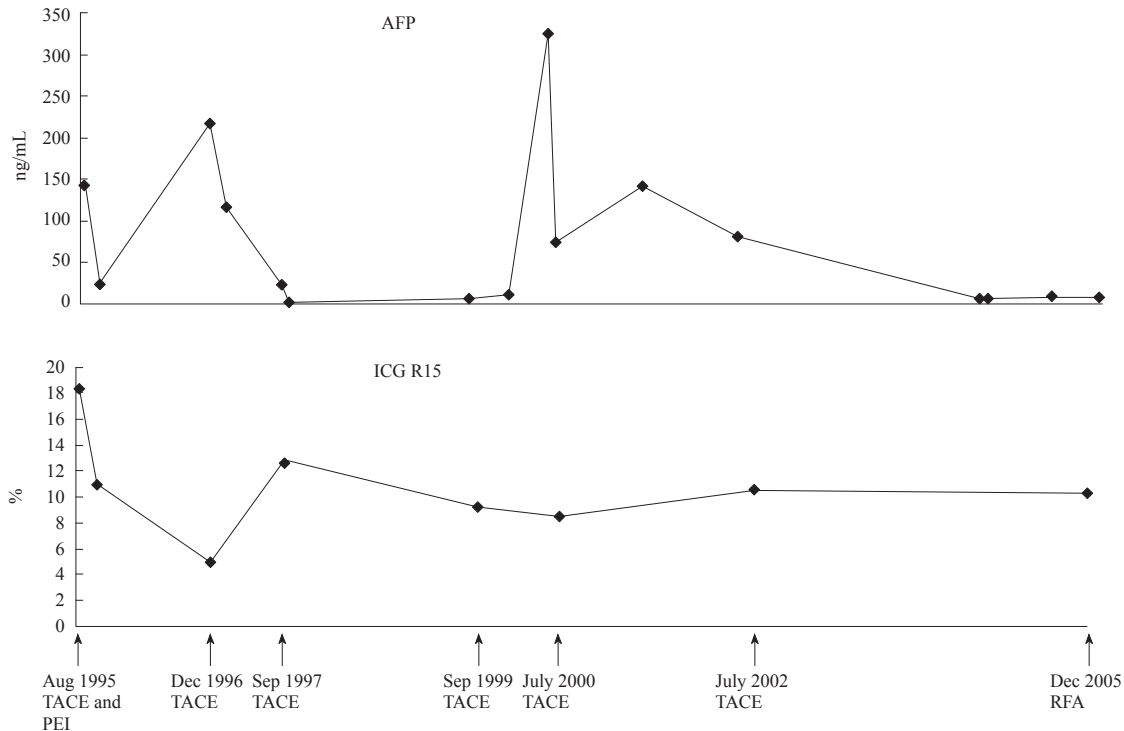


Figure 7 The patient's serum alpha-fetoprotein (AFP) levels and hepatic reserve.

recurrent lesions were rapidly diagnosed using a combination of a sensitive tumor marker and imaging techniques; and (3) good local control was achieved via careful treatment.

CONFLICT OF INTERESTS

There are no conflicts of interest with regard to the present study.

REFERENCES

- Uka K, Aikata H, Takaki S, Shirakawa H, Jeong SC, Yamashina K, Hiramatsu A, Komada H, Takahashi S, Chayama K. Clinical features and prognosis of patients with extrahepatic metastases from hepatocellular carcinoma. *World J Gastroenterol* 2007; **13**(3): 414-420.
- Natsuizaka M, Omura T, Akaike T, Kuwata Y, Yamazaki K, Sato T, Karino Y, Toyota J, Suga T, Asaka M. Clinical features of hepatocellular carcinoma with extrahepatic metastases. *J Gastroenterol Hepatol* 2005; **20**: 1781-1787.
- Jung SM, Jang JW, You CR, Yoo SH, Kwon JH, Bae SH, Choi JY, Yoon SK, Chung KW, Kay CS, Jung HS. Role of intrahepatic tumor control in the prognosis of patients with hepatocellular carcinoma and extrahepatic metastases. *J Gastroenterol Hepatol* 2012; **27**: 684-689.
- Kanda M, Tateishi R, Yoshida H, Sato T, Masuzaki R, Ohki T, Imamura J, Goto T, Yoshida H, Hamamura K, Obi S, Kanai F, Shiina S, Omata M. Extrahepatic metastasis of hepatocellular carcinoma: incidence and risk factors. *Liver Int* 2008; **28**: 1256-1263.
- Uenishi T, Hirohashi K, Shuto T, Kubo S, Tanaka H, Sakata C, Ikebe T, Kinoshita H. The Clinical significance of lymph node metastases in patients undergoing surgery for hepatocellular carcinoma. *Surg Today* 2000; **30**: 892-895.
- Uehara K, Hasegawa H, Ogiso S, Sakamoto E, Ohira S, Igami T, Mori T. Skip lymph node metastases from a small hepatocellular carcinoma with difficulty in preoperative diagnosis. *J Gastroenterol Hepatol* 2003; **18**: 345-349.
- Sun HC, Zhuang PY, Qin LX, Ye QH, Wang L, Ren N, Zhang JB, Qian YB, Lu L, Fan J, Tang ZY. Incidence and prognostic values of lymph node metastasis in operable hepatocellular carcinoma and evaluation of routine complete lymphadenectomy. *J Surg Oncol* 2007; **96**: 37-45.
- Hasegawa K, Makuuchi M, Kokudo N, Izumi N, Ichida T, Kudo M, Ku Y, Sakamoto M, Nakashima O, Matsui O, Matsuyama Y. Impact of histologically confirmed lymph node metastases on patient survival after surgical resection for hepatocellular carcinoma: report of a Japanese nationwide survey. *Ann Surg* 2014; **259**: 166-170.
- Kobayashi S, Takahashi S, Kato Y, Gotohda N, Nakagohri T, Konishi M, Kinoshita T. Surgical treatment of lymph node metastases from hepatocellular carcinoma. *J Hepatobiliary Pancreat Sci* 2011; **18**: 559-566.
- Momoi H, Shimahara Y, Terajima H, Iimura Y, Yamamoto N, Yamamoto Y, Ikai I, Yamaoka Y. Management of adrenal metastasis from hepatocellular carcinoma. *Surg Today* 2002; **32**: 1035-1041.

Peer reviewer: Yongfang Jiang, Md&Phd Associate Professor, Liver Diseases Research Center, The Second Xiangya Hospital, Central South University, No.139 Middle Renmin Road, Changsha, Hunan 410011, P.R. China.