

Clinical Aspects of Gastric and Duodenal Neuroendocrine Neoplasms

Sung Chul Park, Hoon Jai Chun

Sung Chul Park, Division of Gastroenterology and Hepatology, Department of Internal Medicine, Kangwon National University School of Medicine, Chuncheon, Korea

Hoon Jai Chun, Division of Gastroenterology and Hepatology, Department of Internal Medicine, Korea University Anam Hospital, Korea University College of Medicine, Seoul, Korea

Correspondence to: Hoon Jai Chun, MD, PhD, Division of Gastroenterology and Hepatology, Department of Internal Medicine, Korea University Anam Hospital, Korea University College of Medicine, 126-1, Anam-dong 5 ga, Seongbuk-gu, Seoul 136-705, Korea. drchunhj@chol.com

Telephone: +82-2-920-6555 Fax: +82-2-953-1943

Received: May 3, 2012 Revised: June 18, 2012

Accepted: June 29, 2012

Published online: September 21, 2012

ABSTRACT

With the development of endoscopy, the incidence of gastric and duodenal neuroendocrine neoplasms (NENs) has increased in recent decades. In the 2010 World Health Organization (WHO) classification, well-differentiated NENs were classified into NET G1 or G2, which is equivalent to the carcinoid tumor. Poorly differentiated NENs were named neuroendocrine carcinoma (NEC). Gastric NENs are classified into four types in accordance with their characteristics. Type 1 generally appears as multiple polypoid tumors at the fundus and corpus and takes a benign course. Type 2 has morphologically similar characteristics to type 1 and is associated with Zollinger-Ellison syndrome. Endoscopic treatment should be considered for cases in which the tumor is less than 2 cm and confined to mucosa and submucosa. In type 1 and type 2 accompanying hypergastrinemia, if the tumor was less than or equal to 1 cm, observation without endoscopic resection may be considered. Type 3 occurs sporadically and requires aggressive surgical treatment, including gastric resection and lymph node dissection due to poor prognosis. Poorly differentiated neuroendocrine carcinomas were classified as type 4. Although type 4 tumors are usually inoperable, surgery is sometimes performed with the aim of reducing tumor volume. Somatostatin analog, interferon alpha, and cytotoxic chemotherapy can be used with metastatic NENs. Duodenal NENs are rare compared to stomach NENs. The prognosis of duodenal NENs depends on their size. Endoscopic resection can be

performed in small duodenal NENs. Surgery, including Whipple's procedure, should be considered in large tumors.

© 2012 Thomson research. All rights reserved.

Key words: Neuroendocrine tumor; Stomach; Duodenum

Park SC, Chun HJ. Clinical Aspects of Gastric and Duodenal Neuroendocrine Neoplasms. *Journal of Gastroenterology and Hepatology Research* 2012; 1(8): 139-146 Available from: URL: <http://www.ghrnet.org/index./joghr/>

INTRODUCTION

Since Oberndorfer^[1] distinguished carcinoid tumors from gastrointestinal tract carcinoma in 1907, carcinoid tumors have been considered members of the same group. However, carcinoid tumors were found to have various disease groups in histology, hormone production, and biology. In addition, some endocrine tumors have without the features of carcinoid tumors been found. For these reasons, carcinoid tumors have been named a more comprehensive term, neuroendocrine tumors (NETs)^[2,3]. The classification and treatment of gastroenteropancreatic NETs (GEP-NETs) are now approached with a more detailed perspective. In 2010, the World Health Organization (WHO) classification adopted a more accurate name, neuroendocrine neoplasm (NEN) in place of NET^[4]. All GEP-NENs are considered potentially malignant, although the probabilities of metastasis are different. Tumors were classified by a three-step grading system of G1, G2, and G3 according to their proliferation activity (Ki-67 index, mitotic count) (Table 1). In other words, well-differentiated NENs were classified into NET G1 or G2 which is equivalent to the carcinoid tumor. Poorly differentiated NENs were named neuroendocrine carcinomas (NECs) and were divided into small and large cell types. All NECs are equivalent to G3 grade. Neoplasms with a mix of at least 30% neuroendocrine cells and non-endocrine cells such as adenocarcinoma were named mixed adenoneuroendocrine carcinoma (MANEC) to distinguish them from pure NENs (Table 2). In this paper, the stomach, duodenum, and ampullary NET are mentioned mainly for their clinical aspects.

Table 1 Grading system of neuroendocrine neoplasms.

Grade	Mitoses (10 HPF) ¹	Proliferative (Ki-67) index (%) ²
G1	<2	<3
G2	2-20	3-20
G3	>20	>20

Modified from reference^[4]; ¹10 HPF (high power field)=2 mm², at least 40 fields (at 40×magnification) evaluated in areas of highest mitotic density; ²MIB1 antibody; % of 2000 tumor cells in areas of highest nuclear labeling.

Table 2 2010 WHO classification for gastrointestinal neuroendocrine neoplasms.

NET	Low to intermediate grade (G1-2), well to moderately differentiated neoplasms
NEC (small cell or large cell type)	High grade (G3), moderate to poorly differentiated neoplasms
MANEC	Neoplasms with at least 30% of tumor cells that have neuroendocrine characteristics

WHO: World Health Organization; NET: Neuroendocrine tumor; NEC: Neuroendocrine carcinoma; MANEC: Mixed adenoneuroendocrine carcinoma.

STOMACH

Epidemiology

Gastric NET was a very rare tumor in the past, with an incidence of 4% within the entire gastrointestinal tract carcinoid tumors and comprising 0.3% of gastric neoplasias. However, it has been reported that in recent years 11-30% of carcinoid tumors of the gastrointestinal tract occurred in the stomach^[5]. This increase in tumor incidence was thought to be due to increases in NEN awareness, commonplace endoscopic examination, improved histopathological evaluation, and enhanced diagnostic techniques. An increase in case reports seems to occupy some portion in addition to a substantial increase of tumors^[6].

Clinicopathological classification

Gastric NENS were classified into three types by their clinical pathology aspects, in accordance with the methods of Rindi *et al*^[7]. The fourth type was added later^[8,9] (Table 3).

Table 3 Types of gastric neuroendocrine neoplasms.

Characteristics	Type 1	Type 2	Type 3	Type 4
Proportion	70-80%	5-10%	15-20%	Rare
Associated disease	CAG pernicious anemia	MEN 1 ZES	Sporadic	Sporadic
Site of tumor	Fundus and corpus	Fundus, corpus, and occasionally antrum	Anywhere	Anywhere
Plasma gastrin level	High	High	Normal	Mostly Normal
Gastric acid output	Low or absent	High	Normal or low	Mostly Normal
Number of tumors	Multiple	Multiple	Single	Single
Size of tumors (cm)	< 1-2	< 1-2	2-5	2-5
Prognosis	Good	Good, but metastasis in 10-30% (minority)	Poor	Very Poor

CAG: Chronic atrophic gastritis; MEN 1: Multiple endocrine neoplasia type 1; ZES: Zollinger-Ellison syndrome.

Type 1: Type 1 is the most common type among gastric NENS and accounts for 70-80%. The average age of this group is 63 years. Type

1 NENS are more common in women than in men. It generally occurs at the fundus and corpus accompanied by chronic atrophic gastritis, and appears as multiple small red polypoid tumors^[10]. Autoimmune chronic atrophic gastritis is caused by autoantibodies that destroy parietal cells. It also causes the hyperactivity of gastrin secretion and can clinically induce achlorhydria and rarely pernicious anemia. Chronic serum gastrin elevation causes proliferation (hyperplasia) and dysplasia of enterochromaffin-like (ECL) cells. ECL cell carcinoid tumors occur over an extended time period. Type 1 gastric NEN occurs in less than 1% of patients with hypergastrinemia due to achlorhydric atrophic gastritis.

Histologically, the tumors are well differentiated and have a mixture of trabecular and solid patterns. The proliferative index (Ki-67 index) was usually less than 2% (G1). 27% were confined to the mucosal layer while 64% were confined to the submucosal layer. Only 9% invaded the muscle layer. Metastasis was rare, but often occurred when the tumor was larger than 1-2 cm and invaded the muscle layer or vascular structure. Only 2-9% of patients had lymph nodes metastasis.

Patients often had no symptoms. Tumors were coincidentally found by gastroscopy in patients with an iron deficiency or pernicious anemia, which is the most common feature of atrophic gastritis.

Type 2: Five to ten percent of gastric NENS are considered type 2. It has the same sex ratio and the average age at diagnosis is 50 years. Type 2 gastric NEN is mainly associated with multiple endocrine neoplasia type 1 (MEN 1). It occurred in patients with Zollinger-Ellison syndrome (ZES) due to duodenal gastrinoma. It does not appear at first, but appears after 15-20 years^[11]. When gastroscopy was performed in patients with reflux esophagitis or recurrent duodenal ulcer, type 2 was found in the fundus and corpus. Seventy five percent of tumors are small (less than 15 mm), multiple, and confined to the mucosal and submucosal layers. Histologically, type 2 is well differentiated and shows a trabecular pattern. The proliferative rate was usually less than 2% (G1).

Similar to type 1, type 2 gastric NENS originated from ECL cells. Carcinoid tumors occurred through varying degrees of ECL cell hyperplasia^[12]. Unlike type 1, there was the hyperplasia of the chief and parietal cells without atrophy of the gastric mucosa around the lesion.

Gastric NENS appeared in 15-30% of MEN 1 and rarely occurred in sporadic ZES without MEN 1. Genetic changes in patients with MEN 1 are thought to make ECL cells that are more sensitive to the proliferative effects of gastrin^[11].

Type 3: Fifteen to twenty percent of gastric NENS belong to type 3^[10]. The average age at diagnosis is about 55 years and type 3 is more common in men. These patients do not have chronic atrophic gastritis, hypergastrinemia, or hyperplasia of ECL cells. Type 3 occurred sporadically without a relationship to MEN 1. It can occur in any part of the stomach. Type 3 appeared as one or a few polypoid tumors. Type 3 is histologically well-differentiated and shows a trabecular or solid pattern. The proliferative rate often exceeds 2% (G2 or G3).

Most type 3 NENS are larger than 1 cm and show muscle layer involvement or vascular invasion^[13,14]. In 75% of the cases there were regional lymph nodes or liver metastasis at the time of diagnosis and prognosis was poor.

Type 4: Poorly differentiated NECs are classified into type 4 and

rarely occur^[15]. This type mainly occurs in older men and has an average age in the 60s. It was not associated with chronic atrophic gastritis and was only rarely associated with MEN 1. Type 4 can occur in any part of the stomach as a solitary tumor, and it often had ulcers. It is frequently present as a significant sized tumor more than 4 cm in diameter. Histologically, type 4 showed small cell or large cell NEC and a solid pattern without ECL cells. Type 4 had increased cell mitoses and vessel invasion, and the proliferative rate exceeded 20-30%.

At diagnosis, most poorly differentiated NECs showed advanced stages accompanied by widespread metastasis and grew aggressively. There have been composite tumors, in which squamous cell carcinoma or adenocarcinoma and poorly differentiated NEN are mixed and histological transition occurs. There have been also collision tumors in which adenocarcinoma and NECs occur simultaneously to form a single mass. However, they were very rare^[16,17].

Clinical manifestations

Almost all type 1 and 2 gastric NENs have no symptoms^[18]. Many cases are found from a gastroscopy performed for other indications such as anemia, nonspecific abdominal pain, and gastroesophageal reflux disease^[10,13]. In contrast, types 3 and 4 can show symptoms, with abdominal discomfort, gastrointestinal bleeding, chronic diarrhea, and weight loss as the main symptoms^[19].

Carcinoid syndrome occurred very rarely, usually in type 3, with an incidence of 3-8%^[13]. Typical carcinoid syndrome presents at the metastatic ileal carcinoid tumor, but most gastric NENs showed atypical aspects. Atypical carcinoid syndrome was characterized by a persistent purple rash that involved the limbs and trunk without diarrhea and usually occurred with liver metastasis. It occurred because gastric NENs lacked dopa carboxylase and secreted 5-hydroxytryptophan. This is unlike the ileal carcinoid tumor, which secreted 5-hydroxytryptamine.

ZES due to gastrinoma in the stomach was rare. ZES is characterized by reflux esophagitis, recurrent duodenal ulcers, and chronic diarrhea^[19].

Diagnosis

Although endoscopy is helpful for diagnosing gastric NEN, biopsy is required for accurate diagnosis. A biopsy of tissue around the lesion may be helpful for investigating the degree of gastritis and ECL cell hyperplasia. Endoscopic ultrasound (EUS) is widely used to examine the size and degree of invasion of gastric NEN. It is also useful for finding gastrinoma and performing needle aspiration.

For gastric NEN diagnosed by endoscopic and histologic methods, further tests should be performed to classify its subtype (Figure 1). First, serum gastrin values should be measured. If these values are high, it is potentially a type 1 or 2 NEN. If serum gastrin values are normal, the NEN is likely to be type 3 or 4. Because type 1 mostly occurs due to hypochlorhydria or atrophic gastritis, an antibody test for parietal cell and intrinsic factor should be included in the blood test to examine pernicious anemia with vitamin B12 deficiency^[20].

For type 2 NENs with ZES, which features gastric acid hypersecretion, it may be helpful to directly measure gastric pH. However, there are limitations to this method's use in clinical practice. In ZES, serum gastrin usually exceeds 1000 pg/mL and diagnosis can be confirmed by measuring the gastric acid hypersecretion. However, diagnosis may be elusive when gastrin is in the range of 100-1000 pg/mL. In these cases, other tests may be used

to find accompanying gastrinoma. Parathyroid (PTH and calcium profile) or pituitary function tests are performed to diagnose MEN 1. In addition, the MENIN genetic test may be helpful. Type 3 or 4 NEN can be diagnosed by excluding ZES through a secretin provocation test, which shows elevated gastrin in type 3 or 4. However this test is clinically difficult^[21]. It may be helpful if tissue around the lesion is not accompanied by atrophic gastritis on histopathologic examination.

In addition to tests performed for subtypes, radiologic imaging should be performed to identify local disease progression and distant metastasis. Computed tomography (CT) is useful for evaluating invasion or metastasis and for finding the location of gastrinoma in type 2. Whereas CT is helpful for finding the tumor's anatomical location, somatostatin receptor scintigraphy (SRS) can be useful for examining the functional aspects of the tumor. According to one study, SRS has a sensitivity and specificity of 63% and 95%, respectively^[22]. However, it is expensive and has limitations in estimating the anatomical locations of tumors. ¹¹C-5-hydroxytryptophan (HTP) positron emission tomography (PET) can also be helpful in finding functional aspects of the tumor^[23].

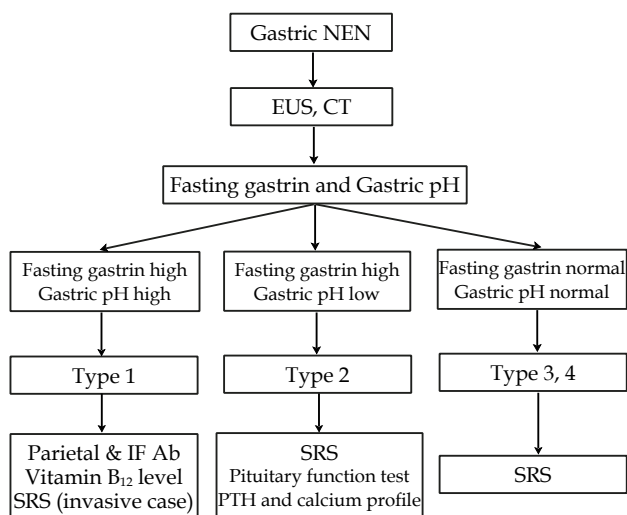


Figure 1 Diagnostic flow of gastric neuroendocrine neoplasm. NEN: neuroendocrine neoplasm; EUS: endoscopic ultrasound; CT: computed tomography; IF: intrinsic factor; Ab: antibody; SRS: somatostatin receptor scintigraphy.

Treatments

Treatment principles were determined by tumor size, location of origination, invasiveness, and metastasis. In other words, the treatment of gastric NENs depended on subtype, size, and number.

Localized NENs: First, gastric wall invasion and peripheral lymph node metastasis are determined by EUS in type 1 and type 2 patients with hypergastrinemia. According to the 2010 treatment guidelines of the North American Neuroendocrine Tumor Society (NANETS), endoscopic resection is advised for up to 6 NENs smaller than 2 cm. NENs of more than 2 cm size, more than 6 lesions, or recurrent NENs should be treated by aggressive treatment such as surgical resection^[24]. Type 1 NEN has been reported to have a good prognosis when observed through endoscopy^[25]. Therefore, in type 1 and type 2 accompanying hypergastrinemia, if the tumor is less than or equal to 1 cm, observation and surveillance every six to twelve months without endoscopic resection may be considered. When tumors were greater than 1 cm, there were more than 5 tumors, and there was

local recurrence after endoscopic resection, surgical local excision and antrectomy for blocking gastrin secretion were recommended. Gastrectomy was usually performed for multiple tumors, but is rarely performed now because of the good response to a somatostatin analog. In general, type 1 prognosis was very good and tumors had low mortality rates. However, endoscopy follow-up is still important because of recurrent cases^[26]. Follow-up endoscopy at 6-12 month intervals after treatment is preferable.

For type 2 NENs, which occur secondary to ZES/MEN 1, somatostatin analogs may be considered because a loss of NENs can be expected. Surgical treatment is performed to remove the cause of gastrin hypersecretion. Eliminating gastrin stimulation by finding and removing gastrinoma can lead to degeneration of gastric NEN. Since duodenal gastrinoma is common in MEN 1, the gastrinoma can be removed by performing a resection through the duodenal incision or a pancreatic-duodenectomy with peripheral lymph node dissection. However, gastric NENs do not always respond to removing gastrin stimulation, and more research is needed in this area^[27]. In ZES, symptoms can be controlled by a proton pump inhibitor and somatostatin analog.

Type 3 NENs exhibited aggressive clinical aspects, such as metastases. At the time of diagnosis, more aggressive treatments were needed, including surgery. Surgical treatment, such as total or partial gastrectomy and lymph node dissection, is the preferred treatment for single tumors greater than 1 cm and for multiple lesions^[28]. Endoscopic resection can be performed for the lesion that is not invasive like early gastric cancer, but the reports on this therapy could not be found.

In type 4 gastric NENs, surgery is not generally possible. However, surgery with the aim of reducing tumor volume can sometimes be performed^[9]. Similar to small cell lung cancer, chemotherapy can be performed with symptom control.

Metastatic NENs:

(1) Management of hepatic metastasis

The organ of metastasis, disease progression, and severity of symptoms should be considered in determining treatment for metastatic NEN accompanied by symptoms. The most common site of metastasis is the liver and lung, while bone metastases occurred rarely. Because morbidity and mortality due to hepatic resection has decreased in recent years, tumor resection is recommended in hepatic metastasis due to NEN. However, complete surgical excision is often difficult in the cases in which the location is difficult to resect. In a report on liver metastasis from NENs, there were multiple hepatic metastases in most cases^[29]. Therefore, surgical resection is only possible in 10% to 20% of cases^[30]. For local treatment of non-resectable metastatic NENs, hepatic arterial chemotherapy, radiofrequency ablation or cryoablation can be performed. Even for cases in which surgical resection was impossible, if the mass was reduced by these therapies, it could subsequently undergo surgical resection. Therefore, aggressive combination therapy should be considered. It was reported that after treatment with yttrium, down staging was induced and successful resection could be performed^[31]. Even when NENs had serious symptoms and could not be completely resected, partial resection for symptom relief was a reasonable treatment.

In patients with liver metastasis, liver transplantation could be considered. It was reported that in 15 patients who received liver transplants, eight patients suffered major complications associated with transplantation and one of these patients died from complications associated with surgery with seven patients who were

disease-free^[32]. However, recent transplant research in the Milan group demonstrated a 5-year survival rate and disease-free survival of 90% and 77% respectively^[33]. Therefore, liver transplantation could be suggested as one of the radical treatment methods for cases of multiple bilateral liver metastases.

(2) Somatostatin analog and interferon alpha

Metastatic gastrointestinal NENs often cause symptoms such as diarrhea and flushing due to hormone hypersecretion. Because secreted hormones from NENs with liver metastasis directly enter the systemic circulation, carcinoid syndrome is often expressed. Treatment of unresectable NENs continues to develop and diversify. Somatostatin analogs are very useful in controlling NEN symptoms and are expected to treat tumors. In a study about octreotide LAR (long acting release form, intramuscular injection of 30 mg once per month) in metastatic gastrointestinal NENs, the median time to progression for the treatment and placebo groups was 14.3 and 6 months, respectively^[34]. Interferon alpha treatment reduced hormone hypersecretion in half of the cases, stabilized the tumor in 20-40% of the cases, and caused a tumor reduction in approximately 15% of the cases^[35-40]. The amount administered is 3 to 9 MU (million units) 3-7 times a week by subcutaneous injection. This amount should be adjusted in cases of lymphopenia. Somatostatin analogs and interferon therapy are expected to increase therapeutic effects in combination with conventional cytotoxic drug therapy. Further studies are needed because objective tumor regression and survival prolongation have not been proven. Steroids and cyproheptadine could also be used for symptom control in metastatic tumors.

(3) Cytotoxic chemotherapy

A variety of anticancer drugs can be used monotherapy or combination therapy for metastatic gastrointestinal NENs of G1/G2. These include 5-FU, streptozocin, doxorubicin, etoposide, dacarbazine (DTIC), and temozolomide^[41-46]. Caution is needed with these drugs because the response is short and chemotherapy can cause various side effects. In G3 gastrointestinal NECs, etoposide/cisplatin is used as primary therapy. In addition, a variety of new anti-cancer therapies, such as oxaliplatin/capecitabine and temozolomide, have been attempted. However, further comparative studies are needed.

Several molecular target agents including sunitinib, everolimus, and bevacizumab have recently been applied as treatment, and prolonged survival without tumor progression has been reported^[47-49]. Targeted radionuclide therapy has also been used, in which radionuclide is attached to somatostatin analogs as an investigational approach^[50].

Prognosis

Cases of death have not been reported with type 1, and its prognosis is usually good. Survival rates of 5 and 10 years in type 1 were not much different from those of the general population^[51]. The prognosis of type 2 is worse than type 1 and better than type 3. Lymph node metastasis was found in 10-30% of patients, especially in tumors larger than 2 cm or with muscle layer involvement or vascular invasion. The mortality rate was reported to be less than 10% and the 5-year survival rate was 60-75%^[52]. Type 3 prognoses are poor, with a mortality rate of 25-30% and a 5-year survival rate of less than 50%^[10,52]. The prognosis of type 4 was the poorest among the four types of gastric NENs and three fourths of patients died within 12 months due to widespread metastasis^[18,53].

DUODENUM AND AMPULLA OF VATER

Epidemiology

Two to five percent of gastrointestinal NENs occur in the duodenum and the annual incidence of duodenal NEN is 0.07 per 100 000. According to a recent report, duodenal and jejunal NEN have been reported to account for 22 percent of all gastrointestinal NENs^[54]. Duodenal NEN was 1-3% of all duodenal tumors, Most duodenal NENs were slightly more common in men. The average age was in the 60s but onset age varied from 15 to 91 years old.

Clinicopathological classifications

NENs that occur in the duodenum and proximal jejunum can be classified by several types. The NET that secreted gastrin is the most common (62-65%), followed by somatostatin-secreting tumors (18-21%) and then gangliocytic paraganglioma (9%). Non-functional NET (5.6%) and NEC were very rare^[55].

More than 90% of duodenal NEN occurs in the duodenal bulb or second portion. About 25% of duodenal NEN occurs at the periampullary area. In many studies, the ampulla of Vater or periampullary NEN were distinguished from other duodenal NENs because their growth patterns and clinical, histological, and immunohistochemical properties are different^[56]. In general, duodenal NENs are small tumors with an average size of 1.2-1.8 cm^[57].

Gastrin producing NETs: Gastrin producing duodenal NET was the most common type of duodenal NEN, accounting for approximately 62-65% of cases. Among gastrin producing tumors, clinical functioning tumors associated with ZES were called gastrinoma. Gastrinomas were usually sporadic and 25-33% of them were associated with MEN 1. Gastrinomas were usually located in the duodenal bulb and polypoid lesions less than 2 cm and confined to the mucosa or submucosal layer. In 60-75% of patients with sporadic ZES, gastrinomas were located in the duodenum while the rest were in the pancreas. In contrast, almost all cases associated with MEN 1 were located in the duodenum^[58]. Duodenal gastrinomas of sporadic cases were mostly single, whereas those associated with MEN 1 were almost always multiple and very small, less than 1 mm. Tumors that were not accompanied by ZES usually had no symptoms and were found in older people. Local lymph node metastasis was found in 60-80% of the cases at the time of diagnosis. In these cases, lymph nodes were larger than the primary tumor and could be mistaken for a pancreatic tumor. Liver metastases occurred in approximately 10% of cases and occurred several years after development of the disease. Local lymph node metastasis did not affect the survival of patients with ZES. Pancreatic gastrinomas were always sporadic and had no association with MEN 1. Liver metastasis in pancreatic gastrinoma occurred earlier than in duodenal gastrinoma^[55].

Somatostatinoma: Somatostatinoma was the second most common type (18-21%) of duodenal NEN and usually occurred around the periampullary area with an average size of 2.3 cm. Histologically, somatostatinoma showed a glandular pattern with a psammoma body. The risk of metastasis was over 50% if it invaded the muscle layer, was larger than 2 cm, or showed an increased proliferative rate^[55]. However, lymph node metastasis around the duodenum may occur even in tumors with a diameter between 1 cm and 2 cm or smaller. Liver metastasis was rare, but in recurrent cases the liver was the most common site of metastases. Duodenal somatostatinoma did not cause somatostatin syndrome (cholelithiasis, diabetes, weight loss, diarrhea, hypochlohydria, achlohydria, and anemia), unlike pancreatic somatostatinoma.

Ampullary somatostatinoma was frequent in patients with

neurofibromatosis type 1 (von Recklinghausen's disease). Twenty to thirty percent of somatostatinoma cases were associated with neurofibromatosis.

Gangliocytic paraganglioma: Gangliocytic paraganglioma accounted for 9% of duodenal NEN. Polypoid tumors occurred in the ampulla of Vater and periampullary area with size that varied from 1.5-7 cm. In general, gangliocytic paraganglioma occurred at a younger age than other duodenal NENs. Tumors consisted of three different types of tumor cells, epithelial/endocrine cells, spindle-shaped Schwann cells, and ganglion cells. The epithelial/endocrine cells were somatostatin and pancreatic polypeptide-positive, the spindle cells expressed neurofilament and S-100, and the ganglion cells were neuron specific enolase-positive. Even with cases in which the tumor was large and invaded the muscle layer, local lymph node metastasis was rare and it took a benign course^[59]. Sometimes large (>2 cm) tumors spread to regional lymph nodes and endocrine cells of the lesion contributed to malignancy. Gangliocytic paraganglioma did not show specific symptoms, but some cases were found by postprandial abdominal pain and upper gastrointestinal bleeding symptoms such as melena. Intestinal or biliary obstruction could occur. Gangliocytic paraganglioma is not associated with familial syndromes.

Non-functional duodenal NET: Non-functional NET was composed of calcitonin-secreting cells or EC cells that normally secrete serotonin. It did not cause hormone induced clinical syndrome. Incidence of non-functional NET was rare and it showed few signs or symptoms of invasive growth. The prognosis was very good compared to the prognoses for gastrinoma associated with ZES syndrome or ampullary somatostatinoma. Metastasis did not occur until the tumors invaded beyond the submucosal layer^[2].

Poorly differentiated NEC: Poorly differentiated NEC is very rare and was mainly located in the ampulla and periampullary area. It was 2-3 cm in size, larger than a typical duodenal NEN and ulcerated or protruding tumor. Histologically, poorly differentiated NEC is an undifferentiated small cell carcinoma that characteristically invades the muscle layer. Clinically, most patients had jaundice and bleeding, and the NEC was hormone-inactive. At diagnosis, poorly differentiated NEC was in an advanced stage with regional lymph node or liver metastases^[60]. In patients with metastases, the median survival was 14.5 months.

Clinical manifestations

In most cases, there was no specific clinical hormonal syndrome and the tumors were sporadic and slow growing^[61]. They were found by chance with gastroscopy due to symptoms unrelated to NEN. Common symptoms include vague abdominal pain (37%), upper gastrointestinal bleeding (21%), anemia (21%), and jaundice (18%)^[62]. Periampullary or ampulla of Vater NENs often caused symptoms such as jaundice, abdominal pain, nausea, diarrhea, and vomiting. Jaundice occurred in up to 60% of cases in some reports.

Duodenal NENs were usually asymptomatic regarding hormones, but ZES was present in approximately 10±3% of cases and Cushing's syndrome was present in 4±2%. In rare cases, acromegaly due to the NET that secreted growth hormones (GRFoma) occurred. There were also rare functional duodenal NETs such as insulinoma and glucagonoma^[62]. Patients with ZES complained of symptoms such as heartburn, duodenal ulcer disease, and chronic diarrhea^[63]. The clinical characteristics of patients with ZES did not differ in frequency between duodenum and pancreas gastrinoma and

they did not help find the primary location of gastrinoma. Fasting serum gastrin was significantly higher in patients with pancreatic gastrinoma than duodenal gastrinoma. Therefore, less than five times fasting gastrin indicated a duodenal tumor. Because liver metastasis was much more common in pancreatic gastrinoma than in duodenal gastrinoma, the 10-year survival rate of duodenal gastrinoma was 94%, significantly higher than that of pancreatic gastrinoma, 59%^[64]. Typical carcinoid syndrome occurred only exceptionally in duodenal NEN and was associated with liver metastasis of the tumor.

Diagnosis

Most duodenal NENS were found as a tumor in the lumen by endoscopy, CT, and magnetic resonance imaging (MRI). Duodenal NENS can be diagnosed by endoscopy with biopsy, and lymph node metastasis can be predicted by tumor size and depth of invasion. Therefore, EUS, abdominal CT, and scintigraphy can help to diagnose peripheral metastasis, staging, and histological features.

Treatments

There is not the established guidelines about the treatment of duodenal NEN yet, but the same methods used for gastric NENS can be attempted. Small duodenal NENS could be treated by endoscopic resection and surgeries, such as Whipple's procedure, may be considered for large tumors. The indication of endoscopic resection is difficult to define exactly. However, based on experience and data, an estimated size of less than 1 cm indicates endoscopic resection. A size of up to 2 cm may be included in the indication as well. It was thought to be beneficial to estimate the invasion depth of duodenal NENS through EUS^[65]. There is not enough data about the treatment of duodenal NENS and further studies are needed.

Prognosis

Metastasis from duodenal NENS was observed in 6-10% of cases^[55,66]. In duodenal NENS that were not associated with hormone syndrome, there was a very low probability of metastasis if they were smaller than 10 mm and showed GI without muscle layer involvement of vascular invasion. These cases could be considered early duodenal NENS. In duodenal NENS associated with ZES, regardless of association with MEN 1, regional lymph nodes and distant organ metastasis may occur in tumors having a size of only a few mm.

The five-year survival rate of duodenal NENS has been reported as 84%^[15]. However, survival rates vary depending on histological type, range of lesion, presence of hormone syndrome, and genetic background. If localized, the 5-year survival rate was 95%, but this rate decreased to about 10% in metastatic cases.

CONCLUSION

Gastric and duodenal NENS show a variety of clinical features and characteristics depending on anatomical position, origin of neuroendocrine cells, and secreting products. However, they also have many common features according to classification. Through the identification of biological characteristics of NEN, a more accurate and meaningful classification system for individualized therapy could become available. This would also improve assessments for patient prognosis.

REFERENCES

- 1 Oberndorfer S. Karzinoide tumoren des dunndarms. *Frank Z Pathol* 1907; **1**: 426-429
- 2 Klöppel G, Perren A, Heitz PU. The gastroenteropancreatic

- neuroendocrine cell system and its tumors: the WHO classification. *Ann N Y Acad Sci* 2004; **1014**: 13-27
- 3 Solcia E, Kloppel G, Sobin L. Histological Typing of Endocrine tumours. WHO International Histological Classification of Tumours. 2nd ed. ed. New York: Springer, 2000
- 4 Rindi G, Arnold R, Bosman F. Nomenclature and classification of neuroendocrine neoplasms of the digestive system. In: Bosman F, Carneiro F, Hruban R, Theise N, eds. WHO classification of tumours of the digestive system. Lyon: IARC, 2010
- 5 Modlin IM, Kidd M, Latich I, Zikusoka MN, Shapiro MD. Current status of gastrointestinal carcinoids. *Gastroenterology* 2005; **128**: 1717-1751
- 6 Scherübl H, Cadiot G, Jensen RT, Rösch T, Stölzel U, Klöppel G. Neuroendocrine tumors of the stomach (gastric carcinoids) are on the rise: small tumors, small problems? *Endoscopy* 2010; **42**: 664-671
- 7 Rindi G, Luinetti O, Cornaggia M, Capella C, Solcia E. Three subtypes of gastric argyrophil carcinoid and the gastric neuroendocrine carcinoma: a clinicopathologic study. *Gastroenterology* 1993; **104**: 994-1006
- 8 Klöppel G, Clemens A. The biological relevance of gastric neuroendocrine tumors. *Yale J Biol Med* ; **69**: 69-74
- 9 Rindi G, Bordi C, Rappel S, La Rosa S, Stolte M, Solcia E. Gastric carcinoids and neuroendocrine carcinomas: pathogenesis, pathology, and behavior. *World J Surg* 1996; **20**: 168-172
- 10 Ruzsniwski P, Delle Fave G, Cadiot G, Komminoth P, Chung D, Kos-Kudla B, Kianmanesh R, Hochhauser D, Arnold R, Ahlman H, Pauwels S, Kwekkeboom DJ, Rindi G. Well-differentiated gastric tumors/carcinomas. *Neuroendocrinology* 2006; **84**: 158-164
- 11 Berna MJ, Annibale B, Marignani M, Luong TV, Corleto V, Pace A, Ito T, Liewehr D, Venzon DJ, Delle Fave G, Bordi C, Jensen RT. A prospective study of gastric carcinoids and enterochromaffin-like cell changes in multiple endocrine neoplasia type 1 and Zollinger-Ellison syndrome: identification of risk factors. *J Clin Endocrinol Metab* 2008; **93**: 1582-1591
- 12 Rindi G, Solcia E. Endocrine hyperplasia and dysplasia in the pathogenesis of gastrointestinal and pancreatic endocrine tumors. *Gastroenterol Clin North Am* 2007; **36**: 851-865
- 13 Burkitt MD, Pritchard DM. Review article: Pathogenesis and management of gastric carcinoid tumours. *Aliment Pharmacol Ther* 2006; **24**: 1305-1320
- 14 Rindi G, Klöppel G, Ahlman H, Caplin M, Couvelard A, de Herder WW, Eriksson B, Falchetti A, Falconi M, Komminoth P, Krner M, Lopes JM, McNicol AM, Nilsson O, Perren A, Scarpa A, Scoazec JY, Wiedenmann B. TNM staging of foregut (neuro)endocrine tumors: a consensus proposal including a grading system. *Virchows Arch* 2006; **449**: 395-401
- 15 Modlin IM, Lye KD, Kidd M. A 5-decade analysis of 13,715 carcinoid tumors. *Cancer* 2003; **97**: 934-959
- 16 Namikawa T, Kobayashi M, Okabayashi T, Ozaki S, Nakamura S, Yamashita K, Ueta H, Miyazaki J, Tamura S, Ohtsuki Y, Araki K. Primary gastric small cell carcinoma: report of a case and review of the literature. *Med Mol Morphol* 2005; **38**: 256-261
- 17 Nilsson O, Van Cutsem E, Delle Fave G, Yao JC, Pavel ME, McNicol AM, Sevilla Garcia MI, Knapp WH, Keleştimur F, Sauvanet A, Pauwels S, Kwekkeboom DJ, Caplin M. Poorly differentiated carcinomas of the foregut (gastric, duodenal and pancreatic). *Neuroendocrinology* 2006; **84**: 212-215
- 18 Modlin IM, Oberg K, Chung DC, Jensen RT, de Herder WW, Thakker RV, Caplin M, Delle Fave G, Kaltsas GA, Krenning EP, Moss SF, Nilsson O, Rindi G, Salazar R, Ruzsniwski P, Sundin A. Gastroenteropancreatic neuroendocrine tumours. *Lancet Oncol* 2008; **9**: 61-72
- 19 Borch K, Ahrén B, Ahlman H, Falkmer S, Granérus G, Grimelius L. Gastric carcinoids: biologic behavior and prognosis after differentiated treatment in relation to type. *Ann Surg*

- 2005; **242**: 64-73
- 20 Annibale B, Lahner E, Negrini R, Baccini F, Bordi C, Monarca B, Delle Fave G. Lack of specific association between gastric autoimmunity hallmarks and clinical presentations of atrophic body gastritis. *World J Gastroenterol* 2005; **11**: 5351-5357
 - 21 Dockray GJ. Clinical endocrinology and metabolism. Gastrin. *Best Pract Res Clin Endocrinol Metab* 2004; **18**: 555-568
 - 22 Gibril F, Reynolds JC, Lubensky IA, Roy PK, Peghini PL, Doppman JL, Jensen RT. Ability of somatostatin receptor scintigraphy to identify patients with gastric carcinoids: a prospective study. *J Nucl Med* 2000; **41**: 1646-1656
 - 23 Orlefors H, Sundin A, Garske U, Juhlin C, Oberg K, Skogseid B, Langstrom B, Bergstrom M, Eriksson B. Whole-body (11)C-5-hydroxytryptophan positron emission tomography as a universal imaging technique for neuroendocrine tumors: comparison with somatostatin receptor scintigraphy and computed tomography. *The Journal of clinical endocrinology and metabolism* 2005; **90**: 3392-3400
 - 24 Kulke MH, Anthony LB, Bushnell DL, de Herder WW, Goldsmith SJ, Klimstra DS, Marx SJ, Pasieka JL, Pommier RF, Yao JC, Jensen RT. NANETS treatment guidelines: well-differentiated neuroendocrine tumors of the stomach and pancreas. *Pancreas* 2010; **39**: 735-752
 - 25 Ravizza D, Fiori G, Trovato C, Fazio N, Bonomo G, Luca F, Bodei L, Pelosi G, Tamayo D, Crosta C. Long-term endoscopic and clinical follow-up of untreated type 1 gastric neuroendocrine tumours. *Dig Liver Dis* 2007; **39**: 537-543
 - 26 Ichikawa J, Tanabe S, Koizumi W, Kida Y, Imaizumi H, Kida M, Saigenji K, Mitomi H. Endoscopic mucosal resection in the management of gastric carcinoid tumors. *Endoscopy* 2003; **35**: 203-206
 - 27 Richards ML, Gauger P, Thompson NW, Giordano TJ. Regression of type II gastric carcinoids in multiple endocrine neoplasia type 1 patients with Zollinger-Ellison syndrome after surgical excision of all gastrinomas. *World J Surg* 2004; **28**: 652-658
 - 28 Lawrence B, Kidd M, Svejda B, Modlin I. A clinical perspective on gastric neuroendocrine neoplasia. *Curr Gastroenterol Rep* 2011; **13**: 101-109
 - 29 Niederle MB, Niederle B. Diagnosis and treatment of gastroenteropancreatic neuroendocrine tumors: current data on a prospectively collected, retrospectively analyzed clinical multicenter investigation. *Oncologist* 2011; **16**: 602-613
 - 30 Reddy SK, Clary BM. Neuroendocrine liver metastases. *Surg Clin North Am* 2010; **90**: 853-861
 - 31 Whitney R, Tatum C, Hahl M, Ellis S, Scoggins CR, McMasters K, Martin RC. Safety of hepatic resection in metastatic disease to the liver after yttrium-90 therapy. *J Surg Res* 2011; **166**: 236-240
 - 32 Le Treut YP, Delpero JR, Dousset B, Cherqui D, Segol P, Manton G, Hannoun L, Benhamou G, Launois B, Boillot O, Domergue J, Bismuth H. Results of liver transplantation in the treatment of metastatic neuroendocrine tumors. A 31-case French multicentric report. *Ann Surg* 1997; **225**: 355-364
 - 33 Mazzaferro V, Pulvirenti A, Coppa J. Neuroendocrine tumors metastatic to the liver: how to select patients for liver transplantation? *J Hepatol* 2007; **47**: 460-466
 - 34 Rinke A, Müller HH, Schade-Brittinger C, Klose KJ, Barth P, Wied M, Mayer C, Aminossadati B, Pape UF, Bläker M, Harder J, Arnold C, Gress T, Arnold R. Placebo-controlled, double-blind, prospective, randomized study on the effect of octreotide LAR in the control of tumor growth in patients with metastatic neuroendocrine midgut tumors: a report from the PROMID Study Group. *J Clin Oncol* 2009; **27**: 4656-4663
 - 35 Bajetta E, Zilembo N, Di Bartolomeo M, Di Leo A, Pilotti S, Bochicchio AM, Castellani R, Buzzoni R, Celio L, Dogliotti L. Treatment of metastatic carcinoids and other neuroendocrine tumors with recombinant interferon-alpha-2a. A study by the Italian Trials in Medical Oncology Group. *Cancer* 1993; **72**: 3099-3105
 - 36 Dirix LY, Vermeulen PB, Fierens H, De Schepper B, Corthouts B, Van Oosterom AT. Long-term results of continuous treatment with recombinant interferon-alpha in patients with metastatic carcinoid tumors—an antiangiogenic effect? *Anticancer Drugs* 1996; **7**: 175-181
 - 37 Eriksson B, Oberg K, Alm G, Karlsson A, Lundqvist G, Andersson T, Wilander E, Wide L. Treatment of malignant endocrine pancreatic tumours with human leucocyte interferon. *Lancet* 1986; **2**: 1307-1309
 - 38 Faiss S, Pape UF, Böhmig M, Dörrfel Y, Mansmann U, Goldner W, Riecken EO, Wiedenmann B. Prospective, randomized, multicenter trial on the antiproliferative effect of lanreotide, interferon alfa, and their combination for therapy of metastatic neuroendocrine gastroenteropancreatic tumors—the International Lanreotide and Interferon Alfa Study Group. *J Clin Oncol* 2003; **21**: 2689-2696
 - 39 Pisegna JR, Slimak GG, Doppman JL, Strader DB, Metz DC, Benya RV, Orbuch M, Fishbeyn VA, Fraker DL, Norton JA. An evaluation of human recombinant alpha interferon in patients with metastatic gastrinoma. *Gastroenterology* 1993; **105**: 1179-1183
 - 40 Schöber C, Schmolle E, Schmolle HJ, Poliwoda H, Schuppert F, Stahl M, Bokemeyer C, Wilke H, Weiss J. Antitumour effect and symptomatic control with interferon alpha 2b in patients with endocrine active tumours. *Eur J Cancer* 1992; **28A**: 1664-1666
 - 41 Bukowski RM, Tangen CM, Peterson RF, Taylor SA, Rinehart JJ, Eyre HJ, Rivkin SE, Fleming TR, Macdonald JS. Phase II trial of dimethyltriazenoimidazole carboxamide in patients with metastatic carcinoid. A Southwest Oncology Group study. *Cancer* 1994; **73**: 1505-1508
 - 42 Ekeblad S, Sundin A, Janson ET, Welin S, Granberg D, Kindmark H, Dunder K, Kozlovacki G, Orlefors H, Sigurd M, Oberg K, Eriksson B, Skogseid B. Temozolomide as monotherapy is effective in treatment of advanced malignant neuroendocrine tumors. *Clin Cancer Res* 2007; **13**: 2986-2991
 - 43 Engstrom PF, Lavin PT, Moertel CG, Folsch E, Douglass HO. Streptozocin plus fluorouracil versus doxorubicin therapy for metastatic carcinoid tumor. *J Clin Oncol* 1984; **2**: 1255-1259
 - 44 Kelsen D, Fiore J, Heelan R, Cheng E, Magill G. Phase II trial of etoposide in APUD tumors. *Cancer Treat Rep* 1987; **71**: 305-307
 - 45 McCollum AD, Kulke MH, Ryan DP, Clark JW, Shulman LN, Mayer RJ, Bartel S, Fuchs CS. Lack of efficacy of streptozocin and doxorubicin in patients with advanced pancreatic endocrine tumors. *Am J Clin Oncol* 2004; **27**: 485-488
 - 46 Moertel CG, Hanley JA, Johnson LA. Streptozocin alone compared with streptozocin plus fluorouracil in the treatment of advanced islet-cell carcinoma. *N Engl J Med* 1980; **303**: 1189-1194
 - 47 Kulke MH, Lenz HJ, Meropol NJ, Posey J, Ryan DP, Picus J, Bergsland E, Stuart K, Tye L, Huang X, Li JZ, Baum CM, Fuchs CS. Activity of sunitinib in patients with advanced neuroendocrine tumors. *J Clin Oncol* 2008; **26**: 3403-3410
 - 48 Yao JC, Phan A, Hoff PM, Chen HX, Charnsangavej C, Yeung SC, Hess K, Ng C, Abbruzzese JL, Ajani JA. Targeting vascular endothelial growth factor in advanced carcinoid tumor: a random assignment phase II study of depot octreotide with bevacizumab and pegylated interferon alpha-2b. *J Clin Oncol* 2008; **26**: 1316-1323
 - 49 Yao JC, Phan AT, Chang DZ, Wolff RA, Hess K, Gupta S, Jacobs C, Mares JE, Landgraf AN, Rashid A, Meric-Bernstam F. Efficacy of RAD001 (everolimus) and octreotide LAR in advanced low- to intermediate-grade neuroendocrine tumors: results of a phase II study. *J Clin Oncol* 2008; **26**: 4311-4318
 - 50 Kwekkeboom DJ, de Herder WW, Kam BL, van Eijck CH,

- van Essen M, Kooij PP, Feelders RA, van Aken MO, Krenning EP. Treatment with the radiolabeled somatostatin analog [177 Lu-DOTA 0,Tyr3]octreotate: toxicity, efficacy, and survival. *J Clin Oncol* 2008; **26**: 2124-2130
- 51 Landry CS, Brock G, Scoggins CR, McMasters KM, Martin RC. A proposed staging system for gastric carcinoid tumors based on an analysis of 1,543 patients. *Ann Surg Oncol* 2009; **16**: 51-60
- 52 Hou W, Schubert ML. Treatment of gastric carcinoids. *Curr Treat Options Gastroenterol* 2007; **10**: 123-133
- 53 Yao JC, Hassan M, Phan A, Dagohoy C, Leary C, Mares JE, Abdalla EK, Fleming JB, Vauthey JN, Rashid A, Evans DB. One hundred years after "carcinoid": epidemiology of and prognostic factors for neuroendocrine tumors in 35,825 cases in the United States. *J Clin Oncol* 2008; **26**: 3063-3072
- 54 Bilimoria KY, Bentrem DJ, Wayne JD, Ko CY, Bennett CL, Talamonti MS. Small bowel cancer in the United States: changes in epidemiology, treatment, and survival over the last 20 years. *Ann Surg* 2009; **249**: 63-71
- 55 Garbrecht N, Anlauf M, Schmitt A, Henopp T, Sipos B, Raffel A, Eisenberger CF, Knoefel WT, Pavel M, Fottner C, Musholt TJ, Rinke A, Arnold R, Berndt U, Plöckinger U, Wiedenmann B, Moch H, Heitz PU, Komminoth P, Perren A, Klöppel G. Somatostatin-producing neuroendocrine tumors of the duodenum and pancreas: incidence, types, biological behavior, association with inherited syndromes, and functional activity. *Endocr Relat Cancer* 2008; **15**: 229-241
- 56 Clements WM, Martin SP, Stemmerman G, Lowy AM. Ampullary carcinoid tumors: rationale for an aggressive surgical approach. *J Gastrointest Surg* ; **7**: 773-776
- 57 Soga J. Endocrinocarcinomas (carcinoids and their variants) of the duodenum. An evaluation of 927 cases. *J Exp Clin Cancer Res* 2003; **22**: 349-363
- 58 Pipeleers-Marichal M, Donow C, Heitz PU, Klöppel G. Pathologic aspects of gastrinomas in patients with Zollinger-Ellison syndrome with and without multiple endocrine neoplasia type I. *World J Surg* ; **17**: 481-488
- 59 Capella C, Riva C, Rindi G, Usellini L, Chiaravalli A, Solcia E. Endocrine tumors of the duodenum and upper jejunum. A study of 33 cases with clinico-pathological characteristics and hormone content. *Hepatogastroenterology* 1990; **37**: 247-252
- 60 Sata N, Tsukahara M, Koizumi M, Yoshizawa K, Kurihara K, Nagai H, Someya T, Saito K. Primary small-cell neuroendocrine carcinoma of the duodenum - a case report and review of literature. *World J Surg Oncol* 2004; **2**: 28
- 61 Klöppel G, Rindi G, Anlauf M, Perren A, Komminoth P. Site-specific biology and pathology of gastroenteropancreatic neuroendocrine tumors. *Virchows Arch* 2007; **451** Suppl 1: S9-27
- 62 Hoffmann KM, Furukawa M, Jensen RT. Duodenal neuroendocrine tumors: Classification, functional syndromes, diagnosis and medical treatment. *Best Pract Res Clin Gastroenterol* 2005; **19**: 675-697
- 63 Jensen RT, Niederle B, Mitry E, Ramage JK, Steinmuller T, Lewington V, Scarpa A, Sundin A, Perren A, Gross D, O'Connor JM, Pauwels S, Kloppel G. Gastrinoma (duodenal and pancreatic). *Neuroendocrinology* 2006; **84**: 173-182
- 64 Weber HC, Venzon DJ, Lin JT, Fishbein VA, Orbuch M, Strader DB, Gibril F, Metz DC, Fraker DL, Norton JA. Determinants of metastatic rate and survival in patients with Zollinger-Ellison syndrome: a prospective long-term study. *Gastroenterology* 1995; **108**: 1637-1649
- 65 Dalenbäck J, Havel G. Local endoscopic removal of duodenal carcinoid tumors. *Endoscopy* 2004; **36**: 651-655
- 66 Ito T, Tanaka M, Sasano H, Osamura YR, Sasaki I, Kimura W, Takano K, Obara T, Ishibashi M, Nakao K, Doi R, Shimatsu A, Nishida T, Komoto I, Hirata Y, Imamura M, Kawabe K, Nakamura K. Preliminary results of a Japanese nationwide survey of neuroendocrine gastrointestinal tumors. *J Gastroenterol* 2007; **42**: 497-500

Peer reviewer: Sun-Young Lee MD, PhD, Department of Internal Medicine, Konkuk University Medical Center, 4-12 Hwayang-dong, Gwangjin-gu, Seoul 143-729, Korea.