

Adult Multisystem Langerhans Cell Histiocytosis with Gastrointestinal Presentation: A Case Report

Muhammad Firdaus Md Salleh, Nik Raihan Nik Mustapha, Zalwani Zainuddin, Kuang Kiat Kiew, Mohd Azri Mohd Suan, Muhammad Radzi Abu Hassan

Muhammad Firdaus Md Salleh, Gastroenterology Unit, Medical Department, Hospital Sultanah Bahiyah, Malaysia

Nik Raihan Nik Mustapha, Department of Pathology, Hospital Sultanah Bahiyah, Alor Setar, Kedah, Malaysia

Zalwani Zainuddin, Gastroenterology Unit, Medical Department, Hospital Sultanah Bahiyah, Alor Setar, Kedah, Malaysia

Kuang Kiat Kiew, Gastroenterology Unit, Medical Department, Hospital Sultanah Bahiyah, Alor Setar, Kedah, Malaysia

Mohd Azri Mohd Suan, Clinical Research Center, Hospital Sultanah Bahiyah, Malaysia

Muhammad Radzi Abu Hassan, Gastroenterology Unit, Medical Department, Hospital Sultanah Bahiyah, Alor Setar, Kedah, Malaysia

Correspondence to: Muhammad Radzi Abu Hassan, Gastroenterology Unit, Medical Department, Hospital Sultanah Bahiyah, Alor Setar, Kedah, Malaysia.

Email: irzah96@yahoo.com; drradzi91@yahoo.co.uk

Telephone: +6047406227

Fax: +6047407373

Received: May 1, 2016

Revised: June 8, 2016

Accepted: June 12, 2016

Published online: August 21, 2016

ABSTRACT

Langerhans cell histiocytosis is a rare histiocytic disorder, characterised by histiocyte infiltration of the body organ. Although this disease has been diagnosed in all age groups, it is most common in children from one to three years old. The LCH patients may vary in presentation depending upon the sites and extent of involvement. The disease is limited to one organ system in approximately 55% of patients while the remainder presents with multisystem disease. Gastrointestinal involvement of Langerhans cell histiocytosis is even rarer. The majority of gastrointestinal Langerhans cell histiocytosis are from paediatric cases. We present a case of a 69-year old female who had presented with chronic diarrhoea for a three month duration, associated with a significant weight loss.

Clinical examination and biochemical tests ruled out thyrotoxicosis. Colonoscopy showed mild to moderate pancolitis. Histopathological examination of the colonic mucosa confirmed Langerhans cell histiocytosis.

Key words: Adult; Colonoscopy; Gastrointestinal Tract; Histiocytosis; Langerhans-Cell

© 2016 The Authors. Published by ACT Publishing Group Ltd.

Salleh MFM, Mustapha NRN, Zainuddin Z, Kiew KT, Suan MAM, Hassan MRA. Adult Multisystem Langerhans Cell Histiocytosis with Gastrointestinal Presentation: A Case Report. *Journal of Gastroenterology and Hepatology Research* 2016; 5(4): 2152-2155 Available from: URL: <http://www.ghrnet.org/index.php/joghr/article/view/1701>

INTRODUCTION

Langerhans cell histiocytosis (LCH) is a rare disorder of unknown cause. The granuloma-like pathologic lesion is crucially characterised by cells sharing many characteristics with normal cutaneous Langerhans cells and variably associated with collections of T-lymphocytes, macrophages, neutrophils and eosinophils^[1]. These cells, now known as LCH cells, are CD1a and Langerin-positive. LCH encompasses a spectrum of disorders with diverse clinical presentations, ranging from single organ to multiple organ involvements, which includes bone, skin, lung, gut, liver, bone marrow and central nervous system. LCH can occur at any age, but the peak incidence is in children below two years old^[1-3].

The LCH patients may present with gastrointestinal involvement, yet symptoms like diarrhoea and failure to thrive, are nonspecific. The reported incidence ranges from 2% to 13%, but the actual figure is unknown. Well-documented colon involvement is very rare, with fewer than 20 convincing published reports worldwide. In these instances, initial presenting symptoms included diarrhoea, sometimes with blood or mucus, malabsorption, failure to thrive and oedema

secondary to protein-losing enteropathy. We present a case of an adult female with colonic LCH, who presented with chronic diarrhoea, weight loss, and hypoalbuminaemia.

CASE REPORT

A 69-year old female with no known underlying comorbidity had presented with multiple episodes of diarrhoea over the preceding three months, which had started without any apparent precipitant. She described diarrhoea as being a loose stool, a small volume with more than ten episodes per day and even had to wake up in the middle of the night to purge. There was associated generalised mild crampy abdominal pain, which resolved after purging. She had never experienced prior similar episodes. There was no complaint of fever and chills, and she did not notice any mucous or blood in the stool. She had denied any prior recent trip before diarrhoea started. In addition to non-significant personal or family history of colon or small bowel malignancy, she also denied alcohol consumption, smoking, or illicit drug use. She had no known allergies, and she was not on any medication or supplement. Before presenting to our hospital, she had been prescribed with ciprofloxacin for her diarrhoea, which she took for seven days but without any relief.

During our clinic assessment, she appeared haemodynamically stable. Her physical examination was unremarkable. Her initial laboratory results were notable for albumin of 22 g/dL and haemoglobin of 9.6 gm/dL, with normal white cell count (6.2×10^3 /uL) and platelets (288×10^3 /uL). Her renal profile was also normal. Additionally, the patient had negative stool studies for ova and parasites, as well as, negative stool cultures. Her Human Immunodeficiency Virus (HIV) test was nonreactive, and thyroid-stimulating hormone was within normal limit.

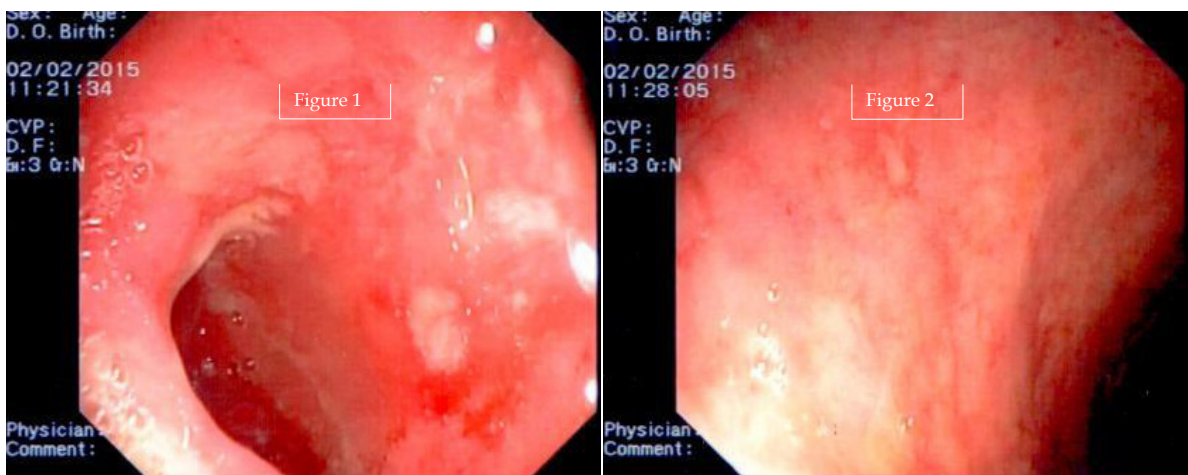
A colonoscopy was performed within a few days following the clinic review, which revealed pancolitis, represented by generalised colonic mucosal erythema, small superficial ulcerations, and loss of vascular pattern (Figures 1 and 2). Ileocaecal valve and terminal ileal mucosa appeared normal. Biopsies from terminal ileum and each colonic segment were obtained. Her oesophagogastroduodenoscopy (OGDS) showed normal findings.

On histology examination (Figures 3, 4, 5 and 6), all the biopsied areas in the large bowel, as well as, terminal ileum revealed irregular mucosal infiltration by varying amount of fairly large atypical cells,

which resulted in partial/variable crypt loss and villous flattening. These abnormal cells displayed oval, variably convoluted/folded nuclei and with fine chromatin pattern. Some cells had one to two small nucleoli. Cytoplasm was pale and fairly abundant. Mitoses were seen scattered, with proliferative index (ki-67) of about 50% observed. The atypical cells infiltrated a few crypts, giving an appearance reminiscent of lymphoepithelial lesions. There was also a remarkable number of eosinophils, neutrophils, histiocytes and lymphoplasmacytic cells noted in the background. Immunohistochemically, these abnormal cells were positive for vimentin, S-100 protein, CD1a, and Langerin (Figure 7, 8 and 9). Negative staining was observed with CD20, CD79a, BCL2, CD2, CD3, CD7, CD8, TdT, CD30, CD15, ALK-1 protein, myeloperoxidase, as well as, pancytokeratin markers. With triple positivity for S-100 protein, CD1a, and Langerin, the diagnosis of intestinal Langerhans cell histiocytosis was histologically confirmed.

Following the histologic diagnosis, a whole body computerized tomography (CT) scan was done, and showed features of colitis, associated with mesenteric and pericolic lymphadenopathy. There were no sclerotic or lytic bone lesions identified. The liver and spleen were of normal size. A bone marrow aspiration and trephine biopsy showed reactive features with an increased number of plasma cells. Some haemophagocytic activity was also revealed on bone marrow analysis, following which, she was clinically concluded as having multiorgan LCH with high-risk organ involvement.

Partial remission was achieved following a 6-week course of chemotherapy, consisting of vinblastine and prednisolone. A repeated CT scan upon completion of the initial 6-week chemotherapy revealed a reduced size of the right upper deep cervical node from 1.1 to 0.7 cm, reduced the size of mesenteric lymph nodes from 1.3 cm (biggest) to 0.9cm and disappearance of the pericolic lymphadenopathy and pericolic streakiness. Clinically, the symptom of diarrhoea had resolved. The second course of induction phase chemotherapy which consists of the same regime of vinblastine and prednisolone for 6-week was given, and she responded well too. The CT scan upon completion the second course of the induction chemotherapy had revealed no significantly enlarged lymph nodes. She is now on maintenance phase chemotherapy, consisting of vinblastine and prednisolone with mercaptopurine and she is planned to complete a total of a 12-month duration of treatment.



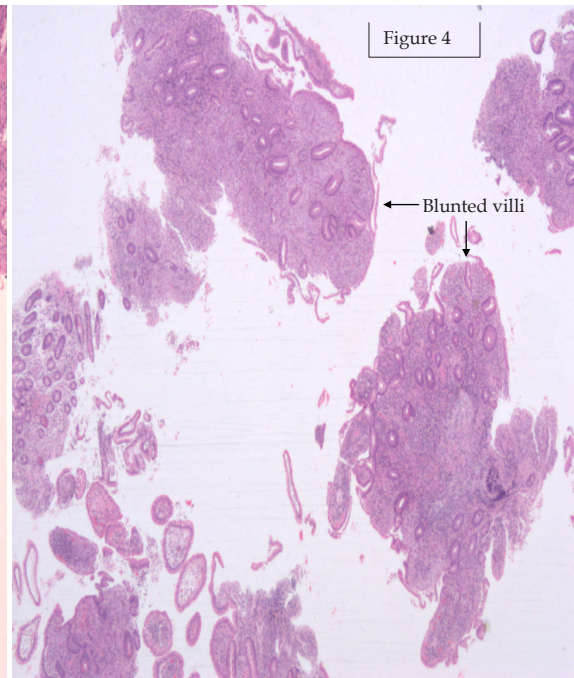
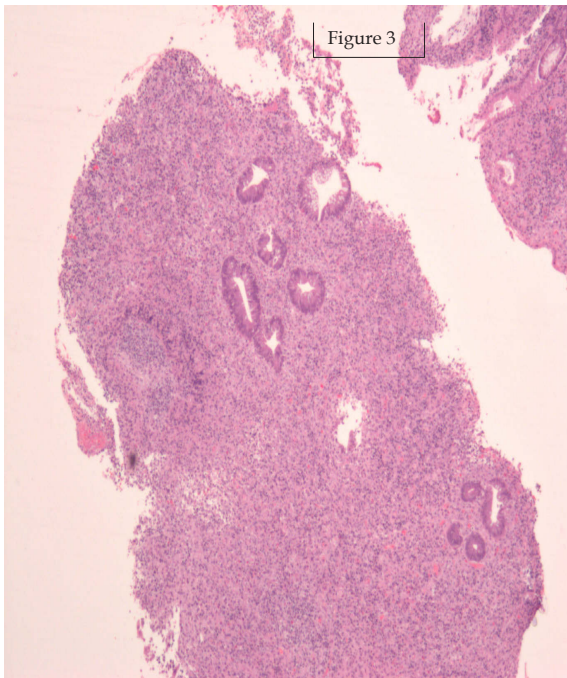
Figures 1 and 2 Colonoscopic images from the patient: Note the changes of colitis, represented by generalized erythema, mucosal oedema and superficial ulcerations.

DISCUSSION

Gastrointestinal involvement by LCH is a highly uncommon condition, being reported in fewer than 2% of cases^[4,5]. When present, it is often associated with multisystem disease^[1,5]. Geissmann *et al* reported that the gastrointestinal tract involvement is found to be the least involved site at initial presentation^[4]. Children with gastrointestinal LCH present with failure to thrive, bloody diarrhoea and anaemia^[6]. Endoscopically, it shows an involvement of the duodenum and multiple colonic sites. In contrast to paediatrics, 50% of adult patients are asymptomatic^[6,7]. Adult cases are predominantly females, are encountered incidentally as a solitary polyp (80%) that

primarily involving the colorectum (88%) and are associated with good prognosis^[6]. Although rare, physician should be aware that this condition does exist among adult population.

Histologic diagnosis is based on the findings of abnormal cell infiltration that display morphologic and immunohistochemical (positivity for CD1a, Langerin, and S-100 protein) characteristics similar to cutaneous Langerhans cells^[8-11]. Once the diagnosis of LCH is confirmed by histopathology, further workups are to be carried out to determine if the disease is a single- or multi-system or with the involvement of 'risk organs' (i.e. liver, spleen, marrow). Patients are risk stratified based upon the extent of disease. An initial risk stratification scheme was suggested based on data from the LCH-I randomised study^[5].



Figures 3 and 4: Low power view of large bowel mucosa (Figure 3) and terminal ileum (Figure 4): There is increased lamina propria cellularity, associated with ulceration, crypt loss and villous blunting.

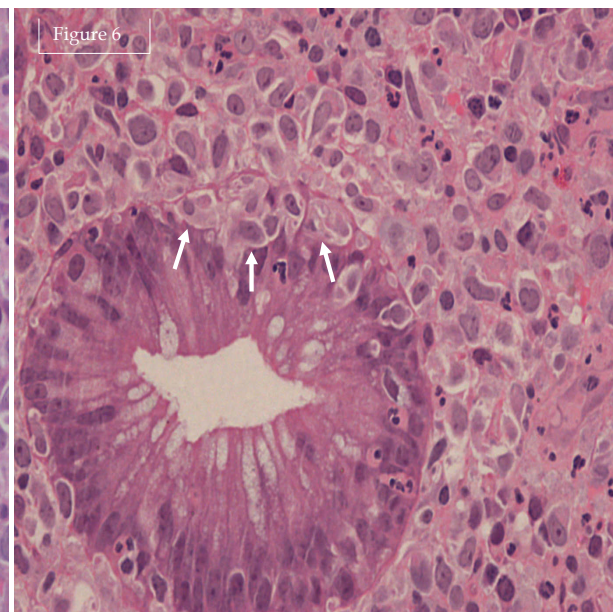
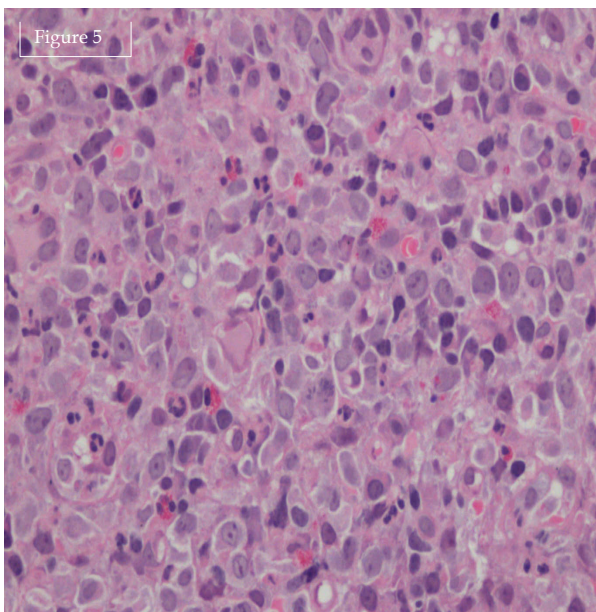


Figure 5 High power view showing abnormal cells admixed with eosinophils and neutrophils. The former are fairly large, exhibiting oval, variably folded nuclei, with fine chromatin pattern and abundant cytoplasm. They infiltrate the crypt epithelium (**Figure 6**), giving an appearance of lymphoepithelial-like lesion (arrows).

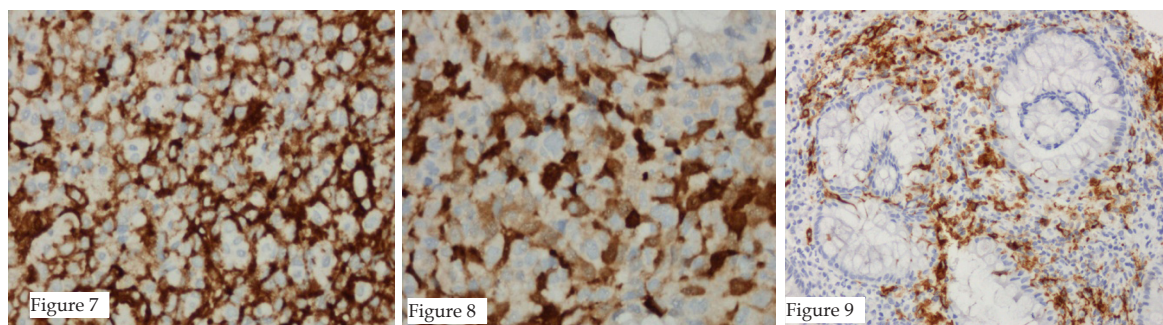


Figure 7, 8 and 9: Positive immunohistochemical staining were observed with CD1a, S-100 protein and Langerin, respectively.

There have been no clinical trials to inform practitioners of the optimal therapy for adult patients. In the paediatric model, the choice of treatment is made based upon the site of involvement and number of lesions with an aim to minimise toxicity. Treatment options include single-agent prednisone, the combination of vinblastine and prednisone^[5,12], curettage of bone lesions, and topical therapy for skin problems. Alternatively, a subset of patients may select close observation with treatment upon progression. None of these management options has been directly compared in prospective trials.

In LCH-III study, Gardner *et al* found that 66% of patients with "risk organ" involvement and 86% of patients without "risk organ" involvement demonstrated a response to therapy by six weeks^[12]. Subsequent treatment is dependent upon disease response at six weeks and whether "risk organs" (i.e. hematopoietic system, liver, and/or spleen) were involved at the time of diagnosis. Patients with an adequate response should proceed with maintenance phase of chemotherapy until a total treatment duration of 12 months is completed^[13]. Maintenance chemotherapy consists of vinblastine and prednisolone with mercaptopurine added for patients with risk-organ involvement. Patients without an adequate response may undergo a second induction phase or proceed with second-line chemotherapy regimens^[5,13]. Finally, multidisciplinary collaboration is essential for better management of this complex and rare disease.

CONFLICT OF INTEREST

All authors declared no potential conflicts of interest. All authors received no financial support.

REFERENCES

- 1 Windebank K, Nanduri V. Langerhans cell histiocytosis. *Arch Dis Child* 2009; **94**(11): 904-908
- 2 Aruna DR, Pushpalatha G, Galgali S, Prashanthi. Langerhans cell histiocytosis. *J Indian Soc Periodontol* 2011; **15**(3): 276-279
- 3 Selim MA, Shea CR. Langerhans Cell Histiocytosis [Internet]. [cited 2015 Oct 22]. Available from: <http://www.emedicine.medscape.com>
- 4 Geissmann F, Thomas C, Emile JF, Micheau M, Canioni D, Cerf-Bensussan N, *et al* Digestive tract involvement in Langerhans cell histiocytosis. The French Langerhans Cell Histiocytosis Study Group. *J Pediatr* 1996; **129**(6): 836-845
- 5 Gardner H, Grois N, Arico M, Broadbent V, Ceci A, Jakobson A, Komp D, Michaelis J, Nicholson S, Pötschger U, Pritchard J, Ladisch S. A randomized trial of treatment for multisystem Langerhans' cell histiocytosis. *J Pediatr* 2001; **138**(5): 728-734
- 6 Singhi AD, Montgomery EA. Gastrointestinal tract langerhans cell histiocytosis: A clinicopathologic study of 12 patients. *Am J Surg Pathol* 2011; **35**(2): 305-301.
- 7 Hait E, Liang M, Degar B, Glickman J, Fox VL. Gastrointestinal tract involvement in Langerhans cell histiocytosis: case report and literature review. *Pediatrics* 2006; **118**(5): e1593-9.
- 8 Wilson AJ, Maddox PH, Jenkins D. CD1a and S100 antigen expression in skin Langerhans cells in patients with breast cancer. *J Pathol* 1991; **163**(1): 25-30
- 9 Lau SK, Chu PG, Weiss LM. Immunohistochemical expression of Langerin in Langerhans cell histiocytosis and non-Langerhans cell histiocytic disorders. *Am J Surg Pathol* 2008; **32**(4): 615-619
- 10 Jenny Valladeau, Odile Ravel, Colette Dezutter-Dambuyant, Kevin Moore, Monique Kleijmeer, Ying Liu, Valérie Duvert-Frances, Claude Vincent, Daniel Schmitt, Jean Davoust, Christophe Caux, Serge Lebecque, Sem Saeland, correspondencePress enter key for correspondence informationemail. Langerin, a novel C-type lectin specific to Langerhans cells, is an endocytic receptor that induces the formation of Birbeck granules. *Immunity* 2000; **12**(1): 71-81
- 11 Coppola D, Fu L, Nicosia SV, Kounelis S, Jones M. Prognostic significance of p53, bcl-2, vimentin, and S100 protein-positive Langerhans cells in endometrial carcinoma. *Hum Pathol* 1998; **29**(5): 455-462
- 12 Gardner H, Grois N, Pötschger U, Minkov M, Aricò M, Braier J, Broadbent V, Donadieu J, Henter JI, McCarter R, Ladisch S. Improved outcome in multisystem Langerhans cell histiocytosis is associated with therapy intensification. *Blood* 2008; **111**(5): 2556-2562
- 13 Langerhans Cell Histiocytosis: Evaluation and Treatment Guidelines [Internet]. Histiocyte Society; 2009 [cited 2015 Jul 22]. Available from: <http://www.histiocytesociety.org/document.doc?id=290>

Peer reviewer: Everson L.A. Artifon, Professor, Rua guimaraes passos 260 apto 111, University of Sao Paulo(USP)-Sao Paulo, Brazil.