

## Major Motility Abnormality (MMA): A Needed But Unusual Category of Esophageal Dysmotility

Mustafa Abdul-Hussein, Katherine Boland, Stephen Schable, Donald Castell

Mustafa Abdul-Hussein, MD, Esophageal motility fellow, Medical University of South Carolina, 114 Doughty St., Suite 249, MSC 702, Charleston, SC 29425, the United States

Katherine Boland, BS, Medical University of South Carolina, the United States

Stephen Schable, MD, Professor, Department of radiology, Medical University of South Carolina, the United States

Donald Castell, MD, Professor, department of medicine, Gastroenterology and Hepatology, Director, esophageal disorders program, Medical University of South Carolina, the United States

Correspondence to: Mustafa Abdul-Hussein, MD, Esophageal motility fellow, Medical University of South Carolina, 114 Doughty St., Suite 249, MSC 702, Charleston, SC 29425, the United States.

Email: [abdulahu@musc.edu](mailto:abdulahu@musc.edu)

Telephone: +1-843-792-2301

Fax: +1-843-876-7232

Received: May 10, 2016

Revised: June 8, 2016

Accepted: June 10, 2016

Published online: June 21, 2016

### ABSTRACT

**BACKGROUND:** A small group of patients with esophageal motility abnormalities including achalasia are difficult to diagnose definitely with esophageal manometry. In our laboratory we invoke the term “major motility abnormality” (MMA) to incorporate diagnosis of two motility disorders with overlapping features, while conveying a message to the referring physician that the manometry is definitely abnormal. The aim of this study was to investigate the role of barium esophagram (BE) as the next step in helping to sort out the diagnosis in this group of patients.

**METHODS:** A retrospective review was performed of high resolution manometry (HRM) studies performed in our laboratory over 27 months from Aug 2012-Oct 2014 to identify the eventual diagnosis of patients with MMA, with special interest in those who

have achalasia as one of the potential diagnoses on manometry. BE interpretation was performed by a single radiologist blinded from manometry results. Criteria used to exclude achalasia were presence of primary peristalsis, esophago-gastric junction (EGJ) diameter greater than 12.5 mm to exclude a typical “bird beak”, and esophageal dilatation.

**RESULTS:** 68 of 1971 (3.4%) patients seen in our Esophageal Disorders clinic were diagnosed as MMA by HRM; 29/68 (42.6%) had achalasia as a potential manometric diagnosis. BE interpretation was felt to exclude achalasia in 25/29 (86%) of these patients. 14/29 had features of achalasia and Ineffective Esophageal Manometry (IEM); BE was felt to rule out achalasia in all of them (100%). 11/29 had features of achalasia and distal esophageal spasm (DES); BE showed no achalasia in 8/11 (72%). 4/29 had features of achalasia and scleroderma; BE excluded achalasia in 3/4 (75%).

**CONCLUSION:** MMA is an unusual motility diagnosis we find helpful when HRM is confusing. We believe that BE is an important complementary diagnostic test to rule out achalasia in patients with an ambiguous manometry study finding of MMA. Do not forget the BE!!

**Key words:** Achalasia; Esophageal dysmotility

© 2016 The Authors. Published by ACT Publishing Group Ltd.

Abdul-Hussein M, Boland K, Schable S, Castell D. Major Motility Abnormality (MMA): A Needed But Unusual Category of Esophageal Dysmotility. *Journal of Gastroenterology and Hepatology Research* 2016; 5(3): 2082-2087 Available from: URL: <http://www.ghrnet.org/index.php/joghr/article/view/1705>

### INTRODUCTION

Patients with esophageal motility disorders can exhibit a variety of symptoms, including dysphagia, chest pain and regurgitation. Patients

with suspected esophageal dysmotility are frequently referred for esophageal manometry testing. The barium esophagram would appear to be used with lesser frequency at present in the evaluation of esophageal diseases probably because of wide availability of endoscopy and decreasing interest in BE by radiologists.

We believe that BE plays an important role in the diagnostic work up of esophageal disorders, both structural and functional. Previous studies showed that BE had comparative sensitivity and specificity with both endoscopy<sup>[1]</sup> and manometry<sup>[2-6]</sup> in several structural and functional esophageal abnormalities and had good association in patients with a diagnosis of achalasia<sup>[7]</sup>.

Esophageal manometry; both conventional and high resolution play a crucial and important role in the diagnosis of esophageal motility disorders. However, some motility abnormalities are complex and difficult to fit into a well characterized classification. This kind of abnormality can be challenging even to experts in this field. We recently conducted a survey of expert esophagologists showing that they are faced with complex and challenging tracings in about 10% of cases<sup>[8]</sup>. Major Motility Abnormality (MMA) is an esophageal manometric diagnosis that is reserved for patients whose motility study is clearly abnormal, but difficult to simply categorize into one of the “named” motility abnormalities. The aim of this study is evaluate the role of BE in helping to solve complicated and difficult to interpret esophageal motility abnormalities found on manometry.

## METHODS

### Patient Population

A retrospective review was performed of HRM studies from Aug 2012-Oct 2014 to identify patients with a diagnosis of MMA, with special interest in those who have achalasia as one of the potential manometric diagnoses. MMA diagnoses that do not have achalasia as a potential diagnosis were excluded. Patients who did not have their BE done in our institution also were excluded. A total of 1971 consecutive HRM studies were reviewed, 68/1971 (3.4%) of these had MMA on their final report and BE recommended as a next step. Of these, 45 had features of achalasia and either IEM or scleroderma in their final reports. 29/45 had their BE done in our institution. The other 16 who had their BE in another facility were excluded. BE results were evaluated by a single radiologist blinded from manometry results. Primary criteria used to exclude achalasia were presence of definite primary peristalsis and lower esophageal EG junction diameter > 12.5 mm (i.e. absence of a “bird beak”). Other criteria used to exclude achalasia were diameter of the esophageal body less than the width of the vertebral body and absent esophageal fluid level<sup>[9]</sup>. The Institutional Review Board at the Medical University of South Carolina approved this retrospective analysis.

### Testing Procedures

The Sandhill Scientific Inc. HRM probe (Sandhill Scientific Inc, Highlands Ranch, CO) has 32 circumferential pressure sensors spaced 1 cm apart and 16 impedance channels with 2 cm spacing. The study is acquired with high resolution guided protocol on the Sandhill Scientific Inc. InSIGHT™ Acquisition software and analyzed using BioVIEW Analysis dedicated software. Esophageal manometry was performed using this combined high-resolution impedance-manometry system. Esophageal function testing was conducted in our standard fashion. After nasal local anesthesia (lidocaine gel), the HRM catheter was passed through the nasal cavity

into the pharynx. Further intubation into the stomach up to a depth of 60 cm was facilitated by repeated water swallows. The catheter was then slowly pulled back in a step-by-step (0.5 to 1.0) fashion to identify the lower esophageal sphincter (LES). The catheter was positioned so that impedance segments were located 5, 10, 15, and 20 cm above the LES. Once proper catheter placement was confirmed with real-time waveform analysis and identification of the LES, the catheter was fixed in place by taping it to the nose. Subjects then underwent standard HRM testing involving 10 liquid (5 mL saline 0.9%) and 10 viscous swallows. Subsequently, the data were analyzed with the Sandhill BioVIEW Analysis Suite 64 software. This software package allowed each interpreter to analyze each swallow using pressure topography plots by calculating esophageal body measures including the distal contractile integral (DCI), distal latency (DL) and integrated relaxation pressure (IRP). Impedance results of liquid and viscous swallows (when applicable) were reviewed, however, there was no specific pattern noticed to any of the motility disorders (achalasia, DES or scleroderma). Each tracing was analyzed twice, first by a special esophageal research fellow and then by the attending gastroenterologist (DOC).

Radiographic examination of the esophagus was performed in the prone oblique position, with evaluation of both motility and structure. Several views of the full length esophagus were obtained. Double contrast films were routinely performed. Radiologically, normal primary peristalsis was defined as a progression of a stripping wave that traverses the entire esophagus and cleared barium from the latter. Barium esophagram images were initially interpreted by both a radiology resident and a supervising attending. Later, on retrospective evaluation; all of these radiology images were evaluated by a single radiology attending (S.S) blinded from both esophageal impedance-manometry results and initial barium esophagram reports.

## RESULTS

68 of 1971 (3.4%) patients were diagnosed with MMA. 29 of them had MMA with achalasia as a possible diagnosis and had their BE done in our institution. BE interpretation by the blinded attending radiologist excluded achalasia in 25 (86%) of these patients. Results of manometry and BE evaluation are shown in (Table 1). 14/29 had features of achalasia and ineffective esophageal manometry (IEM); BE was felt to rule out achalasia in all of them (100%). 11/29 had features of achalasia and distal esophageal spasm (DES); BE showed no achalasia in 8/11 (72%). 4/29 had features of achalasia and scleroderma; BE excluded achalasia in 3/4 (75%) (Figure 1). The results of BE were interpreted as being very helpful to establish the final diagnosis. In one case the HRM showed 100% failed peristalsis (DCI < 100 mmHg.s.cm), and normal IRP; criteria that represent “absent contractility” also known as “scleroderma like esophagus”, barium esophagram showed typical radiologic findings of achalasia; narrow “beakbird”, (< 12.5 mm EGJ) esophageal dilation and fluid level.

Results of the impedance bolus transit studies are shown in table 2. Patients who had features of achalasia and IEM had incomplete bolus transit with liquid. Only 1 had normal viscous swallows (viscous swallow was done in 8/14). 2/11 patients who had features of achalasia and DES showed normal liquid bolus transit, and one of them also had normal viscous bolus transit. None of the patients who had features of achalasia and scleroderma showed normal liquid or viscous swallow.

Patients (n)	Manometry results	Barium esophagram results
14	Achalasia and IEM	All negative for achalasia
11	Achalasia and DES	8/11 negative for achalasia
4	Achalasia and Secleroderma	3/4 negative for achalasia

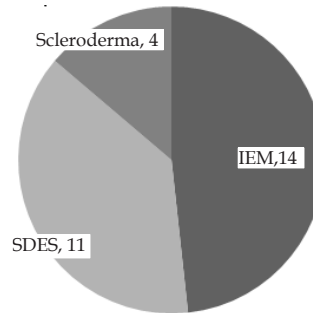


Figure 1 Distribution of motility abnormalities.

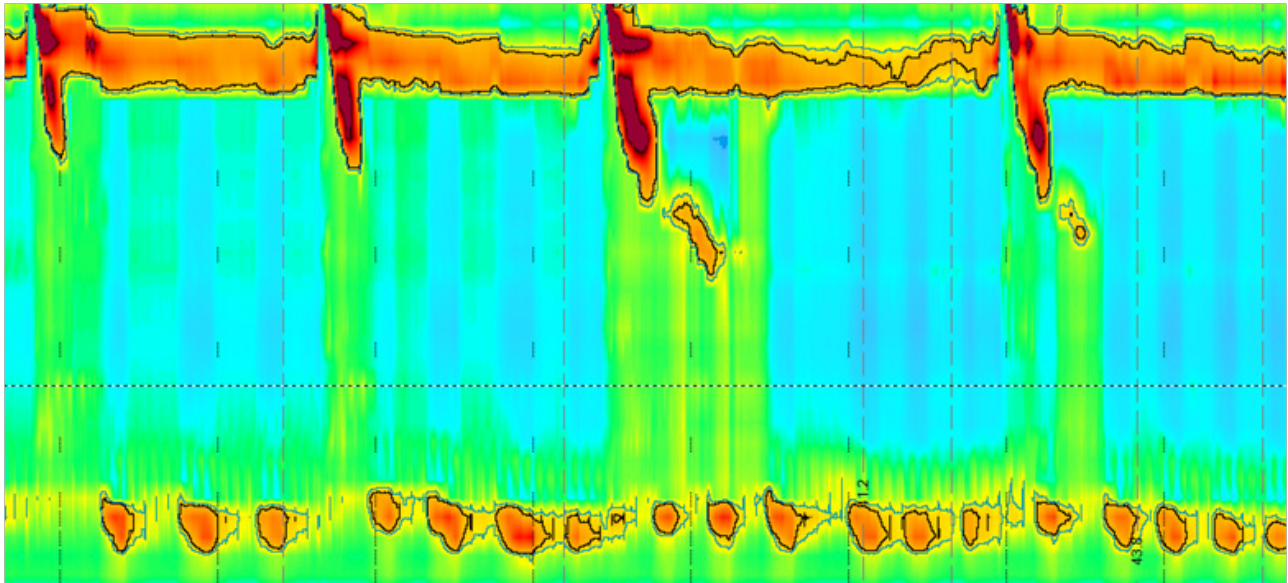
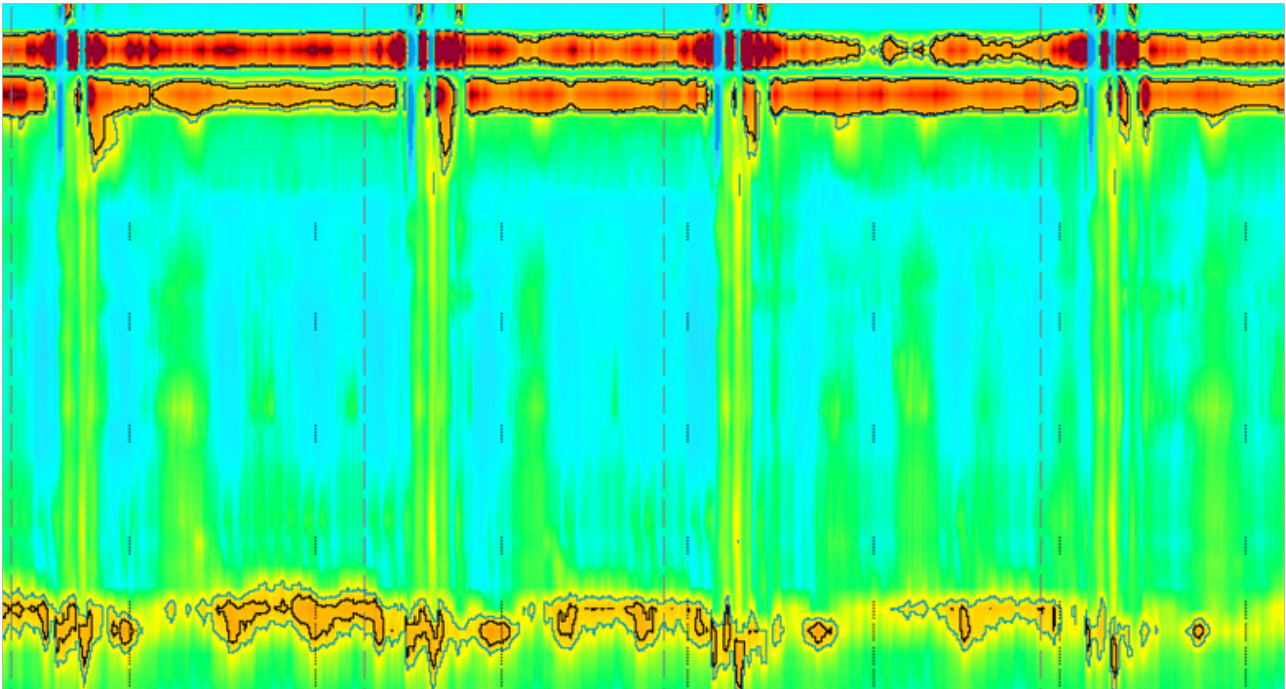


Figure 2 A: MMA with features of Achalasia and IEM. HRM showed 90% failed peristalsis (DCI < 100), 10% weak (DCI < 450) normal IRP (< 15). Some pressurization also can be noticed.

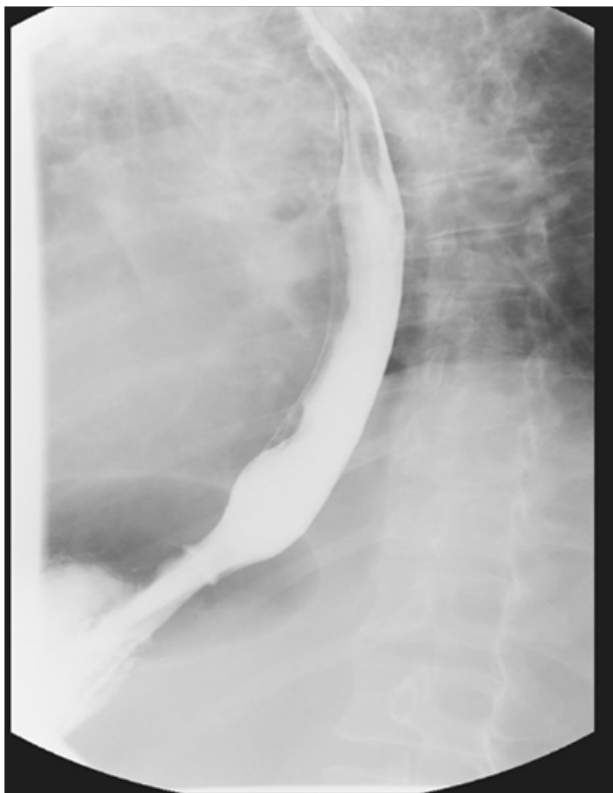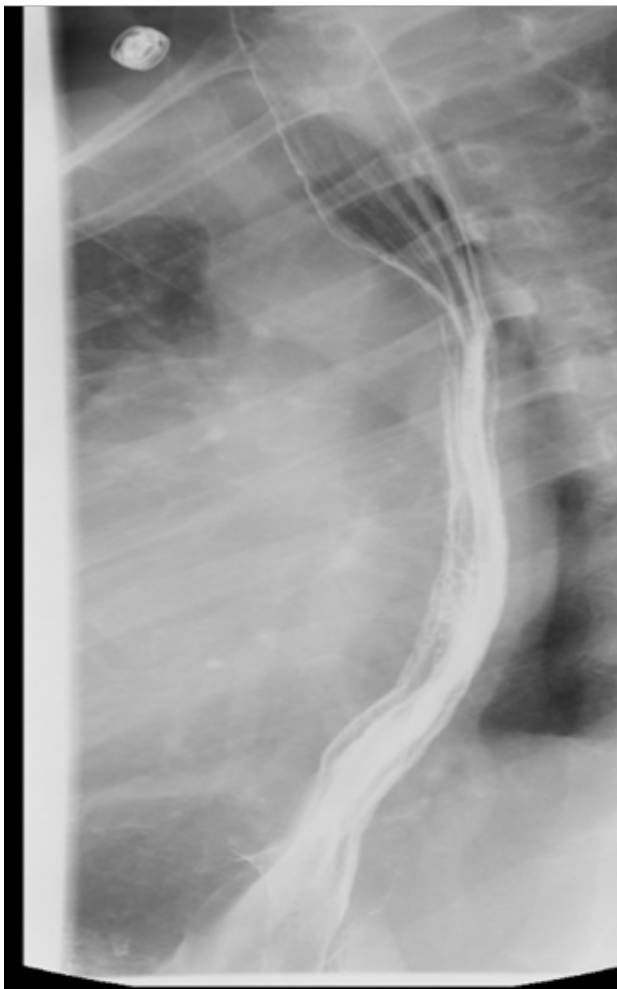


Figure 2 B: Barium esophagram shows no features of achalasia.

MMA	Barium esophagram	Normal liquid swallow transit	Normal viscous swallow transit
Achalasia and IEM	No achalasia	0 of 10	Not done
Achalasia and IEM	No achalasia	3 of 10	9 of 10
Achalasia and IEM	No achalasia	4 of 10	1 of 10
Achalasia and IEM	No achalasia	0 of 10	Not done
Achalasia and IEM	No achalasia	0 of 10	Not done
Achalasia and IEM	No achalasia	1 of 10	Not done
Achalasia and IEM	No achalasia	0 of 10	0 of 10
Achalasia and IEM	No achalasia	0 of 10	0 of 10
Achalasia and IEM	No achalasia	1 of 10	1 of 10
Achalasia and IEM	No achalasia	0 of 10	0 of 10
Achalasia and IEM	No achalasia	1 of 10	Not done
Achalasia and IEM	No achalasia	0 of 10	Not done
Achalasia and IEM	No achalasia	1 of 10	0 of 10
Achalasia and IEM	No achalasia	2 of 10	1 of 10
Achalasia and DES	Achalasia	2 of 10	5 of 10
Achalasia and DES	No achalasia	8 of 10	3 of 10
Achalasia and DES	No achalasia	4 of 10	Not done
Achalasia and DES	No achalasia	8 of 10	9 of 10
Achalasia and DES	No achalasia	5 of 10	3 of 10
Achalasia and DES	No achalasia	3 of 10	1 of 10
Achalasia and DES	No achalasia	4 of 10	9 of 10
Achalasia and DES	No achalasia	1 of 10	1 of 10
Achalasia and DES	Achalasia	0 of 10	0 of 10
Achalasia and DES	Achalasia	1 of 10	1 of 10
Achalasia and DES	No achalasia	2 of 10	1 of 10
Achalasia and SS	Achalasia	0 of 10	Not done
Achalasia and SS	No achalasia	0 of 10	0 of 10
Achalasia and SS	No achalasia	1 of 10	1 of 10
Achalasia and SS	No achalasia	0 of 10	0 of 10



**Figure 3 A:** MMA with features of achalasia and scleroderma. HRM showed 100% failed peristalsis (DCI < 100) and normal IRB (< 15). Some pressurization and low LES pressure can also be noticed.



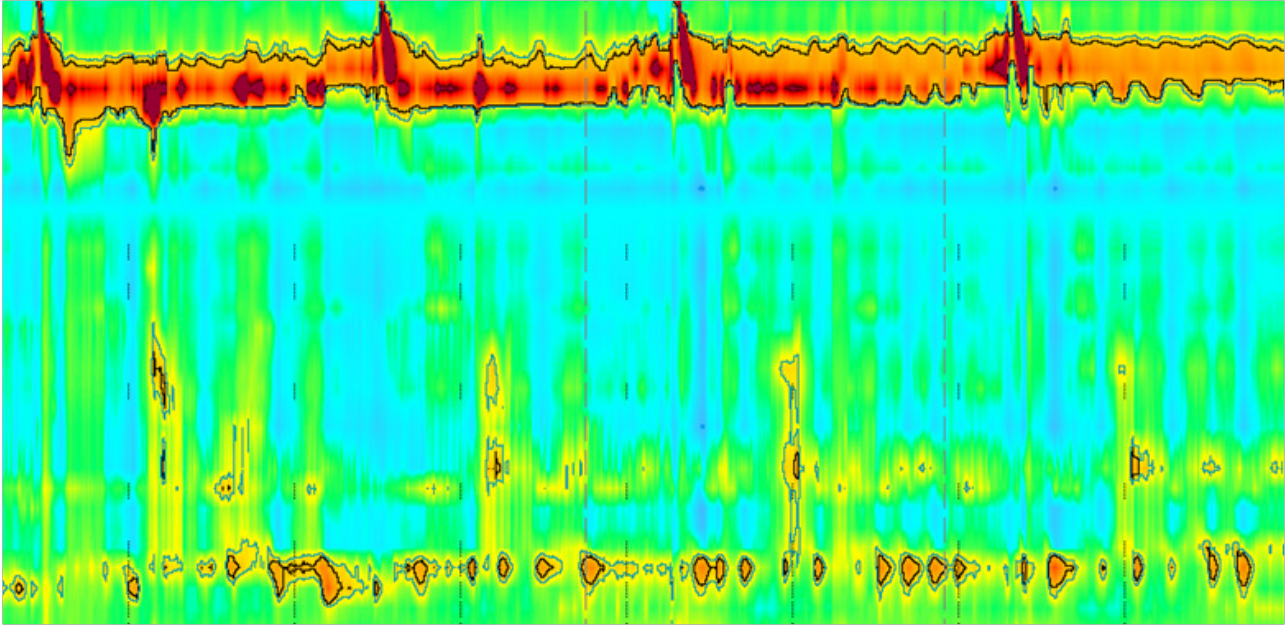
**Figure 3 B:** Barium esophagram shows no evidence of achalasia.

## DISCUSSION

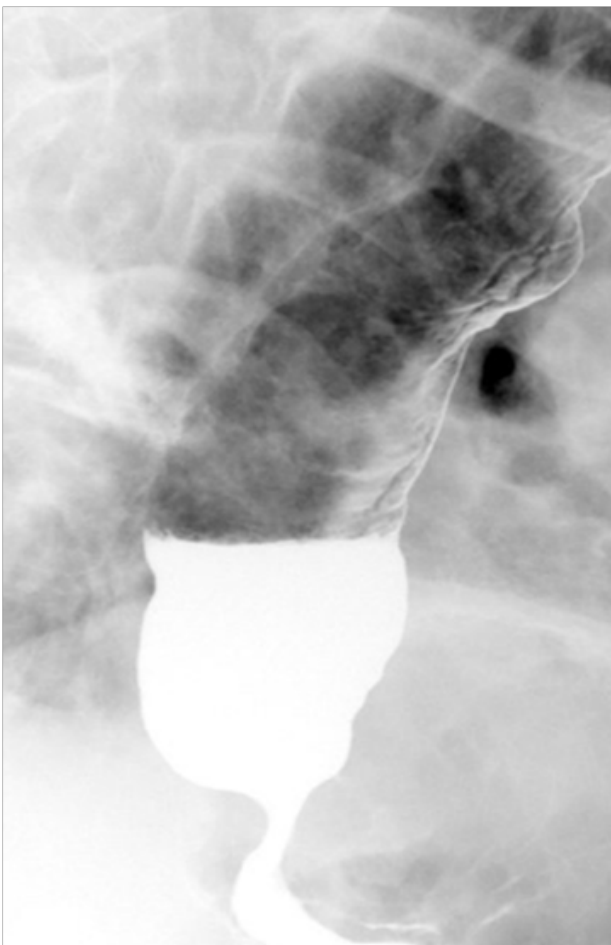
Achalasia is a rare motility disorder of the esophagus that affects about 1 in 100,000 people<sup>[10]</sup>. It is characterized by absence of peristalsis and abnormal lower esophageal sphincter relaxation. Although dysphagia to both liquids and solids is the most common presenting symptom of achalasia, some patients may initially present with heartburn, chest pain or regurgitation. After ruling out the more common causes of dysphagia, usually by endoscopy to determine if there is underlying structural etiology, esophageal manometry becomes the test of choice to identify motility abnormalities.

The manometric findings of normal IRP and 100% failed peristalsis can have two possible explanations. Achalasia should be considered when there is normal median IRP and 100% failed peristalsis. IEM is characterized by normal IRP and  $\geq 50\%$  ineffective swallows which can be weak (DCI < 450) or failed (DCI < 100)<sup>[11]</sup>, hypothetically,  $\geq 50\%$  can be 100%. The international HRM working group recommended further investigation to explain the manometric finding of esophagogastric (EGJ) outflow obstruction which is characterized by elevated median IRP with some instances of intact or weak peristalsis<sup>[11]</sup>. The EGJ outflow obstruction might represent early or not fully expressed achalasia.

Manometric studies that show 100% failed peristalsis, but normal IRP and some evidence of pressurization are considered atypical manometric findings for achalasia. In these situations, achalasia cannot be 100% ruled out and other esophageal motility disorders like IEM should be considered. On HRM, IEM is characterized by normal IRP and  $\geq 50\%$  ineffective swallows<sup>[11]</sup>, all these ineffective swallows can be failed (DCI < 100 mmHg.s.cm) and/or weak (DCI < 450 mmHg.s.cm) (Figure 2, A, B). Scleroderma should also be considered when there is normal IRP, and ineffective swallows and sometimes low LES resting pressure (Figures 3, 4, A,



**Figure 4 A:** MMA with features of achalasia and scleroderma. HRM showed 100% failed peristalsis (DCI < 100) and normal IRP (< 15). Low LES pressure can also be noticed.



**Figure 4 B:** Barium esophagram shows achalasia.

B). Another example is achalasia and distal esophageal spasm (DES). DES is characterized by normal IRP,  $\geq 20\%$  premature swallows with DCI > 450 mmHg.s.cm and some normal peristalsis “may be” present on HRM<sup>[11]</sup>. Therefore, based on manometric findings of no peristalsis and  $\geq 20\%$  premature swallows, type III achalasia is still a possible diagnosis, although IRP is normal (Figure 5 A, B).

We use the term MMA to describe these uncommon manometric findings that are difficult to comfortably fit within one manometric diagnosis. Therefore another diagnostic test is warranted to reach the diagnosis. Barium esophagram is a well-known and established test in the evaluation of achalasia. Barium esophagram and esophageal manometry are complimentary procedures that are readily available diagnostic modalities used in order to both establish the diagnosis and follow up of achalasia<sup>[12]</sup>.

We first reported our use of the term “MMA” in 2013<sup>[13]</sup>. Major Motility Abnormality (MMA) is an esophageal manometric diagnosis that has evolved in our laboratory over the past 10 years. It is reserved for patients whose motility study is clearly abnormal, but difficult to simply categorize into one of the “named” motility abnormalities. It is also intended to inform the referring physician that the study is definitely abnormal. The final diagnosis on the report will read as “Major Motility Abnormality with features of “--- and ----“which include any combination of the following: achalasia, scleroderma, IEM or DES. Several combinations of manometric diagnosis patterns were described. We subsequently developed interest in MMA findings where achalasia is one of the subtypes.

The purpose of this paper is neither to show the superiority of barium esophagram over HRM nor to criticize HRM. The purpose of this research is to study and help find a diagnostic approach to those “difficult to interpret” HRM findings using barium esophagram.

In summary, BE remains a viable and reasonable diagnostic

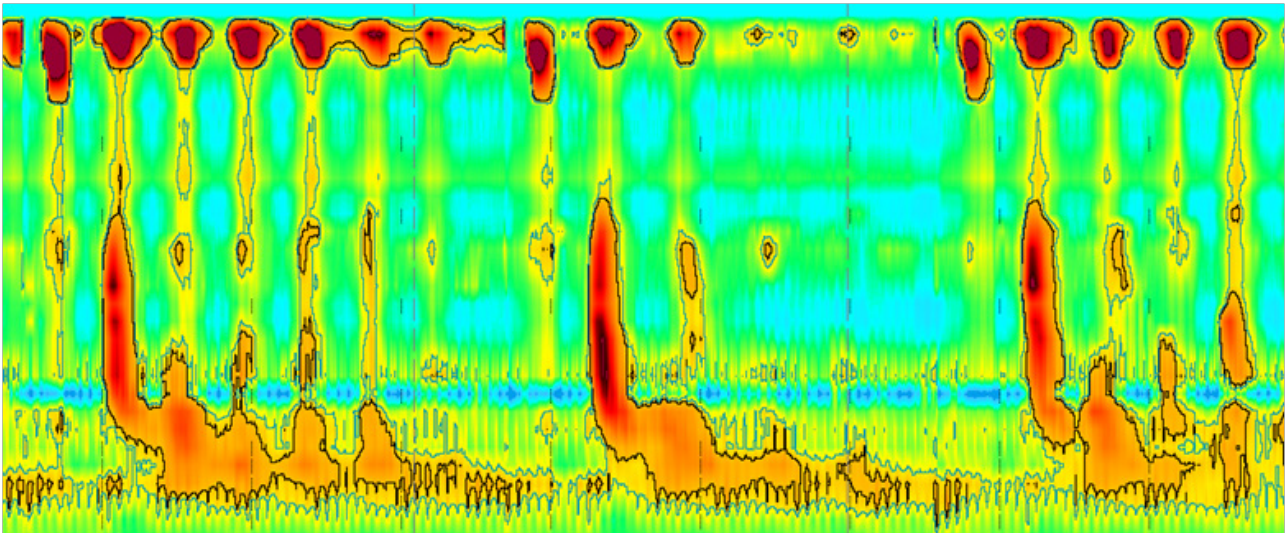


Figure 5 A. MMA with features of achalasia and DES. Elevated IRP, > 20% premature contractions and 10-20% possible peristaltic activity.

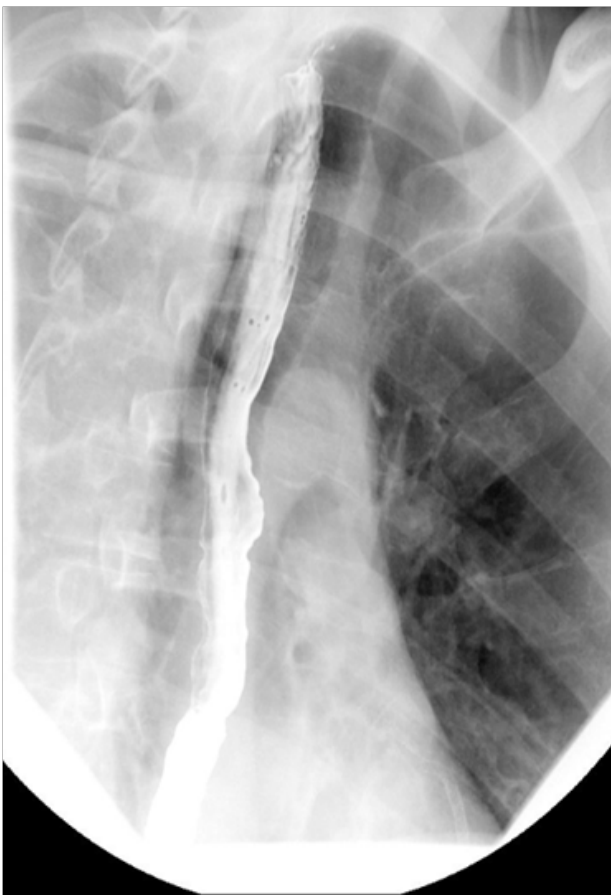

Figure 5 B: Barium esophagram shows no evidence of achalasia.

test to establish or rule out the diagnosis of achalasia when the manometric findings are inconclusive.

## CONFLICT OF INTERESTS

There are no conflicts of interest with regard to the present study.

## REFERENCES

- Ott DJ, Wu WC, Gelfand DW. Efficacy of radiology of the esophagus for evaluation of dysphagia. *Gastrointest Radiol.* 1981; **6**: 109-10.
- Ott DJ, Richter JE, Chen YM, Wu WC, Gelfand DW, Castell DO. Radiographic and manometric correlation in achalasia with apparent relaxation of the lower esophageal sphincter. *Gastrointest Radiol.* 1989; **14**: 1-5.
- Hewson EG, Ott DJ, Dalton CB, Chen YM, Wu WC, Richter JE. Manometry and radiology. Complementary studies in the assessment of esophageal motility disorders. *Gastroenterology.* 1990; **98**: 626-32.
- Zanoni A, Rice TW, Lopez R, Birgisson S, Shay SS, Thota PN, Baker ME, Raymond DP, Blackstone EH. Timed barium esophagram in achalasia types. *Dis Esophagus.* 2015; **28**: 336-44.
- Cho YK, Choi MG, Oh SN, Baik CN, Park JM, Lee IS, Kim SW, Choi KY, Chung IS. Comparison of bolus transit patterns identified by esophageal impedance to barium esophagram in patients with dysphagia. *Dis Esophagus.* 2012; **25**: 17-25.
- Massey BT, Dodds WJ, Hogan WJ, Brasseur JG, Helm JF. Abnormal esophageal motility. An analysis of concurrent radiographic and manometric findings. *Gastroenterology* 1991; **101**: 344-54.
- Fuller L, Huprich JE, Theisen J, Hagen JA, Crookes PF, Demeester SR, Bremner CG, Demeester TR, Peters JH. Abnormal esophageal body function: Radiographic-manometric correlation. *Am Surg.* 1999; **65**: 911-4.
- Ala A, Abdel Jalil, Mustafa Abdul-Hussein, Donald O. Castell. Even Experts Have Problems with Esophageal Manometry Diagnosis. *Digestive Disease Week (DDW)* 2015. Tu1179
- Richard M. Gore, Marc S. Levine. Textbook of Gastrointestinal Radiology: Expert Consult.
- Mayberry JF. Epidemiology and demographics of achalasia. *Gastrointest Endosc Clin N Am* 2001; **11**: 235-248.
- Kahrilas PJ, Bredenoord AJ, Fox M, Gyawali CP, Roman S, Smout AJ, Pandolfino JE; International High Resolution Manometry Working Group. The Chicago Classification of esophageal motility disorders, v3.0. *Neurogastroenterol Motil.* 2015; **27**: 160-74.
- Pohl D, Tutuian R. Achalasia: an overview of diagnosis and treatment. *J Gastrointestin Liver Dis.* 2007; **16**: 297-303.
- Obinna C. Ukabam, Erik B. Person, Janice Freeman, Donald O. Castell. Characterization and stratification of the esophageal diagnosis "major motility abnormality". P1220. ACG 2013.