

## Biochemical and Histological Effectiveness of Long-term Use of Fenofibrate for Asymptomatic Primary Biliary Cholangitis

Kazufumi Dohmen, Hirofumi Tanaka, Masatora Haruno, Shinichi Aishima

Kazufumi Dohmen, Hirofumi Tanaka, Masatora Haruno, Internal Medicine, Chihaya Hospital, Fukuoka, Japan  
Shinichi Aishima, Pathology & Microbiology, Saga University, Saga, Japan

Correspondence to: Kazufumi Dohmen, Internal Medicine, Chihaya Hospital 2-30-1 Chihaya Higashi-ku Fukuoka 813-8501 Japan.

Email: [dohmen-kzfm@cool.odn.ne.jp](mailto:dohmen-kzfm@cool.odn.ne.jp)

Telephone: +81-92-661-2211

Fax: +81-92-683-0411

Received: May 3, 2016

Revised: July 1, 2016

Accepted: July 3, 2016

Published online: August 21, 2016

### ABSTRACT

**AIM:** Ursodeoxycholic acid (UDCA) is currently the standard treatment for asymptomatic primary biliary cholangitis (aPBC). Potential favourable effects of fibrates have been demonstrated in aPBC patients exhibiting an incomplete response to UDCA. The mechanism of action of fibrates involves regulation of the expression of various lipids and proteins via the activation of peroxisome proliferator-activated receptor- $\alpha$  (PPAR- $\alpha$ ). Among different fibrates, the binding activity of fenofibrate to PPAR- $\alpha$  is stronger than that of bezafibrate. However, whether fenofibrate is histologically effective for treating aPBC remains to be elucidated. The aim of this study was to evaluate the biochemical and histological effects of the long-term use of fenofibrate in patients with aPBC refractory to UDCA.

**METHODS:** Of 17 aPBC patients treated with fenofibrate plus UDCA, 13 patients treated for more than 36 months were involved in this study. Various characteristics of these 13 patients were compared between the time of initiation of fenofibrate treatment and 36 months after the administration of fenofibrate. Liver biopsy examinations were performed in five patients at the initial administration of fenofibrate and at approximately two and a half years (22–39 months) after the initiation of fenofibrate therapy. The histological stage was determined based on Scheuer's classification and Nakanuma's classification.

**RESULTS:** Among the patients treated with UDCA and fenofibrate, the serum alkaline phosphatase (ALP),  $\gamma$ -glutamyl transpeptidase ( $\gamma$ GTP) and serum IgM levels decreased from  $524.6 \pm 190.8$  to  $218.7 \pm 74.8$  IU/L,  $192.7 \pm 87.1$  to  $29.5 \pm 7.5$  IU/L and  $391.5 \pm 244.0$  to  $166.3 \pm 115.3$  mg/dL ( $p < 0.0001$ ), respectively. With regard to the histological findings of the liver, three cases of Scheuer's stage 1 disease improved to portal inflammation, while two cases of Scheuer's stage 1 or Scheuer's stage 2 remained stable. Similarly, three cases of Nakanuma stage 2 improved to Nakanuma stage 1 and one case of Nakanuma stage 3 improved to stage 2. Although one case of Nakanuma stage 2 remained unchanged, the grading in that case improved from a hepatitis activity (HA) of 1 to HA0.

**CONCLUSION:** Combination therapy with fenofibrate plus UDCA results in significant biochemical and histological improvements in patients with aPBC.

**Limitation:** Short follow-up; Small number of samples; Retrospective; Single-center study

**Key words:** Fenofibrate; Fibrate; Primary Biliary Cholangitis; Histology; Primary Biliary Cirrhosis

© 2016 The Authors. Published by ACT Publishing Group Ltd.

Dohmen K, Tanaka H, Haruno M, Aishima S. Biochemical and Histological Effectiveness of Long-term Use of Fenofibrate for Asymptomatic Primary Biliary Cholangitis. *Journal of Gastroenterology and Hepatology Research* 2016; 5(4): 2125-2131 Available from: URL: <http://www.ghrnet.org/index.php/joghr/article/view/1706>

### INTRODUCTION

Primary biliary cholangitis (PBC) is a chronic autoimmune liver disease characterized by progressive inflammatory destruction of the interlobular bile duct that eventually leads to cholestasis, fibrosis, cirrhosis and subsequent hepatic failure<sup>[1]</sup>. Although there is no established etiology for this disease, the onset of PBC has been attributed to autoimmunity, primarily due to its association with autoantibodies,

especially anti-mitochondrial antibodies (AMA) and elevated levels of immunoglobulin M (IgM).

The only approved therapeutic agent for PBC is ursodeoxycholic acid (UDCA), which has been demonstrated to delay the development of fibrosis. UDCA-responsive patients have a similar life expectancy as age- and sex-matched controls<sup>[2-5]</sup>, however, not all patients achieve a complete biochemical response to UDCA and 10~20% progress to cirrhosis or require liver transplantation, indicating a clear need for additional therapies<sup>[6,7]</sup>.

Fibrate is a fibric acid derivative used in the treatment of hypercholesterolemia and hyperglyceridemia that has been incidentally noted to cause decreases in the levels of serum liver biochemical markers. The proposed mechanism of action of fibric acid derivatives involves the regulation of cell proliferation and the expression levels of various lipids and proteins via the activation of peroxisome proliferator-activated receptor (PPAR)- $\alpha$ <sup>[8-10]</sup>. Therefore, fibric acid is referred to as a "PPAR- $\alpha$ agonist". Bezafibrate activates all three isoforms of human PPAR (PPAR- $\alpha$ , PPAR- $\delta$ , and PPAR- $\gamma$ ) at similar concentrations (i.e., 50, 20 and 60  $\mu$ M, respectively)<sup>[11,12]</sup>. Therefore, the term "pan-PPAR" agonist is a more accurate description of bezafibrate. On the other hand, fenofibrate has been confirmed to exhibit a stronger binding activity for PPAR- $\alpha$  than bezafibrate<sup>[12]</sup>. Hence, fenofibrate is referred to as a "PPAR- $\alpha$ -selective" agonist<sup>[11]</sup>.

There are scarce data regarding the biochemical effects of fenofibrate in patients with aPBC<sup>[11,13-19]</sup>. Moreover, there are currently no findings on the long-term biochemical effects of fenofibrate for aPBC. As for histological studies of PBC patients treated with UDCA or UDCA plus fibrate, Angulo *et al* reported that long-term UDCA therapy for six and a half years in 16 PBC patients resulted in eight cases of "no change/improvement" histologically and eight cases of "worse" findings, although the difference was not significant between the UDCA group and the control group (50% vs 71%)<sup>[20]</sup>. In addition, Yano *et al* reported that clear histological improvements were not observed in their study despite a dramatic biochemical response in patients treated with bezafibrate plus UDCA for PBC<sup>[21]</sup>. Therefore, we confirmed the biochemical and histological effectiveness of fenofibrate plus UDCA in aPBC patients.

## PATIENTS AND METHODS

### Patients

From 2008 to 2013, we consecutively recruited 17 patients with aPBC treated with fenofibrate plus UDCA. Of the 17 patients with aPBC, 13 aPBC patients treated for more than 36 months were involved in this study. The patients included in this study were diagnosed based on the following eligibility criteria; (1) an established diagnosis of PBC made according to published criteria<sup>[22]</sup>, including liver biochemical findings of cholestasis associated with PBC (elevated alkaline phosphatase and/or  $\gamma$ -glutamyl transferase), compatible serological parameters (antimitochondrial antibodies) at a titer of > 1:40 and/or a compatible or diagnostic liver histology; (2) treatment with 13-15 mg/kg/day of UDCA for at least six months and (3) persistent elevation of the serum ALP level greater than two-fold the upper limit of normal on two separate measurements. Thirteen female patients with aPBC who showed incomplete responses to UDCA for at least six months were evaluated. Thirteen patients (52.2  $\pm$  10.9 years-old) were given 80 mg/day of fenofibrate in addition to their usual dose of UDCA. The dose of 80 mg/day of fenofibrate was chosen based on the findings of our previous paper, in which treatment with fenofibrate showed effectiveness for decreasing the ALP and IgM levels at that dose<sup>[14,19]</sup>. All patients were negative for serum hepatitis B surface antigens and hepatitis C virus antibodies. Indi-

viduals with known cerebrovascular disease, diabetes mellitus, cancer, renal disease or thyroid disease were excluded. No patients had received treatment with D-penicillamine, corticosteroids, colchicine or immunosuppressive agents within four weeks. Liver biopsies were not required according to the inclusion criteria.

### Methods

The subjects underwent history-taking and physical examinations at the time of administration of fenofibrate. Laboratory tests for liver biochemical parameters, the lipids, uric acid, serum creatinine and serum IgM levels and complete blood cell count were performed at the initiation of fenofibrate therapy and months 1, 6, 12, 24 and 36. Various characteristics of the 13 overall patients treated with fenofibrate were analyzed. The findings of liver biopsies performed at the initiation of fenofibrate and approximately two and a half years (22-39 months) after fenofibrate administration were compared in the five patients with aPBC. Histological evaluations of aPBC were made using Scheuer's classification<sup>[23]</sup> (stage 1: a damaged bile ducts surrounded by chronic inflammatory cells or florid ductal lesion, stage 2: abnormal proliferating bile ductules without a duct lumen, the disappearance of normal bile ducts, and extension of portal inflammation into the hepatic parenchyma, stage 3: substantially increased fibrosis and fibrous septa formation and stage 4: cirrhosis with regenerative nodules) in combination with Nakanuma's classification<sup>[24,25]</sup> (stage 1 (no progression): score 0 fibrosis and bile duct loss, stage 2 (mild progression): score 1-2 fibrosis and bile duct loss, stage 3 (moderate progression): score 3-4 fibrosis and bile duct loss, and stage 4 (advanced progression): score 5-6 fibrosis and bile duct loss; cholangitis activity (CA), 0: no activity, 1: mild activity, 2: moderate activity and 3: marked activity; and hepatitis activity (HA), 0: no activity, 1: mild activity, 2: moderate activity and 3: marked activity). The assessment of the effects of adding fibrate to UDCA was performed in accordance with the ethical guidelines of the Declaration of Helsinki and the study protocol approved by the Chihaya Hospital Ethics Committee.

### Statistical analysis

All values are expressed as the mean  $\pm$  standard deviation (SD). The analyses were conducted using the Dunnett's test and the  $\chi^2$ -test, as appropriate. A *p* value of < 0.05 was considered to be statistically significant.

## RESULTS

### Changes in the biochemical characteristics after treatment with fenofibrate in addition to UDCA (Table 1)

The biochemical characteristics obtained at the initiation of fenofibrate treatment and after 36 months of treatment are summarized in Table 1. Combination therapy with fenofibrate and UDCA resulted in significant decreases in the serum alanine

**Table 1** Biochemical Characteristics.

	Baseline	36 months	<i>p</i>
Total Bil (mg/dL)	0.6 $\pm$ 0.2	0.5 $\pm$ 0.2	0.0281
ALT (IU/L)	68.9 $\pm$ 59.9	21.6 $\pm$ 7.7	0.0001
ALP (IU/L)	524.6 $\pm$ 190.8	218.7 $\pm$ 74.8	< 0.0001
$\gamma$ GTP(IU/L)	192.7 $\pm$ 87.1	29.5 $\pm$ 7.5	< 0.0001
Alb (mg/dL)	3.9 $\pm$ 0.4	4.2 $\pm$ 0.3	0.0519
Total Chol (mg/dL)	195.3 $\pm$ 43.9	187.6 $\pm$ 24.5	0.754
HDL (mg/dL)	67.4 $\pm$ 14.4	81.7 $\pm$ 13.6	0.0031
LDL (mg/dL)	113.1 $\pm$ 36.6	97.4 $\pm$ 27.4	0.0132
TG (mg/dL)	115.2 $\pm$ 74.3	72.4 $\pm$ 35.2	0.0168
Uric acid (mg/dL)	4.6 $\pm$ 1.3	3.8 $\pm$ 1.0	0.0098
IgM (mg/dL)	391.5 $\pm$ 244.0	166.3 $\pm$ 115.3	< 0.0001
mito.M2ab	86.8 $\pm$ 57.8	110.9 $\pm$ 102.2	0.2735

aminotransferase (ALT), serum alkaline phosphatase (ALP),  $\gamma$ -glutamyl transpeptidase ( $\gamma$ -GTP) and immunoglobulin M (IgM) levels as early as one month of treatment. The serum ALT, ALP,  $\gamma$ -GTP and IgM levels decreased from baseline to 36 months, from  $68.9 \pm 59.9$  to  $21.6 \pm 7.7$  IU/L,  $524.6 \pm 190.8$  to  $218.7 \pm 74.8$  IU/L,  $192.7 \pm 87.1$  to  $29.5 \pm 7.5$  IU/L and  $391.5 \pm 244.0$  to  $166.3 \pm 115.3$  mg/dL ( $p < 0.0001$ ), respectively (Figures 1 and 2). In contrast, the anti-mitochondrial M2 antibody titers did not change (from  $86.8 \pm 57.8$  to  $110.9 \pm 102.2$  U) ( $p = 0.2735$ ).

The levels of serum low-density lipoprotein (LDL), triglycerides (TGs) and uric acid decreased significantly from  $113.1 \pm 36.6$  to  $97.4 \pm 27.4$  mg/L ( $p = 0.0132$ ),  $115.2 \pm 74.3$  to  $72.4 \pm 35.2$  mg/dL ( $p = 0.0168$ ) and  $4.6 \pm 1.3$  to  $3.8 \pm 1.0$  mg/dL ( $p = 0.0098$ ), respectively. Conversely, the levels of serum high-density lipoprotein (HDL) increased significantly from  $67.4 \pm 14.4$  to  $81.7 \pm 13.6$  mg/L ( $p = 0.0031$ ).

No adverse events such as transient elevation of the transaminase levels<sup>[26,27]</sup>, renal dysfunction, rhabdomyolysis or esophagitis, known adverse side effects of these drugs, were observed.

**Changes in the histological characteristics after treatment with fenofibrate in addition to UDCA (Table 2)**

Of 13 patients, liver histological studies were performed in five patients.

Case 1 (Figure 3): A 39-year-old female with an elevated serum level of ALP was admitted to our hospital for a further examination. The levels of ALP and IgM were 335 IU/mL and 200 mg/dL, respectively, at the initiation of fenofibrate in addition to UDCA. A diagnosis of aPBC of Scheuer's stage 1, Nakanuma activity CA3, HA2, stage 2 (score 2: fibrosis 0, duct loss 2) was made based on the histological examination. Thirty months later, the serum levels of ALP and IgM decreased to the normal range, at 134 IU/mL and 130 mg/dL, respectively. A second liver biopsy performed at the thirty months showed improved portal inflammation and a Nakanuma activity of CA1, HA0, stage 1 (score 0: fibrosis 0, duct loss 0).

Case 2 (Figure 4): A 56-year-old female with an elevated serum level of ALP was admitted to our hospital for a further examination. The levels of ALP and IgM were 495 IU/mL and 395 mg/dL, respectively, at the initiation of fenofibrate in addition to UDCA. A diagnosis of aPBC of Scheuer's stage 1, Nakanuma activity CA3, HA1, stage 2 (score 1: fibrosis 1, duct loss 0) was made based on the histological examination. Twenty-eight months later, the serum levels of ALP and IgM decreased to the normal range, at 338 IU/mL and 93

mg/dL, respectively. A second liver biopsy performed at 28 months demonstrated improved portal inflammation and a Nakanuma activity of CA0, HA0, stage 1 (score 0: fibrosis 0, duct loss 0).

Case 3: A 53-year-old female with an elevated serum level of ALP (381 IU/mL) was admitted to our hospital for a further examination. The levels of ALP and IgM were 495 IU/mL and 625 mg/dL,

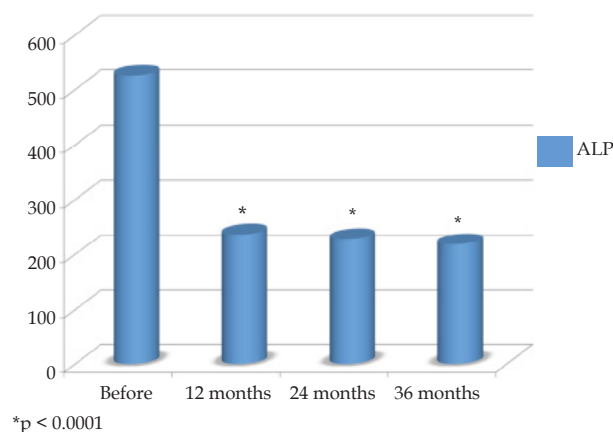


Figure 1 Changes in the levels of ALP after treatment with fenofibrate in addition to UDCA. \* $p < 0.0001$

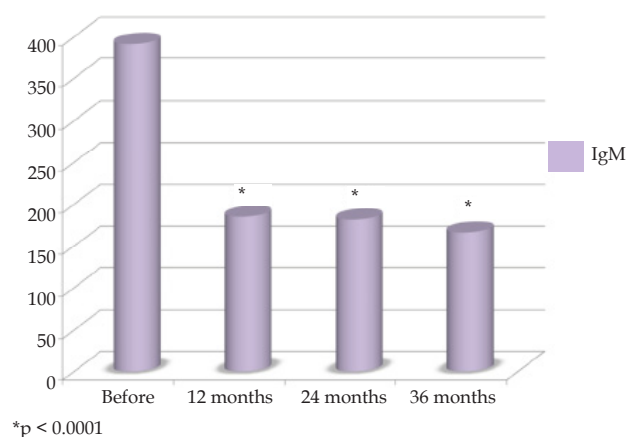
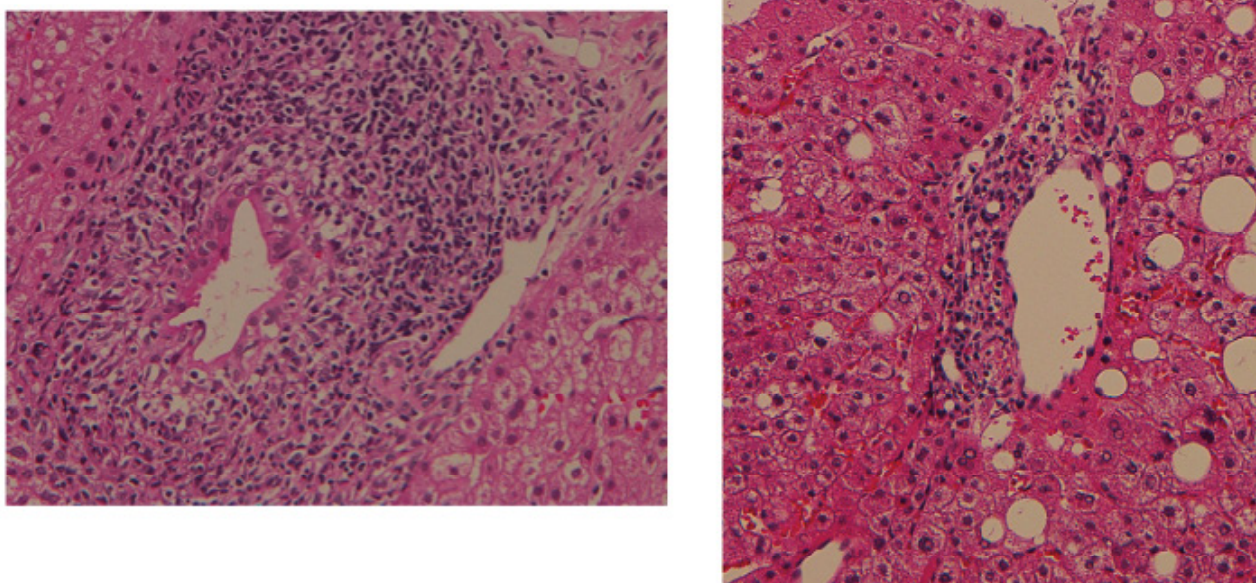


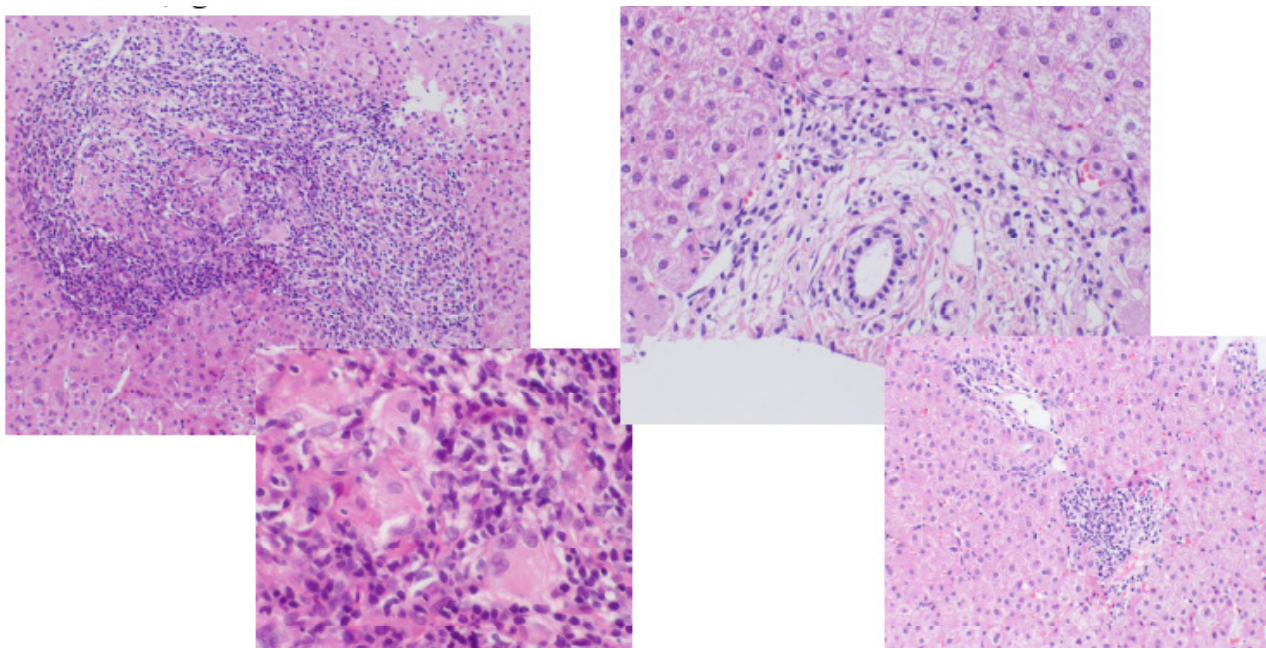
Figure 2 Changes in the levels of IgM after treatment with fenofibrate in addition to UDCA. \* $p < 0.0001$

**Table 2** Histological Characteristics.

No.	Age Sex	Histological stage	Before treatment	After treatment	Intervals (months)
1	39 F	Scheuer's stage	1	portal inflammation	30
		Nakanuma's stage (score: fibrosis, duct loss)	2 (2 : 0, 2)	1 (0 : 0, 0)	
		Activities of Nakanuma's stage	CA 3, HA 2	CA 1, HA 0	
2	56 F	Scheuer's stage	1	portal inflammation	28
		Nakanuma's stage (score: fibrosis, duct loss)	2 (1 : 1, 0)	1 (0 : 0, 0)	
		Activities of Nakanuma's stage	CA 3, HA 1	CA 0, HA 0	
3	53 F	Scheuer's stage	1	portal inflammation	39
		Nakanuma's stage (score: fibrosis, duct loss)	2 (1 : 0, 1)	1 (0 : 0, 0)	
		Activities of Nakanuma's stage	CA 3, HA 1	CA 0, HA 0	
4	60 F	Scheuer's stage	1	1	33
		Nakanuma's stage (score: fibrosis, duct loss)	2 (1 : 0, 1)	2 (2 : 1, 1)	
		Activities of Nakanuma's stage	CA 1, HA 1	CA 1, HA 0	
5	69 F	Scheuer's stage	2	2	22
		Nakanuma's stage (score: fibrosis, duct loss)	3 (4 : 2, 2)	2 (2 : 1, 1)	
		Activities of Nakanuma's stage	CA 3, HA 3	CA 2, HA 2	



**Figure 3** Changes in liver histology after treatment with fenofibrate in addition to UDCA in case 1 (a 39-year-old female). Left: At the initiation of fenofibrate plus UDCA (Scheuer's stage 1, Nakanuma's stage 2 of score 2: fibrosis 0, duct loss 2, activity CA3, HA2). Right: Two years and six months after fenofibrate plus UDCA treatment (portal inflammation and Nakanuma's stage 1 of score 0: fibrosis 0, duct loss 0, activity CA1, HA0).



**Figure 4** Changes in liver histology after treatment with fenofibrate in addition to UDCA in case 2 (a 56-year-old female). Left: At the initiation of fenofibrate plus UDCA (Scheuer's stage 1, Nakanuma's stage 2 of score 1: fibrosis 1, duct loss 0, activity CA3, HA1). Right: Two years and four months after fenofibrate plus UDCA treatment (portal inflammation and Nakanuma's stage 1 of score 0: fibrosis 0, duct loss 0, activity CA0, HA0).

respectively, at the initiation of fenofibrate in addition to UDCA. A diagnosis of aPBC of Scheuer's stage 1, Nakanuma activity CA3, HA1, stage 2 (score 1: fibrosis 0, duct loss 1) was made based on the histological examination. Thirty-nine months later, the serum levels of ALP and IgM decreased to the normal range, at 310 IU/mL and 93 mg/dL, respectively. A second liver biopsy performed at 39 months indicated improved portal inflammation and a Nakanuma activity of CA0, HA0, stage 1 (score 0: fibrosis 0, duct loss 0).

Case 4: A 60-year-old female with an elevated serum level of ALP was admitted to our hospital for a further examination. The levels of ALP and IgM were 594 IU/mL and 291 mg/dL, respectively, at the initiation of fenofibrate in addition to UDCA. A diagnosis of

aPBC of Scheuer's stage 1, Nakanuma activity CA1, HA1, stage 2 (score 1: fibrosis 0, duct loss 1) was made based on the histological examination. Thirty-three months later, the serum levels of ALP and IgM decreased to the normal range, at 211 IU/mL and 94 mg/dL, respectively. A second liver biopsy performed at 33 months showed no change, at Scheuer's stage 1 and Nakanuma stage 2 (score 2: fibrosis 1, duct loss 1), whereas the Nakanuma activity improved from CA1, HA1 to CA1, HA0.

Case 5: A 69-year-old female with an elevated serum level of ALP was admitted to our hospital for a further examination. The levels of ALP and IgM were 336 IU/mL and 998 mg/dL, respectively, at the initiation of fenofibrate in addition to UDCA. A diagnosis of

aPBC of Scheuer's stage 2, Nakanuma activity CA3, HA3, stage 3 (score 4: fibrosis 2, duct loss 2) was made based on the histological examination. Twenty-two months later, the serum level of ALP decreased to the normal range, at 199 IU/mL, and the serum level of IgM decreased to 539 mg/dL. A second liver biopsy performed at 22 months showed no change in the Scheuer's stage (stage 2), whereas the Nakanuma activity changed from CA3, HA3, stage 3 (score 4: fibrosis 2, duct loss 2) to CA2, HA2, stage 2 (score 2, fibrosis 1, duct loss 1).

## DISCUSSION

The present study demonstrated that the administration of combination therapy with UDCA and fenofibrate for 36 months in patients with aPBC who have previously demonstrated incomplete responses to UDCA monotherapy is effective for eliciting biochemical and histological responses.

Since aPBC patients exhibiting an incomplete biochemical response to UDCA in the first three months generally have a poor outcome, a new therapeutic approach is needed for these patients<sup>[28]</sup>. According to several studies in Japan, bezafibrate successfully lowers the levels of biliary liver enzymes in patients with PBC<sup>[29-32]</sup>. In the earliest study, Nakai *et al* randomized 23 patients to receive either UDCA at a dose of 600 mg/day or UDCA at a dose of 600 mg/day plus bezafibrate at a dose of 400 mg/day for one year<sup>[29]</sup>. The combination therapy with UDCA and bezafibrate resulted in greater reductions in the levels of serum liver biochemical markers and IgM without inducing significant side effects. Similar results were obtained in a number of subsequent studies conducted in Japan<sup>[30-32]</sup>. For example, Hazzan *et al* and Lens *et al* demonstrated that the addition of bezafibrate to UDCA significantly and safely improves the biochemical profiles of European patients with PBC<sup>[33,34]</sup>.

The proposed mechanism of action of fibric acid derivatives in the setting of PBC involves the regulation of cell proliferation and the expression of various lipids and proteins via the activation of PPAR- $\alpha$ <sup>[8,10]</sup>. Through PPAR- $\alpha$  activation, fibrates inhibit NF- $\kappa$ B activation, resulting in decreased expression levels of IL-1 and IL-6, thereby potentially reducing the inflammatory and immune responses<sup>[9,10]</sup>. In addition to regulating proteins and lipids, the benefits of fibrates in cases of PBC may result from cross-talk between PPAR- $\alpha$  and the bile acid-activated nuclear receptor farnesoid-X-receptor (FXR)<sup>[35]</sup>. Pineda-Torra *et al* demonstrated that bile acid-activated FXR enhances PPAR- $\alpha$  transcription in human hepatic stellate cells<sup>[35]</sup>. Furthermore, fibrates may facilitate the expression of multidrug resistance gene 3 (MDR), a transport element of the ATP-dependent bile secretion system found in biliary membranes<sup>[10,36-38]</sup>. An increased expression of MDR-3-encoded proteins would lead to the enhanced secretion of biliary phospholipids and improved inactivation of hydrophobic bile acids via micellization, thus protecting hepatocytes and the biliary epithelium. In the current study, the use of combination therapy with a fibrate and UDCA in patients with aPBC confirmed the findings of previous studies showing significant reduction in the serum levels of ALP,  $\gamma$ GTP and IgM.

The activity of fenofibrate for PPAR- $\alpha$  is stronger and more specific than that for bezafibrate<sup>[11,12,19]</sup>. However, there have been only a few studies investigating the effects of fenofibrate in PBC patients<sup>[11,13-19]</sup>. In one study, treatment with fenofibrate in addition to UDCA for six months resulted in reductions in the levels of liver biochemical parameters such as ALT,  $\gamma$ GTP and IgM in seven patients with PBC<sup>[13]</sup>. In another study, the serum levels of

ALP and IgM were significantly reduced following fenofibrate therapy, and the titers of AMA decreased in four of nine patients with aPBC<sup>[14]</sup>. Walker *et al* reported the first European experience with administering a fibric acid derivative in PBC patients<sup>[15]</sup>. The investigators reviewed the effects of 134-200 mg/day of fenofibrate in 16 patients who had previously failed to respond to therapy with 13-15 mg/day of UDCA: these patients received combination therapy for a mean 22.4 months. Notably, both the serum ALP and IgM levels dropped significantly, with 89% of the patients exhibiting normalized serum ALP levels<sup>[15]</sup>. Another pilot study of six patients with PBC treated with fenofibrate plus UDCA showed significant reductions in the levels of ALP,  $\gamma$ GTP and ALT compared to the values observed in four patients with PBC treated with UDCA alone<sup>[16]</sup>. Similarly, Levy *et al* reported significant decreases in the levels of ALP and IgM following the use of combination therapy consisting of fenofibrate and UDCA for 48 weeks in 20 patients with PBC who had not responded to treatment with UDCA alone<sup>[17]</sup>. Furthermore, Han *et al* investigated the effectiveness of the administration of combination therapy with fenofibrate and UDCA for more than one year in 22 Chinese patients with PBC who displayed a partial response to UDCA and confirmed that the levels of ALP,  $\gamma$ GTP, TG, AST and ALT decreased with no obvious adverse effects, during the treatment period<sup>[18]</sup>. Although these studies<sup>[11,13-19]</sup> demonstrate the biochemical effectiveness of fenofibrate, the histological efficacy of this drug has not been investigated and the effectiveness of treatment with UDCA or UDCA plus fibrate with respect to improving the liver histology remains unclear. Angulo *et al* performed histological evaluations in 16 patients with noncirrhotic PBC treated with UDCA for six and a half years<sup>[20]</sup>. In that study, progression in the histological stage, determined using the Ludwig classification, occurred in eight patients (one stage in seven cases and two stages in one case), whereas no changes were observed in the histological stage in the other eight patients<sup>[20]</sup>. Yano *et al* reported that a histological improvement was not necessarily related to the biochemical response in two patients with aPBC treated with bezafibrate plus UDCA<sup>[21]</sup>.

Therefore, we compared the differences in the reductions in the levels of ALT, ALP,  $\gamma$ GTP and IgM in 13 patients and the changes in liver histology in five patients with aPBC who received therapy with fenofibrate plus UDCA. Our findings demonstrated that combination therapy consisting of UDCA and fenofibrate given for more than 36 months is effective in significantly decreasing the serum levels of ALT, ALP,  $\gamma$ GTP and IgM in patients with aPBC who have previously exhibited an incomplete response to UDCA monotherapy. Moreover, significant reductions were noted in the low-density lipoprotein (LDL), triglyceride and uric acid levels in addition to significant elevation of the high-density lipoprotein (HDL) levels. These effects may help to prevent cardiovascular events in aPBC patients expected to achieve long-term survival.

With regard to the histological evaluations of the liver, we used Scheuer's staging system<sup>[23]</sup> and Nakanuma's staging and grading system<sup>[24,25]</sup>. Histological examinations were performed at the initial administration of fenofibrate and 22-39 months after the start of the fenofibrate therapy in five cases. Consequently, three cases of Scheuer's stage 1 disease improved to portal inflammation, while two cases of Scheuer's stage 1 or Scheuer's stage 2 remained stable. Similarly, three cases of Nakanuma stage 2 improved to Nakanuma stage 1 and one case of Nakanuma stage 3 improved to stage 2. Although one case of Nakanuma stage 2 remained unchanged, the grading in that case improved from HA1 to HA0. Considering the results of our study, the Nakanuma classification, which is based on the degree of fibrosis, bile duct loss and the grade of

necroinflammatory activity according to the CA and HA values, appears to be precise, accurate and more useful than Scheuer's classification for assessing histological aspects of the efficacy of the therapeutic approach.

Our results demonstrated that the use of fenofibrate plus UDCA treatment for aPBC leads to histological improvements as well as reductions in the levels of ALT, ALP,  $\gamma$ GTP and IgM. In this study, there was no apparent tendency for fenofibrate to cause elevation of the levels of total bilirubin, transaminase or creatinine. In addition, no patients experienced adverse effects, such as rhabdomyolysis, miosis or increased serum creatinine phosphokinase (CK) levels.

In conclusion, the present study provides evidence that the administration of fenofibrate in addition to UDCA is safe for aPBC. Moreover, this combination treatment achieves significant biochemical and histological improvements in aPBC patients exhibiting an incomplete response to UDCA. In the future a large sample size and a multi-center case analysis are needed to evaluate whether combination therapy improves histological staging and prognosis.

## CONFLICT OF INTEREST

No funding sources supported this work, and the authors declare that no organizations sponsored the current study.

## REFERENCES

- Talwalker JA, Lindor KD. Primary biliary cirrhosis. *Lancet* 2003; **9377**: 53-61
- Lindor KD, Jorgensen RA, Therneau TM, Malinchoc M, Dickson ER. Ursodeoxycholic acid delays the onset of esophageal varices in primary biliary cirrhosis. *Mayo Chli Proc* 1997; **2**: 1137-40
- Poupon RE, Lindor KD, Cauch-Dudek K, Dickson ER, Poupon R, Heathcote EJ. Combined analysis of randomized controlled trials of ursodeoxycholic acid in primary biliary cirrhosis. *Gastroenterology* 1997; **113**: 884-90
- Floreani A, Caroli D, Variola A, Rizzotto ER, Antoniazzi S, Chiamonte M, Cazzagon N, Brombin C, Salmaso L, Baldo V. A 35-year follow-up of a large cohort of patients with primary biliary cirrhosis seen at a single centre. *Liver International* 2011; **31**: 361-68
- Cuperus FJC, Halilbasic E, Trauner M. Fibrate treatment for primary biliary cirrhosis. *Curr Opin Gastroenterol* 2014; **30**: 279-86
- Pares A, Caballeria L, Rodes J. Excellent long-term survival in patients with primary biliary cirrhosis and biochemical response to ursodeoxycholic acid. *Gastroenterology* 2006; **130**: 715-20
- Corpechot C, Carrat F, Poupon R, Poupon RE. Primary biliary cirrhosis: incidence and predictive factors of cirrhosis development in ursodiol-treated patients. *Gastroenterology* 2002; **122**: 652-58
- Gebel T, Arand M, Oesch F. Induction of the peroxisome proliferator-activated receptor by fenofibrate in rat liver. *FEBS Lett* 1992; **309**: 37-40
- Schoonjans K, Staels B, Auwerx J. Role of the peroxisome proliferator-activated receptor (PPAR) in mediating the effects of fibrates and fatty acids on gene expression. *J Lipid Res* 1996; **37**: 907-25
- Honda A, Ikegami T, Nakamura M, Miyazaki T, Iwamoto J, Hirayama T, Saito Y, Takikawa H, Imawari M, Matsuzaki Y. Anti-cholestatic effects of bezafibrate in patients with primary biliary cirrhosis treated with ursodeoxycholic acid. *Hepatology* 2013; **57**: 1931-41
- Ghonem NS, Boyer JL. Fibrates as adjuvant therapy for chronic cholestatic liver disease: Its time has come. *Hepatology* 2013; **57**: 1691-93
- Wilson TM, Brown PJ, Sternbach DD, Henke BR. The PPAR- $\alpha$ : from orphan receptors to drug discovery. *J Med Chem* 2000; **43**: 527-50
- Ohira H, Sato Y, Ueno T, Sata M: Fenofibrate treatment in patients with primary biliary cirrhosis. *Am J Gastroenterol* 2002; **97**: 2147-49
- Dohmen K, Mizuta T, Nakamura M, Shimohashi N, Ishibashi H, Yamamoto K: Fenofibrate for patients with asymptomatic primary biliary cirrhosis. *World J Gastroenterol* 2004; **10**: 894-898
- Walker LJ, Newton J, Jones DE, Bassendine MF: Comment on biochemical response to ursodeoxycholic acid and long-term prognosis in primary biliary cirrhosis. *Hepatology* 2009; **49**: 337-38
- Liberopoulos EN, Florentin M, Elisaf MS, Mikhailidis DP, Tsianos E: Fenofibrate in primary biliary cirrhosis: a pilot study. *Open Cardiovasc Med J* 2010; **4**: 120-26
- Levy C, Peter JA, Nelson DR, each J, Petz J, Cabrera R, Clark V, Firpi RJ, Morelli G, Soldevila-Pico C, Lindor K: Pilot study: fenofibrate for patients with primary biliary cirrhosis and an incomplete response to ursodeoxycholic acid. *Aliment Pharmacol Ther* 2011; **33**: 235-42
- Han XE, Wang QX, Liu Y, You ZR, Bian ZL, Qiu de K, Ma X: Efficacy of fenofibrate in Chinese patients with primary biliary cirrhosis partially responding to ursodeoxycholic acid therapy. *J Dig Dis* 2012; **13**: 219-24
- Dohmen K, Tanaka H, Haruno M. The effectiveness of fenofibrate in comparison to bezafibrate for patients with asymptomatic primary biliary cirrhosis. *Fukuoka Acta Medica* 2013; **104**: 350-61
- Angulo P, Batts KP, Therneau TM, Jorgensen RA, Dickson ER, Lindor KD: Long-term ursodeoxycholic acid delays histological progression in primary biliary cirrhosis. *Hepatology* 1999; **29**: 644-47
- Yano K, Kato H, Morita S, Takahara O, Ishibashi H, Furukawa R: Is bezafibrate histologically effective for primary biliary cirrhosis. *Am J Gastroenterol* 2002; **97**: 1075-77
- Lindor KD, Gershwin ME, Poupon R, Kaplan M, Bergasa NV, Heathcote EJ; American Association for Study of Liver Diseases: Primary biliary cirrhosis. *Hepatology* 2009; **50**: 291-308
- Scheuer PJ. Primary biliary cirrhosis. *Proc R Soc Med* 1967; **60**: 1257-60
- Hiramatsu K, Aoyama H, Zen Y, Aishima S, Kitagawa S, Nakanuma Y: Proposal of a new staging and grading system of the liver for primary biliary cirrhosis. *Histopathology* 2006; **49**: 466-78
- Nakanuma Y, Zen Y, Harada K, Sasaki M, Nonomura A, Uehara T, Sano K, Kondo F, Fukusato T, Tsuneyama K, Ito M, Wakasa K, Nomoto M, Minato H, Haga H, Kage M, Yano H, Haratake J, Aishima S, Masuda T, Aoyama H, Miyakawa-Hayashino A, Matsumoto T, Sanefuji H, Ojima H, Chen TC, Yu E, Kim JH, Park YN, Tsui W. Application of a new histological staging and grading system for primary biliary cirrhosis to liver biopsy specimen: Interobserver agreement. *Pathol Int* 2010; **60**: 167-74
- Vu-Dac N, Schoonjans K, Kosykh V, Dallongeville J, Fruchart JC, Staels B, Auwerx J: Fibrates increase human apolipoprotein A-II expression through activation of the peroxisome proliferator-activated receptor. *J Clin Invest* 1995; **96**: 741-50
- Thulin P, Rafter I, Stockling K, Tomkiewicz C, Norjavaara E, Aggerbeck M, Hellmold H, Ehrenborg E, Andersson U, Cotgreave I, Glinghammar B: PPARalpha regulates the hepatotoxic biomarker alanine aminotransferase (ALT1) gene expression in human hepatocytes. *Toxicol Appl Pharmacol* 2008; **231**: 1-9
- Zhang L-N, Shi T-Y, Shi X-H, Wang L, Yang YJ, Liu B, Gao LX, Shuai ZW, Kong F, Chen H, Han W, Han SM, Fei YY, Cui QC, Wang Q, Shen M, Xu D, Zheng WJ, Li YZ, Zhang W, Zhang X, Zhang FC: Early biochemical response to ursodeoxycholic acid and long-term prognosis of primary biliary cirrhosis: results of a 14-year cohort study. *Hepatology* 2013; **58**: 264-72
- Nakai S, Masaki T, Kurokohchi K, Deguchi A, Nishioka M. Combination therapy of bezafibrate and ursodeoxycholic acid in

- primary biliary cirrhosis: a preliminary study. *Am J Gastroenterol* 2000; **95**: 326-27
- 30 Kanda T, Yokosuka O, Imazeki F, Saisho H: Bezafibrate treatment: a new medical approach for PBC patients? *J Gastroenterol* 2003; **38**: 573-78
- 31 Itakura J, Izumi N, Nishimura Y, Inoue K, Ueda K, Nakanishi H, Tsuchiya K, Hamano K, Asahina Y, Kurosaki M, Uchihara M, Miyake S: Prospective randomized crossover trial of combination therapy with bezafibrate and UDCA for primary biliary cirrhosis. *Hepatol Res* 2004; **29**: 216-22
- 32 Iwasaki S, Ohira H, Nishiguchi S, Zeniya M, Kaneko S, Onji M, Ishibashi H, Sakaida I, Kuriyama S, Ichida T, Onishi S, Toda G; Study Group of Intractable Liver Diseases for Research on a Specific Disease, Health Science Research Grant, Ministry of Health, Labour and Welfare of Japan: The efficacy of ursodeoxycholic acid and bezafibrate combination therapy for primary biliary cirrhosis: a prospective, multicenter study. *Hepatol Res* 2008; **38**: 557-64
- 33 Hazzan R, Tur-Kaspa R: Bezafibrate treatment of primary biliary cirrhosis following incomplete response to ursodeoxycholic acid. *J Clin Gastroenterol* 2010; **44**: 371-73
- 34 Lens S, Leoz M, Nazal L, Bruguera M, Parés A: Bezafibrate normalizes alkaline phosphatase in primary biliary cirrhosis patients with incomplete response to ursodeoxycholic acid. *Liver Int* 2014; **34**: 197-203
- 35 Pineda-Torra I, Claudel T, Duval C, Kosykh V, Fruchart JC, Staels B: Bile acids induce the expression of the human peroxisome proliferator-activated receptor alpha gene via activation of the farnesoid X receptor. *Mol Endocrinol* 2003; **17**: 259-72
- 36 Chianale J, Vollrath V, Wielandt AM, Amigo L, Rigotti A, Nervi F, Gonzalez S, Andrade L, Pizarro M, Accatino L: Fibrates induce mdr2 gene expression and biliary phospholipid secretion in the mouse. *Biochem J* 1996; **314**: 781-86
- 37 Smit JJ, Schinkel AH, Oude Elferink RP, Groen AK, Wagenaar E, van Deemter L, Mol CA, Ottenhoff R, van der Lugt NM, van Roon MA: Homozygous disruption of the murine mdr2 P-glycoprotein gene leads to a complete absence of phospholipid from bile and to liver disease. *Cell* 1993; **75**: 451-62
- 38 Matsumoto T, Miyazaki H, Nakahashi Y, Hirohara J, Seki T, Inoue K, Okazaki K: Multidrug resistance 3 is in situ decreased in the liver of patients with primary biliary cirrhosis, and induced in human hepatoma cells by bezafibrate. *Hepatol Res* 2004; **30**: 125-36
- Peer reviewer:** Fethi Derbel, Professor, University hospital Sahloul. Department of general and digestive surgery, 4056. SOUSSE. Tunisia.