

Osteopontin as A Tumor Marker for Hepatocellular Carcinoma

Amal Ahmed Mohamed, Naglaa El-Toukhy, Ayman Abdel-Hady Alkhalegy, Sherif Boraii

Amal Ahmed Mohamed, Department of Biochemistry, National Hepatology and Tropical Medicine Research Institute, Cairo, Egypt
Naglaa El-Toukhy, Department of Hepatology & Gastroenterology and Infectious diseases, Faculty of medicine, Benha University, Egypt

Ayman Abdel-Hady Alkhalegy, Department of General Surgery, Al Sahel Teaching Hospital, Cairo, Egypt

Sherif Boraii, Department of Surgery, National Hepatology and Tropical Medicine Research Institute, Cairo, Egypt

Correspondence to: Amal Ahmed Mohamed, Consultant of Biochemistry and Molecular Biology, Biochemistry department, National Hepatology and Tropical Medicine Research Institute, Fom El-Khalig, Cairo, 11796, Egypt.

Email: amalahmedhcp@yahoo.com

Telephone: +201224847367

Fax: +201094918168

Received: June 18, 2016

Revised: July 15, 2016

Accepted: July 17, 2016

Published online: August 21, 2016

systems.

RESULTS: Serum OPN was significantly higher in HCC patients compared to cirrhotic patients and controls. The sensitivity and specificity in diagnosis of HCC were 92.5% and 85% respectively at cutoff of 239 ng/mL with 91.1% accuracy. OPN has a positive significant correlation with tumor number ($p = 0.036$), CLIP ($p = 0.02$), Tokyo ($P = 0.03$), and VISUM ($P = 0.01$) staging systems.

CONCLUSION: OPN could be a useful diagnostic & prognostic marker for detection of HCC.

Key words: Hepatocellular carcinoma; Osteopontin; Alpha-fetoprotein

© 2016 The Authors. Published by ACT Publishing Group Ltd.

Mohamed AA, El-Toukhy N, Abdel-Hady Alkhalegy A, Boraii S. Osteopontin as A Tumor Marker for Hepatocellular Carcinoma. *Journal of Gastroenterology and Hepatology Research* 2016; 5(4): 2140-2146 Available from: URL: <http://www.ghrnet.org/index.php/joghr/article/view/1733>

ABSTRACT

AIM: Hepatocellular carcinoma (HCC) is a global health problem because of its increasing prevalence worldwide and its poor prognosis. In Egypt HCC incidence has increased sharply and nearly doubled over the last decade. The outcome of HCC depends mainly on its early diagnosis; therefore, new and specific markers for HCC are critically needed. Osteopontin (OPN) is a glycoprotein that overexpressed in HCC, and known to be an independent predictor of poor prognosis. The aim was to assess the value of OPN in Egyptian patients with HCC.

METHODS: This study included 40 patients with HCC, 20 patients with liver cirrhosis and 20 healthy controls. For all groups, clinical data and image findings were studied; serum alpha-fetoprotein & OPN levels were detected by enzyme immunoassay (EIA) kit. Tumor characteristics were assessed including size, number and site. Tumor staging was done using Okuda, CLIP, VISUM and Tokyo staging

INTRODUCTION

Worldwide, Hepatocellular carcinoma (HCC) is the fifth most common cancer in men and the seventh in women, with more than 748,000 new cases being diagnosed each year, accounting for 9.2% of all new global cancer cases (7.9% in men; 3.7% in women) [1,2]. Hepatocellular carcinoma (HCC) is the third leading cause of cancer-related death worldwide and one of the leading causes of death among patients with cirrhosis [3]. In Egypt, HCC is the second most common cancer in men and the sixth most common cancer in women [4]. Hospital-based studies in Egypt have reported an increase in the relative frequency of all liver-related cancers; from 4% in 1993 to 7.3% in 2003 [5] and the increased survival rate among patients with cirrhosis allowing time for some of them to develop HCC [4]. Hepatic resection and transplantation remain the standard curative therapies for HCC. These treatments are limited to either patients with early-stage tumors in the case of transplantation or patients with preserved

liver function in the case of resection^[6]. Early detection is critically important because the most effective treatment for HCC is surgical resection or ablation therapy when the tumor is small^[7].

Prognosis for patients with HCC depends on tumor stage, with curative therapies only available for patients detected at an early stage, patients detected at an early stage can achieve 5-year survival rates of 70% with transplant or resection, whereas those with advanced HCC are only eligible for palliative treatments and have a median survival of less than one year^[8]. Up to 20% of HCC do not produce alpha-fetoprotein (AFP) even when very large^[9]. The fibrolamellar variant most commonly occurs in young Caucasian females often with lymph node metastasis and without elevations of AFP^[10] and slight increases are usual in acute hepatitis, chronic hepatitis and cirrhosis and overlaps can cause diagnostic difficulties^[11]. Osteopontin (OPN) is known to be a secreted adhesive glycoprotein, associated with tumorigenesis and metastasis in several cancers^[12]. Plasma OPN level is a potential diagnostic marker for HCC, especially among high-risk group of patients^[13]. Osteopontin (OPN) has been reported as one of the most promising markers for HCC^[14]. Overexpression of OPN was associated significantly with the metastatic potential of primary HCC^[15]. Moreover, subsequent study suggested OPN plasma level was elevated in HCC patients, and it has superior diagnostic accuracy as a tumor marker compared with α -fetoprotein^[16]. In this study we aimed at evaluating the diagnostic and prognostic value of osteopontin in comparison to AFP levels in patients with HCC.

METHODS

This study was approved by the Ethics and Research Committee of the Benha faculty of Medicine, Benha University, Egypt. Serum samples were obtained from sixty patients with chronic liver disease, divided into two groups: Group (I) included forty patients with HCC, Patients with cancers other than HCC or metastatic liver cancer were excluded. Group (II) included twenty patients with liver cirrhosis and without any evidence of HCC and Twenty healthy adults were recruited as controls (Group III). All patients included in this study had the procedure thoroughly explained to them. HCC was diagnosed by abdominal US and confirmed by triphasic CT scan. AFP was assayed by an enzyme immunoassay (EIA) Kit (Roche Mannheim, Germany). The clinical/pathological data of the patients were recorded, including age, sex, viral infections {Hepatitis C Virus (HCV) and Hepatitis B Virus (HBV)}, alcohol intakes, biochemical liver function test results, and AFP levels. Severity of liver disease was assessed by modified Child-Pugh score^[17] and MELD (model for end stage liver disease) score^[18] and the updated MELD (uMELD) score^[19]. Tumor characteristics were detected by abdominal US with or without CT scan (including tumor size, number, site, halo sign and neovascularization). Tumor staging was done using Okuda^[20], CLIP (The Cancer of the Liver Italian Program)^[21], VISUM (Vienna survival model for HCC)^[22] and Tokyo^[23] staging systems.

Blood sampling and biochemical assays

Fasting venous blood samples (5 mL) were collected by trained laboratory technicians. A portion of blood was allowed to clot and then centrifuged at 3,500 g for 5 min to separate the serum used for assessment of aspartate aminotransferase (AST), alanine aminotransferase (ALT), and γ -glutamyl transpeptidase (GGT), total bilirubin, direct bilirubin, albumin, creatinine and glucose concentrations were assayed using Beckman CX4 chemistry analyzer (NY, USA, supplied by the Eastern Co. For Eng. & Trade-Giza, Egypt). Viral infection status (HCV Ab and HBsAg) were measured using Abbott, Axyam

(USA, Supplied by Al kamal company). Serum aliquots were stored at -80°C until assayed and thawed immediately before the measurements levels. Serum AFP and Osteopontin levels was determined using an enzyme-linked binding protein assay kit. All assays were performed in duplicate according to the manufacturer's instructions.

Tissue Samples

For cases with HCC, liver samples were collected intraoperative after the patients were surgically operated for hepatic lobectomy. Specimens were obtained from the tumour tissue and fixed in formalin then embedded in paraffin blocks for histopathological examination. Using a microtome, sections 5 μm thick were cut from formalin-fixed paraffin embedded tissue blocks and subjected for H&E staining and pathological diagnosis, grading.

Statistical Analysis

Statistical package (SPSS, version 20.0) was used for data management. Descriptive statistics was presented as mean \pm standard deviations for continuous variables, number and percentage for categorical variables (frequency distribution). Unpaired student t-test (two sided) was used to test the significance of difference between the mean value of studied groups and chi-square test was used for comparison of categorical variables. The diagnostic value for each marker was assessed using sensitivity, specificity, positive (PPV) and negative (NPV) predictive values. Receiver operating characteristic curves (ROC) were constructed to assess the validity of the markers in predicting HCC by calculating the area under the curve (AUC). Pearson correlation test was used to identify the correlation between Osteopontin and different clinico-pathological variables. The significance level was set at $P < 0.05$.

RESULTS

The demographic features and characteristics of the (two patients' groups) were summarized in Table 1. A total of 80 adults, which comprised 40 patients with HCC, 20 patients with liver cirrhosis in addition to 20 apparently normal control subjects were studied for the osteopontin and AFP. The mean age of HCC patients was 60.9 ± 9 years with a range between 48 and 89 years. In liver cirrhosis patients the mean age was 56.5 ± 9.3 years with a range between 34 and 80 years, with no significant difference in the mean ages of patient groups, however HCC tends to occur at higher age. There was male predominance among the patients with HCC, 31 men (77.5%) versus 9 women (22.5%), with a male-to- female ratio of 3.4:1. There was a significant difference in the sex ratios of HCC patients, liver cirrhosis patients ($P = 0.01$). Concerning the residence, either rural or urban, 62.5% of HCC cases had urban residence. In addition, a positive history for farming was found in 35% of HCC cases. Regarding HCC etiology, the results showed that the frequency of HBV positivity had no statistically significant difference between the studied patients. It was detected only in two HCC cases and in 0% in cirrhotic cases. HCV was present in 92.5% of HCC cases and 90% of cirrhotic cases with no statistically significant difference between the two groups. The liver functions in cirrhosis assessed by Child-Pugh classification among the studied patients showed that 15% of HCC cases were Child A, while 20% of HCC cases were Child B and 65% were Child C with no statistical significant difference between the two groups. There was no statistically significant difference among the two groups as regards the severity of liver disease assessed by MELD scores (Table 1). Tumor imaging characteristics of HCC patients were illustrated in (Table 2). Abdominal CT showed the dominant

occurrence of HCC on top of cirrhosis (100%) and a percentage of portal vein thrombosis (PVT) of (12.5%) and the higher incidence of the focal lesion to be single (57.5%), large and affecting the right lobe (60 %), and halo sign in 95% of the patients.

Regarding Okuda, CLIP, VISUM and Tokyo staging systems, most of HCC patients were relatively at advanced stage of the disease. As regards AFP levels, the data revealed that as regards AFP values there was no significant difference between HCC cases and cirrhotics (P1=0.051) and between cirrhotics and control groups (P3=0.995), but AFP values were higher in HCC cases than control group (P2=0.05) (Table 3), Figure 1. As regards osteopontin values were higher in HCC cases than cirrhotics (P1=0.000), higher in HCC than control (P2=0.000), but no significant difference between cirrhotics & control (P3=0.227). (Table 3), Figure 2. In the receiver operating

curve (ROC) (Table 4), Figure3, the area under curve (AUC) for AFP was 78.7% when we use 12.9 ng/mL as a cutoff point, with a sensitivity of 70% and a specificity of 77.5%, PPV of 95.2% and NPV of 62.5%. For Osteopontin the cutoff point that gives an AUC of 91.1% was 239 ng/mL with a sensitivity of 92.5% and a specificity of 85%, PPV of 95.2% and NPV of 86.95%. There was significant positive correlation between AFP and CLIP ($P = 0.005$), Tokyo ($p = 0.03$) and VISUM ($P = 0.02$) staging system among HCC cases.

There was significant positive correlation between Osteopontin and Tumor number ($P = 0.036$), CLIP ($p = 0.02$), Tokyo ($p = 0.03$), and VISUM ($P = 0.01$) staging system among HCC cases, Figures (4, 5, 6, 7) respectively.

Table 1 Demographic Features of the studied patient groups:

Characteristics	HCC Patients (n = 40)	Liver Cirrhosis (n = 20)	P. value
Age (years)			
Range	48- 89	34- 80	0.08
Mean ± SD	60.9 ± 9	56.5 ± 9.3	
Gender			
Male	31 (77.5%)		0.01*
Female	9 (22.5%)	9 (45%)	
Residence		11 (55%)	
Urban	25 (62.5%)		0.54
Rural	15 (37.5%)	13 (65%)	
Occupation		7 (35%)	
Farmer	14 (35%)		
Non- farmer	26 (65%)	4 (20%)	0.186
Etiology		16 (80%)	
Smoking	22 (55%)		0.2
Alcohol	1 (2.5%)	8 (40%)	
HCV	37 (92.5%)	1 (5%)	0.54
HBV	2 (5%)	18 (90%)	0.44
Severity of Liver disease Child- Pugh score		0 (0%)	
Child A	6 (15%)	2 (10%)	0.59
Child B	8 (20%)	4 (20%)	1
Child C	26 (65%)	14 (70%)	0.65
MELD Score			
Range	6- 44	7- 45	0.79
Mean ± SD	19.9 ± 9.1	20.6 ± 9.4	
uMELD Score			
Range	2.6 - 7.1	2 - 6.6	0.58
Mean ± SD	4.08 ± 1.1	4.2 ± 1.18	

*: Significant; SD: Standard deviation; HCC: hepatocellular carcinoma; HCV: Hepatitis c virus; HBV: Hepatitis B virus; MELD: Model for end stage liver disease; uMELD: updated MELD.

Table 2 Tumour- related findings and characteristics of the HCC Patient group.

Characteristics	HCC Patients (n = 40)	Percentage (%)
Computed Tomographic Features		
Tumor size		
< 3 / 3-5 / > 5 cm	9/ 17/ 14	22.5/ 42.5/ 35
No. of nodules		
Single / 2 or more	23 / 17	57.5 / 42.5
Site of Tumor		
Right lobe/left lobe/both	24/ 3 / 13	60/ 7.5/ 32.5
Shape		
Rounded/oval/filldefined	23 / 12 / 5	57.5 / 30 / 12.5
Echogenicity		
Hyperechoic/hypoechoic/isoechoic	24 / 13 / 3	60 / 32.5 / 7.5
Halo sign	38	95
Metastasis	1	2.5
Portal vein invasion	5	12.5
Tumor staging		
Okuda stage		
I / II / III	6 / 16 / 18	15 / 40/ 45
CLIP stage		
I / II / III	4 / 22/ 14	10/ 55/ 35
Tokyo stage		
Early (0- 4)	17	42.5
Advanced (5 or more)	23	57.5
VISUM stage		
I / II / III	19/ 13/ 8	47.5/ 32.5/ 20
AFP (ng/mL) level		
Range	2.5- 30000	
Mean	2687.5	
Osteopontin (ng/mL) level		
Range	40- 913	
Mean	537.2	

AFP: Alphafetoprotein; CLIP: Cancer of the liver Italian program; HCC: hepatocellular carcinoma; VISUM: Vienna survival model.

Table 3 AFP and Osteopontin as markers for HCC AFP and Osteopontin values in the studied groups.

Marker	Group I HCC (N = 40)		Group II cirrhosis (N = 20)		Group III control (N = 20)		P value
	Range	Mean ± SD	Range	Mean ± SD	Range	Mean ± SD	
Osteopontin(ng/mL)	40-913	537.2 ± 211.3	40-321	202.2 ± 62.49	42-722	134.1 ± 176.09	P1=0.000* P2=0.000* P3=0.227
AFP (ng/mL)	2.5-30000	2687.5 ± 6887.4	0.5-187	20.5 ± 40.9	4.2-35	10.8 ± 8.2	P1=0.057 P2=0.05* P3=0.995

*: significant.

Table 4 AFP and Osteopontin as markers for HCC.

Test	Cut off	Sensitivity %	Specificity %	PPV %	NPV %	AUC %	P-value
Osteopontinng/mL	239	92.5	85	95.2	86.95	91.1	0.000*
AFP ng/mL	12.5	70	77.5	95.2	62.5	78.7	0.000*

*: significant; PPV: positive predictive value; NPV: negative predictive value; AUC: area under curve: AFP=alphafetoprotein.

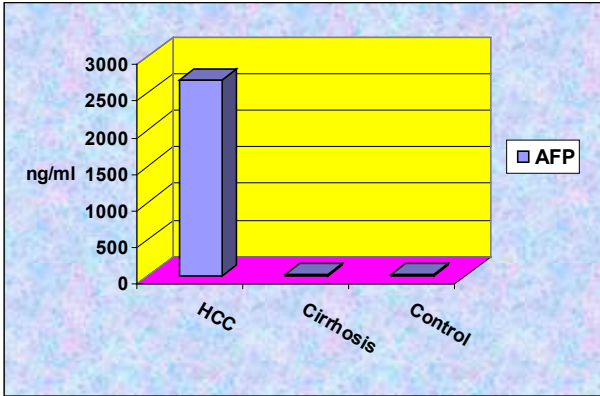


Figure 1 Alpha fetoprotein levels among the studied groups.

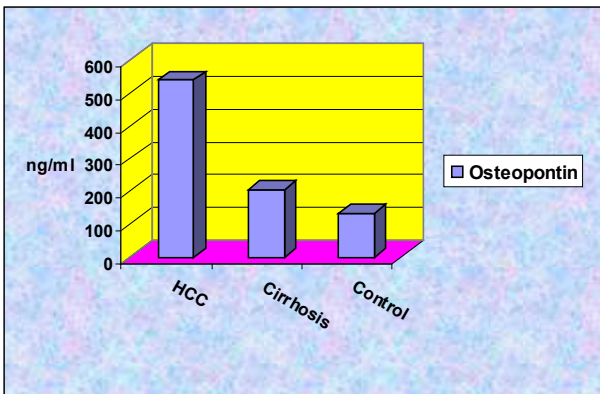


Figure 2 Osteopontin levels among the studied groups.

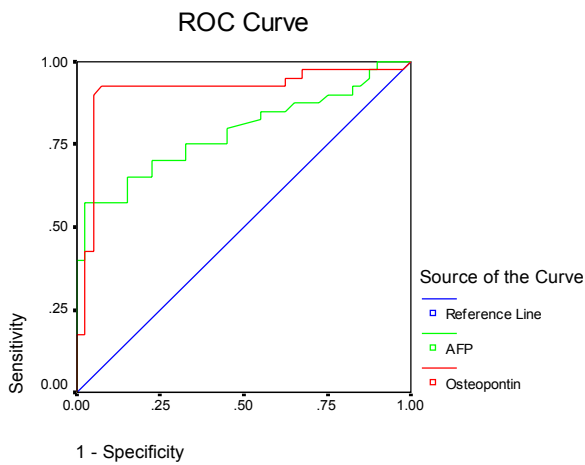


Figure 3 ROC curve of AFP and osteopontin as a marker for HCC.

DISCUSSION

AFP is the most established tumour marker in HCC and is the gold standard by which other markers for the disease are judged^[24]. In the current study AFP in HCC cases had a mean value of 2687.5 ng/mL which was higher than that of patients with cirrhosis (although not statistically significant) (20.5 ng/mL) and control (10.8 ng/mL) subjects, these results are in agreement with Abdel-Hamid *et al.*^[25] who reported that AFP in HCC cases had a mean value of 1172.4 ng/ml which was statistically higher than that of patients with cirrhosis (22.5 ng/mL) and control (7.01 ng/mL) subjects. Furthermore, similar

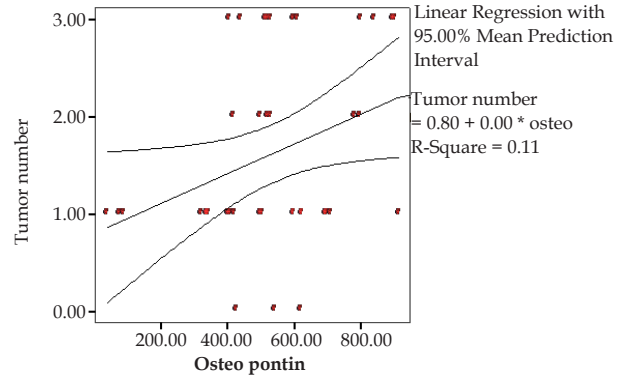


Figure 4 Correlations of osteopontin values and Tumor number among HCC cases.

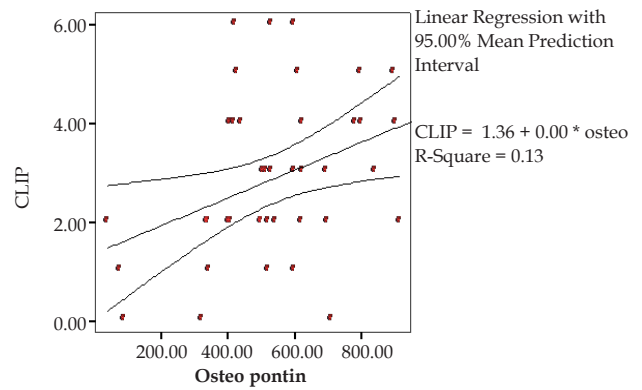


Figure 5 Correlations of osteopontin values and CLIP stage among HCC cases.

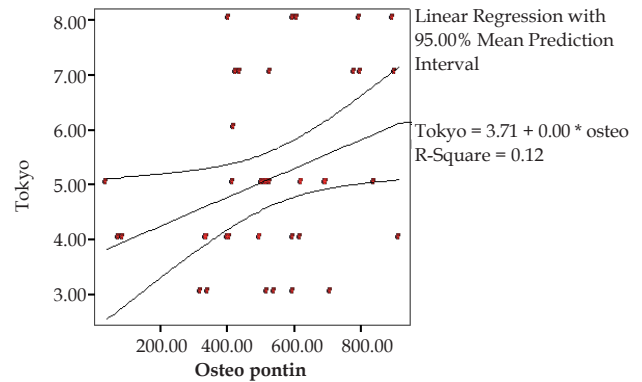


Figure 6 Correlations of osteopontin values and Tokyo stage among HCC cases.

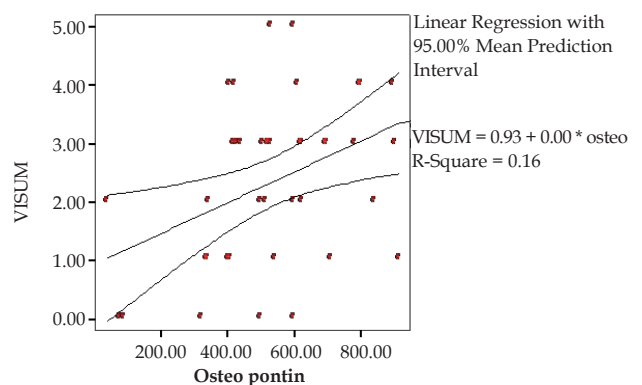


Figure 7 Correlations of osteopontin values and VISUM stage among HCC cases.

findings were observed by Salem *et al.*^[26], Lee *et al.*^[27], Abdel gawad *et al.*^[28] and El-Shenawy *et al.*^[29] who reported higher mean values of AFP for HCC cases. ROC analysis of AFP used as a diagnostic test suggested that a value of about 12.9 ng/mL provided the optimal balance between sensitivity and specificity, however at this level the sensitivity was only 70% and the specificity was 77.5%, which is inadequate sensitivity and specificity for early diagnosis of HCC.

This goes in agreement with Bruix and Sherman^[30] and Abu El-Makarem *et al.*^[13] who reported the same results. Accordingly, the role of AFP in the diagnosis of HCC is limited, these results were supported by El-Serag *et al.*^[31] who mentioned that AFP is not elevated in all patients with HCC, its sensitivity for detecting HCC ranges between 25%-60%, and its specificity is also low because serum AFP can also be detected in patients with cirrhosis and chronic hepatitis.

Therefore, the finding of a mass in the liver with an elevated AFP does not automatically indicate HCC; intrahepatic cholangiocarcinoma (ICC) is also more common in cirrhosis than in non cirrhotics. The fact that both are more common in cirrhosis means that care must be taken to distinguish between them given the differences in treatment and outcomes. Since AFP can be elevated in either condition, it is recommended that it no longer be used^[30]. There is a debate in defining the AFP cut-off level for the diagnosis of HCC, an AFP value above 400-500 ng/mL has been considered to be diagnostic for HCC in patients with cirrhosis, however, such a cut-off value is problematic in absolute diagnostic terms, since high levels of this magnitude are not as common in the presence of smaller tumors (< 5 cm) and furthermore, only 30% of HCC patients have levels higher than 100 ng/mL in this context^[32]. There was non-significant correlation between AFP and the severity of the liver disease (Child, MELD and uMELD scores), tumor number, size, OPN and Okuda stage, this finding is supported by Huo *et al.*^[33] and Atta *et al.*^[34] who reported that no correlation was observed between AFP and severity of the liver disease. This can be explained by that transient increases and fluctuations in serum AFP may occur in chronic liver disease and cirrhosis, especially during exacerbations of hepatitis^[24], mild to moderate elevations (20-400 ng/mL) occur in cirrhosis^[35]. But the frequency of elevated AFP did not differ with regards to MELD score or cirrhotic disease^[36]. But there was significant positive correlation between AFP and CLIP, Tokyo, and VISUM staging system among HCC cases, these were in agreement with El-Shenawy *et al.*^[29] and El-Zayadi *et al.*^[37] who reported that there was significant positive correlation between AFP and CLIP staging systems.

Regarding AFP as prognostic predictor in HCC, our results supported by Kim *et al.*^[38] and Tandon and Garcia-Tsao^[39] who concluded that serum AFP may have a prognostic meaning in patients with HCC, and is included in prognostic classifications such as CLIP score and VISUM staging system, this may be explained by the issue that an increase in AFP concentration might reflect tumor aggressiveness including differentiation degree and vascular invasion^[40]. Concerning OPN mean value, HCC cases had a mean value of (537.2 ng/mL) which was higher than that of patients with cirrhosis (202.2 ng/mL) and control (134.1 ng/mL) subjects, these results were in agreement with Shang *et al.*^[41] who reported that plasma levels of OPN were significantly higher in HCC patients (mean 271.4 ng/mL) than in cirrhosis (mean 86.2 ng/mL) and healthy controls (mean 32 ng/mL). Similar results by Kim *et al.*^[16], El-Din Bessa *et al.*^[42] and Abu El Makarem *et al.*^[13] were reported, who found that the median plasma OPN level was significantly higher in the HCC group than in the cirrhotic group or in the normal control group. ROC analysis of OPN used as a diagnostic test suggested that a value of 239 ng/mL provided the optimal balance between sensitivity and specificity, at this level the

sensitivity was 92.5% and specificity was 85%, which is considered good sensitivity and specificity for diagnosis of HCC. This goes in agreement with Abu El Makarem *et al.*^[13] who reported that OPN had high diagnostic efficiency for HCC (the sensitivity and specificity of plasma OPN levels in HCC patients relative to the CLD group were 97.67% and 100% respectively, at a cut-off value of 300 ng/mL).

Similar results by Kim *et al.*^[16] and El-Din Bessa *et al.*^[42] were observed, who reported that OPN had high diagnostic sensitivity and specificity for HCC group over non-HCC group (cirrhotic group and healthy control). There was no significant correlation between plasma OPN and severity of liver disease; this was in agreement with Abu El Makarem *et al.*^[13] and Abdel-Hamid *et al.*^[25] who reported the same results.

There was significant correlation between plasma OPN and tumor number; this goes in agreement with Salem *et al.*^[26] and Abu El Makarem *et al.*^[13] who reported that there was a significant correlation between plasma OPN and number of nodules. There was no significant correlation between plasma OPN and the size of the tumor, this goes in agreement with Salem *et al.*^[26], but disagree with Abu El Makarem *et al.*^[13] who reported that there was significant correlation between plasma OPN and size of tumor nodules.

There was significant positive correlation between plasma OPN and CLIP, Tokyo, and VISUM staging system among HCC cases, these results were in agreement with Abu El Makarem *et al.*^[13] and Zhang *et al.*^[43] who reported that plasma OPN was significantly correlated with advancing degree of tumor stage and tumor progression. There was no significant correlation between plasma OPN and AFP in the present study, this goes in agreement with Abu El Makarem *et al.*^[13] and Kim *et al.*^[16] who reported that exactly.

CONCLUSION

Regarding OPN as prognostic marker for HCC, these results suggested that plasma OPN level could be a potential prognostic marker for HCC, this suggestion was supported by Hua *et al.*^[44] and Abu El-Makarem *et al.*^[13] who documented that there is significant correlation between OPN overexpression and tumor progression (high grade, late stage, LN/vascular invasion). Also Chen *et al.*^[45] stated that OPN overexpression has been revealed as an independent prognostic factor for poor overall and disease free survival in HCC patients.

According to this study, plasma OPN level was elevated in HCC patients than cirrhotic and apparently healthy patients, with better diagnostic sensitivity and specificity for HCC group over non-HCC group (cirrhotic group and healthy control) with slightly better prognosis than AFP, these results suggested that plasma OPN level could be a potential diagnostic and prognostic marker for HCC.

CONFLICT OF INTEREST

The authors declare that they do not have conflict of interests.

REFERENCES

- 1 Ferlay J, Shin H, Bray F, Forman D, Mathers C, Parkin DM. Estimates of worldwide burden of cancer in 2008: GLOBOCAN 2008. *Int J Cancer* 2010; **127**: 2893-2917.
- 2 Jemal A, Bray F, Center MM, Ferlay J, Ward E, Forman D. Global cancer statistics. *Carcinogenesis* 2011; **61**: 69-90.
- 3 El-Serag HB. Epidemiology of viral hepatitis and hepatocellular carcinoma. *Gastroenterology* 2012; **142**: 1264-1273.
- 4 Omar A, Abou-Alfa GK, Khairy A, Omar H. Risk factors for developing hepatocellular carcinoma in Egypt. *Chin Clin Oncol*

- 2013; **2(4)**: 43.
- 5 Lehman EM, Wilson ML. Epidemiology of hepatitis viruses among hepatocellular carcinoma cases and healthy people in Egypt: a systematic review and meta-analysis. *Int J Cancer* 2009; **124(3)**: 690-697.
 - 6 Llovet JM, Beaugrand M. Hepatocellular carcinoma: present status and future prospects. *J Hepatol* 2003; **38(Suppl 1)**: S136-S149.
 - 7 Bolondi L, Gaini S, Celli N, Rita Golfieri, Walter Francesco Grigioni, Simona Leoni, Anna Maria Venturi, Fabio Piscaglia. Characterization of small nodules in cirrhosis by assessment of vascularity: the problem of hypovascular hepatocellular carcinoma. *Hepatology* 2005; **42**: 24-34.
 - 8 Padhya KT, Marrero JA, Singal AG. Recent advances in the treatment of hepatocellular carcinoma. *Curr Opin Gastroenterol* 2013; **29**: 285-292.
 - 9 Ryder SD. Guidelines for the diagnosis and treatment of hepatocellular carcinoma (HCC) in adults. *Gut* 2003; **52 (suppl III)**: 1-8.
 - 10 El-Serag HB, Davila JA. Is fibrolamellar carcinoma different from hepatocellular carcinoma? A US population-based study. *Hepatology* 2004; **39(3)**: 798-803.
 - 11 Sherlock S, Dooley J. Diseases of the liver and biliary system. 11th ed., Blackwell SC, Oxford, London, Eninburgh, 2002 Chapter 31, page 537-561.
 - 12 Anborgh PH, Mutrie JC, Tuck AB, Chambers AF. Role of the metastasis-promoting protein osteopontin in the tumor microenvironment. *J Cell Mol Med* 2010; **14**: 2037-2044.
 - 13 Abu El Makarem MA, Abdel-Aleem A, Ali A *et al* Diagnostic significance of plasma osteopontin in hepatitis C virus related hepatocellular carcinoma. *Ann Hepatol* 2011; **10**: 296-305.
 - 14 Wan HG, Xu H, Gu YM, Wang H, Xu W, Zu MH. Comparison osteopontin vs AFP for the diagnosis of HCC: A meta-analysis. *Clin Res Hepatol Gastroenterol* 2014; **38(6)**: 706-714.
 - 15 Ye QH, Qin LX, Forgues M, He P, Kim JW, Peng AC, Simon R, Li Y, Robles AI, Chen Y, Ma ZC, Wu ZQ, Y SL, Liu YK, Tang ZY, Wang XW. Predicting hepatitis B virus-positive metastatic hepatocellular carcinomas using gene expression profiling and supervised machine learning. *Nat Med* 2003; **9**: 416-423.
 - 16 Kim J, Ki SS, Lee SD, Han CJ, Kim YC, Park SH, Cho SY, Hong YJ, Park HY, Lee M, Jung HH, Lee KH, Jeong SH. Elevated plasma osteopontin levels in patients with hepatocellular carcinoma. *Am J Gastroenterol* 2006; **101**: 2051-2059.
 - 17 Pugh RN, Murray-Lyon IM, Dawson JL, Pietroni MC, Williams R. Transection of the oesophagus for bleeding oesophageal varices. *Br J Surg* 1973; **60**: 646-649.
 - 18 Kamath PS, Wiesner RH, Malinchoc M, Kremers W, Therneau TM, Kosberg CL, D'Amico G, Dickson ER, Kim WR. A model to predict survival in patients with end-stage liver disease. *Hepatology* 2001; **33**: 464-470.
 - 19 Sharma P, Shaubel DE, Sima CS, Merion R, Lok AS. Re-weighting the model for 2nd-stage liver disease score components. *Gastroenterology* 2008; **135**: 1575-1581.
 - 20 Okuda K, Ohtsuki T, Obata H, Masahiko Tomimatsu, Nobuo Okazaki, Hiroshi Hasegawa, Yukio Nakajima, Kunihiko Ohnishi. Natural history of hepatocellular carcinoma and prognosis in relation to treatment. Study of 850 patients. *Cancer* 1985; **56**: 918-928.
 - 21 The Cancer of the Liver Italian Program (CLIP) Investigators. A new prognostic system for hepatocellular carcinoma: a retrospective study of 435 patients. *Hepatology* 1998; **28**: 751-755.
 - 22 Henkele MS, Muller C, Kutilek M, Oesterreicher C, Ferenci P, Gangl A. Hepatocellular carcinoma in central Europe: prognostic features and survival. *Gut* 2001; **48**: 103-109.
 - 23 Tateishi R, Yoshida H, Shiina S, Imamura H, Hasegawa K, Teratani T, Obi S, Sato S, Koike Y, Fujishima T, Makuuchi M, Omata M. Proposal of a new prognostic model for hepatocellular carcinoma: an analysis of 403 patients. *Gut* 2005; **54**: 419-425.
 - 24 Lopez JB. Recent development in the first detection of hepatocellular carcinoma. *Clin Biochem Rev* 2005; **26**: 65-79.
 - 25 Abdel-Hamid M, Ellakwa DE, Omar NN. Role of Serum Osteopontin Level as a Diagnostic Biomarker for Early Hepatocellular Carcinoma. *International Journal of Cancer Research* 2014; **10(1)**: 37-45.
 - 26 Salem M, Attia SA, El- Raziky M *et al* Clinical Significance of Plasma Osteopontin Level as a Biomarker of Hepatocellular Carcinoma. *Gastroenterology Research* 2013; **6(5)**: 191-199.
 - 27 Lee HJ, Yeon JE, Suh SJ, Lee SJ, Yoon EL, Kang K, Yoo YJ, Kim JH, Seo YS, Yim HJ, Byun KS. Clinical Utility of Plasma Glypican-3 and Osteopontin as Biomarkers of Hepatocellular Carcinoma. *Gut and Liver* 2014; **8(2)**: 177-185.
 - 28 Abdelgawad IA, Mossallam GI, Radwan NH, Elzawahry HM, El-hifnawy NM. Can Glypican3 be Diagnostic for Early Hepatocellular Carcinoma among Egyptian Patients? *APJCP* 2013; **14(12)**: 7345-7349.
 - 29 El-Shenawy S, El Sabawi S, Sheble N *et al* Diagnostic Role of Serum Glypican -3 as a tumor Marker for Hepatocellular Carcinoma. *Nature and Science* 2012; **10(4)**: 32-38.
 - 30 Bruix J, Sherman M. Management of hepatocellular carcinoma. An update. *Hepatology* 2011; **53(3)**: 1020-1022.
 - 31 El-Serag HB, Marrero JA, Rudolph L, Reddy KR. Diagnosis and treatment of hepatocellular carcinoma. *Gastroenterology* 2008; **134**: 1752-1763.
 - 32 França AVC, Junior JE, Lima BLG *et al* Diagnosis, staging and treatment of hepatocellular carcinoma. *Braz J Med Biol Res* 2004; **37(11)**: 1689-1705.
 - 33 Huo TI, Huang YH, Lui WY, Wu JC, Lee PC, Chang FY, Lee SD. Selective prognostic impact of serum α -fetoprotein level in patients with hepatocellular carcinoma: analysis of 543 patients in a single center. *Oncology Reports* 2004; **11**: 543-550.
 - 34 Atta M, EL Masry S, Abdel Hameed M, Baiomy HA, Ramadan NE. Value of serum anti-p53 antibodies as a prognostic factor in Egyptian patients with hepatocellular carcinoma. *Clinical Biochemistry* 2008; **41**: 1131-1139.
 - 35 Craig JR. Tumours of the liver. In: *Hepatology: a textbook of liver disease*. Zakim, D. and Boyer, T.D. (eds), 4th edition 2003, Saunders, Philadelphia, London, New York, St. Louis, Sydney, Toronto, p: 1355-1370.
 - 36 Wong LL, Kim CJ, Kwee SA, Hernandez BY. Alpha-fetoprotein testing for hepatocellular carcinoma may not be helpful in non-alcoholic steatohepatitis. *Open Journal of Gastroenterology* 2013; **3**: 49-54.
 - 37 El-Zayadi AR, Badran HM, Shawky S, Emara S, El-Bareedy A, Sobhi M. Effect of surveillance for hepatocellular carcinoma on tumor staging and treatment decisions in Egyptian patients. *Hepatol Int* 2010; **4(2)**: 500-506.
 - 38 Kim SH, Park JW, Jang JS, Kim HJ, Shin WG, Kim KH, Lee JH, Kim HY, Jang MK. Prognostic values of α -fetoprotein and protein induced by vitamin K absence or antagonist-II in hepatitis B virus-related hepatocellular carcinoma. A prospective study. *J Clin Gastroenterol* 2009; **43**: 482-488.
 - 39 Tandon P, Garcia-Tsao G. Prognostic indicators in hepatocellular carcinoma: a systematic review of 72 studies. *Liver Int* 2009; **29**: 502-510.
 - 40 Toso C, Asthana S, Bigam DL, Shapiro JAM, Kneteman N. Reassessing selection criteria prior to liver transplantation for hepatocellular carcinoma utilizing the scientific registry of transplant recipient's database. *Hepatology* 2009; **49**: 832-838.
 - 41 Shang S, Plymoth A, Ge S, Feng Z, Rosen HR, Sangrajang S, Hainaut P, Marrero JA, Beretta L. Identification of osteopontin as a novel marker for early hepatocellular carcinoma. *Hepatology* 2012; **55**: 483-490.
 - 42 El-Din Bessa SS, Elwan NM, Suliman GA. Clinical significance of plasma osteopontin level in Egyptian patients with hepatitis C virus-related hepatocellular carcinoma SH. Clinical significance

- of plasma osteopontin level in Egyptian patients with hepatitis C virus-related hepatocellular carcinoma. *Arch Med Res* 2010; **41**(7): 541-547.
- 43 Zhang H, Ren N, Ye QH, Sun HC, Wang L, Liu YK, Tang ZY, Qin LX. The prognostic significance of preoperative plasma levels of osteopontin in patients with hepatocellular carcinoma. *J Cancer Res Clin Oncol* 2006; **132**(11): 709-717.
- 44 Hua Z, Chen J, Sun B, Zhao G, Zhang Y, Fong Y, Jia Z, Yao L. Specific expression of osteopontin and S100A6 in hepatocellular carcinoma. *Surgery* 2011; **149**: 783-791.
- 45 Chen R, Xia Y, Cui J, Xue TC, Ye SL. Osteopontin, a single marker for predicting the prognosis of patients with tumor-node-metastasis stage I hepatocellular carcinoma after surgical resection. *Journal of Gastroenterology and Hepatology* 2010; **25**: 1435-1442.

Peer reviewer: Mohamed Hassany, Hepatology and Gastroenterology Consultant, National Hepatology and Tropical Medicine Research Institute (NHTMRI), 10 Kasr Al-Aini St., Cairo, Egypt.