

Repeated Minocycline Hydrochloride Injections for Symptomatic Polycystic Liver Disease

Hiroshi Yoshida, Hiroshi Makino, Tadashi Yokoyama, Hiroshi Maruyama, Atsushi Hirakata, Junji Ueda, Toshimitsu Miyasaka, Yasuhiro Mamada, Nobuhiko Taniyai, Eiji Uchida

Hiroshi Yoshida, Hiroshi Makino, Tadashi Yokoyama, Hiroshi Maruyama, Atsushi Hirakata, Junji Ueda, Toshimitsu Miyasaka, Department of Surgery, Nippon Medical School Tama Nagayama Hospital, Tokyo, Japan

Yasuhiro Mamada, Nobuhiko Taniyai, Eiji Uchida, Department of Gastrointestinal Surgery, Nippon Medical School, Tokyo, Japan

Correspondence to: Hiroshi Yoshida, MD, Department of Surgery, Nippon Medical School Tama Nagayama Hospital, 1-7-1 Nagayama, Tama-city, Tokyo 206-8512, Japan.

Email: hiroshiy@nms.ac.jp

Telephone: +81-42-371-2111

Fax: +81-42-372-7384

Received: March 24, 2016

Revised: April 28, 2016

Accepted: April 30, 2016

Published online: June 21, 2016

ABSTRACT

AIM: The present study evaluated the safety and effectiveness of repeated injections of minocycline hydrochloride (MINO) for symptomatic polycystic liver disease (PLD).

METHODS: We retrospectively studied patients who received percutaneous MINO injections for symptomatic PLD and were followed up for at least 2 years between 2002 and 2015. Huge hepatic cysts (diameter > 10 cm) were treated by continuous drainage and multiple MINO injections. Small hepatic cysts underwent one-step drainage followed by a single injection of MINO. Only several cysts that caused complications were treated by percutaneous injection of MINO. Patients were discharged 1 day after treatment.

RESULTS: Ten patients, (4men and 6 women; mean age, 57.8 years) were studied. All patients had Type 2 PLD according to Gigot's classification. The chief complaints were abdominal distension ($n = 10$), abdominal pain ($n = 6$), back pain ($n = 4$), and appetite loss ($n = 8$). Four patients had mild liver dysfunction. One

patient complained of moderate right subscapular pain immediately after the injection, and another had pain at the site of catheter insertion. Liver dysfunction did not develop in any patient after treatment. The mean follow-up was 63.4 months. The interval from the first to last admission for MINO injection therapy was 14 to 148 months (mean, 40.8 months). The number of admissions for MINO injection therapy ranged from 2 to 12 times (mean, 4.0 times). The average interval for MINO injection therapy was 8.3 to 19 months (mean, 14.8 months). The hepatic cysts shrank in all patients after treatment. Complications improved consistently, and all patients were satisfied with the outcome of treatment.

CONCLUSIONS: Symptomatic PLD was controllable by 14.8 months of repeated MINO injections on average. Repeated MINO injections are a safe, definitive treatment for symptomatic PLD.

Key words: Minocycline hydrochloride; Polycystic liver disease

© 2016 The Authors. Published by ACT Publishing Group Ltd.

Yoshida H, Makino H, Yokoyama T, Maruyama H, Hirakata A, Ueda J, Miyasaka T, Mamada Y, Taniyai N, Uchida E. Repeated Minocycline Hydrochloride Injections for Symptomatic Polycystic Liver Disease. *Journal of Gastroenterology and Hepatology Research* 2016; 5(3): 2063-2069 Available from: URL: <http://www.ghrnet.org/index.php/joghr/article/view/1747>

INTRODUCTION

Polycystic liver disease (PLD) is a rare genetic disorder. Typically, disconnected biliary structures are present in very-early-stage disease^[1]. Because the hepatic cyst epithelium shows the immunohistochemical, structural, and functional features of cholangiocytes, a hepatic cyst can be described as a fluid-filled cavity lined with cholangiocytes^[2-5]. Most patients with PLD remain asymptomatic, but 2% to 5% of patients will have symptomatic hepatomegaly caused by a continuous increase in the volumes

and numbers of hepatic cysts^[6-8]. Documented complications of nonparasitic hepatic cysts include obstructive jaundice^[9,10], rupture^[11-13], intracystic hemorrhage^[13-16], and infection^[17-19]. In PLD, the polycystic liver annually grows by 0.9% to 3.2%^[20-24]. As polycystic livers grow up to 10 times their normal size, they compress adjacent abdominal and thoracic organs. Symptoms typically caused by massive enlargement of the liver include abdominal distension, abdominal pain, back pain, and appetite loss, which will induce severe malnutrition in some patients. Liver dysfunction, portal hypertension, ascites, or Budd-Chiari Syndrome will develop in some of these patients^[20,25].

A number of treatments for symptomatic hepatic cyst have been developed^[26-47]. We have previously shown that minocycline hydrochloride (MINO) effectively promotes the regression of symptomatic simple hepatic cyst acutely^[26,27]. In symptomatic PLD, radical treatment is difficult, with the exception of liver transplantation. We therefore inject MINO into only several cysts that cause complications. MINO injection is then repeated when complications recur.

In the present study, we evaluated the safety and effectiveness of repeated injections of MINO in patients with symptomatic PLD.

METHODS

We obtained approval from our hospital ethics committee to perform a study evaluating the safety and effectiveness of MINO injections for the treatment of symptomatic PLD. Informed consent was obtained from the patients or their guardians before treatment.

We retrospectively reviewed the database on patients who received percutaneous MINO injection in our department from January 2002 through September 2015. All patients were referred from other hospitals because of symptomatic PLD. Patients included in this study had to have received percutaneous MINO injection for symptomatic PLD with clinical, biological, and imaging follow-up for at least 2 years. Hemorrhagic or infected cysts were excluded from this study. Exclusion criteria were contraindications to percutaneous treatment (a platelet count less than 50,000/mm³) and the concomitant presence of hepatobiliary malignancy, hemorrhagic cyst, or infected cyst. Percutaneous fluid sampling was performed as required for cytological and chemical analysis.

Imaging analysis

The diagnosis of PLD was based on ultrasonography (US), computed tomography (CT), or magnetic resonance imaging (MRI) without or with intravenous contrast material, and follow-up studies were performed using US, CT, or MRI. A travel history was also obtained, especially concerning areas where echinococcosis is endemic. All patients were considered to have PLD. We interviewed the patients regarding potential complications and performed imaging studies to detect cysts responsible for complications.

Gigot's classification

PLD was classified into three types according to Gigot's classification on the basis of the number, size, and location of cysts within the liver^[46]. Type 1 (mild form) included patients with a limited number (< 10) of large (> 10 cm) cysts. Type 2 (moderate form) included patients with diffuse involvement of the liver parenchyma by multiple medium-sized cysts, with remaining large areas of non cystic liver parenchyma. Type 3 (severe form) included patients with massive, diffuse involvement of the liver parenchyma by small and medium-sized hepatic cysts, with small areas of liver parenchyma between

cysts.

Percutaneous MINO injection protocol

Large hepatic cysts (diameter > 10 cm) were treated by continuous drainage and multiple MINO injections. Smaller hepatic cysts were treated by one-step drainage and a single injection of MINO. Percutaneous MINO injections were used to treat only cysts that caused complications.

Before treatment, all patients were informed of the details of the procedure. Following premedication with an intravenous injection of pentazocine (15 mg), hydroxyzine (25 mg), and/or diazepam (5 mg), MINO (Lederle, Ltd., Tokyo, Japan) was injected under local anesthesia.

Multiple MINO injection therapy: In patients who underwent continuous drainage, the target cyst was punctured with a needle, and an 8-Fr pigtail catheter (Ultrasonic Guided One-step Drainage Set type S, Hakko Shoji, Co., Ltd., Tokyo, Japan) was inserted under US guidance. The cyst fluid was then aspirated from the intraluminal needle under fluoroscopic control. After approximately 50 mL of fluid was removed for cytological examination and chemical analysis, contrast medium was injected. The needle was then removed, and the pigtail catheter was inserted into the cyst without the use of a guide wire. After catheter insertion, another 50 mL of contrast medium was injected into the cyst to confirm the absence of leakage into the peritoneal cavity. After complete aspiration of the cyst fluid, 200 mg of MINO dissolved in 5 mL of saline was injected, and the catheter was flushed with 5 mL of saline, for a total of 10 mL of saline. The catheter was then clamped for 30 min. Improvement was checked by palpating the patient's distended abdominal region. MINO was injected daily for 7 to 8 days, and the catheter was removed. After clinical checks, patients were discharged 1 day after treatment.

Single MINO injection therapy: In patients who underwent one-step drainage, only several cysts that caused complications were punctured with an 18-gauge needle under US guidance. The cyst fluid was aspirated for cytologic examination and chemical analysis. After complete aspiration of the cyst fluid, 1 or 2 mL of MINO (200 mg dissolved in 5 mL of saline) was injected into each cyst without resumption. Improvement was checked by palpating the distended abdominal region. After clinical checks, patients were discharged 1 day after treatment (2 days' admission).

The effectiveness of treatment was evaluated on the basis of the patient's complications and laboratory test results 1 month after treatment.

RESULTS

Ten patients (4 men and 6 women; mean age, 57.8 years; range, 35 to 71) who received percutaneous MINO injection for symptomatic PLD were studied. The baseline characteristics of the patients are presented in Table 1. All patients had Type 2 PLD according to Gigot's classification. PLD was associated with autosomal dominant polycystic kidney disease in 5 patients (50%). No patient had underlying cirrhosis. The results of all cytologic examinations and cultures were negative.

The chief complaint was abdominal distension in all patients. Other symptoms included abdominal pain ($n = 6.60\%$), back pain ($n = 4.40\%$), and appetite loss ($n = 8.80\%$). On initial laboratory tests, including assessment of liver function, 4 patients (40%) had mild liver dysfunction with slightly elevated levels of serum aspartate transaminase (AST), aspartate aminotransferase (ALT), and gamma-glutamyl transpeptidase (γ -GTP). No patient had a hemorrhagic

diathesis, fever, or signs of infection. One patient had received ethanol injection therapy 10 months previously, and another had received transarterial embolization 8 months previously for the treatment of PLD in other hospitals.

One patient complained of moderate right subscapular pain immediately after the injection, and another had pain at the site of catheter insertion. Pain was controlled with non-steroidal anti-inflammatory suppositories in both cases. No patient had liver dysfunction after treatment. Serum AST, ALT, and γ -GTP levels decreased after treatment in all 4 patients who had liver dysfunction before treatment.

Follow-up ranged from 26 to 157 months (mean, 63.4 months). The interval from the first to the last admission for MINO injection therapy was 14 to 148 months (mean, 40.8 months). The number of admissions for MINO injection therapy ranged from 2 to 12 times (mean, 4.0 times). The average interval for MINO injection therapy was 8.3 to 19 months (mean, 14.8 months). Multiple and single MINO injection therapy was given an average of 0.5 times and 3.5 times, respectively.

The size of the hepatic cysts decreased in all patients after treatment. Complications improved consistently, and all patients were satisfied with the outcome of treatment (Table 2).

Case 1 (Figures 1 and 2)

A 43-year-old woman with PLD was admitted with abdominal distension, abdominal pain, back pain, appetite loss, and liver dysfunction. She had received ethanol injection therapy 10 months previously in another hospital. First, multiple MINO injection therapy was performed 3 times. Single MINO injection therapy was then performed a total of 9 times when the patient complained of abdominal distension. The follow-up time was 157 months. The interval from the first to last admission was 148 months. MINO injection therapy was performed 12 times. The interval of MINO injection therapy was 13.5 months. The interval of multiple and single MINO injection therapy was 16.0 months and 12.5 months, respectively. Abdominal distension improved with no recurrence during the past 9 months.

Table 1. Baseline characteristics

Case	Age	Sex	Gigot's classification	Polycystic kidney	complications					Complications after treatment	Past treatment
					Abdominal pain	Abdominal distension	Back pain	Appetite loss	Liver dysfunction		
1	43	F	Type 2	+	+	+	+	+	+		Ethanol injection therapy
2	35	F	Type 2	-	+	+	-	+	-	Moderate right subscapular pain	
3	60	F	Type 2	+	+	+	+	+	-		Transarterial embolization
4	71	F	Type 2	+	-	+	-	-	+	Pain at the site of catheter insertion	
5	70	M	Type 2	-	+	+	+	+	-		
6	52	M	Type 2	+	-	+	-	+	+		
7	56	M	Type 2	-	-	+	-	+	-		
8	61	M	Type 2	-	-	+	-	-	-		
9	65	F	Type 2	+	+	+	-	+	+		
10	65	F	Type 2	-	+	+	+	+	-		
Ave	57.8										
SD	11.6										

Liver dysfunction: elevation of serum AST, ALT, or γ GTP levels

Table 2. Clinical data

Case	Follow-up time (months)	Interval from first to last admission (months)	Number of admissions	Average interval of admission (months)	Times of multiple MINO injection	Times of single MINO injection
1	157	148	12	13.5	3	9
2	108	108	9	13.5	0	9
3	26	25	4	8.3	0	4
4	135	28	3	14.0	1	2
5	39	18	2	18.0	0	2
6	36	15	2	15.0	1	1
7	34	15	2	15.0	0	2
8	34	14	2	14.0	0	2
9	33	19	2	19.0	0	2
10	32	18	2	18.0	0	2
Mean	63.4	40.8	4.0	14.8	0.5	3.5
SD	49.7	47.1	3.6	3.1	1.0	3.0

DISCUSSION

We repeatedly injected MINO to treat symptomatic PLD. Symptomatic PLD was controlled by repeated MINO injections given over the course of 14.8 months on average.

PLD is a collection of rare human disorders that result from structural changes in biliary tree development^[48-50]. The biliary tree emerges from the endodermal hepatic diverticulum^[48]. Development of the biliary system starts from the 8th week of gestation by formation of a single layer of hepatoblasts around the portal vein (ductal plate). The ductal plate is the anatomical template for the development of the intrahepatic bile ducts. The PLD results from a ductal-plate malformation during embryonic liver development^[51]. In PLD, complexes of disconnected intralobular bile ductules are retained, which explains the non communicating nature of the cysts in PLD. The multiple cysts then arise from progressive dilatation of these abnormal ductules from biliary hamartoma (von Meyenburg complexes)^[52-54].

PLD shows two main clinical presentations: (1) PLD associated with autosomal dominant polycystic kidney disease; and (2) isolated PLD. Both of these forms of PLD have an autosomal dominant pattern of inheritance^[55].

There are various treatments for symptomatic hepatic cysts, such as cyst aspiration sclerotherapy^[26,27,30,35-45], cyst fenestration (deroofting)^[28,46], liver resection^[32-34,47], hepatic arterial embolization^[29], and transplantation^[31]. These treatments do not alter the natural course of the disease.

Surgery has been the traditional treatment for symptomatic hepatic cysts, but is quite invasive and has a relatively high incidence of complications^[32-34,40]. The recurrence rate after liver resection has been reported to be 3% to 33%^[56-58]. In Japan, postoperative complications of liver resection include ascites, bile leakage, and intra abdominal abscess, with an incidence of 31.8%^[59]. Cyst fenestration, i.e., surgical de roofing of a cyst, is a minimally invasive surgical treatment, but the recurrence rate has been reported to range from 20% to 72%, with large differences among previous studies^[60-63]. The most commonly reported postoperative complication is ascites, with are latively high incidence of 33% to 69%. Liver transplantation is the only radical treatment option for PLD, but carries high risks of postoperative morbidity and mortality^[23,56,64].

Among nonsurgical treatments, a 100% recurrence rate has been reported after cyst aspiration alone; an alternative method of treatment is thus required^[65]. The instillation of various sclerosing agents has been used to obliterate symptomatic congenital hepatic cysts^[26,27,30,35-45]. Aspiration sclerotherapy involves cyst aspiration followed by the injection of a sclerosing agent, which destroys

the epithelial cells lining the cyst cavity. However, aspiration sclerotherapy for PLD was reported to be impractical because of its high recurrence rate, ranging from 50% to 78%^[36,59]. The most commonly used sclerosing agent is ethanol or MINO. Ethanol injection therapy for the treatment of hepatic cysts has been associated with pain, hyperthermia, hypotension, and intoxication^[35,37,44].

MINO is the antibiotic most widely used to treat cysts. A low concentration of MINO (1 to 2 mg/mL) is usually injected

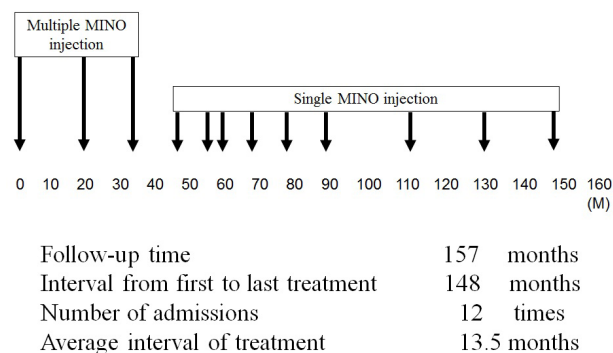


Figure 1 Medical history of Case 1. MINO: minocycline hydrochloride.

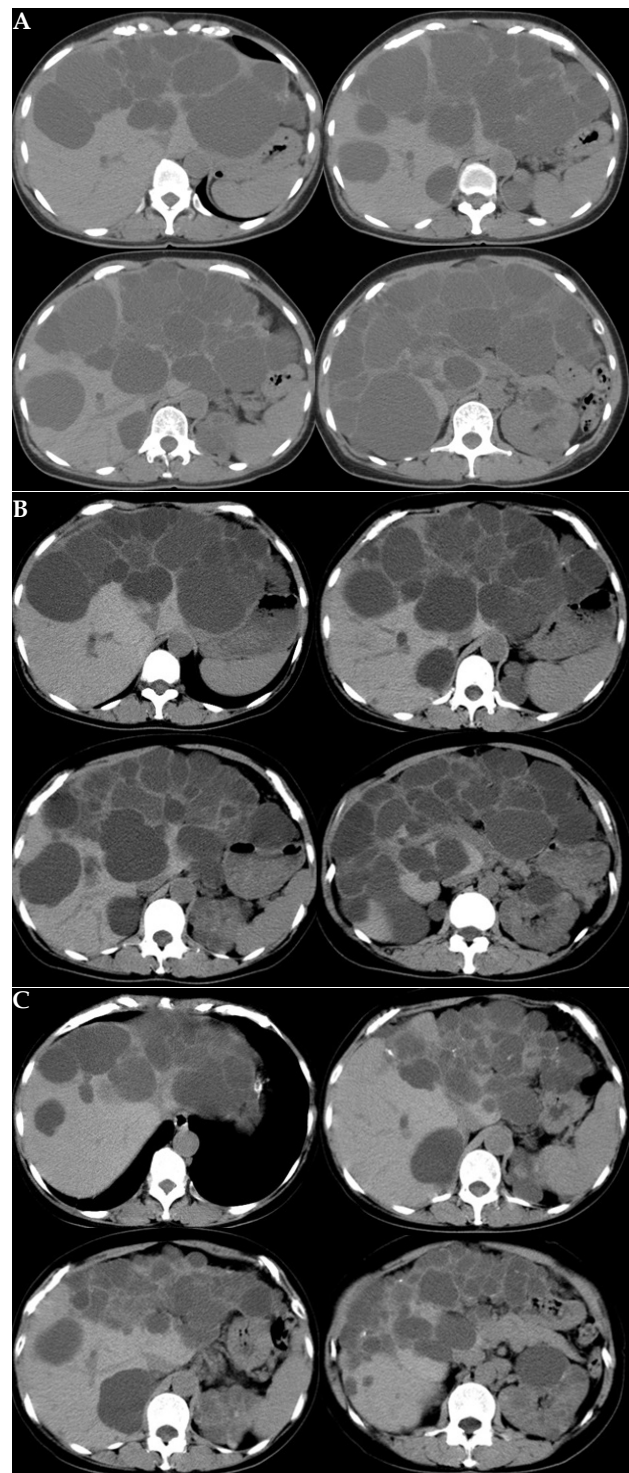


Figure 2 Computed tomography (A) before treatment; (B) 72 months after first treatments; and (C) 150 months after first treatments.

intravenously. MINO injection has been used to treat renal cysts^[66-68], splenic cysts^[69], thyroid cysts^[70], and hepatic cysts^[26,27,38,41-43]. MINO 100 mg/mL was injected to treat thyroid cysts^[70], and MINO 10 mg/mL^[66] was instilled into renal cysts. Concentrations of MINO that have been used to manage hepatic cysts range from 5 to 50 mg/mL^[26,27,38,41-43].

The efficacy of MINO injection is related to the extremely low pH of the tetracycline in solution, which destroys the mesothelial cells secreting the effusion, leading to involution of the cyst. Furthermore, Rubinson *et al.*^[71] have suggested that the antibiotic effect of tetracycline provides some protection against infection after instillation.

In MINO injection therapy, pain occurs when MINO leaks into the abdominal cavity. Burette *et al.*^[72] reported that MINO had hepatotoxic effects in one patient. Unlike the usual histologic features of tetracycline-induced hepatic injury, fatty metamorphosis was predominantly macrovesicular. The patient recovered after drug therapy was discontinued. Close monitoring of liver function is recommended in patients who receive high-dose parenteral MINO, particularly if they are pregnant or have renal disease. MINO injection is contraindicated in patients who have a hemorrhagic diathesis, echinococcal cyst, protrusion of the hepatic vein into the cyst, communication with the biliary tree, or extravasation into the peritoneal cavity. The side effects in our study included moderate right sub scapular pain immediately after the injection of MINO in one patient and pain at the catheter insertion site in another patient. Pain was controllable with non-steroidal anti-inflammatory suppositories in both patients. In our series, serum AST, ALT, and γ -GTP levels decreased after treatment in all patients who had liver dysfunction before treatment.

There are two methods for treating hepatic cysts by MINO injection: multiple injection therapy^[26,27,41] and single injection therapy^[38,42,43]. In our series, continuous drainage and multiple MINO injections were performed in patients with huge hepatic cysts measuring > 10 cm in diameter. We previously reported that multiple MINO injection therapy was effective with no recurrence when used to treat huge symptomatic solitary hepatic cysts^[27]. After multiple MINO injections, complications improved because huge cysts decreased in size. However, it was difficult to control complications caused by small hepatic cysts in PLD. The goals of treatment for PLD are to alleviate abdominal symptoms and prevent their recurrence by decreasing liver volume^[5]. Symptom recurrence is caused by the growth of new cysts or the re growth of treated cysts. We therefore treated only several cysts that caused complications and repeated treatment on the recurrence of complications. In case 1, the interval of multiple and single MINO injection therapy was 16.0 months and 12.5 months, respectively. In single MINO injection therapy, only a few days of hospitalization are required for treatment per year.

The Gigot classification of PLD is based on the number, size, and location of cysts within the liver. It reflects disease severity and is useful when choosing treatment options. Recently, several reports on PLD treatment have recommended aspiration sclerotherapy, cyst fenestration, and liver resection for Gigot type 1 or 2 PLD and liver transplantation for type 3 PLD; however, no standardized criteria for the selection of treatment exist^[5,23,35,46,59,64,65,73-75]. In our series, all patients had Gigot type 2 PLD.

In our series, the duration of hospitalization for MINO injection therapy ranged from 8.3 to 19 months (mean, 14.8 months). The hepatic cysts shrank after treatment in all patients. PLD-related complications improved consistently, and all patients were satisfied with the treatment response. Symptomatic PLD could thus be

controlled by 14.8 months of MINO injection therapy on average. The effectiveness of the treatments continued beyond 1 year. Because liver transplantation is the only radical treatment option for all cysts in PLD, the duration of treatment effect in our study is considered satisfactory.

In conclusion, symptomatic PLD was controllable by 14.8 months of repeated MINO injections on average. Repeated MINO injection is a safe, definitive treatment for symptomatic PLD.

CONFLICT OF INTERESTS

There are no conflicts of interest with regard to the present study.

REFERENCES

- Drenth JP, Chrispijn M, Bergmann C. Congenital fibrocystic liver diseases. *Best Pract Res Clin Gastroenterol.* 2010; **24**(5): 573-584.
- Everson GT, Emmett M, Brown WR, Redmond P, Thickman D. Functional similarities of hepatic cystic and biliary epithelium: studies of fluid constituents and in vivo secretion in response to secretin. *Hepatology.* 1990; **11**(4): 557-565.
- Perrone RD, Grubman SA, Rogers LC, Lee DW, Moy E, Murray SL, Torres VE, Jefferson DM. Continuous epithelial cell lines from ADPKD liver cysts exhibit characteristics of intrahepatic biliary epithelium. *Am J Physiol.* 1995; **269**(3 Pt 1): G335-345.
- Perrone RD, Grubman SA, Murray SL, Lee DW, Alper SL, Jefferson DM. Autosomal dominant polycystic kidney disease decreases anion exchanger activity. *Am J Physiol.* 1997; **272**(5 Pt 1): C1748-1756.
- Temmerman F, Missiaen L, Bammens B, Laleman W, Cassiman D, Verslype C, van Pelt J, Nevens F. Systematic review: the pathophysiology and management of polycystic liver disease. *Aliment Pharmacol Ther.* 2011; **34**(7): 702-713.
- Harris RA, Gray DW, Britton BJ, Toogood GJ, Morris PJ. Hepatic cystic disease in an adult polycystic kidney disease transplant population. *Aust N Z J Surg.* 1996; **66**(3): 166-168.
- Sherstha R, McKinley C, Russ P, Scherzinger A, Bronner T, Showalter R, Everson GT. Postmenopausal estrogen therapy selectively stimulates hepatic enlargement in women with autosomal dominant polycystic kidney disease. *Hepatology.* 1997; **26**(5): 1282-1286.
- Temmerman F, Dobbels F, Ho TA, Pirson Y, Vanslembrouck R, Coudyzer W, Bammens B, van Pelt J, Pirenne J, Nevens F. Development and validation of a polycystic liver disease complaint-specific assessment (POLCA). *J Hepatol.* 2014; **61**(5): 1143-1150.
- Schwed DA, Edoga JK, Stein LB. Biliary obstruction due to spontaneous hemorrhage into benign hepatic cyst. *J Clin Gastroenterol.* 1993; **16**(1): 84-86.
- Kaneya Y, Yoshida H, Matsutani T, Hirakata A, Matsushita A, Suzuki S, Yokoyama T, Maruyama H, Sasajima K, Uchida E. Biliary obstruction due to a huge simple hepatic cyst treated with laparoscopic resection. *J Nippon Med Sch.* 2011; **78**(2): 105-109.
- Andersson R, Tranberg KG, Bengmark S. Hemoperitoneum after spontaneous rupture of liver tumor: results of surgical treatment. *HPB Surg.* 1988; **1**(1): 81-83.
- Ueda J, Yoshida H, Taniai N, Mineta S, Kawano Y, Uchida E. A case of spontaneous rupture of a simple hepatic cyst. *J Nippon Med Sch.* 2010; **77**(3): 181-185.
- Yamaguchi M, Kuzume M, Matsumoto T, Matsumiya A, Nakano H, Kumada K. Spontaneous rupture of a nonparasitic liver cyst complicated by intracystic hemorrhage. *J Gastroenterol.* 1999; **34**(5): 645-648.
- Yoshida H, Onda M, Tajiri T, Mamada Y, Taniai N, Uchida E, Arima Y, Akimaru K, Yamashita K. Intracystic hemorrhage of a simple hepatic cyst. *Hepatogastroenterology.* 2002; **49**(46): 1095-1097.
- Takahashi G, Yoshida H, Mamada Y, Taniai N, Bando K, Tajiri T.

- Intracystic hemorrhage of a large simple hepatic cyst. *J Nippon Med Sch.* 2008; **75**(5): 302-305.
- 16 Kawano Y, Yoshida H, Mamada Y, Taniai N, Mineta S, Yoshioka M, Mizuguchi Y, Katsuta Y, Kawamoto C, Uchida E. Intracystic hemorrhage required no treatment from one of multiple hepatic cysts. *J Nippon Med Sch.* 2011; **78**(5): 312-316.
 - 17 Yoshida H, Onda M, Tajiri T, Mamada Y, Taniai N, Mineta S, Hirakata A, Futami R, Arima Y, Inoue M, Hatta S, Kishimoto A. Infected hepatic cyst. *Hepatogastroenterology.* 2003; **50**(50): 507-509.
 - 18 Yoshida H, Tajiri T, Mamada Y, Taniai N, Kawano Y, Mizuguchi Y, Shimizu T, Takahashi T, Uchida E, Watanabe M, Uchida E. Infected solitary hepatic cyst. *J Nippon Med Sch.* 2003; **70**(6): 515-518.
 - 19 Ishii K, Yoshida H, Taniai N, Moneta S, Kawano Y, Tajiri T. Infected hepatic cyst treated with percutaneous transhepatic drainage. *J Nippon Med Sch.* 2009; **76**(3): 160-164.
 - 20 van Keimpema L, Nevens F, Vanslebrouck R, van Oijen MG, Hoffmann AL, Dekker HM, de Man RA, Drenth JP. Lanreotide reduces the volume of polycystic liver: a randomized, double-blind, placebo-controlled trial. *Gastroenterology.* 2009; **137**(5): 1661-8. e1-2.
 - 21 Hogan MC, Masyuk TV, Page LJ, Kubly VJ, Bergstralh EJ, Li X, Kim B, King BF, Glockner J, Holmes DR 3rd, Rossetti S, Harris PC, LaRusso NF, Torres VE. Randomized clinical trial of long-acting somatostatin for autosomal dominant polycystic kidney and liver disease. *J Am Soc Nephrol.* 2010; **21**(6): 1052-1061.
 - 22 Caroli A, Antiga L, Cafaro M, Fasolini G, Remuzzi A, Remuzzi G, Ruggenenti P. Reducing polycystic liver volume in ADPKD: effects of somatostatin analogue octreotide. *Clin J Am Soc Nephrol.* 2010; **5**(5): 783-9.
 - 23 Drenth JP, Chrispijn M, Nagorney DM, Kamath PS, Torres VE. Medical and surgical treatment options for polycystic liver disease. *Hepatology.* 2010; **52**(6): 2223-2230.
 - 24 Grantham JJ, Chapman AB, Torres VE. Volume progression in autosomal dominant polycystic kidney disease: the major factor determining clinical outcomes. *Clin J Am Soc Nephrol.* 2006; **1**(1): 148-157.
 - 25 van Keimpema L, Höckerstedt K. Treatment of polycystic liver disease. *Br J Surg.* 2009; **96**(12): 1379-1380.
 - 26 Yoshida H, Egami K, Onda M, Tajiri T, Uchida E. Treatment of symptomatic hepatic cyst by injection of minocycline hydrochloride. *J Hepatobiliary Pancreat Surg.* 1996; **3**(4): 491-494.
 - 27 Yoshida H, Onda M, Tajiri T, Arima Y, Mamada Y, Taniai N, Akimaru K. Long-term results of multiple minocycline hydrochloride injections for the treatment of symptomatic solitary hepatic cyst. *J Gastroenterol Hepatol.* 2003; **18**(5): 595-598.
 - 28 Palanivelu C, Rangarajan M, Senthilkumar R, Madankumar MV. Laparoscopic management of symptomatic multiple hepatic cysts: a combination of deroofing and radical excision. *JSLS.* 2007; **11**(4): 466-469.
 - 29 Wang MQ, Duan F, Liu FY, Wang ZJ, Song P. Treatment of symptomatic polycystic liver disease: transcatheter super-selective hepatic arterial embolization using a mixture of NBCA and iodized oil. *Abdom Imaging.* 2013; **38**(3): 465-473.
 - 30 Nakaoka R, Das K, Kudo M, Chung H, Innoue T. Percutaneous aspiration and ethanolamine oleate sclerotherapy for sustained resolution of symptomatic polycystic liver disease: an initial experience. *AJR Am J Roentgenol.* 2009; **193**(6): 1540-1545.
 - 31 Zamora-Valdés D, Contreras AG, Mercado MA. Liver transplantation for polycystic liver disease. *J Am Coll Surg.* 2014; **219**(6): 1192.
 - 32 Jones WL, Mountain JC, Warren KW. Symptomatic non-parasitic cysts of the liver. *Br J Surg.* 1974; **61**(2): 118-123.
 - 33 Diez J, Decoud J, Gutierrez L, Suhl A, Merello J. Laparoscopic treatment of symptomatic cysts of the liver. *Br J Surg.* 1998; **85**(1): 25-7.
 - 34 Klingler PJ, Gadenstatter M, Schmid T, Bodner E, Schwelberger HG. Treatment of hepatic cysts in the era of laparoscopic surgery. *Br J Surg.* 1997; **84**(4): 438-444.
 - 35 Bean WJ, Rodan BA. Hepatic cysts: treatment with alcohol. *AJR Am J Roentgenol.* 1985; **144**(2): 237-241.
 - 36 Erdogan D, van Delden OM, Rauws EA, Busch OR, Lameris JS, Gouma DJ, van Gulik TM. Results of percutaneous sclerotherapy and surgical treatment in patients with symptomatic simple liver cysts and polycystic liver disease. *World J Gastroenterol.* 2007; **13**(22): 3095-3100.
 - 37 Benzmira J, Ronot M, Fuks D, Abdel-Rehim M, Sibert A, Farges O, Vilgrain V. Hepatic cysts treated with percutaneous ethanol sclerotherapy: time to extend the indications to haemorrhagic cysts and polycystic liver disease. *Eur Radiol.* 2014; **24**(5): 1030-1038.
 - 38 Cellier C, Cuenod CA, Deslandes P, Auroux J, Landi B, Siauve N, Barbier JP, Fria G. Symptomatic hepatic cysts: treatment with single-shot injection of minocycline hydrochloride. *Radiology.* 1998; **206**(1): 205-209.
 - 39 Dumot JA, Fields MS, Meyer RA, Shay SS, Conwell DL, Brzezinski A. Alcohol sclerosis for polycystic liver disease and obstructive jaundice: use of a nasobiliary catheter. *Am J Gastroenterol.* 1994; **89**(9): 1555-1557.
 - 40 Goldstein HM, Carlyle DR, Nelson RS. Treatment of symptomatic hepatic cyst by percutaneous instillation of Pantopaque. *AJR Am J Roentgenol.* 1976; **127**(5): 850-853.
 - 41 Yoshihara K, Yamashiro S, Koizumi S, Matsuo Y, Shigeru J, Kanegae S, Oda Y. Obstructive jaundice caused by non-parasitic hepatic cyst treated with percutaneous drainage and instillation of minocycline hydrochloride as a sclerosing agent. *Intern Med.* 1996; **35**(5): 373-375.
 - 42 Yamada N, Shinzawa H, Ukai K, Makino N, Matsuhashi T, Wakabayashi H, Togashi H, Takahashi T. Treatment of symptomatic hepatic cysts by percutaneous instillation of minocycline hydrochloride. *Dig Dis Sci.* 1994; **39**(11): 2503-2509.
 - 43 Hagiwara H, Kasahara A, Hayashi N, Kono M, Suzuki K, Kashio S, Fusamoto H, Kamada T. Successful treatment of a hepatic cyst by one-shot instillation of minocycline chloride. *Gastroenterology.* 1992; **103**(2): 675-677.
 - 44 Okano A, Hajiro K, Takakuwa H, Nishio A. Alcohol sclerotherapy of hepatic cysts: its effect in relation to ethanol concentration. *Hepatology Res.* 2000; **17**(3): 179-184.
 - 45 ROSENBERG GV. Solitary non-parasitic cysts of liver. *Am J Surg.* 1956; **91**(3): 441-444.
 - 46 Gigot JF, Jadoul P, Que F, Van Beers BE, Etienne J, Horsmans Y, Collard A, Geubel A, Pringot J, Kestens PJ. Adult polycystic liver disease: is fenestration the most adequate operation for long-term management? *Ann Surg.* 1997; **225**(3): 286-294.
 - 47 Tseng J, Orloff SL. Management of Symptomatic Polycystic Liver Disease With Hepatic Resection. *JAMA Surg.* 2014.
 - 48 Roskams T, Desmet V. Embryology of extra- and intrahepatic bile ducts, the ductal plate. *Anat Rec (Hoboken).* 2008; **291**(6): 628-635.
 - 49 Raynaud P, Carpentier R, Antoniou A, Lemaigre FP. Biliary differentiation and bile duct morphogenesis in development and disease. *Int J Biochem Cell Biol.* 2011; **43**(2): 245-256.
 - 50 Cnossen WR, Drenth JP. Polycystic liver disease: an overview of pathogenesis, clinical manifestations and management. *Orphanet J Rare Dis.* 2014; **9**: 69.
 - 51 Desmet VJ. Ludwig symposium on biliary disorders--part I. Pathogenesis of ductal plate abnormalities. *Mayo Clin Proc.* 1998; **73**(1): 80-89.
 - 52 Ramos A, Torres VE, Holley KE, Offord KP, Rakela J, Ludwig J. The liver in autosomal dominant polycystic kidney disease. Implications for pathogenesis. *Arch Pathol Lab Med.* 1990; **114**(2): 180-184.
 - 53 Qian Q, Li A, King BF, Kamath PS, Lager DJ, Huston J, Shub C, Davila S, Somlo S, Torres VE. Clinical profile of autosomal domi-

- nant polycystic liver disease. *Hepatology*. 2003; **37**(1): 164-171.
- 54 Lazaridis KN, Strazzabosco M, Larusso NF. The cholangiopathies: disorders of biliary epithelia. *Gastroenterology*. 2004; **127**(5): 1565-1577.
- 55 Everson GT, Helmke SM, Doctor B. Advances in management of polycystic liver disease. *Expert Rev Gastroenterol Hepatol*. 2008; **2**(4): 563-576.
- 56 Schnellendorfer T, Torres VE, Zakaria S, Rosen CB, Nagorney DM. Polycystic liver disease: a critical appraisal of hepatic resection, cyst fenestration, and liver transplantation. *Ann Surg*. 2009; **250**(1): 112-118.
- 57 Vons C, Chauveau D, Martinod E, Smadja C, Capron F, Grunfeld JP, Franco D. Liver resection in patients with polycystic liver disease. *Gastroenterol Clin Biol*. 1998; **22**(1): 50-54.
- 58 Soravia C, Mentha G, Giostra E, Morel P, Rohner A. Surgery for adult polycystic liver disease. *Surgery*. 1995; **117**(3): 272-275.
- 59 Ogawa K, Fukunaga K, Takeuchi T, Kawagishi N, Ubara Y, Kudo M, Ohkohchi N. Current treatment status of polycystic liver disease in Japan. *Hepatol Res*. 2014; **44**(11): 1110-1118.
- 60 Martin IJ, McKinley AJ, Currie EJ, Holmes P, Garden OJ. Tailoring the management of nonparasitic liver cysts. *Ann Surg*. 1998; **228**(2): 167-172.
- 61 Koperna T, Vogl S, Satzinger U, Schulz F. Nonparasitic cysts of the liver: results and options of surgical treatment. *World J Surg*. 1997; **21**(8): 850-4; discussion 4-5.
- 62 Kabbej M, Sauvanet A, Chauveau D, Farges O, Belghiti J. Laparoscopic fenestration in polycystic liver disease. *Br J Surg*. 1996; **83**(12): 1697-1701.
- 63 Farges O, Bismuth H. Fenestration in the management of polycystic liver disease. *World J Surg*. 1995; **19**(1): 25-30.
- 64 Russell RT, Pinson CW. Surgical management of polycystic liver disease. *World J Gastroenterol*. 2007; **13**(38): 5052-5059.
- 65 Saini S, Mueller PR, Ferrucci JT, Simeone JF, Wittenberg J, Butch RJ. Percutaneous aspiration of hepatic cysts does not provide definitive therapy. *AJR Am J Roentgenol*. 1983; **141**(3): 559-560.
- 66 Uemasu J, Fujihara M, Munemura C, Nakamura E, Kawasaki H. Cyst sclerotherapy with minocycline hydrochloride in patients with autosomal dominant polycystic kidney disease. *Nephrol Dial Transplant*. 1996; **11**(5): 843-846.
- 67 Uemasu J, Fujiwara M, Munemura C, Tokumoto A, Kawasaki H. Effects of topical instillation of minocycline hydrochloride on cyst size and renal function in polycystic kidney disease. *Clin Nephrol*. 1993; **39**(3): 140-144.
- 68 Ohkawa M, Tokunaga S, Orito M, Shimamura M, Hirano S, Okasho A, Kosaka S. Percutaneous injection sclerotherapy with minocycline hydrochloride for simple renal cysts. *Int Urol Nephrol*. 1993; **25**(1): 37-43.
- 69 Shimanuki K, Satake M. Non-surgical treatment of splenic cyst, using with installation of minocycline chloride. *Fukushima J Med Sci*. 1996; **42**(1-2): 23-30.
- 70 Lee JK, Tai FT, Lin HD, Chou YH, Kaplan MM, Ching KN. Treatment of recurrent thyroid cysts by injection of tetracycline or minocycline. *Arch Intern Med*. 1989; **149**(3): 599-601.
- 71 Rubinson RM, Bolooki H. Intrapleural tetracycline for control of malignant pleural effusion: a preliminary report. *South Med J*. 1972; **65**(7): 847-849.
- 72 Burette A, Finet C, Prigogine T, De Roy G, Deltenre M. Acute hepatic injury associated with minocycline. *Arch Intern Med*. 1984; **144**(7): 1491-1492.
- 73 van Keimpema L, Nevens F, Adam R, Porte RJ, Fikatas P, Becker T, Kirkegaard P, Metselaar HJ, Drenth JP; European Liver and Intestine Transplant Association. Excellent survival after liver transplantation for isolated polycystic liver disease: an European Liver Transplant Registry study. *Transpl Int*. 2011; **24**(12): 1239-1245.
- 74 Mekeel KL, Moss AA, Reddy KS, Douglas DD, Vargas HE, Carey EJ, Byrne TJ, Harrison ME, Rakela J, Mulligan DC. Living donor liver transplantation in polycystic liver disease. *Liver Transpl*. 2008; **14**(5): 680-683.
- 75 Kirchner GI, Rifai K, Cantz T, Nashan B, Terkamp C, Becker T, Strassburg C, Barg-Hock H, Wagner S, Lück R, Klempnauer J, Manns MP. Outcome and quality of life in patients with polycystic liver disease after liver or combined liver-kidney transplantation. *Liver Transpl*. 2006; **12**(8): 1268-1277.

Peer reviewer: Yutao Zhan, MD, Associate Professor, Department of Gastroenterology and Hepatology, Beijing Tongren Hospital, Capital Medical University, NO.1 Dongjiao minxiang Dongcheng District, Beijing 100730, China.