

Perforated Jejunal Diverticulum Treated by Exteriorization in An Adult Patient with Alcoholic Psychosis: A Case Report

Yoshifumi Nakayama, Masaki Akiyama, Yusuke Sawatsubashi, Jun Nagata, Koichi Arase, Noritaka Minagawa, Takayuki Torigoe, Keiji Hirata

Yoshifumi Nakayama, Masaki Akiyama, Yusuke Sawatsubashi, Jun Nagata, Koichi Arase, Noritaka Minagawa, Takayuki Torigoe, Keiji Hirata, Department of Surgery 1, School of Medicine, University of Occupational and Environmental Health. 1-1 Iseigaoka, Yahata-nishi-ku, Kitakyushu 807-8555, Japan

Yoshifumi Nakayama, Masaki Akiyama, Yusuke Sawatsubashi, Jun Nagata, Department of Gastroenterological and General Surgery, Wakamatsu Hospital of University of Occupational and Environmental Health, 1-17-1 Hamamachi, Wakamatsu-ku, Kitakyushu 808-0024, Japan

Conflict-of-interest statement: The author(s) declare(s) that there is no conflict of interest regarding the publication of this paper.

Open-Access: This article is an open-access article which was selected by an in-house editor and fully peer-reviewed by external reviewers. It is distributed in accordance with the Creative Commons Attribution Non Commercial (CC BY-NC 4.0) license, which permits others to distribute, remix, adapt, build upon this work non-commercially, and license their derivative works on different terms, provided the original work is properly cited and the use is non-commercial. See: <http://creativecommons.org/licenses/by-nc/4.0/>

Correspondence to: Yoshifumi Nakayama, Department of Gastroenterological and General Surgery, Wakamatsu Hospital of University of Occupational and Environmental Health, Japan.

Email: nakayama@med.uoeh-u.ac.jp

Telephone: +81-93-761-0090

Fax: +81-93-588-3904

Received: June 15, 2016

Revised: December 8, 2016

Accepted: December 14, 2016

Published online: February 21, 2017

ABSTRACT

We herein describe a surgical case of perforated jejunal diverticulum in an adult patient with alcoholic psychosis and dementia. A 70-year-old Japanese male presented with vomiting and abdominal pain in a mental hospital. He had undergone a distal gastrectomy, the

details of which are unclear. He entered the internal medicine ward of our hospital and was diagnosed with bowel obstruction and conservatively treated with a long tube. At the 4th hospital day, he suffered from severe abdominal pain with muscular defense. Computed tomography revealed a dilated small intestine and intra-abdominal free air and ascites. After laparotomy, a perforated jejunal diverticulum was identified at 30 cm along the anal side from the ligament of Treitz. Adhesiolysis and exteriorization of the perforated jejunal diverticulum using a tube were performed, as the status of the patient was too serious to tolerate resection of the small intestine including the perforated lesion. The patient eventually recovered and left the hospital on Day 37 after the operation. This report presents a rare surgical case of perforated jejunal diverticulum due to small bowel obstruction in an adult patient with alcoholic psychosis and dementia.

Key words: Jejunal diverticulum; Perforation; Alcoholic psychosis

© 2017 The Author(s). Published by ACT Publishing Group Ltd. All rights reserved.

Nakayama Y, Akiyama M, Sawatsubashi Y, Nagata J, Arase K, Minagawa N, Torigoe T, Hirata K. Perforated Jejunal Diverticulum Treated by Exteriorization in An Adult Patient with Alcoholic Psychosis: A Case Report. *Journal of Gastroenterology and Hepatology Research* 2017; **6(1)**: 2296-2299 Available from: URL: <http://www.ghrnet.org/index.php/joghr/article/view/1757>

INTRODUCTION

Small intestinal diverticulum is rare, and the incidence ranges from 0.05% to 6.0%^[1]. These diverticula are most frequently seen in the proximal jejunum, and the prevalence in the proximal jejunum, distal jejunum, and ileum are 75%, 20% and 5% respectively^[2].

Small intestinal diverticulum, except for Meckel's diverticulum, are mostly acquired diverticulum. Pseudo-diverticulum is thought to arise due to outpouching of the mucosa and submucosa through the muscle coat at the point where the mesenteric vessels penetrate the intestinal wall. They occur commonly on the mesenteric side of the jejunum and are frequently seen in elderly males^[3].

Although jejunal diverticulum is usually asymptomatic, it may

cause abdominal pain, nausea, vomiting, and malabsorption. It may also lead to acute fetal complications, such as perforation, intestinal hemorrhage, and obstruction^[4].

We herein report a rare surgical case of perforated jejunal diverticulum due to small bowel obstruction in an adult patient with alcoholic psychosis and dementia.

CASE REPORT

A 70-year-old Japanese male presented with vomiting and abdominal pain in a mental hospital. He had previously undergone a distal gastrectomy, the details of which are unclear. He was transferred to our hospital for further examination and treatment of these symptoms. An abdominal X-ray examination revealed the apparently dilated loops of the small intestine (Figure 1a). Abdominal computed tomography (CT) also revealed the dilated small intestine, including the presence of gas and fluid (Figure 1b). He entered the internal medicine ward of our hospital, where he was diagnosed with bowel obstruction and conservatively treated with a long tube. At the 4th hospital day, he suffered from severe abdominal pain with muscular defense. CT revealed the dilated small intestine and intra-abdominal free air and ascites (Figure 2a, 2b). He was then introduced to our

surgical department, where he was diagnosed with perforation of the small intestine and panperitonitis.

A physical examination revealed abdominal distension with tenderness and muscular defense. A previous operation scar was identified on the upper middle abdomen. Laboratory investigations revealed a white blood cell count of 1,500/mm³ and a hemoglobin level of 11.6 g/dL with a hematocrit value of 34.6% and a platelet count of 247,000/mm³. His serum albumin level was 2.8 g/dL. The renal and liver function test results were all within the normal limits. His C-reactive protein level was 20.0 mg/dl. Coagulation studies revealed a prothrombin time of 13.9 seconds and an activated partial thromboplastin time of 28.3 seconds.

A laparotomy incision was created in the upper middle abdomen, and a 3-cm-diameter perforated jejunal diverticulum was identified. Approximately 1,000 mL of yellow brown muddy fluid was noted and drained (Figure 3, 4). The cause of the bowel obstruction was tight adhesion between the jejunum at 130 cm along the anal side from the ligament of Treitz and the scar from the previous operative incision. This diverticulum was located on the mesenteric side of the jejunum, located 30 cm along the anal side from the ligament of Treitz. Given that the wall of the perforated diverticulum lacked a muscular layer, this diverticulum was a pseudo-diverticulum of the

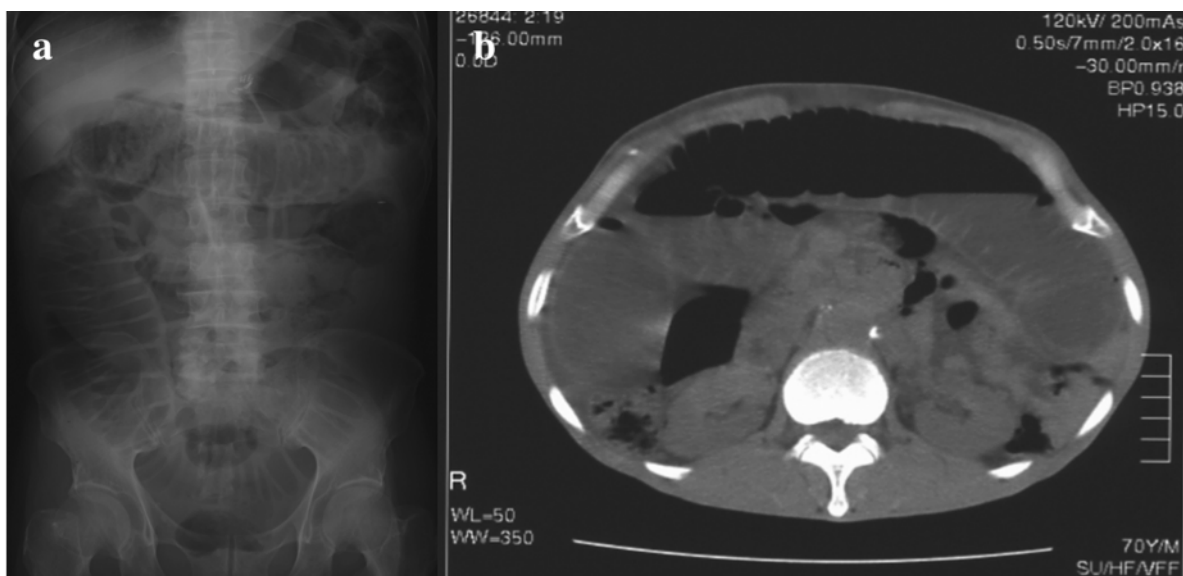


Figure 1 An abdominal X-ray examination revealed the apparently dilated loops of the small intestine. (a). Abdominal computed tomography (CT) also revealed the dilated small intestine including gas and fluid (b).

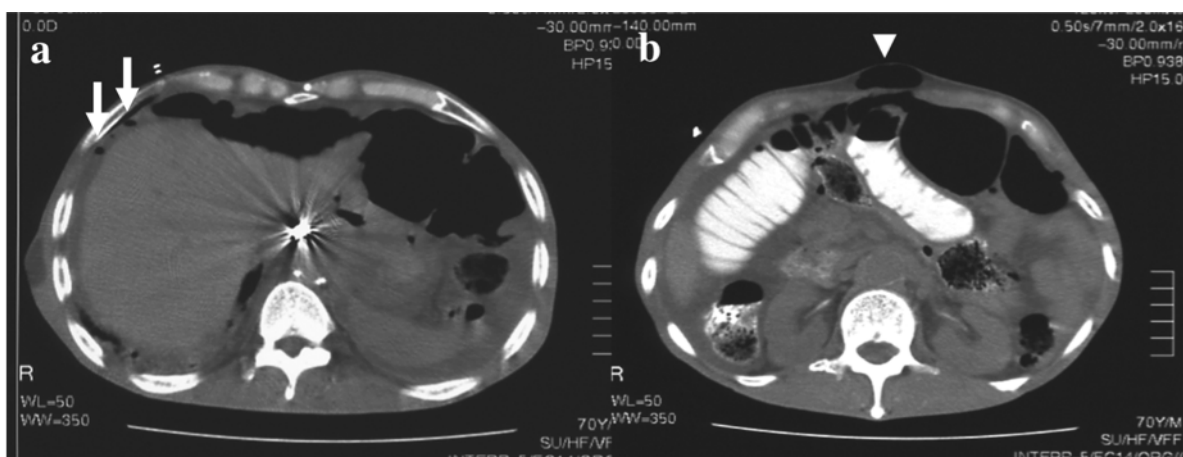


Figure 2 CT showed the dilated small intestine, with intra-abdominal free air at the liver surface (a white arrow) and in the sac of the incisional hernia (b, white arrow head), and ascites (a, b).

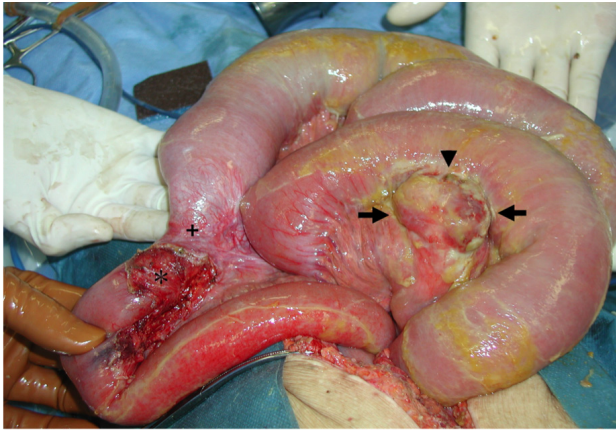


Figure 3 After the removal of the adhesion between the jejunum at 130cm along the anal side from the ligament of Treitz and the previous operative wound (black star), a caliber change in the jejunum was identified (black cross). A perforated jejunal diverticulum was observed (black arrows) at 30cm along the anal side from the ligament of Treitz, and the hole of the perforated jejunal diverticulum was also identified (black arrow head).

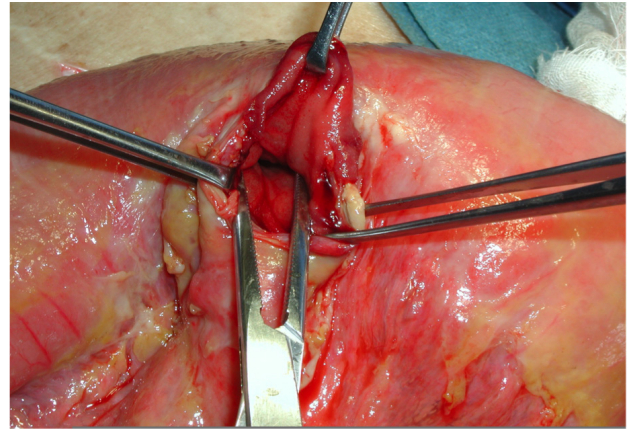


Figure 4 The wall of the perforated diverticulum was thinner than the nearby normal jejunal wall and lacked a muscular layer.

jejunum. Adhesiolysis and exteriorization of the perforated jejunal diverticulum using a tube were performed, because the status of the patient was too serious to tolerate the resection of the small intestine including the perforated lesion. Especially, it was hard to maintain his circular status for long time.

The patient tolerated the procedure with great difficulty and was sent to the intensive care unit for his serious condition.

The patient eventually recovered, and the tube was removed on Day 14 after the operation. The wound of the removed tube was closed on Day 30 and he left the hospital on Day 37 after the operation.

DISCUSSION

The incidence of jejunal diverticulum ranges from 0.5%^[5] to 2.3%^[6] in radiographic examinations and from 0.26%^[7] to 4.6%^[8] on autopsy. This condition is believed to develop from a combination of abnormal peristalsis, intestinal dyskinesia, and high segmental intra-luminal pressures. Krishnamurthy *et al* suggested that intestinal dyskinesia due to abnormality of the smooth muscle or myenteric plexus results in diverticula formation^[9]. Kongara *et al* believed that irregular intestinal contractions increased the intraluminal pressure, resulting in diverticula formation through the weakest point^[10]. The cause of the perforation in the present case is speculated to be unusually increased intra-luminal pressure of the jejunum due to worsening of the adhesional ileus.

Though diverticula are generally asymptomatic, they are occasionally accompanied by life-threatening symptoms, such as malabsorption, diverticulitis, hemorrhaging, obstruction, and perforation^[11]. Perforation occurs in 2.3%-6.4% of patients with jejunal diverticulosis^[12], and 10% of patients with small bowel diverticulosis may require surgical intervention for complications^[13]. Roses *et al* reported that the mortality rate from perforated jejunal diverticula can be high as 21% to 40%, according to some reports, particularly in patients who are old or have a delayed diagnosis^[12].

Novak *et al* reported the possibility of non-surgical management for perforated jejunal diverticula if the perforation causes only localized peritonitis and the patient remains stable^[14]. This is a relatively new idea, and the evidence supporting a good outcome with this strategy is limited to case reports such as the present one^[14]. The current treatment of choice for perforated jejunal diverticula that is causing generalized peritonitis or compromising the patient's

condition is prompt laparotomy with segmental intestinal resection and primary anastomosis^[15]. In this case, the patient also received a prompt operation because of the generalized peritonitis.

This report presents a rare surgical case of perforated jejunal diverticulum due to small bowel obstruction in an adult patient with alcoholic psychosis and dementia. Although some reports have indicated that alcohol consumption is a risk factor for colonic diverticulosis^[16,17], there are no reports of an association between jejunal diverticulum and alcohol consumption.

CONCLUSION

In cases of a perforated jejunal diverticulum with panperitonitis, an emergency laparotomy are recommended.

REFERENCES

1. Staszewicz W, Christodoulou M, Proietti S, Demartines N. Acute ulcerative jejunal diverticulitis: case report of an uncommon entity. *World J Gastroenterol* 2008; **14**: 6265-6267. [PMID: 18985822]; [DOI: 10.3748/wjg.14.6265]
2. Singal R, Gupta S and Airon A. Giant and multiple jejunal diverticula presenting as peritonitis a significant challenging disorder. *J Med Life* 2012; **5**: 308-310. [PMCID: PMC3464999]
3. Patel VA, Jefferis H, Spiegelberg B, Iqbal Q, Prebhudesai A and Harris S. Jejunal diverticulosis is not always a silent spectator. *World J Gastroenterol* 2008; **14**: 5916-5919. [PMID: 18855994]; [DOI: 10.3748/wjg.14.5916]
4. Woods K, William E, Melvin W and Sharp K. Acquired jejunoileal diverticulosis and its complications. A review of the literature. *Am Surg* 2008; **74**: 849-854. [PMID: 18807676]
5. Ritvo M, Votta PJ. Diverticulosis of jejunum and ileum. *Radiology* 1946; **46**: 343-350. [PMID: 21027367]; [DOI: 10.1148/46.4.343]
6. Maglinte DD, Chemish SM, DeWeese R, Kelvin FM and Brunelle RL. Acquired jejunoileal diverticular disease: subject review. *Radiology* 1986; **58**: 577-580. [PMID: 3080802]; [DOI: 10.1148/radiology.156.3.3080802]
7. Altermeier WA, Bryant LR and Wulsin JH. The surgical significance of jejunal diverticulosis. *Arch Surg* 1963; **86**: 732-745. [PMID: 14012298]
8. Noer T. Non meckelian diverticula of the small bowel. The incidence in an autopsy material. *Acta Chir Scand* 1960; **120**: 175-179. [PMID: 13729424]

9. Krishnamurthy S, Kelly MM, Rohmann CA, and Schuffer MD. Jejunal diverticulosis, A heterogeneous disorder caused by a variety of abnormalities of smooth muscle or myenteric plexus. *Gastroenterology* 1983; **85**: 538-547. [PMID: 6409704]
10. Kongara KR and Soffer EE. Intestinal motility in small bowel diverticulosis: a case report and review of the literature. *J Clin Gastroenterol* 30, 84-86, 2000. [PMID: 10636218]
11. Akhrass R, Yaffe MB, Fischer C, Ponsky J and Shuck JM. Small bowel diverticulosis: Perceptions and reality. *J Am Col Surg* 1997; **184**: 383-388. [PMID: 9100684]
12. Roses DF, Gouge TH, Schher KS and Ranson JH. Perforated diverticula of the jejunum and ileum. *Am J Surg* 1976; **132**: 649-652. [PMID: 824970]
13. Tesiotos GG, Farnell MB, Iistrup DM. Nonmeckelian jejunal or ileal diverticulosis: An analysis of 112 cases. *Surgery* 1994; **116**: 726-732. [PMID: 7940172]
14. Novak JS, Tobias J and Barkin JS. Nonsurgical management of acute jejunal diverticulitis: a review. *Am J Gastroenterol* 1997; **92**: 1929-1931. [PMID: 9382070]
15. Mattioni R, Lolli E, Barbieri A and D'Ambrosi M. Perforated jejunal diverticulitis: Personal experience and diagnostic with therapeutical considerations. *Ann Ital Chir* 2000; **71**: 95-98. [PMID: 10829530]
16. Sharara AI, El-Halabi MM, Mansour NM, Malli A, Ghaith OA, Hashash JG, Maasri K, Soweid A, Barada K, Mourad FH and El Zahabi L. Alcohol consumption is a risk factor for colonic diverticulosis. *J Clin Gastroenterol* 2013; **47**: 420-425. [PMID: 23164685]; [DOI: 10.1097/MCG.0b013e31826be847]
17. Nagata N, Niikura R, Shimbo T, Kishida Y, Sekine K, Tanaka S, Aoki T, Watanabe K, Akiyama J, Yanase M, Itoh T, Mizokami M and Uemura N. Alcohol and smoking affect risk factor of uncomplicated colonic diverticulosis in Japan. *PLOS ONE* 2013; **8**: e81137. [PMID: 24339905]; [DOI: 10.1371/journal.pone.0081137]

Peer reviewer: Hsien Chung, Magdy El-Serafy