

## How Should Hilar Cholangiocarcinoma Be Treated In Patients Starting Dual Antiplatelet Therapy Just After Implantation Of Drug-Eluting Coronary Stents?

Hisatsugu Maekawa, Takahisa Fujikawa, Akira Tanaka

Hisatsugu Maekawa, Takahisa Fujikawa, Akira Tanaka, Department of Surgery, Kokura Memorial Hospital, Kitakyushu, Fukuoka 802-8555, Japan

Takahisa Fujikawa, Department of Surgery, Graduate School of Medicine, Kyoto University, Kyoto, Japan

Correspondence to: Takahisa Fujikawa, MD, PhD, FACS, Department of Surgery, 3-2-1 Asano, Kokurakita-ku, Kitakyushu, Fukuoka 802-8555, Japan.

Email: [fujikawa-t@kokurakinen.or.jp](mailto:fujikawa-t@kokurakinen.or.jp)

Telephone: +81-93-511-2000

Fax: +81-93-511-3240

Received: July 5, 2016

Revised: August 23, 2016

Accepted: August 27, 2016

Published online: October 21, 2016

Maekawa H, Fujikawa T, Tanaka A. How Should Hilar Cholangiocarcinoma Be Treated In Patients Starting Dual Antiplatelet Therapy Just After Implantation Of Drug-Eluting Coronary Stents? *Journal of Gastroenterology and Hepatology Research* 2016; 5(5): 2209-2211 Available from: URL: <http://www.ghrnet.org/index.php/joghr/article/view/1776>

### LETTER TO THE EDITOR

We have focused on perioperative management of patients with recent drug-eluting coronary stent (DES) implantation during pancreaticoduodenectomy in a recent issue of *Journal of Gastroenterology and Hepatology Research*<sup>[1]</sup>. Likely, we recently experienced a case requiring treatment for hilar cholangiocarcinoma in a patient starting dual-antiplatelet therapy (DAPT) just after implanting a drug-eluting coronary stent.

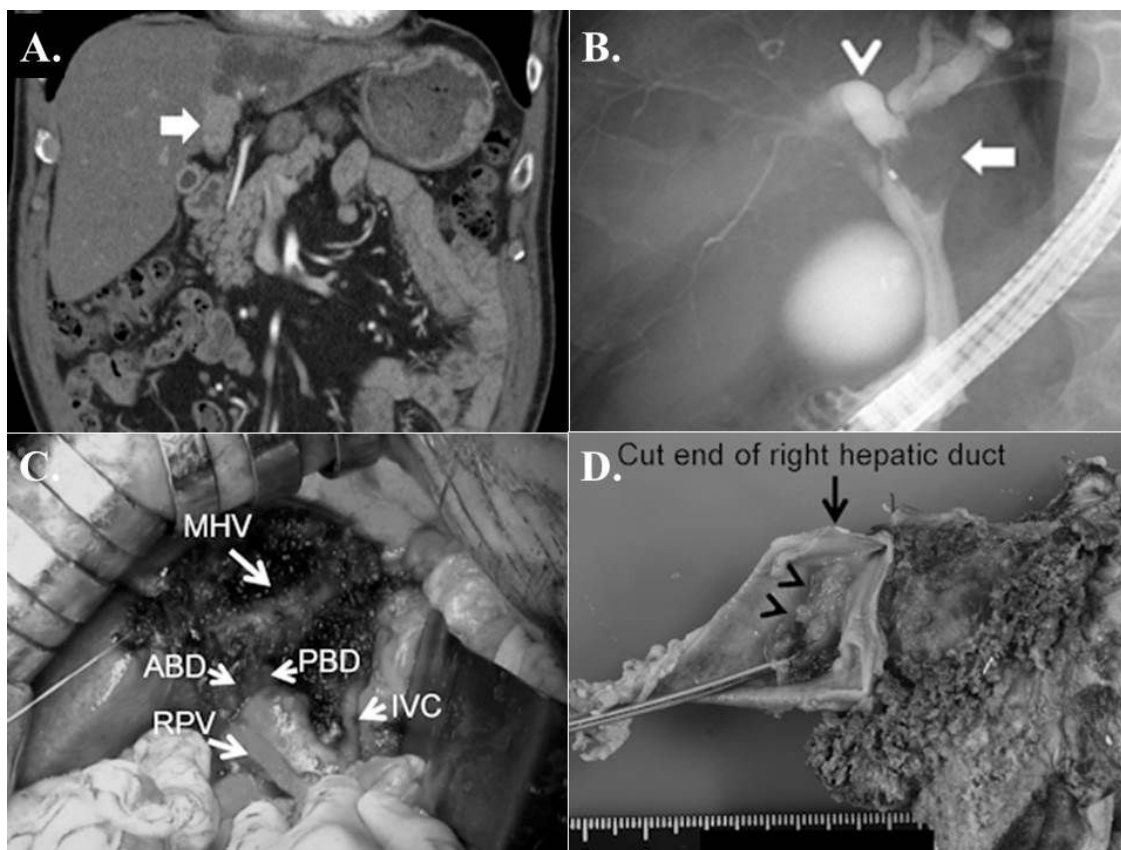
A 76-year-old Japanese male patient was admitted to our hospital for myocardial infarction and underwent DES insertion (everolimus-eluting stent) into both his right coronary artery and left circumflex artery. Follow-up computed tomography was performed a few days later, and an enhanced tumor shadow, accompanied by obstruction of the left hepatic duct, was detected (Figure 1A). Endoscopic retrograde cholangiopancreatography (Figure 1B) confirmed the diagnosis of locally advanced hilar cholangiocarcinoma (Bismuth-Corlette type IIIb), and an internal biliary drainage catheter was left in place. The patient was considered to require surgical resection, but the risks of surgical intervention were heightened by the facts that he had experienced myocardial infarction, that the DES had been placed within the previous 4 weeks, and that he had just started DAPT following DES implantation. After the patient was informed of the risks, benefits, and alternative therapies, we decided to begin cisplatin plus gemcitabine chemotherapy with continuation of DAPT. The patient received 7 cycles of chemotherapy without any significant adverse drug events, and the tumour response was assessed as stable disease.

Six months after the initial diagnosis, a surgical intervention was attempted. According to our perioperative antithrombotic protocol

### ABSTRACT

Patients who undergo drug-eluting coronary stent (DES) implantation require dual antiplatelet therapy for at least 6 months. When these patients require non-cardiac surgery, determination of the most appropriate antiplatelet therapy to minimize the risk of stent thrombosis and/or bleeding complications is always difficult. In particular, patients who have just undergone DES implantation have an extremely high risk of stent thrombosis, and delaying surgery is required to reduce the risk. We herein report the case of a male patient in whom hilar cholangiocarcinoma was detected just after implanting DES and who safely underwent curative resection for the hilar cholangiocarcinoma following neoadjuvant chemotherapy. This case serves as an example of successful resolution of this challenging problem.

**Key words:** Hilar cholangiocarcinoma; Drug-eluting coronary stent (DES); Surgery; Neoadjuvant chemotherapy



**Figure 1** (A) Dynamic abdominal computed tomography during the venous phase of the coronal image revealed an enhanced tumor shadow measuring 3.0 × 2.1 cm in the hilum (arrow), obstruction of the left hepatic duct, and a dilated left intrahepatic bile duct. (B) Endoscopic retrograde cholangiopancreatography revealed a tumor defect in the left hepatic duct (arrow), a dilated left intrahepatic bile duct, and a slightly dilated posterior hepatic duct (arrow head). (C) Intraoperative picture. RPV = right portal vein, MHV = middle hepatic vein, IVC = inferior vena cava, ABD = anterior bile duct, PBD = posterior bile duct. (D) Resected specimen revealed papillary adenocarcinoma in the left bile duct with extension to the bifurcation of the hilar bile duct (arrow head); however, a disease-free surgical margin was secured (arrow).

in high thromboembolic risk patients (“Kokura Protocol”)<sup>[2,3]</sup>, DAPT was discontinued 7 days prior to surgery and aspirin monotherapy was continued until surgery to minimize the risks of intraoperative bleeding and thromboembolic complications. We carried out left hepatectomy with Spiegel lobe resection, followed by biliary reconstruction (Figure 1C). The operative time and estimated blood loss was 478 min and 500 mL, respectively, and no blood transfusion was required. The tumor was pathologically diagnosed with papillary adenocarcinoma, and the surgical margin was negative for malignancy (Figure 1D). His antiplatelet therapy was reinstated on postoperative day (POD) 2 and the patient recovered well postoperatively without any thromboembolic or bleeding complications. He developed minor bile leakage, but he made a full recovery with the use of drainage and antimicrobial therapy and was discharged POD 29.

The 2016 American Heart Association/American College of Cardiology guidelines recommend continuing DAPT for all patients for at least 6 months after DES implantation. According to the guidelines, elective non-cardiac surgery after DES implantation should be delayed until completion of 6 months of DAPT, or, if urgent, the surgery should be performed without cessation of antiplatelet therapy<sup>[4]</sup>. However, surgery for hilar cholangiocarcinoma is the only curative treatment, and patients sometimes become incurable due to delays in the performance of surgery. The present case involved a dilemma regarding whether to perform surgery soon or not because it is one of the most difficult abdominal procedures and carries high risks of bleeding and postoperative complications<sup>[5]</sup>.

In the present case, we could not overlook this increased risk because the patient had undergone DES implantation within the 4 weeks before the diagnosis. Since cardiologists on the patient care team resorted to postponement of surgery for 6 months according to the guideline, we adopted to perform neoadjuvant chemotherapy before surgery. Cisplatin plus gemcitabine chemotherapy for patients with advanced biliary tract cancer improves progression-free survival with the reported median progression-free survival of 8.0 months<sup>[6]</sup>. Thus we adopted this regimen and successfully suppressed the tumor progression during the 6-month waiting period. Subsequently, successful perioperative management and surgical resection could be also performed without any bleeding or thromboembolic complications using “Kokura Protocol”, our perioperative antiplatelet management protocol for patients with high thromboembolic risks<sup>[2,3]</sup>.

Because of the dearth of material on major HPB surgery for patients with DES, no consensus on the optimal strategy in these patients has been established. Further studies and case reports are needed to clarify the best way to treat these patients while minimizing risk. We hope that this case will help other clinicians in determining the most optimal therapeutic strategy for patients in the same situation.

## CONFLICT OF INTEREST

All authors declared no potential conflicts of interest. All authors received no financial support.

## REFERENCES

1. Fujikawa T, Yoshimoto Y, Tanaka A. Surgical Treatment of Pancreatic Head Cancer and Perioperative Management in High Thromboembolic Risk Patients With Recent Drug-Eluting Coronary Stent Implantation. *Journal of Gastroenterology and Hepatology Research* 2016; **5(2)**: 2032-2033. Available from: URL: <http://www.ghrnet.org/index.php/joghr/article/view/1554>.
2. Fujikawa T, Tanaka A, Abe T, Yoshimoto Y, Tada S, Maekawa H. Effect of antiplatelet therapy on patients undergoing gastrointestinal surgery: thromboembolic risks versus bleeding risks during its perioperative withdrawal. *World J Surg* 2015; **39(1)**: 139-149.
3. Fujikawa T, Tanaka A, Abe T, Yoshimoto Y, Tada S, Maekawa H, Shimoike N. Does antiplatelet therapy affect outcomes of patients receiving abdominal laparoscopic surgery? Lessons from more than 1,000 laparoscopic operations in a single tertiary referral hospital. *J Am Coll Surg* 2013; **217(6)**: 1044-1053.
4. Levine GN, Bates ER, Bittl JA, Brindis RG, Fihn SD, Fleisher LA, Granger CB, Lange RA, Mack MJ, Mauri L, Mehran R, Mukherjee D, Newby LK, O'Gara PT, Sabatine MS, Smith PK, Smith SC, Jr. 2016 ACC/AHA Guideline Focused Update on Duration of Dual Antiplatelet Therapy in Patients With Coronary Artery Disease: A Report of the American College of Cardiology/American Heart Association Task Force on Clinical Practice Guidelines. *J Am Coll Cardiol* 2016.
5. Dinant S, Gerhards MF, Rauws EA, Busch OR, Gouma DJ, van Gulik TM. Improved outcome of resection of hilar cholangiocarcinoma (Klatskin tumor). *Ann Surg Oncol* 2006; **13(6)**: 872-880.
6. Valle J, Wasan H, Palmer DH, Cunningham D, Anthoney A, Maraveyas A, Madhusudan S, Iveson T, Hughes S, Pereira SP, Roughton M, Bridgewater J. Cisplatin plus gemcitabine versus gemcitabine for biliary tract cancer. *N Engl J Med* 2010; **362(14)**: 1273-1281.

**Peer reviewer:** Kazumichi Kawakubo, MD, PhD, Department of Gastroenterology, Graduate School of Medicine, The University of Tokyo, 7-3-1, Hongo, Bunkyo-ku, Tokyo, Japan.