

## Duodenal Gastrointestinal Stromal Tumor Treated by Wedge Resection: A Case Report

Yoshifumi Nakayama, Masaki Akiyama, Yusuke Sawatsubashi, Jun Nagata, Kazunori Shibao, Keiji Hirata

Yoshifumi Nakayama, Masaki Akiyama, Yusuke Sawatsubashi, Jun Nagata, Kazunori Shibao, Keiji Hirata, Department of Surgery 1, School of Medicine, University of Occupational and Environmental Health, 1-1 Iseigaoka, Yahata-nishi-ku, Kitakyushu 807-8555, Japan

Yoshifumi Nakayama, Masaki Akiyama, Yusuke Sawatsubashi, Jun Nagata, Department of Gastroenterological and General Surgery, Wakamatsu Hospital of University of Occupational and Environmental Health, 1-17-1 Hamamachi, Wakamatsu-ku, Kitakyushu 808-0024, Japan

**Conflict-of-interest statement:** The author(s) declare(s) that there is no conflict of interest regarding the publication of this paper.

**Open-Access:** This article is an open-access article which was selected by an in-house editor and fully peer-reviewed by external reviewers. It is distributed in accordance with the Creative Commons Attribution Non Commercial (CC BY-NC 4.0) license, which permits others to distribute, remix, adapt, build upon this work non-commercially, and license their derivative works on different terms, provided the original work is properly cited and the use is non-commercial. See: <http://creativecommons.org/licenses/by-nc/4.0/>

**Correspondence to:** Yoshifumi Nakayama, Department of Gastroenterological and General Surgery, Wakamatsu Hospital of University of Occupational and Environmental Health, Japan.

Email: [nakayama@med.uoeh-u.ac.jp](mailto:nakayama@med.uoeh-u.ac.jp)

Telephone: +81-93-761-0090

Fax: +81-93-588-3904

Received: October 29, 2016

Revised: November 1, 2016

Accepted: November 6, 2016

Published online: December 21, 2016

### ABSTRACT

This report describes a patient with a duodenal gastrointestinal stromal tumor (GIST). A 77-year-old Japanese male presented with abdominal fullness and weight loss. Computed tomography (CT) of the abdomen demonstrated an enhanced mass, 4 × 3 cm in size, at the right side

of the inferior vena cava. An endoscopic examination revealed a duodenal submucosal tumor. He was referred to the surgical outpatient clinic for surgical treatment of a duodenal submucosal tumor. Laparotomy allowed for the identification of a nut-sized extramural tumor at the second portion of the duodenum. Wedge resection of the duodenum including the tumor was performed. A histopathological examination revealed that the tumor was composed of a proliferation of spindle cells with spindle nuclei and eosinophilic fibrillar cytoplasm, arranged in fascicles with a hypercellular area. An immunohistochemical examination revealed that these tumor cells were positive for c-kit, CD34, and S-100 and were negative for SMA. The mitotic figures were less than 1 in 20 high-power fields. This duodenal tumor was diagnosed as a low-risk GIST. The patient had an uneventful recovery and was discharged from the hospital on Day 17 after the operation. This report presents a rare surgical case of duodenal GIST treated with wedge resection of the duodenum.

**Key words:** Gastrointestinal stromal tumor; Duodenum; Wedge resection

© 2016 The Author(s). Published by ACT Publishing Group Ltd.

Nakayama Y, Akiyama M, Sawatsubashi Y, Nagata J, Shibao K, Hirata K. Duodenal Gastrointestinal Stromal Tumor Treated by Wedge Resection: A Case Report. *Journal of Gastroenterology and Hepatology Research* 2016; 5(6): 2261-2265 Available from: URL: <http://www.ghrnet.org/index.php/joghr/article/view/1794>

### INTRODUCTION

The incidence of GISTs is estimated to be 10-20 cases per million<sup>[1,2]</sup>, with equal gender distribution<sup>[3]</sup>. GISTs can arise anywhere in the GI tract, although they are more frequently found in the stomach (about 60%), small intestine (about 25%), and colon and rectum (about 10%); only 3%-5% of GISTs occur in the duodenum<sup>[4,5]</sup>. Duodenal GISTs account for < 5% of all GISTs but make up 30% of primary duodenal tumors<sup>[6]</sup>. The most common location of duodenal GISTs is the second portion of the duodenum (26.9%), and they are frequently located close to the ampulla of Vater<sup>[7,8]</sup>.

This report presents a surgical case of duodenal GIST treated with wedge resection of the duodenum.

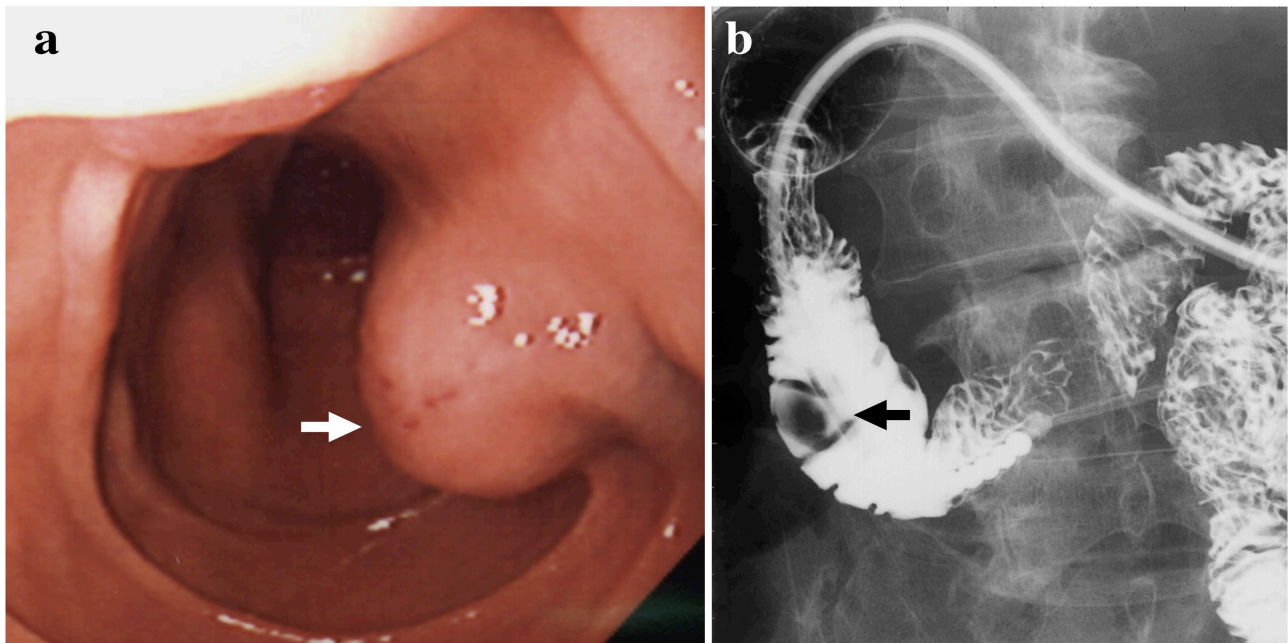
## CASE REPORT

A 77-year-old Japanese male presented with abdominal fullness and weight loss. An endoscopic examination revealed a submucosal tumor 1 cm in diameter at the second portion of the duodenum and opposite-anterior side the papilla of Vater (Figure 1a). Hypotonic duodenography revealed a duodenal tumor mass, 1.5 cm in diameter (Figure 1b).

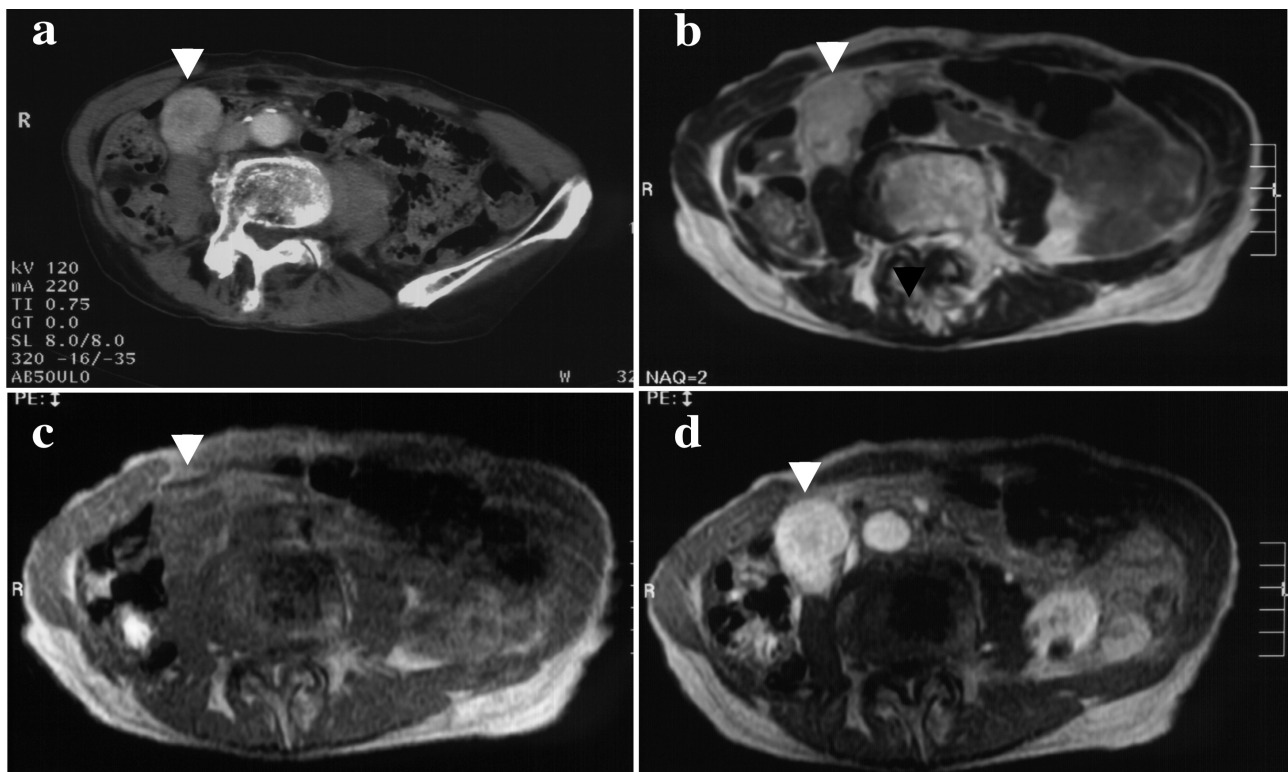
Computed tomography (CT) of the abdomen demonstrated an

enhanced mass, 4 × 3 cm in diameter, at the right side of the inferior vena cava (Figure 2a). Gadolinium-enhanced magnetic resonance imaging (MRI) also revealed a mass (Figure 2d) that showed high intensity in T2 (Figure 2b) and isointensity in T1 (Figure 2c). The patient was referred to the surgical outpatient clinic for surgical treatment of a submucosal tumor of the duodenum.

A physical examination revealed no conjunctival pallor, and there was no muscular rigidity or rebound tenderness in response to abdominal palpation. Laboratory investigations revealed a white blood



**Figure 1** An endoscopic examination revealed a submucosal tumor 1 cm in diameter at the second portion of the duodenum and opposite-anterior side the papilla of Vater (a, black arrow). Hypotonic duodenography revealed a duodenal tumor mass, 1.5 cm in diameter (b, black arrow).



**Figure 2** Computed tomography (CT) of the abdomen demonstrated an enhanced mass, 4 × 3 cm in diameter, at the right side of the inferior vena cava (a, white arrow head). Gadolinium-enhanced magnetic resonance imaging (MRI) also revealed a mass (d), that showed high intensity in T2 (b) and isointensity in T1 (c)(white arrow heads).



cell count of 4,600/mm<sup>3</sup>, hemoglobin 11.2 g/dL with a hematocrit value of 33.9%, 208,000/mm<sup>3</sup> platelets, normal electrolytes, as well as normal blood urea nitrogen levels and a normal liver function. CEA was less than 1.0 ng/mL, and CA19-9 was 8.8 U/mL. Coagulation studies revealed a prothrombin time of 11.9 seconds and an activated partial thromboplastin time of 26.9 seconds.

Laparotomy revealed a nut-sized extramural tumor at the second portion of the duodenum that was white-yellow, elastic, soft, and had dilated vessels on the surface (Figure 3a, 3b).

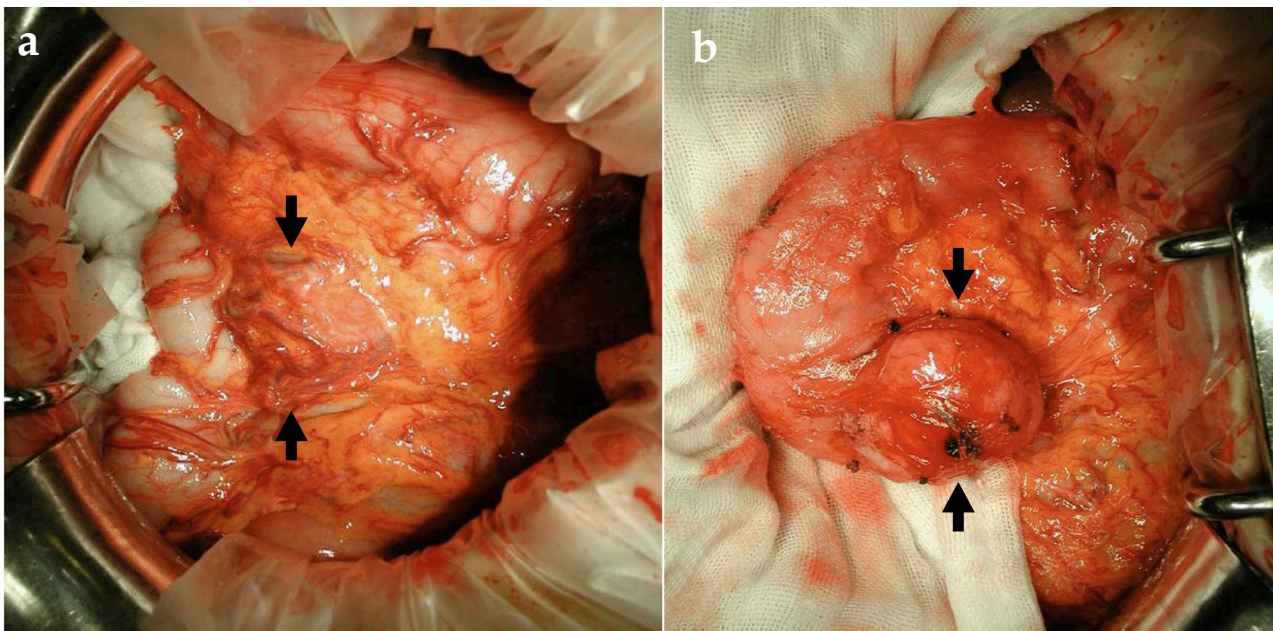
Then, wedge resection of the duodenum including the tumor was performed. The margin of the tumor was at least 0.5 cm. An examination of an operative specimen revealed a transmural growth tumor with a smooth surface. The intramural part of this tumor was 1 cm and the extramural part 3 cm in diameter (Figure 4a). The cut surface revealed

a uniform white-yellow surface without necrotic portions (Figure 4b).

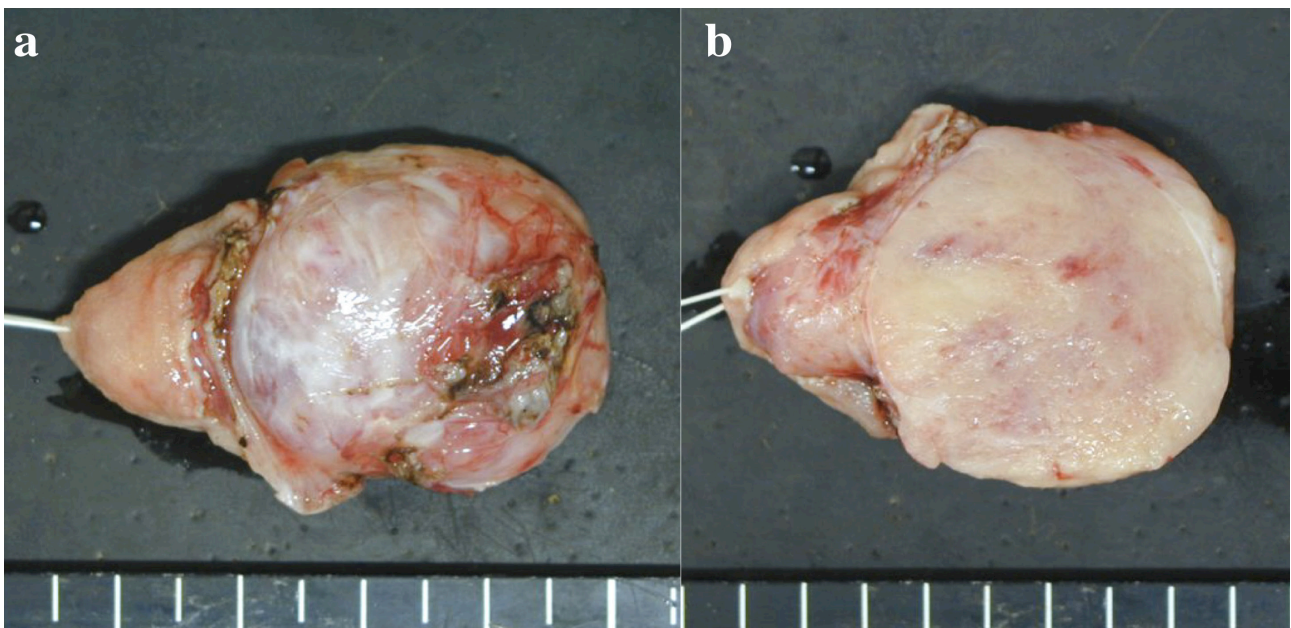
A histopathological examination with hematoxylin and eosin staining revealed that the duodenal tumor was composed of a proliferation of spindle cells with spindle nuclei and eosinophilic fibrillar cytoplasm, arranged in fascicles with a hypercellular area (Figure 5). Figure 5. A histopathological examination with hematoxylin and eosin staining of the duodenal tumor ( $\times 200$ ) revealed that the tumor was composed of a proliferation of spindle cells with spindle nuclei and eosinophilic fibrillar cytoplasm, arranged in fascicles with a hypercellular area.

The immunohistochemical staining revealed positivity for c-kit (Figure 6a), CD34 (Figure 6b), and S-100 (Figure 6d), but negative findings for smooth muscle actin (SMA; Figure 6c).

The mitotic figures were less than 1 in 20 high-power fields (HPF).



**Figure 3** Laparotomy revealed a nut-sized extramural growing tumor at the second portion of the duodenum (a, b) that was white-yellow, elastic soft and had dilated vessels on the surface (black arrows).



**Figure 4** An operative specimen revealed a transmural growth tumor with smooth surface. The intramural part of this tumor was 1 cm and the extramural part 3 cm in diameter (a). The cut surface revealed a uniform white-yellow surface without necrotic portions (b).

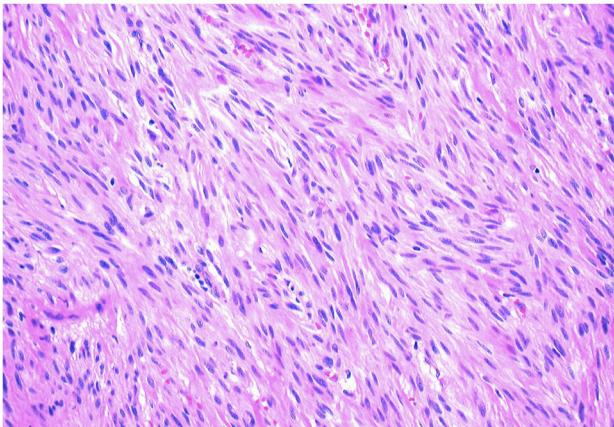


This GIST was classified as low risk, according to the NIH risk classification of GISTs<sup>[9]</sup>. The patient had no family history of GIST and had not experienced NF1. No molecular analysis of the mutations in KIT and PDGFR was performed.

The patient had an uneventful recovery and was discharged from the hospital on Day 17 after the operation.

## DISCUSSION

The malignant potential of GISTs varies from virtually benign to aggressive. Approximately 20%-30% of GISTs are malignant tumors<sup>[3]</sup>. Flecher *et al* proposed a risk stratification system for GISTs which classified them according to size and mitotic count<sup>[10]</sup>. Duodenal GISTs



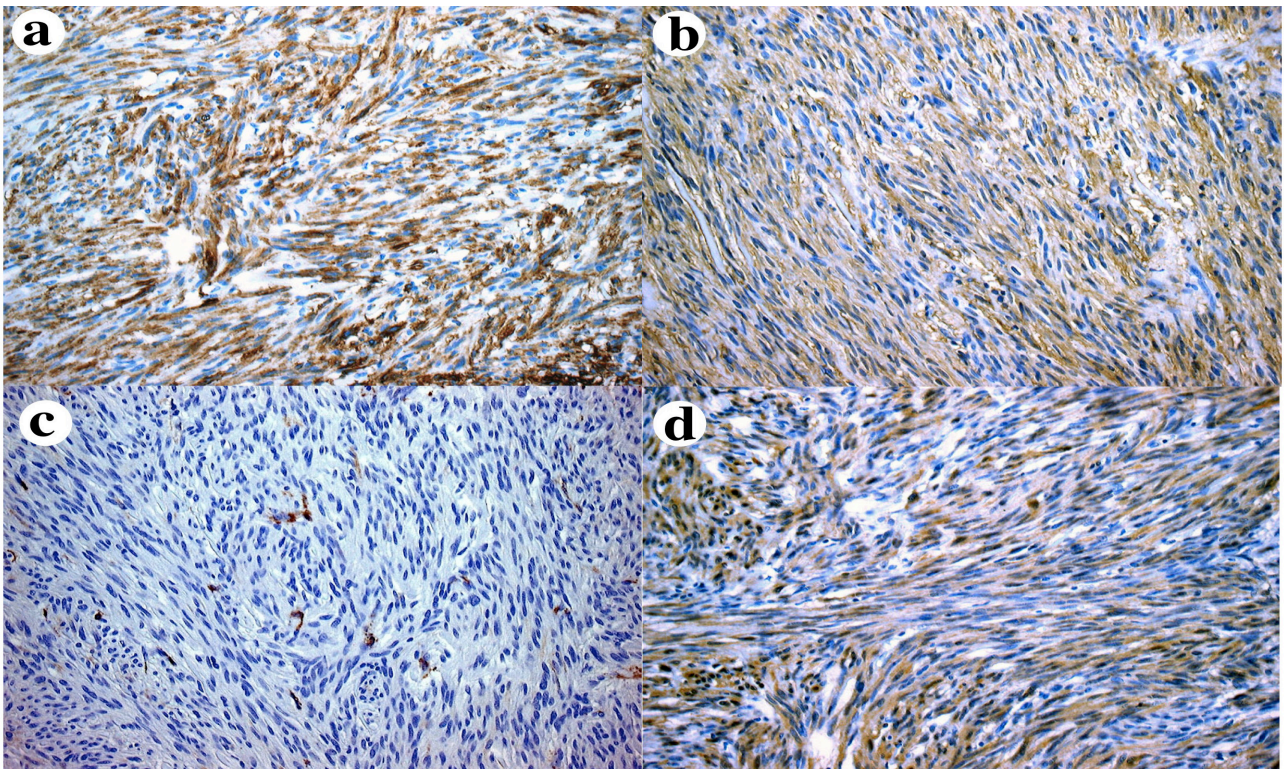
**Figure 5** A histopathological examination with hematoxylin and eosin staining of the duodenal tumor (x200) revealed that the tumor was composed of a proliferation of spindle cells with spindle nuclei and eosinophilic fibrillar cytoplasm, arranged in fascicles with a hypercellular area.

less than 5 cm in diameter and with a mitotic index of less than 5/50 HPF carry a low risk for disease progression (8.3%)<sup>[11]</sup>. Chiarugi *et al* reviewed 156 duodenal GISTs in adult and pediatric patients and found that 86% of those with a tumor > 5 cm in diameter with > 5 mitoses per 50 HPF died of their disease, whereas no recurrence or metastases were seen in patients with tumor < 2 cm in diameter with < 5 mitoses per 50 HPF<sup>[12]</sup>. In our present case, this duodenal GIST was classified as low risk, according to the NIH risk classification of GIST<sup>[9]</sup> or Risk of Aggressive Behavior in GISTs<sup>[10]</sup>.

Since the longitudinal submucosal spread is very limited and lymph node involvement is rare in GISTs, margin-negative resection without lymphadenectomy is the commonly accepted surgical treatment of GISTs<sup>[13,14]</sup>. However, there is no consensus on the optimal surgical treatment for duodenal GISTs<sup>[15,16]</sup>, although several methods have been suggested. These methods include wedge resection, segmental resection, and pancreaticoduodenectomy (Table 1). Generally, small tumors can be treated by local excision and primary closure of the duodenal wall, if the remaining lumen is adequate and the ampulla of Vater can be preserved. Segmental resection of the duodenum with duodenojejunostomy is another possibility. Tumors located near to the ampulla of Vater in particular require duodeno-pancreatectomy. Miettinen *et al* reported that about 20% of patients underwent duodenopancreatectomy, whereas segmental resection

**Table 1** Operative methods for duodenal GISTs in previously reported cases.

Operative methods	Preserved Ampulla of Vater	Risk	Ref.
Wedge resection	Yes	very low-intermediate	[12, 15, 17, 18]
Segmental resection	Yes	low-high	[4, 6, 7, 15, 17]
Pancreaticoduodenectomy	No	low-high	[6, 16, 17]



**Figure 6** The immunohistochemical staining patterns of the duodenal GIST (x200). The tumor cells of duodenal GIST were positive for c-kit (a), CD34 (b), and S-100 (d), but negative for SMA (c).

and local wedge resection were performed in 45% and 20% of cases, respectively<sup>[8]</sup>. Large tumors with high malignant potential or tumors invading adjacent organs still require duodenopancreatectomy. At any rate, the surgical approach should be tailored for each duodenal GIST. In the present case, we performed a wedge resection and primary closure of the duodenal wall, because this tumor was less than 5 cm in diameter and located opposite-anterior of the papilla of Vater.

## CONCLUSION

We herein reported a rare surgical case of a patient with duodenal GIST treated with wedge resection of the duodenum.

## REFERENCES

- 1 Hirota S, Isozaki K, Moriyama Y, Hashimoto K, Nishida T, Ishiguro S, Kawano K, Hanada M, Kurata A, Takeda M, Tunio GM, Matsuzawa Y, Kanakura Y, Shinomura Y, Kitamura Y. Gain-of-function mutations of c-kit in human gastrointestinal stromal tumors. *Science* 1998; **279**: 577-580. [PMID: 9438854; DOI: 10.1126/science.279.5350.577]
- 2 Kindblom LG, Remotti HE, Aldenborg F, Meis-Kindblom JM. Gastrointestinal pacemaker cell tumor (GIPACT). Gastrointestinal stromal tumors show phenotypic characteristics of the interstitial cells of Cajal. *Am J Pathol* 1998; **153**: 1259-1269. [PMID: 9588894]
- 3 Miettinen M, Lasota J. Gastrointestinal stromal tumors-definition, clinical, histological, immunohistochemical and molecular genetic futures and differential diagnosis. *Virchow Arch* 2010; **438**: 1-12. [PMID: 11213830; DOI: 10.1007/s004280000338]
- 4 Kwon SH, Cha HJ, Jung SW, Kim BC, Park JS, Jeong ID, Lee JH, Nah YW, Bang SJ, Shin JW, Park NH, Kim DH. A gastrointestinal tumor of the duodenum masquerading as a pancreatic head tumor. *World J Gastroenterol* 2007; **13**: 3396-3399. [PMID: 17659684; DOI: 10.3748/wjg.v13.124.3396]
- 5 Butt J, Rowley S, Byrne PJ, Reynolds JV. Management of gastrointestinal stromal tumors: a single center experience. *Ir J Med Sci* 2007; **176**: 157-160. [PMID: 17598335; DOI: 10.1007/s11845-007-0054-6]
- 6 Buchs NC, Bucher P, Gervas P, Ostemann S, Pugin F, Morel P. Segmental duodenectomy for gastrointestinal stromal tumor of the duodenum. *World J Gastroenterol* 2010; **16**: 2788-2792. PMID: 20533599; DOI: 10.3748/wjg.v16.i22.2788
- 7 Mennigen R, Wolters HH, Schulte B, Pelster W (2008) Segmental resection of the duodenum for gastrointestinal stromal tumor (GIST). *World J Surg Oncol* 2008; **6**: 105. [PMID: 18826622; DOI: 10.1186/1477-7819-6-105]
- 8 Miettinen M, Kopczynski J, Makhlof HR, Sarlomo-Rikala, Gyorffy H, Burke A, Sobin LH, Lasota J. Gastrointestinal stromal tumors, intramural leiomyomas, and leiomyosarcomas in the duodenum: a clinicopathologic, immunohistochemical, and molecular genetic study of 167 cases. *Am J Surg Pathol* 2003; **27**: 625-641. [PMID: 12717247]
- 9 Joensuu H. Risk stratification of patients diagnosed with gastrointestinal stromal tumor. *Human Pathol* 2008; **39**: 1411-1419. [PMID: 18774375; DOI: 10.1016/j.humpath.2008.06.025]
- 10 Fletcher CDM, Berman JJ, Corless C, Gorstein F, Lasota J, Longley BJ, Miettinen M, O'leary J, Remotti H, Rubin BP, Shmookler B, Sobin LH, Weiss SW. Diagnosis of gastrointestinal stromal tumors: a consensus approach. *Human Pathol* 2002; **33**(5): 459-465. [PMID: 12094370; DOI: 10.1053/hupq.2002.123545]
- 11 Miettinen M, Lasota J. Gastrointestinal stromal tumors: review of morphology, molecular pathology, prognosis, and differential diagnosis. *Arch Pathol Lab Med* 2006; **130**: 1466-1478. [PMID: 17090188]
- 12 Chiarugi M, Galatioto C, Lippolis P, Zocco G, Seccia M. Gastrointestinal stromal tumour of the duodenum in childhood: a rare case report. *BMC Cancer* 2007; **79**: 79. [PMID: 17490483; DOI: 10.1186/1471-2407-7-79]
- 13 Connolly EM, Gaffney F, Reynolds JV. Gastrointestinal stromal tumors. *Br J Surg* 2003; **90**: 1178-1186. [PMID: 14515284; DOI: 10.1002/bjbs.4352]
- 14 Agaimy A, Wunsch PH, Sobin LH, Lasota J, Miettinen M. Occurrence of other malignancies in patients with gastrointestinal stromal tumors. *Semin Diagn Pathol* 2006; **23**: 120-129. [PMID: 17193825]
- 15 Chung JC, Chu CW, Cho GS, Shin EJ, Lim CW, Kim C, Song OP. Management and outcome of gastrointestinal stromal tumor of the duodenum. *J Gastrointestinal Surgery* 2010; **14**: 880-883. [PMID: 20140534; DOI: 10.1007/s11605-010-1170-6]
- 16 Winfield RD, Hochwald SN, Vogel SB, Hemming AW, Liu C, Cance WG, Grobmyer SR. Presentation and management of gastrointestinal stromal tumors of the duodenum. *Am Surg* 2006; **72**: 719-723. [PMID: 16913316]
- 17 Hoepfner J, Kulemann B, Marjanovic G, Bronsert P, Hopt UT. Limited resection for duodenal gastrointestinal stromal tumors: management and clinical outcome. *World J Gastroint est Surg* 2013; **5**: 16-21. [PMID: 23515427; DOI: 10.4240/wjgs.v5.12.16]
- 18 Acar F, Sahin M, Ugras S, Calisir A. A gastrointestinal stromal tumor of the third portion of the duodenum treated by wedge resection: A case report. *World J Gastroint est Surg* 2013; **5**: 332-336. [PMID: 24392185; DOI: 10.4240/wjgs.v5.i12.332]

Peer reviewer: Daniel Neureiter