

## Eight-Year Long-Term Survival of an Advanced Gastric Cancer Patient Treated by Multidisciplinary Therapy Including Repeated Surgery and Metronomic Chemotherapy

Takahisa Fujikawa, Yasunori Yoshimoto, Akira Tanaka

Takahisa Fujikawa, Yasunori Yoshimoto, Akira Tanaka, Department of Surgery, Kokura Memorial Hospital, Kitakyushu, Fukuoka 802-8555, Japan

**Conflict-of-interest statement:** The author(s) declare(s) that there is no conflict of interest regarding the publication of this paper.

**Open-Access:** This article is an open-access article which was selected by an in-house editor and fully peer-reviewed by external reviewers. It is distributed in accordance with the Creative Commons Attribution Non Commercial (CC BY-NC 4.0) license, which permits others to distribute, remix, adapt, build upon this work non-commercially, and license their derivative works on different terms, provided the original work is properly cited and the use is non-commercial. See: <http://creativecommons.org/licenses/by-nc/4.0/>

**Correspondence to:** Takahisa Fujikawa, MD, PhD, FACS, Department of Surgery, 3-2-1 Asano, Kokurakita-ku, Kitakyushu, Fukuoka 802-8555, Japan.

Email: [fujikawa-t@kokurakinen.or.jp](mailto:fujikawa-t@kokurakinen.or.jp)

Telephone: +81-93-511-2000

Fax: +81-93-511-3240

Received: September 12, 2016

Revised: December 20, 2016

Accepted: December 23, 2016

Published online: February 21, 2017

### ABSTRACT

A 69-year-old male, who had gastric cancer with extensive intra-abdominal lymph node metastasis, received palliative distal gastrectomy. He underwent repeated resection of metachronous right and left adrenal metastatic lesions 2 years and 5.3 years after the initial operation, respectively. The patient also experienced right femoral bone metastasis and IVC tumour thrombus 2.9 years and 6.6 years after the initial surgery, which were treated by radiation therapy. The slowly progressive tumour status was maintained by continuation of metronomic chemotherapy including S-1 as a key drug, and a total of 8-year long-term survival was achieved. Although rare, some selected patients with advanced gastric cancer have a chance of long-term survival, like the current case. The efficacy of

multidisciplinary therapy for far advanced gastric cancer patients, especially an important role of repeated surgery and metronomic chemotherapy, was discussed.

**Key words:** Advanced gastric cancer; Distant metastasis; Long-term survival; Multidisciplinary therapy; Repeated surgery; Metronomic chemotherapy

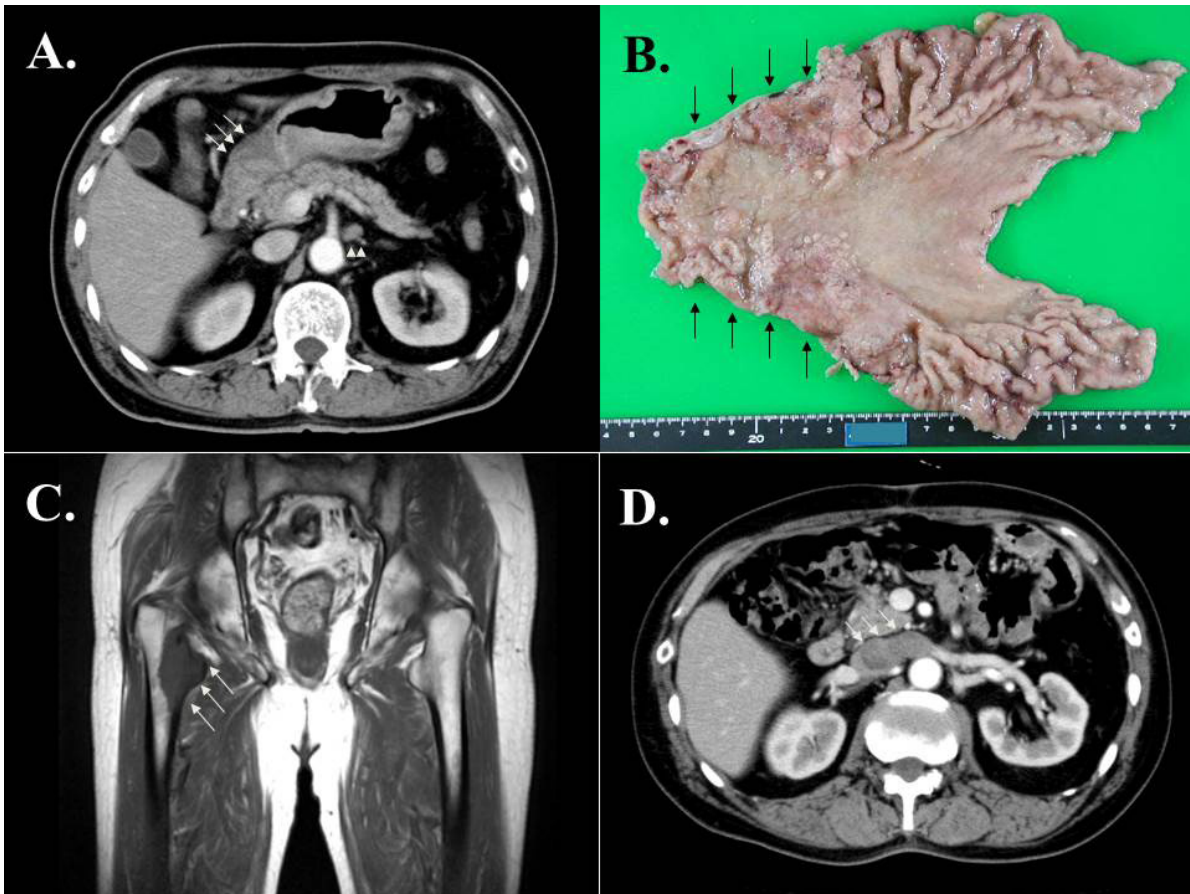
© 2017 The Author(s). Published by ACT Publishing Group Ltd. All rights reserved.

Fujikawa T, Yoshimoto Y, Tanaka A. Eight-Year Long-Term Survival of an Advanced Gastric Cancer Patient Treated by Multidisciplinary Therapy Including Repeated Surgery and Metronomic Chemotherapy. *Journal of Gastroenterology and Hepatology Research* 2017; **6(1)**: 2300-2302 Available from: URL: <http://www.ghrnet.org/index.php/joghr/article/view/1844>

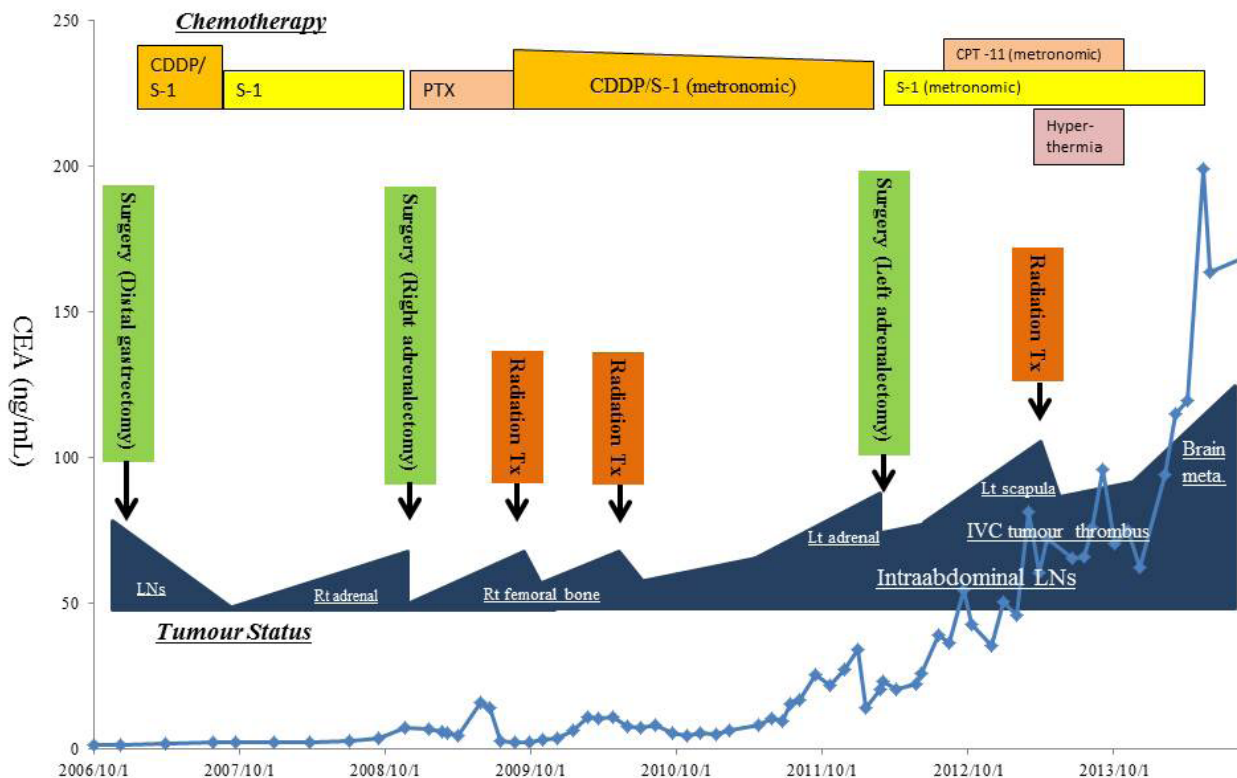
### LETTER TO THE EDITOR

A 69-year-old Japanese gentleman was admitted to a hospital for general malaise. He was diagnosed with advanced gastric cancer with extensive lymph node metastasis by upper gastrointestinal fiberoptic endoscopy and enhanced CT scan (Figure 1A). He underwent palliative distal gastrectomy to avoid progressive GI bleeding, and microscopic examination revealed moderately differentiated tubular adenocarcinoma infiltrating the serosa with extraordinary lymphatic permeations (Figure 1B), accompanied by extensive regional lymph node involvement. Postoperative course was uneventful, and the patient recovered without any complications. He subsequently received three courses of cisplatin/S-1 (CS) combination chemotherapy and complete response was achieved. The stable tumour status was maintained by oral S-1 administration, although solitary right adrenal metastasis was detected and surgically resected 2 years after the initial operation. Postoperative chemotherapy using paclitaxel was introduced and well-tolerated for 9 months until peripheral neuropathy developed. Subsequently, the right femoral bone metastasis was developed 2.9 years after the initial operation (Figure 1C), which was treated by repeated radiation therapy and CS chemotherapy.

The stable tumour status was kept thereafter by continuation of 80% dose of CS chemotherapy, but the left adrenal metastasis



**Figure 1** (A) Enhanced CT scan of the abdomen revealed severely thick wall of the stomach (arrows) with extensive regional lymph node swelling (arrow heads). (B) Gross specimen of the resected distal stomach showed irregular wall thickness involving the antrum. (C) MR images 2.9 years after the initial operation showed right femoral bone metastasis (arrows), which was treated by radiation therapy. (D) Enhanced CT scan 6.6 years after the initial operation revealed tumour thrombus in the inferior vena cava and left renal vein (arrows).



**Figure 2** The whole clinical course of the current patient with serial changes in serum CEA values. Abbreviations: CDDP: cisplatin; PTX: paclitaxel; CPT-11: irinotecan; Tx: therapy; LNs: lymph nodes; Rt: right; Lt: left; IVC: inferior vena cava; meta.: metastasis.

was developed 5.3 years after the initial operation, and again surgically resected. Because the patient's performance status was deteriorated postoperatively, metronomic chemotherapy consisting of bi-daily administration of 60% dose of S-1 was started, and monthly administration of 80% dose of irinotecan was later added. The disease status was slowly progressive but stable without any symptom, when the left scapula metastasis and IVC tumour thrombus were obvious 6.6 years after the initial operation (Figure 1D). Both metastatic lesions were treated by radiation therapy combined with hyperthermia, and partial response was achieved. Slowly progressive tumour status was maintained for additional one year by continuation of metronomic S-1/irinotecan chemotherapy. The patient's performance status was deteriorated due to pneumonia and sepsis 7.2 years after the initial operation, and only metronomic S-1 monotherapy was continued thereafter. Finally, brain metastasis and intractable pleural empyema developed 7.6 years after the initial operation, resulting in discontinuation of chemotherapy, and the patient expired 8 years after the initial operation (Figure 2).

Gastric cancer is the fourth most commonly diagnosed cancer and the second most common cause of cancer-related death worldwide, and most patients present with advanced and/or metastatic diseases except in East Asia<sup>[1]</sup>. The effect of resecting metastatic tumours from gastric cancer is limited because metastasis from gastric cancer is considered to present as multiple recurrence or peritoneal dissemination<sup>[2]</sup>. Some selected patients with advanced and metastatic gastric cancer may have a chance of long-term survival thanks to recent advances in multimodal therapy including surgery, radiation therapy and chemotherapy<sup>[3]</sup>, although an 8-year long-term survival case of far advanced gastric cancer, like the current case, is extremely rare. In our case, maintenance of modulated metronomic chemotherapy and the timing of repeated surgery and radiation therapy were of paramount importance to achieve long-term survival with favourable quality of life. The metronomic chemotherapy, defined as frequent or continuous administration of conventional cytotoxic drug in comparatively low doses over extended periods with no prolonged breaks, has the potential benefit not only by achieving significantly reduced toxicity compared to

maximum tolerated chemotherapy, but also by keeping stable tumour status via optimisation of the antiangiogenic properties of cytotoxic drugs<sup>[4-6]</sup>. In advanced or metastatic gastric cancer patients with relatively poor performance status, the use of oral fluoropyrimidines as metronomic chemotherapy, such as S-1, capecitabine or UFT, seems to be potentially beneficial<sup>[4]</sup>. In the current case, metronomic chemotherapy using S-1 as a key drug could offer an over 5-year long-term survival, as well as a favourable quality of life without any severe symptoms.

## REFERENCES

1. Kamangar F, Dores GM, Anderson WF. Patterns of cancer incidence, mortality, and prevalence across five continents: defining priorities to reduce cancer disparities in different geographic regions of the world. *J Clin Oncol* 2006; **24**: 2137-50. [PMID: 16682732]; [DOI: 10.1200/JCO.2005.05.2308]
2. Ishii T, Ikegami N, Hosoda Y, Koide O, Kaneko M. The biological behaviour of gastric cancer. *J Pathol* 1981; **134**: 97-115. [PMID: 6265613]; [DOI: 10.1002/path.1711340202]
3. Kong F, Qi Y, Liu H, Gao F, Yang P, Li Y, Jia Y. Surgery combined with chemotherapy for recurrent gastric cancer achieves better long-term prognosis. *Clin Transl Oncol* 2015; [Epub ahead of print]. [PMID: 26088414]; [DOI: 10.1007/s12094-015-1327-6]
4. Emmenegger U, Kerbel RS. Five years of clinical experience with metronomic chemotherapy: achievements and perspectives. *Onkologie* 2007; **30**: 606-8. [PMID: 26088414]; [DOI: 10.1007/s12094-015-1327-6]
5. Kerbel RS, Kamen BA. The anti-angiogenic basis of metronomic chemotherapy. *Nat Rev Cancer* 2004; **4**: 423-36. [PMID: 15170445]; [DOI: 10.1038/nrc1369]
6. Klement G, Baruchel S, Rak J, Man S, Clark K, Hicklin DJ, Bohlen P, Kerbel RS. Continuous low-dose therapy with vinblastine and VEGF receptor-2 antibody induces sustained tumour regression without overt toxicity. *J Clin Invest* 2000; **105**: R15-24. [PMID: 10772661]; [PMCID: PMC517491]; [DOI: 10.1172/JCI18829]

Peer reviewer: Fethi Derbel