

Hepatorenal Syndrome with Cirrhotic Cardiomyopathy: A Case Series of A New Approach for Re-refractory Patients

Luis Otávio Mocarzel, Débora Balduci Lima, Davi Gonçalves Dias, Pedro Gemal Lanzieri, Ronaldo Altenburg Gismondi

Luis Otávio Mocarzel, Débora Balduci Lima, Davi Gonçalves Dias, Pedro Gemal Lanzieri, Ronaldo Altenburg Gismondi, Department of Clinical Medicine, Antonio Pedro University Hospital, Fluminense Federal University, Rio de Janeiro, Brazil

Conflict-of-interest statement: The author(s) declare(s) that there is no conflict of interest regarding the publication of this paper.

Open-Access: This article is an open-access article which was selected by an in-house editor and fully peer-reviewed by external reviewers. It is distributed in accordance with the Creative Commons Attribution Non Commercial (CC BY-NC 4.0) license, which permits others to distribute, remix, adapt, build upon this work non-commercially, and license their derivative works on different terms, provided the original work is properly cited and the use is non-commercial. See: <http://creativecommons.org/licenses/by-nc/4.0/>

Correspondence to: Luis Otávio Mocarzel, Department of Clinical Medicine (MMC), Antonio Pedro University Hospital, Fluminense Federal University, Rua Marques do Parana, 303, 6th floor, Bairro Centro, Cidade Niteroi, RJ, Brazil.

Email: pedrogemal@id.uff.br
Telephone: +55-21-26299210

Received: October 16, 2016

Revised: January 30, 2017

Accepted: February 2, 2017

Published online: April 21, 2017

ABSTRACT

Cirrhosis is a common disease that may be complicated with multiple organ dysfunctions, including a progressive deterioration of cardiac and renal function. Hepatorenal syndrome (HRS) is defined as potentially reversible renal failure in patients with liver cirrhosis and ascites. Cirrhotic cardiomyopathy (CCM) is a chronic cardiac dysfunction in cirrhosis in the absence of known cardiac disease. An association between CCM and HRS is suggested in cases of advanced cirrhosis that are nonresponsive to the usual therapies for HRS. We report four cases of patients with severe liver cirrhosis in

different evolutionary stages of CCM who were diagnosed with HRS type I refractory to usual protocols. In these scenarios, a positive inotropic drug was temporarily used in an attempt to reverse the worsening of renal function. This case series may suggest a treatment with efficacy for refractory HRS, although randomized controlled studies are needed to confirm this hypothesis.

Key words: Liver cirrhosis; Hepatorenal syndrome; Cirrhotic cardiomyopathy

© 2017 The Author(s). Published by ACT Publishing Group Ltd. All rights reserved.

Mocarzel LO, Lima DB, Dias DG, Lanzieri PG, Gismondi RA. Hepatorenal Syndrome with Cirrhotic Cardiomyopathy: A Case Series of A New Approach for Re-refractory Patients. *Journal of Gastroenterology and Hepatology Research* 2017; **6(2)**: 2344-2348 Available from: URL: <http://www.ghrnet.org/index.php/joghr/article/view/1901>

INTRODUCTION

Cirrhosis is a common disease that may be complicated with multiple organ dysfunctions^[1]. It is more prevalent in males, mainly in those over the age of 50. In Brazil, it has a prevalence of up to 0.35% in the general population, and reports from the US suggest that the health care costs may be double for patients with cirrhosis compared to non-cirrhotics^[2]. During the course of cirrhosis, there is a progressive deterioration of cardiac and renal function, which are systemic complications of the disease^[3].

Hepatorenal syndrome (HRS) is defined as a potentially reversible renal failure in patients with liver cirrhosis and ascites^[4]. Cirrhotic cardiomyopathy (CCM) is a chronic cardiac dysfunction in the absence of other known cardiac disease^[5]. Recently, an association between HRS and CCM has been suggested^[6]. The activation of Renin-Angiotensin-Aldosterone System (RAAS) and the hyperactivated adrenergic state of HRS lead to a hyperdynamic state, with a consequent increase in cardiac demand that is suppressed by its blunted state; i.e., the heart becomes unable to maintain satisfactory inotropic response to this stress^[7].

We report four clinical cases of patients with severe liver cirrhosis in different evolutionary stages of CCM who were diagnosed with HRS type I refractory to usual protocols^[8,9]. In these scenarios, a positive inotropic drug was temporarily used in an attempt to reverse the worsening of renal function.

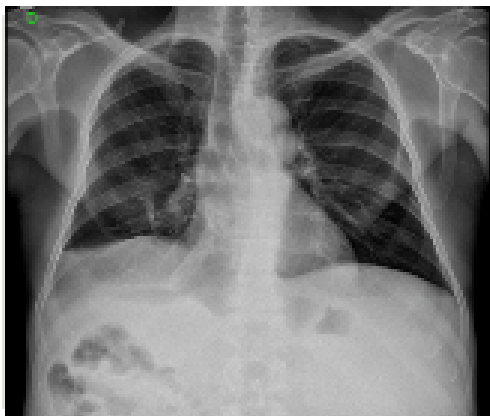CASE 1

A 63-year-old Caucasian male presented with a history of hepatic cirrhosis related to alcohol and hepatitis C virus infection; he had been diagnosed nine years previously, with admissions in the past due to the decompensation of cirrhosis. He was admitted to the emergency room (ER) with a three-day history of fever, progressive worsening dyspnea up to orthopnea, and abdominal distention with a diffuse pain. Spontaneous bacterial peritonitis was confirmed by a diagnostic and therapeutic paracentesis, and despite appropriate treatment with antibiotics, albumin and noradrenaline, he worsened acute kidney injury, with increases in the blood urea nitrogen and creatinine up to 2.28 mg/dL and reduced urinary output. An ecdoplercardiogram (Echo) was performed and showed an ejection fraction of 62.3% (Simpson's method) and a global longitudinal strain of 29%. The N-terminal pro b-type natriuretic peptide (NT pro-BNP) was 444 pg/dL (normal value: up to 135 pg/dL). The patient resumed diuresis 12 hours after dobutamine was started as an adjuvant therapy to refractory HRS. The urine output increased, and the se-

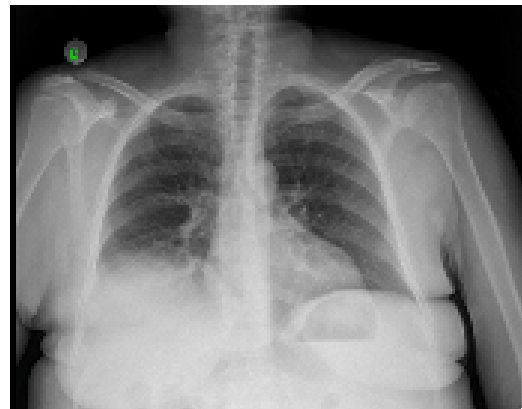
rum creatinine decreased to 1.25 mg/dL. The patient was discharged after fifteen days.

CASE 2

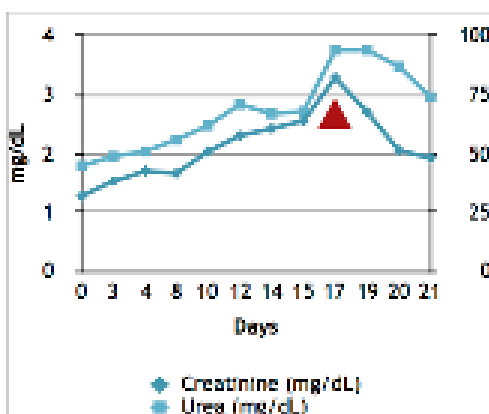
This 46-year-old Afrodescendant woman presented with a history of cryptogenic hepatic cirrhosis that had been diagnosed one year previously. She was admitted to our hospital with a three-week history of progressive edema evolving to anasarca, postprandial fullness, jaundice and acholic feces. There were clinical signs of malnutrition, pallor, and voluminous ascites. The cardiovascular evaluation and jugular venous pressure were normal. The chest x-ray showed a normal cardiac area with no signs of congestion and small pleural effusion on right side. The echo showed otherwise normal ejection fraction (Simpson's) and normal cavity diameters. A paracentesis was diagnostic of spontaneous bacterial peritonitis, and the initial treatment was based on albumin and octreotide administration, following HRS protocols. Nevertheless, the patient evolved to anuria and azotemia. Given this unfavorable scenario, dobutamine was introduced as a rescue therapy. There was a progressive improvement of renal function, increased urine output and reduction of creatinine in the following days. Treatment with dobutamine lasted four days. Upon the discontinuation of inotropic, renal function recovered to its initial state and remained stable. The patient was discharged for outpatient follow up.



A. Small pleural effusion and CTI of 0.50.



B. Bilateral small pleural effusion and CTI of 0.57.



C. Urea and creatinine curves during internation. Arrow indicates when dobutamine was started.

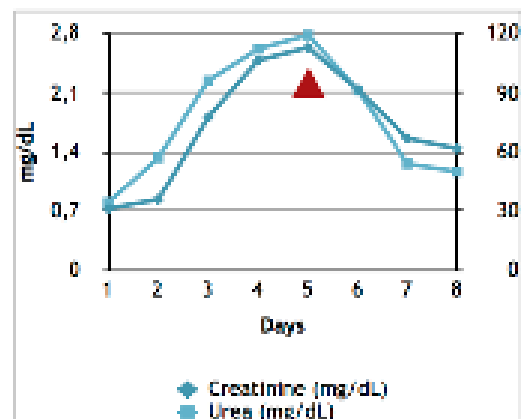


Figure 1 Clinical and radiologic presentations of different evolutionary atages of cirrhotic cardiomyopathy. Case 1 and 2 showed to be responsive to dobutamine treatment.

CASE 3

A 71-year-old Caucasian male presented with a one-month history of altered mental status and anasarca. He had a history of chronic hepatitis C viral infection and alcohol use. On the physical examination, he was pale and dehydrated, with diminished breath sounds at the right lower base and crackles in the left base, an irregular heart rhythm, and the presence of ascites and lower limb edema. The chest image showed bilateral pleural effusions, the NT pro-BNP was 3000 pg/dL and the Echo revealed mild diastolic dysfunction. He evolved with hypotension and oliguria, elevation of the urea and creatinine not responsive to a saline infusion and usual treatment for HRS with albumin and noradrenaline. Despite the diagnosis of cardiomyopathy, he also did not respond to dobutamine and hemodialysis was initiated. The patient improved and was discharged but became dependent on dialysis.

CASE 4

A 59-year-old woman had been diagnosed with hepatitis C-related cirrhosis 9 years previously and was currently on antiviral therapy with sofosbuvir 400 mg s.i.d, daclatasvir 60 mg s.i.d and ribavirin 500 mg b.i.d, on week 12 of treatment. She presented to the ER complaining of weight gain and limb edema. On admission, she had respiratory discomfort and reduced urinary output. The chest image showed an enlarged cardiothoracic index (CTI), bilateral pleural ef-

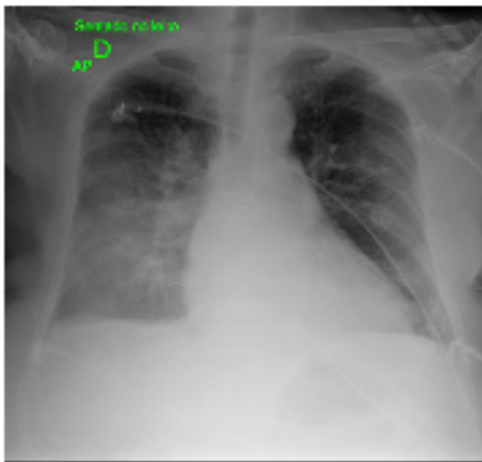
Table 1 Baseline clinical and laboratory characteristics upon admission.

	Case 1	Case 2	Case 3	Case 4
Sex and age (years)	♂, 63	♀, 46	♂, 71	♀, 59
Urinary output (mL/Kg/h)	0.7	1	0.5	0.3
Urea (g/dL)	119	94	151	91
Creatinine (g/dL)	2.6	3.2	2.6	2.2
Total Bilirubin (µmol/l)	200.1	243.2	26.8	234.4
International normalized ratio	1.9	2.3	1.4	4.0
Albumin (g/L)	20	18	15	15
Serum K (mEq/L)	4.1	4.5	5.1	3.3
Serum Na (mEq/L)	139	134	133	137

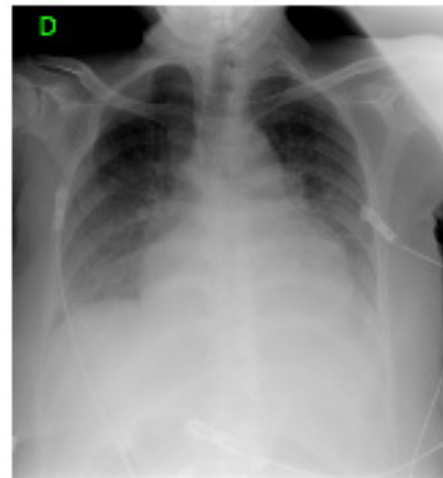
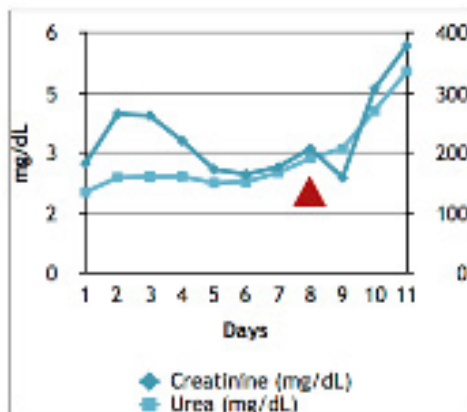
Table 2 Laboratory findings after treatment with Dobutamine.

	Case 1	Case 2	Case 3
Urea (g/dL)	50	74	336
Creatinine (g/dL)	1.44	1.93	5.68
Urinary output (mL/Kg/h)	1.7	1.9	0.7

fusions and signs of pulmonary edema, the NT pro-BNP was up to 5000 pg/dL and the ecodopplercardiogram revealed systolic dysfunction and mild pulmonary hypertension. The patient was nonresponsive to the usual treatment for HRS or a dobutamine infusion and died during the hospitalization.



Mild congestion and CTI of 0.60.



Severe pulmonary congestion and CTI of 0.67.

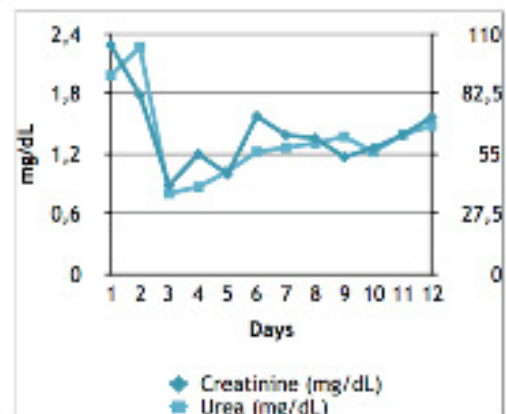


Figure 1(cont) Case 3 and 4 showed not to be responsive to dobutamine treatment.

DISCUSSION

In the present study, we report four cases of patients with liver cirrhosis complicated with HRS in which CCM was identified. The standard treatment of HRS was started: correction of the precipitating factor and intravenous albumin on the first and third days of treatment, associated with continuous vasopressor infusion; however, no satisfactory response was achieved. In this context of progressive deterioration of renal function, CCM was identified as a factor to be corrected; therefore, dobutamine was used to increase cardiac output and renal perfusion.

HRS is a complication of portal hypertension in cirrhotic patients with ascites. Its association with bacterial translocation leads to the release of inflammatory mediators that generate splanchnic and systemic vasodilation^[10]. This leads to a decrease in systemic vascular resistance, hypotension and hypovolemia and, consequently, adrenergic and RAAS hyperactivation. These changes lead to renal failure, with elevated serum creatinine and decreased glomerular filtration rate (GFR), thus developing the HRS^[8].

In this setting, there is an increase in cardiac output (CO) in an attempt to maintain an adequate organ perfusion, leading to a hyperdynamic state and the release of factors that may ultimately lead to a blunted myocardial adaptation. The effects of nitric oxide, carbon monoxide and endogenous cannabinoids to cardiomyocytes may play a role in the pathogenesis of heart failure in this scenario^[11,12]. As a final result, the patient evolves with systolic failure and a low perfusion of organs such as kidney, with decreases in renal perfusion and in glomerular filtration rate, which contributes to the appearance of HRS^[10]. Dobutamine is a catecholamine that acts as a positive inotrope on beta receptors, increasing myocardial contractility and enhancing cardiac output^[13]. Because cirrhotic patients may develop a beta-adrenergic resistance^[14], our group has been studying CCM presentation in HRS based on the evidence of a cardiac component that worsens the prognosis of HRS. We are currently trying to find the most appropriate time to initiate dobutamine so it can benefit cirrhotic patients with HRS and signs of CCM. Dobutamine can prevent the progression of the disease if it is initiated early in the course of the decompensation, e.g., immediately after standard therapy shows ineffectiveness^[6].

In the reported cases, HRS was diagnosed by the decrease in GFR in the absence of shock and nephrotoxic medications, with no improvement in renal function after diuretic withdrawal and expansion of plasma volume and with no signs of intrinsic parenchymal disease.

In cases 1 and 2, there was no response to the HRS treatment, with no decrease in creatinine after volume expansion with albumin and vasopressors^[6,15]. In this setting, the increase of NT pro-BNP in the absence of severe signs of congestion on chest radiography suggested cardiac involvement at an initial stage. Both patients received short courses of intravenous dobutamine and exhibited improvements in renal function, as evidenced by the decrease in creatinine, in the following days.

In cases 3 and 4, HRS was diagnosed early and treated but did not achieve satisfactory results because signs of severe heart failure (pulmonary edema, cardiomegaly and higher NT pro-BNP levels) were present. The clinical setting of more congestion and more compromised heart function played a role in their responses to the inotrope. Specifically, the patient in case 4 had advanced heart failure signs and pulmonary congestion, which led to no response to dobutamine nor dialysis, evolving to death in the following days.

The four cases suggest that the influence of CCM on HRS presentation may have a progressive aspect, as seen in figure 1. There is

a marked progression of signs of heart failure in chest radiographs, with an increasing size of heart chambers and cardiothorax index and more prominent pleural effusions. Evidence-based interventions suggest that the earlier the identification and heart treatment occur, the greater the chances of a favorable prognosis are.

This case series may not bring a definitive answer to the use of inotropic agents in cirrhosis, but it might suggest that the cardiac component must always be considered and treated. Pathophysiological evidence points towards a cardiac impairment in cirrhotic patients that contributes to HRS, and the challenge is to find the clinical applicability of this knowledge. The use of inotropes, particularly dobutamine, showed favorable results in two of the four cases described. The best results were obtained when CCM was in the early stages, before it evolved to advanced systolic dysfunction and pulmonary congestion. Because we know that as the CCM gets worse, the chance of an adverse prognosis increases, clinical observations indicate that the earlier a non-response to baseline treatments of HRS and the CCM intervention occur, the higher the chance of it reverting is. Although this study has limitations – it is observational, and there was no control group because CCM is a rare condition and has a low prevalence that makes difficult to randomize – it still has the power of evidence.

The diagnosis of CCM must always be considered in patients in whom HRS progresses unfavorably with no adequate response to clinical therapy. Once identified, the appropriate intervention in the course of the disease must be defined. We observed that the earlier the diagnosis of CCM occurs, the better the prognosis is; on the other hand, in patients with severe pulmonary congestion and cardiomegaly, the prognosis still tends to be reserved.

CONCLUSION

An association between CCM and HRS is suggested in advanced cirrhosis that shows a non-response to the usual therapy targeted to HRS. In those who do not respond and exhibit early signs of associated cardiac dysfunction, the use of inotropes may be an option to optimize CO and improve kidney function. This case series may suggest a treatment effective for refractory HRS, although randomized controlled studies are needed to confirm this hypothesis.

Ethical Statement

This subject was obtained with informed consent under institutional review board-approved protocols.

REFERENCES

1. Kowalski HJ, Abelmann WH. The cardiac output at rest in Laennec's cirrhosis. *J Clin Invest.* 1953; 32(10): 1025–33. [PMID: 13096569]; [DOI: 10.1172/JCI102813]
2. Carvalho JR De, Portugal FB, Flor LS, Campos MR, Schramm JMDA. Método para estimação de prevalência de hepatites B e C crônicas e cirrose hepática. *Epidemiol e Serviços Saúde.* 2014; 23(4): 691–700. [DOI: 10.5123/S1679-49742014000400011]
3. Schuppan D, Afdhal NH. Liver cirrhosis. *Lancet.* 2008; 371(9615): 838–51. [PMID: 18328931]; [DOI: 10.1016/S0140-6736(08)60383-9]
4. Møller S, Henriksen JH, Bendtsen F. Extrahepatic complications to cirrhosis and portal hypertension: Haemodynamic and homeostatic aspects. *World J Gastroenterol.* 2014; 20(42): 15499–517. [PMID: 25400435]; [DOI: 10.3748/wjg.v20.i42.15499]
5. Ruiz-del-Árbo L, Serradilla R. Cirrhotic cardiomyopathy. *World J Gastroenterol.* 2015 Nov 7; 21(41): 11502–21. [PMID: 26556983]; [DOI: 10.3748/wjg.v21.i41.11502]

6. Mocarzel L, Lanzieri P, Nascimento J, Peixoto C, Ribeiro M, Mesquita E. Hepatorenal syndrome with cirrhotic cardiomyopathy: case report and literature review. *Case reports Hepatol.* 2015; 2015: 573513. [PMID: 25874140]; [DOI: 10.1155/2015/573513]
7. Møller S, Bendtsen F. Cirrhotic Multiorgan Syndrome. *Dig Dis Sci.* 2015 Nov; 60(11): 3209–25. [PMID: 26112989]; [DOI: 10.1007/s10620-015-3752-3]
8. Arroyo V, Gin PS, Gerbes AL, Dudley FJ, Gentilini P, Laffi G, et al. Definition and Diagnostic Criteria of Refractory Ascites and Hepatorenal Syndrome in Cirrhosis. *Hepatology.* 1996 Jan; 23(1): 164-76. [PMID: 8550036]; [DOI: 10.1002/hep.510230122]
9. Bonder A, Botero ML, Cardenas A. Current Therapies for Hepatorenal Syndrome. *Curr Hepatol Reports.* 2014 Mar 1; 13(1): 74–80. [DOI: 10.1007/s11901-014-0217-7]
10. Heidelberg JJ, Sherbondy M. Cirrhosis and chronic liver failure: Part II. Complications and treatment. *Am Fam Physician.* 2006 Sep 1; 74(5): 767-776. [PMID: 16970020]
11. Licata A, Novo G, Colomba D, Tuttolomondo A, Galia M, Camma C. Cardiac involvement in patients with cirrhosis: a focus on clinical features and diagnosis. *J Cardiovasc Med.* 2016 Jan; 17(1): 26–36. [PMID: 26065511]; [DOI: 10.2459/JCM.0000000000000288]
12. Horvatits T, Drolz A, Rutter K, Roedl K, Kluge S, Fuhrmann V. Hepatocardiac disorders: Interactions between two organ systems. *Med Klin Intensivmed Notfmed.* 2016 Jun; 111(5): 447-52. [PMID: 26070920]; [DOI: 10.1007/s00063-015-0043-x]
13. Hunt SA, Abraham WT, Chin MH, Feldman AM, Francis GS, Ganiats TG, et al. Guideline Update for the Diagnosis and Management of Chronic Heart Failure in the Adult: A Report of the American College of Cardiology/American Heart Association Task Force on Practice Guidelines. *Circulation.* 2005; 112(12): e154–235. [PMID: 16168273]; [DOI: 10.1016/j.jacc.2005.08.022]
14. Wiese S, Hove JD, Bendtsen F, Møller S. Cirrhotic cardiomyopathy: pathogenesis and clinical relevance. *Nat Rev Gastroenterol Hepatol.* 2014 Mar 11(3): 177–86. [PMID: 24217347]; [DOI: 10.1038/nrgastro.2013.210]
15. Mocarzel LO, Bicca J, Jarske L, Oliveira T, Lanzieri P, Gismondi R, Ribeiro ML. Cirrhotic Cardiomyopathy: Another Case of a Successful Approach to Treatment of Hepatorenal Syndrome. *Case Rep Gastroenterol.* 2016 Oct 10; 10(3): 531-537. [PMID: 27843430]; [DOI: 10.1159/000448885]

Peer reviewer: Neda Svirtlih