

Combination of Modified Pinch-Burn-Cut (PBC) Technique and Harmonic FOCUS® for Pancreaticoduodenectomy under Preoperative Continuation of Antiplatelets in High Thromboembolic Risk Patients

Takahisa Fujikawa, Yasunori Yoshimoto, Hiroshi Kawamoto, Akira Tanaka

Takahisa Fujikawa, Yasunori Yoshimoto, Hiroshi Kawamoto, Akira Tanaka, Department of Surgery, Kokura Memorial Hospital, Kitakyushu, Fukuoka 802-8555, Japan

Conflict-of-interest statement: The author(s) declare(s) that there is no conflict of interest regarding the publication of this paper.

Open-Access: This article is an open-access article which was selected by an in-house editor and fully peer-reviewed by external reviewers. It is distributed in accordance with the Creative Commons Attribution Non Commercial (CC BY-NC 4.0) license, which permits others to distribute, remix, adapt, build upon this work non-commercially, and license their derivative works on different terms, provided the original work is properly cited and the use is non-commercial. See: <http://creativecommons.org/licenses/by-nc/4.0/>

Correspondence to: Takahisa Fujikawa, MD, PhD, FACS, Department of Surgery, 3-2-1 Asano, Kokurakita-Ku, Kitakyushu, Fukuoka 802-8555, Japan.

Email: fujikawa-t@kokurakinen.or.jp

Telephone: +81-93-511-2000

Fax: +81-93-511-3240

Received: January 5, 2017

Revised: January 23, 2017

Accepted: January 25, 2017

Published online: February 21, 2017

ABSTRACT

AIM: The aim of the study was to assess the safety and feasibility of pancreaticoduodenectomy (PD) using modified Pinch-Burn-Cut (PBC) technique and Harmonic FOCUS® under continuation of antiplatelet therapy in patients with high thromboembolic risks.

METHODS: Consecutive 78 patients who had undergone PD using combination of modified PBC technique and HF in a tertiary care setting from 2009 to 2016 were retrospectively reviewed. Among which 18 patients with high thromboembolic risks underwent preoperative

aspirin continuation and were included in the study. Background and perioperative factors were described with detailed information, and the outcome variables of patients were compared between the pancreatic cancer patients (PC group) and those with the other diseases (non-PC group).

RESULTS: The current cohort included 8 patients in PC group and 10 in non-PC group, respectively. The major indication of APT was history of percutaneous coronary intervention for angina pectoris (15/18, 83.3%). The median of operative time and estimated blood loss were 482 min and 511 mL, respectively. There were no differences between the groups in the operative time, blood loss, or the rates of postoperative complications. None suffered from excessive bleeding requiring platelet transfusion intraoperatively, and there is no case with massive intraoperative bleeding ($\geq 1,000$ mL). Three minor Grade B post-pancreatectomy hemorrhage (PPH, 16.7%) and 2 Grade B postoperative pancreatic fistula (POPF, 11.1%) occurred postoperatively, but no patient suffered from Grade C PPH/POPF or thromboembolic complications. Operative mortality was zero.

CONCLUSION: PD using modified PBC technique and Harmonic FOCUS® can be performed safely and satisfactorily even in APT-burdened patients with high thromboembolic risks. Maintenance of single APT should be considered in patients with high thromboembolic risk, even when PD is performed.

Key words: Pancreaticoduodenectomy; Modified PBC technique; Harmonic FOCUS®; Antiplatelet therapy; Bleeding complication; Thromboembolic complication

© 2017 The Author(s). Published by ACT Publishing Group Ltd. All rights reserved.

Fujikawa T, Yoshimoto Y, Kawamoto H, Tanaka A. Combination of Modified Pinch-Burn-Cut (PBC) Technique and Harmonic FOCUS® for Pancreaticoduodenectomy under Preoperative Continuation of Antiplatelets in High Thromboembolic Risk Patients. *Journal of Gastroenterology and Hepatology Research* 2017; 6(1): 2279-2285 Available from: URL: <http://www.ghrnet.org/index.php/joghr/article/view/1950>

INTRODUCTION

Nowadays, a number of patients undergoing non-cardiac surgery have histories of cerebrovascular or cardiovascular diseases and receive antiplatelet therapy (APT). The perioperative antithrombotic management for these patients is often bothersome due to increased risks of both bleeding and thromboembolic complications^[1-4]. In our perioperative management of patients with high thromboembolic risks such as drug-eluting coronary stent implantation, the protocol included preoperative continuation of aspirin monotherapy and postoperative early reinstatement to prevent fatal postoperative thromboembolic complications (“Kokura Protocol”)^[5,6], and have demonstrated the feasibility and safety of abdominal surgeries, both in laparoscopic and open approach, using the Kokura Protocol^[5-7].

Pancreaticoduodenectomy (PD) is a highly invasive procedure and may expose the APT-received patients to high perioperative risks of either bleeding or thromboembolic complications. It is reported that surgical blood loss and intraoperative blood transfusion is the known risk factors for postoperative complications after PD^[8,9]. To minimize the surgical blood loss during PD, we use modified “Pinch-Burn-Cut” (PBC) technique (the technique for recipient’s operation in living-donor liver transplantation)^[10,11] in combination with ultrasonically activated shears with a curved thin tip [Harmonic FOCUS® (HF), Ethicon Endo-Surgery, Cincinnati, OH]^[12,13] especially in antiplatelet-burdened patients with high thromboembolic risks. The aim of the study was to assess the safety and feasibility of PD using combination of modified PBC technique and HF under continuation of antiplatelet therapy in patients with high thromboembolic risks.

MATERIALS AND METHODS

Patients

Between May 2009 and April 2016, a total of 78 patients underwent PD at our institution. APT was regularly used in 26 patients, among which 18 consecutive patients undergoing PD under preoperative continuation of aspirin monotherapy due to high thromboembolic risks were included in the current study. Surgical procedures included subtotal stomach-preserving PD in 17 and conventional PD in 1 patient. All procedures were performed by or under the guidance of one of the attending surgeons at our institution.

Background, perioperative, and outcome variables were obtained through the standardized electronic surgery database and the hospital charts. The status of patients’ symptoms and functions with respect to ambulatory status and need for care was described according to the ECOG Scale of Performance Status (PS)^[14]. Postoperative complications were categorized and assessed using Clavien-Dindo classification (CDC)^[15] and CDC class II or higher was considered relevant. Postoperative pancreatic fistula (POPF) was defined according to the definition of the International Study Group of Postoperative Pancreatic Fistula (ISGPF)^[16]. Post-pancreatectomy hemorrhage (PPH) was defined according to the definition of the International Study Group of Pancreatic Surgery (ISGPS)^[17]; both POPF and PPH were classified into 3 different grades. Postoperative thromboembolic complication was defined as previously described^[5,6], including myocardial infarction, cerebral infarction, mesenteric infarction, and pulmonary thromboembolism. Operative mortality included death within 30 days after surgery.

Background and perioperative data were described with detailed information, and the outcome variables of patients were compared between the pancreatic cancer patients (PC group) and those with the other diseases (non-PC group). Continuous variables in

the characteristics were expressed as a median with range. The categorized data in each group were compared by chi-square or Fisher’s exact probability test. Continuous variables were compared by Student’s T test or Kruskal-Wallis test. Non-parametric variables were also compared using Kruskal-Wallis test. Statistical significance was set at $p < 0.05$. Data were analyzed using the SPSS package software.

This study was approved by our institutional review board.

Perioperative antithrombotic management

The perioperative antithrombotic management protocol for abdominal and general surgery have been established in our institution to manage thromboembolic risk patients (“Kokura Protocol”), and we have reported that the abdominal surgery in patients with antiplatelet therapy can be performed safely and satisfactorily under the Kokura Protocol without increase of bleeding and thromboembolic complications^[5-7]. Briefly, the protocol consisted of interrupting APT one week before surgery and early postoperative reinstatement in low thromboembolic risk patients, and in case of high thromboembolic risks such as patients with drug-eluting coronary stent (DES) implantation or those with cerebrovascular reconstruction within 3 months, preoperative aspirin monotherapy was continued until surgery, followed by early postoperative reinstatement.

In patients with anticoagulation therapy such as warfarin, anticoagulation was substituted by bridging heparin in case of high thromboembolic risks. In patients using both APT and oral anticoagulation therapy, perioperative management of APT was also combined with those of anticoagulation therapy. For prevention of venous thromboembolism, mechanical prophylaxis (intermittent pneumatic compression and/or graduated compression stockings) and enforcement of early postoperative walking are generally performed, although routine use of medical prophylaxis with heparin is not adopted, except in case of high venous thromboembolic risk patients with previous venous thrombosis or immobilization.

Technical aspects of PD procedure

Our most prevalent type of the operative procedure is subtotal stomach-preserving PD. The procedure consists of (1) exposure of the portal vein (PV) and dissection of the lymph node (LN) around superior mesenteric vein (SMV); (2) Kocherization; (3) skeletonization of the hilar vessels and LN dissection of the hepatoduodenal ligament; (4) transection of the stomach, jejunum and pancreatic neck; and (5) division of the connective tissue and nerve plexus beneath the pancreatic head, LN dissection of the left-side of the superior mesenteric artery (SMA), and removal of the surgical specimen.

The reconstruction is undertaken in retrocolic fashion and anastomosed with choledochojejunostomy, followed by pancreaticojejunostomy and gastrojejunostomy. The pancreaticojejunostomy is executed using modified Blumgart anastomosis with internal lost-tube stent or with external duct stenting^[18]. The gastrojejunostomy and Braun anastomosis are performed antecolically using autosuture devices.

During dissection of the tissue under preoperative continuation of antiplatelet therapy, the combination of modified PBC technique and use of HF is generally applied to reduce intraoperative blood loss (Figure 1). In the PBC technique, a small amount of soft tissue at the dissection plane is pinched with a fine-tipped forceps, and the tissue is coagulated by supplying an electric current by touching it with a monopolar electrocautery until the tissue is cut^[10,11]. Our modified technique for PBC is that the main operator uses monopolar electrocautery in the right hand instead of forceps. Meticulous

dissection is achieved by combination of a fine-tipped forceps in the left hand and right-sided electrocautery; dissecting and ‘pinching’ the tissue by the fine-tipped forceps (Figure 1A), ‘burning’ it by supplying an electric current via electrocautery touching (Figure 1B), and cutting it spontaneously or by electrocautery (Figure 1C). By using both fine-tipped forceps and monopolar electrocautery, tissue dissection and hemostasis are achieved faster. If the middle-sized vessels (1-3 mm in diameter) require to be dissected, HF (curved ultrasonic shears) is applied (Figure 1D). HF is the device developed for meticulous dissection such as LN dissection^[12,13]. With its curved tip and its lightness and small size, the device has the advantage when lymph node is dissected, especially in case of existing bleeding tendency. Suture ligation is limited only for dissection of a large

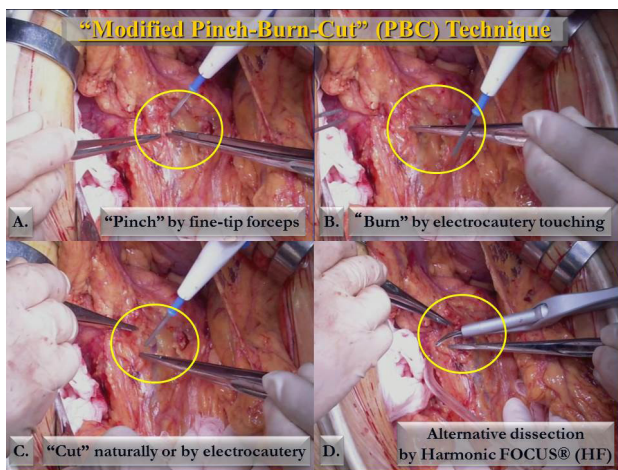


Figure 1 Technical aspect of combination of modified Pinch-Burn-Cut (PBC) technique and Harmonic FOCUS® (HF) use. Meticulous dissection is achieved by combination of forceps in the left hand and monopolar electrocautery in the right hand; dissecting and ‘pinching’ the tissue by fine-tipped forceps (Figure 1A), ‘burning’ it by supplying an electric current via electrocautery touching (Figure 1B), and cutting it spontaneously or by electrocautery (Figure 1C). If the middle-sized vessels (1-3 mm in diameter) require to be dissected, HF (curved ultrasonic shear) is applied (Figure 1D).

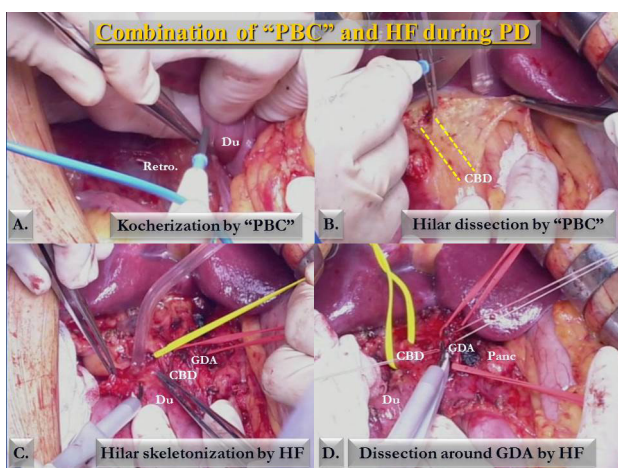


Figure 2 Procedures of pancreaticoduodenectomy using the combination technique of modified PBC technique and HF. After PV and SMV are exposed by the combination technique, modified PBC is mainly used during Kocherization and superficial dissection of the hepatoduodenal ligament (Figure 2A, 2B); subsequently HF is dominantly used for hilar skeletonization and LN dissection (Figure 2C, 2D). Abbreviations: PBC: Pinch-Burn-Cut; PD: pancreaticoduodenectomy; HF: Harmonic FOCUS®; Retro.: retroperitoneum; Du: duodenum; CBD: common bile duct; GDA: gastroduodenal artery; Panc: pancreas.

vascular structure (3 mm or larger).

Figure 2 and 3 shows PD procedures using the combination technique of modified PBC technique and HF. After PV and SMV are exposed by the combination technique, modified PBC is mainly used during Kocherization and superficial dissection of the hepatoduodenal ligament (Figure 2A, 2B); subsequently HF is dominantly used for hilar skeletonization and LN dissection (Figure 2C, 2D). Dissection around the gut is achieved using both devices, and transection of the pancreas is performed by HF (Figure 3A, 3B). Finally, division of the connective tissue and nerve plexus beneath the pancreatic head and LN dissection of the left-side of SMA is accomplished by ligation and sutures of the large vessel structures (3 mm or more) and by severing them using HF (Figure 3C).

RESULTS

Table 1 shows background and tumor characteristics of 18 included patients. The patients were totally Asian, with the median age of 68 years (range; 60-81 years), and the ratio of female/male was 5/13. The major indication of APT was history of percutaneous coronary intervention (PCI) for angina pectoris (15/18, 83.3%). All patients were categorized as high thromboembolic risk, and thus underwent PD under continuation of preoperative aspirin monotherapy. There were 8 patients with pancreatic cancer (PC group), whereas other 10 patients have other diseases (non-PC group). The median size of the tumor was 2.5 cm (range; 1.0-5.0 cm). All the patients’ PS states were grade 0 or 1.

Perioperative characteristics and postoperative morbidity in each group were demonstrated in Table 2. Age, gender, indication of APT was similar between the groups. For the texture of the remnant pancreas, ‘hard pancreas’ was more common in PC group, although the significant difference was not seen statistically between the groups. The median values of the operative time and estimated blood loss were 482 min (range; 320-576 min) and 511 mL (50-975 mL),

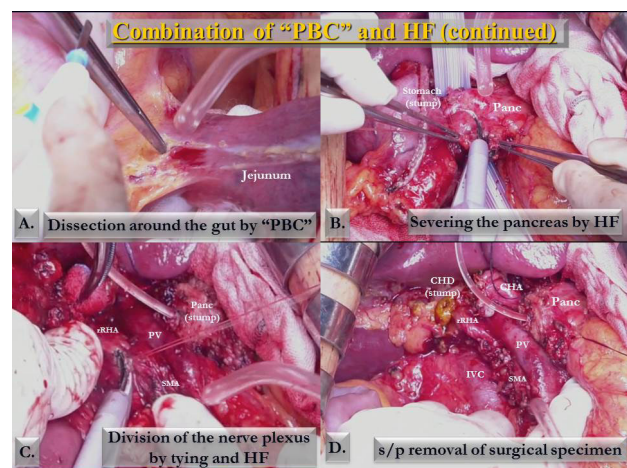


Figure 3 PD procedures using the combination technique of modified PBC technique and HF (continued). Dissection around the gut is achieved using both devices, and transection of the pancreas is performed by HF (Figure 3A, 3B). Finally, division of the connective tissue and nerve plexus beneath the pancreatic head and LN dissection of the left-side of SMA is accomplished by ligation and sutures of the large vessel structures (3 mm or larger) and by severing them using HF (Figure 3C). Figure 3D shows the status post removal of surgical specimen. In this case replaced right hepatic artery (rRHA) was branched from SMA. Abbreviations: PBC: Pinch-Burn-Cut; PD: pancreaticoduodenectomy; HF: Harmonic FOCUS®; rRHA: replaced right hepatic artery; PV: portal vein; CHD: common hepatic duct; CHA: common hepatic artery; IVC: inferior vena cava; SMA: superior mesenteric artery.

respectively. There were also no differences between the groups in the operative time, blood loss, or the rates of intraoperative red blood cell transfusion. No case suffering uncontrollable excessive intraoperative bleeding due to the continuation of APT was experienced, and platelet transfusion was not required in the current series. There is also no case with massive intraoperative bleeding ($\geq 1,000$ mL) in both groups.

Concerning the postoperative complications, the overall rate of complications was 38.9%. There was no difference between the groups in the rates of postoperative complications or length of postoperative stay. Two Grade B POPF (11.1%) and three Grade B PPH (16.7%, two intra-luminal and one extra-luminal) occurred postoperatively, but no patient suffered from Grade C PPH or POPF. There was no perioperative thromboembolic complication. Operative mortality was zero.

DISCUSSION

In the current paper, our technique during PD using combination

of modified PBC technique and HF were described in detail, and satisfactory perioperative outcome was demonstrated in 18 patients with preoperative continuation of aspirin monotherapy. Despite of single APT continuation, there is no case with excessive surgical blood loss of 1,000 mL or more, and no Grade C PPH was experienced. The duration of operation and surgical blood loss were identical between patients with and without pancreatic cancer, and the occurrence of both thromboembolic complication and operative mortality was zero.

APT for prevention of cardiovascular/cerebrovascular events is widely used^[19-21], and patients receiving APT often undergo surgical procedures. The incidence of post-PCI APT-burdened patients receiving non-cardiac surgery within 2 years is approximately 5-15%^[22]. Premature discontinuation of antiplatelet agents is the known risk factor for late coronary stent thrombosis, a rare but life-threatening complications^[21-23], therefore bleeding risk has to be balanced against thromboembolic risk in patients receiving APT. Current guidelines concerning endoscopic procedures or tooth extraction suggest that prevention of thromboembolism is more

Table 1 Background characteristics of patients in the included 18 patients.

No.	Age	Sex	Concurrent Disease	TE risk	Preop. ASA continuation	Disease	Size of the tumor (cm)
1	60	F	Post-CI	high	Yes	AC	1
2	62	M	AP (DES)	high	Yes	AC	2
3	64	M	AP (DES)	high	Yes	PC	2.5
4	81	M	AP (DES)	high	Yes	BDC	3.5
5	75	F	AP, CHF	high	Yes	PC	2.5
6	66	M	AP (BMS)	high	Yes	IPMA	5
7	81	M	AP (DES)	high	Yes	PC	3
8	63	M	Post-CI	high	Yes	PC	5
9	67	M	AP (BMS)	high	Yes	Chronic pancreatitis	2.5
10	79	M	Post-CI	high	Yes	AC	1.2
11	66	M	AP (DES)	high	Yes	AC	2
12	66	F	AP (BMS)	high	Yes	PC	1.5
13	76	F	AP (BMS)	high	Yes	BDC	2
14	75	M	AP (BMS)	high	Yes	AC	4
15	60	F	AP (DES)	high	Yes	PC	2.8
16	68	M	AP (DES)	high	Yes	PC	4
17	74	M	AP (BMS)	high	Yes	PC	2
18	70	M	AP (BMS)	high	Yes	AC	2.5

*Abbreviations: TE, thromboembolism; preop., preoperative; ASA, aspirin, F, female; M, male; CI, cerebral infarction; AP, angina pectoris; DES, drug-eluting coronary stent; CHF, congestive heart failure; BMS, non-drug-eluting bare metal stent; AC, ampullary cancer; PC, pancreatic cancer; BDC, bile duct cancer; IPMA, intraductal papillary mucinous adenoma.

Table 2 Perioperative and outcome factors between patients with pancreatic cancer and other diseases.

Characteristics	Total (n = 18)	PC group (n = 8)	non-PC group (n = 10)	p value
Age, y, median (range)	68 (60-81)	67 (60-81)	69 (60-81)	0.702
Gender (Female/Male), n (%)	5 / 13 (72.2)	3 / 5 (62.5)	2 / 8 (80.0)	0.087
Indication of APT, n (%)				0.056
Hx of PCI	15 (83.3)	7 (87.5)	8 (80.0)	
Hx of CI	3 (16.7)	1 (12.5)	2 (20.0)	
Texture of the remnant pancreas, n (%)				0.143
Soft pancreas	11 (61.1%)	4 (50.0%)	7 (70.0%)	
Hard pancreas	7 (38.9%)	4 (50.0%)	3 (30.0%)	
Duration of ope, min, median (range)	482 (320-576)	487 (350-536)	477 (320-576)	0.853
Surgical blood, loss, mL, median (range)	511 (50-975)	525 (100-960)	498 (50-975)	0.872
Intraoperative RBC transfusion, n (%)	5 (27.8%)	3 (37.5%)	2 (20.0%)	0.087
Postoperative complication, n (%)				
None	11 (61.1%)	4 (50.0%)	7 (70.0%)	0.143
POPF (grade B)	2 (11.1%)	1 (12.5%)	1 (10.0%)	0.345
PPH (grade B)	3 (16.7%)	2 (25.0%)	1 (10.0%)	0.055
Thromboembolic complication	0 (0.0%)	0 (0.0%)	0 (0.0%)	-
Operative mortality, n (%)	0 (0.0%)	0 (0.0%)	0 (0.0%)	-
Length of postop. stay, d, median (range)	26 (15-40)	26 (15-40)	25 (16-40)	0.651

*Abbreviations: PC, pancreatic cancer; APT, antiplatelet therapy; PCI, percutaneous coronary intervention; CI, cerebral infarction; ope., operation; RBC, red blood cell; POPF, postoperative pancreatic fistula; PPH, post-pancreatectomy hemorrhage; postop., postoperative.

crucial because it may cause severe postoperative life-threatening complications^[24-26]. According to the guidelines of post-PCI surgical procedures such as the guideline from American College of Cardiology/American Heart Association, continuation of APT, but not using heparin bridging, should be considered in the perioperative period, particularly in patients with high thromboembolic risks^[27-29]. In our institution, the rate of APT-burdened patients requiring major hepatobiliary and pancreatic surgery is as high as 30-40%, and the number is expected to be increasing. For this reason, we have established our own perioperative antithrombotic protocol ("Kokura Protocol"), and shown that performing abdominal surgery under continuation of preoperative aspirin monotherapy is safe and feasible^[5-7]. The current study also demonstrated that pancreaticoduodenectomy, a highly invasive surgical procedure, can be performed safely without any increase of surgical blood loss or severe PPH in the same situation.

Surgical blood loss and intraoperative blood transfusion have been reported to be the major risk factors for postoperative complications after PD^[8,9]. Furthermore, PPH after PD is a serious postoperative complication and is related to a high mortality rate of up to 60%^[30-32]. Therefore, suppression of intraoperative blood loss and PPH is an important goal when PD is performed, and various technical development has been introduced^[12,13,33]. In our institution, two distinctive technique and device were combined to minimize the surgical blood loss; modified PBC technique and use of HF.

PBC technique was introduced for recipient's operation during living-donor liver transplantation, using a fine-tipped monopolar forceps for tissue dissection^[10,11]. Since the recipient for liver transplantation has abundant fine collateral vessels in the ligaments around the liver due to severe portal hypertension, the surgical procedure is associated with increased bleeding tendency and is more difficult than other abdominal procedures. In consideration of performing PD, many patients suffered from obstructive cholangitis or pancreatitis and therefore rich fine vessels in the ligament or tissues are also encountered. In the PBC technique, a 3-4 mm of width around the tip of the forceps is coagulated before cutting and small collateral vessels in a dissection surface are easily controlled^[11]; thus this technique is suitable not only for recipient's operation in liver transplantation, but also for pancreaticoduodenectomy.

In addition to PBC technique, we use HF for dissection of middle-sized vessels (1-3 mm in diameter) instead of suture or ligation. HF is a ultrasonically activated shear with a curved thin tip, and due to its small size and light weight it is easily handled and is specifically designed for fine and delicate dissection such as LN dissection^[12,13]. Like other ultrasonic energy devices, it employs mechanical vibration for simultaneous coagulation and cutting by mechanical protein denaturing, and prompt bleeding control is achieved without suturing or ligation unless the vessel size is large (more than 3 mm in diameter). In patients receiving preoperative continuation of APT, activation and aggregation of platelets are inhibited and the process of thrombus formation in the cutting edge of the vessels is considered to be delayed. For this reason, Suture or ligation is exclusively applied for dissection of large vascular structures in APT-burdened patients. Otherwise, HF is desirable for meticulous dissection for the tissues with middle-sized vessels, and especially useful for dissecting the hepatoduodenal ligament as well as division of the nerve plexus beneath the pancreatic head, including the numerous small-to middle-sized vessels. We consider that even in APT-burdened patients, the combination of modified PBC technique and HF is one of the preferred technical options during PD to minimize surgical blood loss.

The current study has some limitations. It is a retrospective review from a single center, which lessens the efficacy of the conclusion. This limitation will be mitigated in a later follow-up study. Since we continue to manage high thromboembolic risk patients undergoing PD using the same operative policy and perioperative antiplatelet management, more patients will be accumulated to help us conclude the safety of our approach.

CONCLUSIONS

PD using modified PBC technique and Harmonic FOCUS® can be performed safely and satisfactorily even in APT-burdened patients with high thromboembolic risks. Maintenance of single APT should be considered in patients with high thromboembolic risk, even when PD is performed.

REFERENCES

1. Fujikawa T, Maekawa H, Shiraishi K, Tanaka A. Successful resection of complicated bleeding arteriovenous malformation of the jejunum in patients starting dual anti-platelet therapy just after implanting drug-eluting coronary stent. *BMJ Case Rep* 2012; Sep 24; 2012. [PMID: 23008375]; [PMCID: PMC4543713]; [DOI: 10.1136/bcr-2012-006779]
2. Fujikawa T, Noda T, Tada S, Tanaka A. Intractable intraoperative bleeding requiring platelet transfusion during emergent cholecystectomy in a patient with dual antiplatelet therapy after drug-eluting coronary stent implantation (with video). *BMJ Case Rep* 2013; Mar 26; 2013. [PMID: 23536626]; [PMCID: PMC3618701]; [DOI: 10.1136/bcr-2013-008948]
3. Mita K, Ito H, Murabayashi R, Sueyoshi K, Asakawa H, Nabetani M, Kamasako A, Koizumi K, Hayashi T. Postoperative bleeding complications after gastric cancer surgery in patients receiving anticoagulation and/or antiplatelet agents. *Ann Surg Oncol* 2012; 19(12): 3745-3752. [PMID: 22805868]; [DOI: 10.1245/s10434-012-2500-6]
4. Thachil J, Gatt A, Martlew V. Management of surgical patients receiving anticoagulation and antiplatelet agents. *Br J Surg* 2008; 95(12): 1437-1448. [PMID: 18991253]; [DOI: 10.1002/bjs.6381]
5. Fujikawa T, Tanaka A, Abe T, Yoshimoto Y, Tada S, Maekawa H. Effect of antiplatelet therapy on patients undergoing gastroenterological surgery: thromboembolic risks versus bleeding risks during its perioperative withdrawal. *World J Surg* 2015; 39(1): 139-149. [PMID: 25201469]; [DOI: 10.1007/s00268-014-2760-3]
6. Fujikawa T, Tanaka A, Abe T, Yoshimoto Y, Tada S, Maekawa H, Shimoike N. Does antiplatelet therapy affect outcomes of patients receiving abdominal laparoscopic surgery? Lessons from more than 1,000 laparoscopic operations in a single tertiary referral hospital. *J Am Coll Surg* 2013; 217(6): 1044-1053. [PMID: 24051069]; [DOI: 10.1016/j.jamcollsurg.2013.08.005]
7. Fujikawa T, Yoshimoto Y, Kawamura Y, Kawamoto H, Yamamoto T, Tanaka A. Safety and feasibility of laparoscopic liver resection in antiplatelet-burdened patients with arterial thromboembolic risks. *J Gastroenterol Hepatol Res* 2016; 5(5): 2165-2172. Available from: URL: <http://www.ghrnet.org/index.php/joghr/article/view/1775>; [DOI: 10.17554/j.issn.2224-3992.2016.05.653]
8. Yeh TS, Jan YY, Jeng LB, Hwang TL, Wang CS, Chen SC, Chao TC, Chen MF. Pancreaticojejunal anastomotic leak after pancreaticoduodenectomy--multivariate analysis of perioperative risk factors. *J Surg Res* 1997; 67(2): 119-125. [PMID: 9073557]
9. Gouma DJ, van Geenen RC, van Gulik TM, de Haan RJ, de Wit LT, Busch OR, Obertop H. Rates of complications and death after pancreaticoduodenectomy: risk factors and the impact of hospital volume. *Ann Surg* 2000; 232(6): 786-795. [PMID: 11088073];

- [PMCID: PMC1421271]
10. Tanaka K, Inomata Y, Kaihara S. Living-donor liver transplantation: Surgical techniques and innovations. *Barcelona, Spain: Prous science* 2007.
 11. Park YK, Kim BW, Wang HJ, Xu W. Usefulness of the Pinch-Burn-Cut (PBC) technique for recipient hepatectomy in liver transplantation. *Korean J Hepatobiliary Pancreat Surg* 2012; **16**(1): 13-16. [PMID: 26388900]; [PMCID: PMC4575015]; [DOI: 10.14701/kjhbps.2012.16.1.13]
 12. Salvia R, Malleo G, Marchegiani G, Butturini G, Esposito A, Bassi C. Pancreaticoduodenectomy with harmonic focus curved shears for cancer. *Dig Surg* 2014; **31**(4-5): 249-254. [PMID: 25323993]; [DOI: 10.1159/000363071]
 13. Sato S, Yanagimoto H, Toyokawa H. Use of the new ultrasonically curved shear in pancreaticoduodenectomy for periampullary cancer. *J Hepatobiliary Pancreat Sci* 2011; **18**(4): 609-614. [PMID: 21331806]; [DOI: 10.1007/s00534-011-0370-0]
 14. Sorensen JB, Klee M, Palshof T, Hansen HH. Performance status assessment in cancer patients. An inter-observer variability study. *Br J Cancer* 1993; **67**(4): 773-775. [PMID: 8471434]; [PMCID: PMC1968363]
 15. Dindo D, Demartines N, Clavien PA. Classification of surgical complications: a new proposal with evaluation in a cohort of 6336 patients and results of a survey. *Ann Surg* 2004; **240**(2): 205-213. [PMID: 15273542]; [PMCID: PMC1360123]
 16. Bassi C, Dervenis C, Butturini G, Fingerhut A, Yeo C, Izbicki J, Neoptolemos J, Sarr M, Traverso W, Buchler M. Postoperative pancreatic fistula: an international study group (ISGPF) definition. *Surgery* 2005; **138**(1): 8-13. [PMID: 16003309]; [DOI: 10.1016/j.surg.2005.05.001]
 17. Wente MN, Veit JA, Bassi C, Dervenis C, Fingerhut A, Gouma DJ, Izbicki JR, Neoptolemos JP, Padbury RT, Sarr MG, Yeo CJ, Buchler MW. Postpancreatectomy hemorrhage (PPH): an International Study Group of Pancreatic Surgery (ISGPS) definition. *Surgery* 2007; **142**(1): 20-25. [PMID: 17629996]; [DOI: 10.1016/j.surg.2007.02.001]
 18. Fujii T, Sugimoto H, Yamada S, Kanda M, Suenaga M, Takami H, Hattori M, Inokawa Y, Nomoto S, Fujiwara M, Kodera Y. Modified Blumgart anastomosis for pancreatojejunostomy: technical improvement in matched historical control study. *J Gastrointest Surg* 2014; **18**(6): 1108-1115. [PMID: 24733259]; [DOI: 10.1007/s11605-014-2523-3]
 19. Cattaneo M. Aspirin and clopidogrel: efficacy, safety, and the issue of drug resistance. *Arterioscler Thromb Vasc Biol* 2004; **24**(11): 1980-1987. [PMID: 15388526]; [DOI: 10.1161/01.ATV.0000145980.39477.a9]
 20. Furie KL, Kasner SE, Adams RJ, Albers GW, Bush RL, Fagan SC, Halperin JL, Johnston SC, Katzan I, Kernan WN, Mitchell PH, Ovbiagele B, Palesch YY, Sacco RL, Schwamm LH, Wassertheil-Smoller S, Turan TN, Wentworth D. Guidelines for the prevention of stroke in patients with stroke or transient ischemic attack: a guideline for healthcare professionals from the American Heart Association/American Stroke Association. *Stroke* 2011; **42**(1): 227-276. [PMID: 20966421]; [DOI: 10.1161/STR.0b013e3181f7d043]
 21. King SB, 3rd, Smith SC, Jr., Hirshfeld JW, Jr., Jacobs AK, Morrison DA, Williams jiDO, Feldman TE, Kern MJ, O'Neill WW, Schaff HV, Whitlow PL, Adams CD, Anderson JL, Buller CE, Creager MA, Ettinger SM, Halperin JL, Hunt SA, Krumholz HM, Kushner FG, Lytle BW, Nishimura R, Page RL, Riegel B, Tarkington LG, Yancy CW. 2007 focused update of the ACC/AHA/SCAI 2005 guideline update for percutaneous coronary intervention: a report of the American College of Cardiology/American Heart Association Task Force on Practice guidelines. *J Am Coll Cardiol* 2008; **51**(2): 172-209. [PMID: 18191745]; [DOI: 10.1016/j.jacc.2007.10.002]
 22. Capodanno D, Angiolillo DJ. Management of antiplatelet therapy in patients with coronary artery disease requiring cardiac and noncardiac surgery. *Circulation* 2013; **128**(25): 2785-2798. [PMID: 24366588]; [DOI: 10.1161/CIRCULATIONAHA.113.003675]
 23. Grines CL, Bonow RO, Casey DE, Jr., Gardner TJ, Lockhart PB, Moliterno DJ, O'Gara P, Whitlow P. Prevention of premature discontinuation of dual antiplatelet therapy in patients with coronary artery stents: a science advisory from the American Heart Association, American College of Cardiology, Society for Cardiovascular Angiography and Interventions, American College of Surgeons, and American Dental Association, with representation from the American College of Physicians. *Circulation* 2007; **115**(6): 813-818. [PMID: 17224480]; [DOI: 10.1161/CIRCULATIONAHA.106.180944]
 24. Anderson MA, Ben-Menachem T, Gan SI, Appalaneeni V, Banerjee S, Cash BD, Fisher L, Harrison ME, Fanelli RD, Fukami N, Ikenberry SO, Jain R, Khan K, Krinsky ML, Lichtenstein DR, Maple JT, Shen B, Strohmeier L, Baron T, Dominitz JA. Management of antithrombotic agents for endoscopic procedures. *Gastrointest Endosc* 2009; **70**(6): 1060-1070. [PMID: 19889407]; [DOI: 10.1016/j.gie.2009.09.040]
 25. Boustiere C, Veitch A, Vanbiervliet G, Bulois P, Deprez P, Laquiere A, Laugier R, Lesur G, Mosler P, Nalet B, Napoleon B, Rembacken B, Ajzenberg N, Collet JP, Baron T, Dumonceau JM. Endoscopy and antiplatelet agents. European Society of Gastrointestinal Endoscopy (ESGE) Guideline. *Endoscopy* 2011; **43**(5): 445-461. [PMID: 21547880]; [DOI: 10.1055/s-0030-1256317]
 26. Center for Science Information ASI. Anticoagulant and Antiplatelet Medications and Dental Procedures. American Dental Association Website. Accessed December 29, 2016.
 27. Douketis JD, Spyropoulos AC, Spencer FA, Mayr M, Jaffer AK, Eckman MH, Dunn AS, Kunz R. Perioperative management of antithrombotic therapy: Antithrombotic Therapy and Prevention of Thrombosis, 9th ed: American College of Chest Physicians Evidence-Based Clinical Practice Guidelines. *Chest* 2012; **141**(2 Suppl): e326S-350S. [PMID: 22315266]; [PMCID: PMC3278059]; [DOI: 10.1378/chest.11-2298]
 28. Fleisher LA, Beckman JA, Brown KA, Calkins H, Chaikof EL, Fleischmann KE, Freeman WK, Froehlich JB, Kasper EK, Kersten JR, Riegel B, Robb JF. 2009 ACCF/AHA focused update on perioperative beta blockade incorporated into the ACC/AHA 2007 guidelines on perioperative cardiovascular evaluation and care for noncardiac surgery. *J Am Coll Cardiol* 2009; **54**(22): e13-e118. [PMID: 19926002]; [DOI: 10.1016/j.jacc.2009.07.010]
 29. Korte W, Cattaneo M, Chassot PG, Eichinger S, von Heymann C, Hofmann N, Rickli H, Spannagl M, Ziegler B, Verheugt F, Huber K. Peri-operative management of antiplatelet therapy in patients with coronary artery disease: joint position paper by members of the working group on Perioperative Haemostasis of the Society on Thrombosis and Haemostasis Research (GTH), the working group on Perioperative Coagulation of the Austrian Society for Anesthesiology, Resuscitation and Intensive Care (OGARI) and the Working Group Thrombosis of the European Society for Cardiology (ESC). *Thromb Haemost* 2011; **105**(5): 743-749. [PMID: 21437351]; [DOI: 10.1160/TH10-04-0217]
 30. Correa-Gallego C, Brennan MF, D'Angelica MI, DeMatteo RP, Fong Y, Kingham TP, Jarnagin WR, Allen PJ. Contemporary experience with postpancreatectomy hemorrhage: results of 1,122 patients resected between 2006 and 2011. *J Am Coll Surg* 2012; **215**(5): 616-621. [PMID: 22921325]; [DOI: 10.1016/j.jamcollsurg.2012.07.010]
 31. Darnis B, Lebeau R, Chopin-Laly X, Adham M. Postpancreatectomy hemorrhage (PPH): predictors and management from a prospective database. *Langenbecks Arch Surg* 2013; **398**(3): 441-448. [PMID: 23435636]; [DOI: 10.1007/s00423-013-1047-8]
 32. Yekebas EF, Wolfram L, Cataldegirmen G, Habermann CR,

Bogoevski D, Koenig AM, Kaifi J, Schurr PG, Bubenheim M, Nolte-Ernsting C, Adam G, Izbicki JR. Postpancreatectomy hemorrhage: diagnosis and treatment: an analysis in 1669 consecutive pancreatic resections. *Ann Surg* 2007; **246**(2): 269-280. [PMID: 17667506]; [PMCID: PMC1933568]; [DOI: 10.1097/01.sla.0000262953.77735.db]

from 10,000 procedures: technical tips and wisdom from master pancreatic surgeons to avoid hemorrhage during pancreaticoduodenectomy. *BMC Surg* 2015; **15**: 122. [PMID: 26608343]; [PMCID: PMC4660662]; [DOI: 10.1186/s12893-015-0109-y]

33. Ball CG, Dixon E, Vollmer CM, Howard TJ. The view

Peer reviewer: Premashish Halder