

Acemannan and Formocresol Pulpotomies in Primary Teeth: a Comparative Histopathological Study

Sara Gonna, Elsayed Deraz, Nagwa Ghoname, Amal Kabbash, Akira Yagi

Sara Gonna, M.Sc., Pedodontic Department, Faculty of Dentistry, Tanta University

Elsayed Deraz, PhD., Associate Professor of Oral Pathology Department, Faculty of Dentistry, Tanta University

Nagwa Ghoname, PhD., Professor of Pedodontic Department, Faculty of Dentistry, Tanta University

Amal Kabbash, PhD., Professor of Pharmacognosy Department, Faculty of Pharmacy, Tanta University

Akira Yagi, PhD., Editor in-Chief of Journal of Gastroenterology and Hepatology Research; Emeritus Professor, Fukuyama University, Hiroshima, Japan

Conflict-of-interest statement: The author(s) declare(s) that there is no conflict of interest regarding the publication of this paper.

Open-Access: This article is an open-access article which was selected by an in-house editor and fully peer-reviewed by external reviewers. It is distributed in accordance with the Creative Commons Attribution Non Commercial (CC BY-NC 4.0) license, which permits others to distribute, remix, adapt, build upon this work non-commercially, and license their derivative works on different terms, provided the original work is properly cited and the use is non-commercial. See: <http://creativecommons.org/licenses/by-nc/4.0/>

Correspondence to: Akira Yagi, PhD, Emeritus Professor, Kasuya-machi, Kasuya-gun, Fukuoka-ken, 811-2310, Japan.

Email: akirayagi@nexyzbb.ne.jp

Telephone: +81-92-938-2717

Fax: +81-92-938-2717

Received: May 6, 2017

Revised: May 8, 2017

Accepted: May 8, 2017

Published online: August 21, 2017

ABSTRACT

AIM: The present study was conducted to compare the histopathological effects of acemannan to that of formocresol as pulp-dressing agents in primary teeth underwent pulpotomy.

MATERIALS AND METHODS: *Aloe vera* gel high molecular

weight fractions (AHM) containing native ingredients of polysaccharide (acemannan) and glycoprotein (verectin) were obtained by using the patented hyper dry system after washing out coloured materials with running water from *Aloe vera* gel slurry. Forty-six primary first teeth from children between 6-9 years, which formerly planned for serial extraction were selected. The children were distributed into two equal groups; twelve teeth for each. Pulpotomy was done in both groups; where group I treated by AHM, acemannan, as a dressing agent while formocresol used as a dressing agent in group II. The teeth from each group were extracted at two, four, and twelve week intervals for histopathological evaluation.

RESULTS: In group I (Acemannan), after twelve weeks significantly better results in pulp inflammation, incomplete dentine bridge formation, and soft tissue organization were demonstrated ($p < 0.05$). Most of the acemannan-treated group demonstrated no pulp inflammation with only (3/12, 25%) revealed mild pulp inflammation under the exposure site and only one tooth 1/12 teeth (8.3%) showed partial dentine bridge formation. In contrast, group II (Formocresol) moderate or severe pulp inflammation (10/12, 83%), no dentine bridge formation were observed. In almost all cases (10/12, 83%) the soft tissue of the pulp was not well organized.

CONCLUSION: According to these findings, AHM, acemannan may be a suitable agent for pulpotomy in primary teeth. Moreover, the inflammatory response was less severe and no necrosis was noted after pulpotomy with acemannan compared to formocresol.

Key words: Acemannan; Formocresol; Primary teeth; Pulpotomy

© 2017 The Author(s). Published by ACT Publishing Group Ltd. All rights reserved.

Gonna S, Deraz E, Ghoname N, Kabbash A, Yagi A. Acemannan and Formocresol Pulpotomies in Primary Teeth: a Comparative Histopathological Study. *Journal of Gastroenterology and Hepatology Research* 2017; **6(4)**: 2386-2391 Available from: URL: <http://www.ghrnet.org/index.php/joghr/article/view/2064>

INTRODUCTION

Pulpotomy is one of the most common ways to treat cariously exposed pulp and symptom-free primary teeth^[1]. The rationale is

based on the healing ability of the radicular pulp tissue following amputation of the affected/infected pulp^[2]. Pulpotomy is performed through three phases: devitalization of the coronal pulp, preservation and regeneration^[3]. The ideal pulp dressing material must be bactericidal, harmless to the pulp and surrounding structures promote healing of the radicular pulp and not interfere with the physiological process of root resorption^[4]. The most usual pulp dressing is formocresol, which consists of 19% formaldehyde, 35% cresol, glycerin and water^[5]. Success rate of formocresol pulpotomy is 70-98%^[6,7]. The total success rates of mineral trioxide aggregate, ferric sulfate, and formocresol pulpotomy agents in primary molars were evaluated. Zinc oxide eugenol base, as the only pulpotomy medicament, had a significantly lower success rate than mineral trioxide aggregate. No significant differences were observed, among the three experimental materials at 2 years follow-up^[8]. Concerns have been expressed about effect of formocresol on the enamel structure of the permanent successors^[6]. Recently, there has been a growing trend to seek natural remedies as part of medical and dental therapeutics, which has been termed as “phytotherapeutics” or “ethnopharmacology”^[9]. *Aloe vera* is embracing the concept of phytotherapy; it is a tropical or sub-tropical plant of the genus and belongs to family *Liliaceae*. *Aloe vera* extracts can be used as potential natural disinfecting agents in minimum intervention dentistry^[10]. In addition, it can be used as a direct pulp capping material in primary teeth^[11]. Therefore, the purpose of this *in vivo* study was to evaluate pulp status after pulpotomy with acemannan (*Aloe vera* gel extracts) compared with that of formocresol.

MATERIALS AND METHODS

Selection of teeth

This study was conducted at Faculty of Dentistry, Tanta University, Egypt. The patients were recruited from children who were between 6-9 years and referred to Pedodontic Department. For histological examination, twenty-four primary teeth that formerly planned for serial extraction were selected. These teeth showed no pain or tenderness on percussion, absence of mobility with no fistula or soft tissue swelling. Written informed consent was obtained from the parents. The design and procedure of the present study was accomplished according to the research guidelines published by the research Ethics Committee at Faculty of Dentistry, Tanta University. These teeth will be allocated into two groups, twelve teeth were selected for each group. Group I was treated with acemannan while group II was treated with formocresol.

Pulpotomy procedure

The procedure started with profound local anesthesia and rubber dam isolation, conventional pulpotomy technique was performed. After pulp amputation, pulp chamber was rinsed with normal saline solution. Hemorrhage was controlled by placing a cotton pellet moistened in saline with slight pressure. In formocresol group, after hemostasis, small cotton pellet soaked in formocresol (Sultan Healthcare-Inc. Engle Wood-NJ) was placed over the orifice of canal for 5 min; the orifice was then covered with IRM (DENTSPLY International) and filled with Glass ionomer cement (Vidrion C, White Artigos Dentarios Ltda).

Acemannan sponge preparation

Aloe vera high molecular fractions (AHM) containing native ingredients of polysaccharide (acemannan: molecular weight 1×10^6 D) in rich amount and glycoprotein (verectin: molecular weight 29×10^3 D)

in a small amount, were obtained by using the patented hyper-dry system after washing out coloured materials with running water from *Aloe vera* gel slurry. AHM was applied for the dental study as acemannan sponge. Acemannan sponge, provided by Prof. Yagi A., Emeritus, Fukuyama University, Hiroshima, Japan, was mixed with distilled water and applied on the pulp stump using small sterile pledget of cotton wool moistened with it, then the cavity was sealed with reinforced zinc oxide-eugenol with a sterile suitable plastic instrument and filled with glass ionomer cement. All teeth from each group were extracted at two, four, and twelve weeks.

Histological preparation

All extracted teeth were fixed in 10% formalin. Then, they decalcified in 10% ethylene diaminetetraacetic acid (EDTA) after sealing the apical foramina, for one week, dehydrated in ascending grades of ethanol and embedded in paraffin. Four μ m-thick buccolingual serial sections were obtained by cutting with a microtome. The sections were then deparaffinized in xylene and rehydrated in descending concentrations of ethanol. Then, staining with hematoxylin and eosin stains was done. The slides were mounted for microscopical examination using light microscope. The sections were evaluated for the presence or absence of calcification, inflammation and blood vessel formation in the pulpal tissue. Moreover, the status of odontoblastic layer was investigated. Other encountered histological changes in the pulp were also recorded.

RESULTS

Forty-six primary teeth that formerly planned for serial extraction were selected. Pulpotomy performed on all teeth which was divided in two groups 12 treated with acemannan and the other 12 teeth were treated with formocresol. All the teeth from each group were extracted at two, four, and twelve week intervals. Histopathological evaluation of dental pulp responses after 12 week follow up of acemannan and formocresol are shown in Table 1 according to Songsiripraduboon S. group^[11] with slight modification.

Acemannan group (Group I)

Overall, the acemannan-treated group showed significantly better results in pulp inflammation, dentine bridge formation, and soft tissue organization ($p < 0.05$). Most of the acemannan-treated group demonstrated no pulp inflammation with only (3/12, 25%) reveal mild pulp inflammation under the exposure site p value show significant difference, only one tooth 1/12 teeth (8.3%) had showed partial dentine bridge formation. After two week showed that show no inflammatory cell infiltration and partial dentin bridge formation Figure 1, after four week shows normal pulpal architecture and intact layer of odontoblasts Figure 2, Figure 3, and Figure 4. After twelve weeks follow up the pulp tissue shows normal soft tissue organization without any evidence of inflammation Figure 5.

Table 1 Histopathological evaluation of dental pulp responses after 12 week follow up of acemannan and formocresol (Fc).

Group	After 12 week					
	Inflammation		Soft tissue organization		Dentin bridge	
	N	%	N	%	N	%
Acemannan (N=12)	3	25%	8	66.60%	1	8.30%
Fc (N=12)	10	83.30%	2	16.60%	0	0%
χ^2	4.332		6.551		1.432	
P value	0.03*		0.01*		0.23	

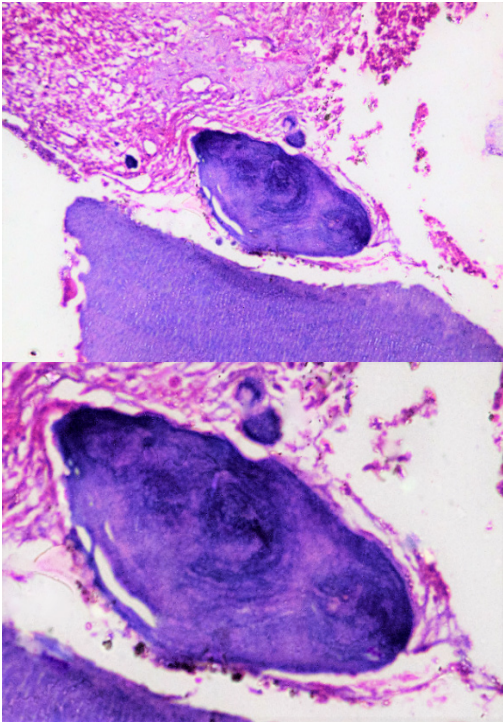


Figure 1 Upper: a photomicrograph exhibits the histological features at 2-weeks follow-up of acemannan-treated group. This figure shows no inflammatory cell infiltration and partial dentin bridge formation (H & E X20). Lower: higher magnification of the same figure (H & E X40).

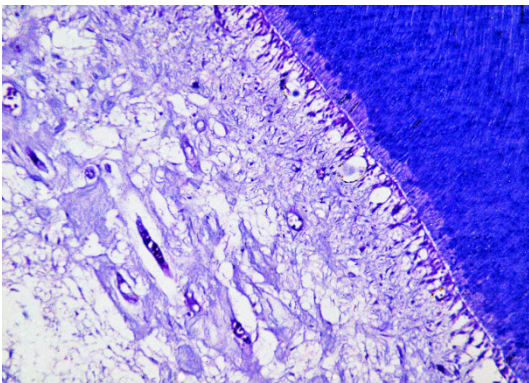


Figure 2 A photomicrograph of acemannan-treated group after 4 week's shows normal pulpal architecture pattern with no inflammatory cell presentation, intact layer of odontoblasts and small to medium sized blood vessels (H & E X20).

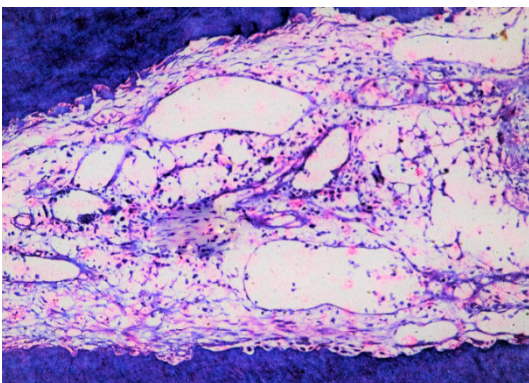


Figure 3 A photomicrograph of acemannan-treated group after 4 weeks reveals small, medium and large sized blood vessels with normal soft tissue organization of pulp tissue, no inflammation was detected (H & E X20).

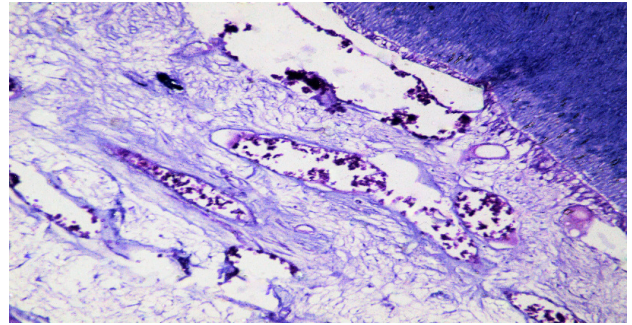


Figure 4 A photomicrograph of acemannan-treated group after 4 week reveals small, medium and large sizes blood vessel with normal soft tissue organization of pulp tissue, no inflammation was detected (H & E X20).

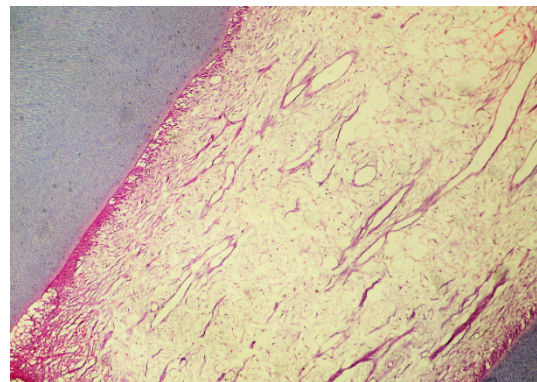


Figure 5 A photomicrograph of acemannan-treated group after 12 weeks. The figure shows a pulp tissue with normal soft tissue organization without any evidence of inflammation (H & E X100).

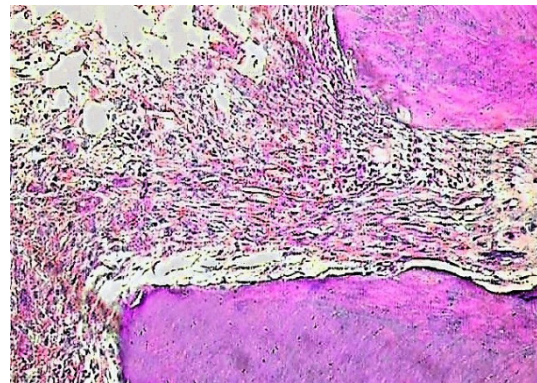


Figure 6 A photomicrograph of formocresol treated group after 2 weeks shows loss of odontoblasts, mild inflammation as well as mild fibrosis (H & E X100).

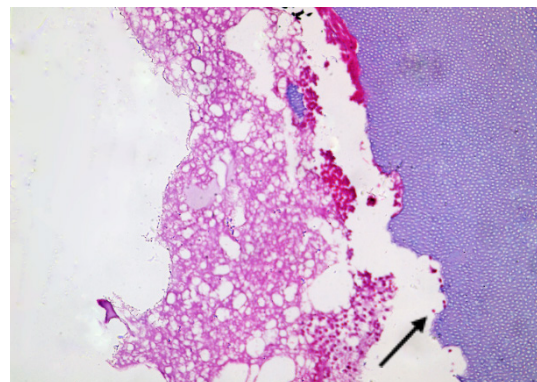


Figure 7 A photomicrograph of formocresol treated group after 4 week reveals destroyed pulp tissue and moderate inflammation, irregular dentinal wall with internal resorption (arrow) and absence of odontoblasts are also detected (H & E X200).

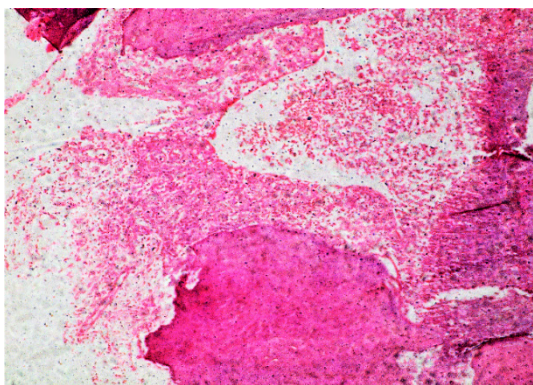


Figure 8 A photomicrograph of formocresol treated group after 12 weeks reveals necrosis of pulpal tissue with sever inflammatory cell infiltration. Absence of odontoblasts is also revealed (H & E X100).

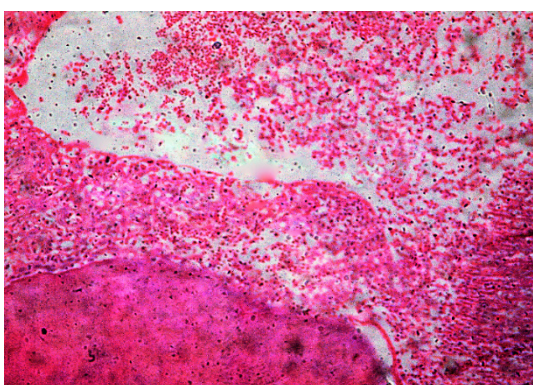


Figure 9 A photomicrograph of formocresol treated group after 12 weeks reveals necrosis of pulpal tissue with sever inflammatory cell infiltration. Absence of odontoblasts is also revealed (H & E X100).

Formocresol group (Group II)

In contrast, all the teeth in the formocresol-treated group demonstrated either moderate or severe pulp inflammation (10/12, 83%), there was no dentine bridge formation. Almost all cases (10/12, 83%) the soft tissue of the pulp was not well organized. The cases after two weeks showed loss of odontoblasts, mild inflammation as well as fibrosis Figure 6. After four week, destructed pulp tissue were demonstrated, moderate inflammation, internal resorption and absence of odontoblasts are also detected Figure 7. After twelve weeks necrosis of pulpal tissue were demonstrated Figure 8 and Figure 9.

DISCUSSION

It seems very important to identify novel and effective pulpotomy agents to increase the rate of success of pulpotomy procedures. Therefore, several investigations have been used to evaluate the clinical and radiographical success of the variable pulpotomy agents in primary teeth, such as the presence of pain or swelling as well as the indication of periapical lesions radiographically^[4,12]. On the other hand, histopathological analysis is necessary to examine the condition of the pulp tissue after pulpotomy procedures. Some animal studies have been used to evaluate the state of the pulp tissue microscopically for teeth submitted to pulpotomy using different agents^[2,13]. In the current study, we used acemannan sponge as a pulpotomy agent in primary teeth planned for serial extraction and compared the histopathological effects of acemannan on pulp tissue with the changes resulted from formocresol after

pulpotomy procedures. Formocresol has been a popular pulpotomy agent because of its ease manipulation. However, it has several side effects^[5]. In the current study, formocresol treated teeth after two weeks exhibited mild fibrosis and inflammation. This finding is in agreement with Cotes O. group^[14] who reported the appearance of fibrous granulation tissue in the root canal after formocresol pulpotomy. After four weeks, the pulp tissue showed destructed pulp tissue and moderate inflammation, irregular dentinal wall with internal resorption and absence of odontoblasts are also detected. This finding is in agreement with Haghgoo R. and Abbasi F.^[15], who reported severe inflammation with teeth treated by formocresol. The inflammation observed in the present study has been confirmed in another histological study by El-Meligy O. group^[16]. After twelve weeks, teeth in formocresol group resulted in necrosis. It was demonstrated that the penetration of formaldehyde into the pulp resulted initially in fixation of the tissue followed by coagulation necrosis as it diffuses apically^[17]. This coagulation necrosis was followed by liquefaction necrosis of the pulp^[18]. This liquefaction is attributed to release of hydrolytic enzymes from dying neutrophils^[19]. Moreover, formocresol is well known to devitalize the pulp and thus can induce necrosis. There was no evidence for hard tissue formation in any of formocresol treated teeth after four weeks or even after twelve weeks postoperatively.

On the other hand, Gupta N. group^[20] evaluated efficacy of *Aloe vera* gel as healing agent in an endodontic procedure called pulpotomy. Fifteen primary molars were treated for pulpotomy using *Aloe vera* gel and after one month to check for any clinical symptoms. None of the patients reported with clinical symptoms of pain, mobility, abscess and histopathological evaluation done following extraction after 2 months showed positive signs of healing. This finding is similar to the results observed in another study which demonstrated formation of dentine bridge, and soft tissue organization of the pulp in acemannan-treated group^[11]. Sahawat D. group^[21] demonstrated that acemannan significantly increased expression of type I collagen, vascular endothelial growth factor, and osteopontin compared with the untreated group, suggesting a possible therapeutic agent for cementum regeneration. After four weeks, current study showed acemannan induced formation of normal pulpal infiltration pattern with no inflammatory cell presentation, intact layer of odontoblasts and small to medium sized-blood vessels. These results are consistent with finding of Jittapiromsak N. group^[22], they found that acemannan increase pulp cell proliferation and enhance pulp tissue organization with mild or no inflammation. Acemannan stimulated differentiation of immune dendritic cells, which are most important accessory cells for primary immune responses. These findings expressed that the adjuvant activity of acemannan is due to its capacity to promote differentiation of immature dendritic cells^[23]. Acemannan sponge exhibited multiple immunomodulatory effects which are important to burn wound healings. Verectin, a radical scavenging glycoprotein in AHM, inhibited Cox-2 and thromboxane A₂ synthase level, suggesting the participation to human immune system^[24]. In animal study, Boonyagul S. group^[25] showed that acemannan revealed significantly increased bone marrow stromal cells proliferation, bone sialoprotein, osteopontin expression, and mineralization. After twelve weeks of acemannan sponge treated group, a pulp tissue appears with normal soft tissue organization without any evidence of inflammation. These findings are similar to the results observed by Songsiripradubboon S. group^[11]. This can be attributed to its biocompatibility, anti-inflammatory, and anti-bacterial properties that made it possible for wide usage in dentistry

for various therapeutic purposes. Acemannan sponges significantly accelerated new alveolar bone, cementum and periodontal ligament formation in class II furcation defects, suggesting acemannan could be a candidate biomolecule for periodontal tissue regeneration^[26]. AHM mainly contained high molecular fractions, such as polysaccharide (acemannan) and glycoprotein (verectin) showing immunomodulatory and anti-inflammatory activities. On the basis of biochemical properties, AHM were examined for the therapy designed by the implementation of well-controlled clinical trials, and exhibited the efficacy as immunomodulators for viral infection-induced hepatic periportal fibrosis and type 2 diabetic patients, and as wound and ulcer-healing ointment to patients suffering from bed sore and lichen planus^[27,28].

In contrast to formocresol, there was no sign of pulp necrosis with acemannan application. According to our results, acemannan sponge resulted in more favorable histological changes in the pulp tissue compared to that of formocresol. Hence, the use of acemannan sponge as a pulpotomy agent could produce beneficial effects. Furthermore, acemannan sponge, AHM, was considered to be a novel low-cost and safe herbal pre-drug of natural origin, indicating a possible therapeutic efficacy in prevention of age-related diseases by slowing aging process^[29]. Further investigations should be performed over a longer period of post-treatment evaluation to confirm the biocompatibility and efficiency of acemannan sponge on dentin regeneration and use it as an alternative to formocresol pulpotomy.

CONCLUSIONS

Within the context of observed results, it is possible to conclude that acemannan sponge (AHM) had advantage over formocresol as a pulpotomy agent as it did not produce inflammation or necrosis of pulp tissue. In addition, it induced the formation of partial hard tissue barrier after pulpotomy procedure. Therefore, acemannan sponge (AHM) has potential for use as an effective pulpotomy agent and offers as a valuable alternative biodegradable material for vital pulp therapy in human primary teeth.

ACKNOWLEDGMENTS

The authors express deep thanks to Mr. Yagi, S., CEO, Ellie Corporation, Shizuoka, Japan for providing aloe vera high molecular weight fractions.

REFERENCES

1. Huth KC, Paschos E, Hajek-AI-Khatar N, Hollweck R, Crispin A, Hickel R, Folwaczny M. Effectiveness of 4 pulpotomy techniques--randomized controlled trial. *J Dent Res* 2005; **84**(12): 1144-1148. [DOI: 10.1177/154405910508401210].
2. Cengiz SB, Batirbaygil Y, Onur MA, Atilla P, Asan E, Altay N, Cehrelci ZC. Histological comparison of alendronate, calcium hydroxide and formocresol in amputated rat molar. *Dent Traumatol* 2005; **21**(5): 281-288. [DOI: 10.1111/j.1600-9657.2005.00325].
3. Fuks AB. Pulp therapy for the primary and young permanent dentitions. *Dent Clin North Am* 2000; **44**(3): 571-596. [PMID: 10925773].
4. Fuks AB, Eidelman E. Pulp therapy in the primary dentition. *Curr Opin Dent* 1991; **1**(5): 556-563. [PMID: 1807455].
5. Burnett S, Walker J. Comparison of ferric sulfate, formocresol, and a combination of ferric sulfate/formocresol in primary tooth vital pulpotomies: a retrospective radiographic survey. *ASDC J*

- Dent Child* 2002; **69**(1): 44-48, 12. [PMID: 12119812]
6. Agamy HA, Bakry NS, Mounir MM, and Avery DR. Comparison of mineral trioxide aggregate and formocresol as pulp-capping agents in pulpotomized primary teeth. *Pediatr Dent* 2004; **26**(4): 302-309. [PMID: 15344622]
7. Bahrololoomi Z, Moeintaghavi A, Emtiazi M, Hosseini G. Clinical and radiographic comparison of primary molars after formocresol and electrosurgical pulpotomy: a randomized clinical trial. *Indian J Dent Res* 2008; **19**(3): 219-223. [PMID: 18797098]
8. Erdem AP, Guven Y, Balli B, Ihan B, Sepet E, Ulukapi I, Aktoren O. Success rates of mineral trioxide aggregate, ferric sulfate, and formocresol pulpotomies: a 24-month study. *Pediatr Dent*. 2011; **33**: 165-170. [PMID: 21703067]
9. Neelakantan PJN, Nazar N. Ethnopharmacological approach in endodontic treatment: A focused review. *Int J Drug Res* 2011; **3**(4): 68-77. [ISSN 0975-9344].
10. Prabhakar AR, Karuna YM, Yavagal C, Deepak BM. Cavity disinfection in minimally invasive dentistry - comparative evaluation of *Aloe vera* and propolis: A randomized clinical trial. *Contemp Clin Dent* 2015; **6**(1): 24-31. [PMID: 25821369]; [DOI: 10.4103/0976-237X.152933].
11. Songsiripraduboon S, Banlunara W, Sangvanich P, Trairatvorakul C, Thunyakitpisal P. Clinical, radiographic, and histologic analysis of the effects of acemannan used in direct pulp capping of human primary teeth: short-term outcomes. *Odontology* 2016; **104**: 329-337. [PMID: 26264630]; [DOI: 10.1007/s10266-015-0215-4]
12. Markovic D, Zivojinovic V, Vucetic M. Evaluation of three pulpotomy medicaments in primary teeth. *Eur J Paediatr Dent* 2005; **6**(3): 133-138. [PMID: 16216093].
13. Ahangari Z, Naseri M, Jalili M, Mansouri Y, Mashhadiabbas F, Torkaman A. Effect of propolis on dentin regeneration and the potential role of dental pulp stem cell in Guinea pigs. *Cell J* 2012; **13**(4): 223-228. [PMCID: PMC3584482]; [PMID: 23508294]
14. Cotes O, Boj JR, Canalda C, Carreras M. Pulpal tissue reaction to formocresol vs. ferric sulfate in pulpotomized rat teeth. *J Clin Pediatr Dent* 1997; **21**(3): 247-253. [PMID: 9484135].
15. Haghgoo R, Abbasi F. A histopathological comparison of pulpotomy with sodium hypochlorite and formocresol. *Iran Endod J*. 2012; **7**(2): 60-62. [PMCID: PMC3467126].
16. El-Meligy O, Abdalla M, El-Baraway S, El-Tekya M, Dean JA. Histological evaluation of electrosurgery and formocresol pulpotomy techniques in primary teeth in dogs. *J Clin Pediatr Dent* 2001; **26**(1): 81-85. [PMID: 11688819].
17. Block RM, Lewis RD, Hirsch J, Coffey J, Langeland K. Systemic distribution of ¹⁴C-labeled paraformaldehyde incorporated within formocresol following pulpotomies in dogs. *J Endod* 1983; **9**(5): 176-189. [PMID: 6574206]; [DOI: 10.1016/S0099-2399(83)80090-9].
18. Cleaton-Jones P, Duggal M, Parak M, William S, Setze S. Ferric sulphate and formocresol pulpotomies in baboon primary molars: histological responses. *Eur J Paediatr Dent* 2002; **3**(3): 121-125. [PMID: 12871000].
19. Robins and Cotran Pathologic basis of disease. 8th Ed. Philadelphia, WB Saunders Co. 2010: 15.
20. Gupta N, Bhat M, Davi P, Girish. *Aloe vera*: A nature's gift to children. *Int J of Clin Pediatr Dent*. 2010; **3**: 87-92. [PMID: 27507917]; [DOI: 10.5005/jp-journals-10005-1059]
21. Sahawat D, Kanthasuwana S, Sangvanich P, Takata T, Kitagawa M, Thunyakitpisal P. Acemannan induces cementoblast proliferation, differentiation, extracellular matrix secretion, and mineral deposition. *J. of Medical Plants Research* 2012; **6**: 4069-4076. [DOI: 10.5897/JMPR12.649]
22. Jittapiromsak N, Sahawat D, Banlunara W, Sangvanich P, Thunyakitpisal P. Acemannan, an extracted product from *Aloe vera*, stimulates dental pulp cell proliferation, differentiation, mineralization, and dentin formation. *Tissue Eng Part A* 2010;

- 16(6): 1997-2006.[PMID: 20088703]; [DOI: 10.1089/ten.TEA.2009.0593]
23. Lee JK, Lee MK, Yun YP, Kim Y, Kim JS, Kim YS, Kim K, Han SS, Lee CK. Acemannan purified from *Aloe vera* induces phenotypic and functional maturation of immature dendritic cells. *Int Immunopharmacolog.* 2001; **1(7)**: 1275-1284. [PMID: 11460308]
 24. Yagi A, Kabbash A, Mizuno K, Moustafa SM, Kaharifa TI, Tsuji H. Radical scavenging glycoprotein inhibiting cyclooxygenase-2 and thromboxane A₂ synthase from *Aloe vera* gel. *Planta Medica* 2003; **69**: 269271. [PMID: 12677534]; [DOI: 10.1055/s-2003-38481]
 25. Boonyagul S, Banlunara W, Sangvanich P, Thunyakitoisal P. Effect of acemannan, an extracted polysaccharide from *Aloe vera*, on BMSCs proliferation, differentiation, extracellular matrix synthesis, mineralization, and bone formation in a tooth extraction model. *Odontology* 2014; **10**: 310-317. [PMID: 23315202]; [DOI: 10.1007/s10266-012-0101-2]
 26. Chantarawatit P, Sangvanich P, Banlunara W, Soontornvipart K, Thunyakitpisal P. Acemannan sponges stimulate alveolar bone, cementum and periodontal ligament regeneration in a canine class II furcation defect model. *J. Periodont Res.* 2014; **49(2)**: 164-178. [DOI: 10.1111/jre.120905]
 27. Yagi A. *Aloe vera* high molecular weight fractions as carbohydrate-based immune adjuvants. *GHR* 2013; **2**: 568-570. [DOI: 10.6051/j.issn.22243992.2013.02.114]
 28. Yagi A. Therapeutic efficacy of *Aloe vera* high molecular fractions for treatment of hepatic fibrosis, type 2 diabetes, bed sores and lichen planus. *GHR* 2013 **2**: 672-679.[DOI: 10.6051/j.issn.2224-3992.2013.02.235]
 29. Yagi A. Putative prophylaxes of *Aloe vera* for age-related diseases. *GHR* 2015; **4**: 1407-1424. [DOI: 10.6051/j.issn.2224-3992.2015.04.416]