

An Unusual Case of Cholestatic Hepatitis

Ahmad M. Al-Tae, Anas K. Gremida, Amanda C. Cheung, Jinping Lai, Brent Neuschwander-Tetri

Ahmad M. Al-Tae, Department of Internal Medicine, Saint Louis University School of Medicine, Saint Louis, Missouri, the United States

Anas K. Gremida, Division of Gastroenterology and Hepatology, University of New Mexico, Albuquerque, New Mexico, the United States

Amanda C. Cheung, Brent Neuschwander-Tetri, Division of Gastroenterology and Hepatology, Saint Louis University School of Medicine, Saint Louis, Missouri, the United States

Jinping Lai, Department of Pathology, University of Florida, Gainesville, Florida, the United States

Conflict-of-interest statement: The author(s) declare(s) that there is no conflict of interest regarding the publication of this paper.

Open-Access: This article is an open-access article which was selected by an in-house editor and fully peer-reviewed by external reviewers. It is distributed in accordance with the Creative Commons Attribution Non Commercial (CC BY-NC 4.0) license, which permits others to distribute, remix, adapt, build upon this work non-commercially, and license their derivative works on different terms, provided the original work is properly cited and the use is non-commercial. See: <http://creativecommons.org/licenses/by-nc/4.0/>

Correspondence to: Ahmad Al-Tae, MD, Department of Internal Medicine, Saint Louis University School of Medicine, 3635 Vista Ave, FDT 14th floor, St Louis, Missouri 63110, the United States.
Email: altaeam@slu.edu
Fax: +877-992-9414

Received: May 10, 2017

Revised: June 28, 2017

Accepted: June 30, 2017

Published online: August 21, 2017

ABSTRACT

Renal cell carcinoma can present with a variety of paraneoplastic syndromes. Reversible hepatic dysfunction in the setting of non-metastatic renal cell carcinoma is a rare paraneoplastic phenomenon that was first described by Stauffer in 1961. This clinical entity is characterized by reversal of liver chemistry abnormalities after

resection of the primary tumor. Here we present an unusual case of non-metastatic hepatic dysfunction secondary to renal cell carcinoma, also known as Stauffer's syndrome, in a 55-year old patient who presented with liver synthetic dysfunction and notable hyperbilirubinemia. Unlike earlier reports, the icteric variant of Stauffer's syndrome has been emerging as the predominantly reported variant in the recent literature. Moreover, poor correlation between the severity of hepatic dysfunction and the liver biopsy findings was noted. The variable and non-specific presenting symptoms and signs as well as the need for extensive evaluation for abnormal liver chemistry usually results in a delay in the diagnosis of the primary tumor. Therefore, physicians need to be familiar with this clinical entity as a possible reversible etiology of liver chemistry abnormalities in patients with renal and other solid tumors as this may guide further investigations, lead to earlier diagnosis and treatment of the primary tumor, and ultimately improve outcomes.

Key words: Stauffer's syndrome; Non-metastatic hepatic dysfunction; Renal cell carcinoma

© 2017 The Author(s). Published by ACT Publishing Group Ltd. All rights reserved.

Al-Tae AM, Gremida AK, Cheung AC, Lai J, Neuschwander-Tetri B. An Unusual Case of Cholestatic Hepatitis. *Journal of Gastroenterology and Hepatology Research* 2017; **6(4)**: 2411-2415 Available from: URL: <http://www.ghrnet.org/index.php/joghr/article/view/2072>

INTRODUCTION

Non-metastatic hepatic dysfunction secondary to renal cell carcinoma, also known as Stauffer's syndrome, was first described by Stauffer in 1961^[1]. The pathophysiology has not been completely elucidated so far. Surgical resection of the primary tumor is characteristically associated with reversal of liver chemistry abnormalities^[2].

CASE PRESENTATION

A 55-year-old Caucasian male with a past medical history of type 2 diabetes mellitus and benign prostatic hyperplasia presented to the emergency room with the chief complaint of worsening abdominal

pain as well as pruritus for three months prior to presentation. Home medications included insulin glargine, insulin lispro, and tamsulosin. He denied any new or recent medications including antibiotics, over-the-counter medications, and herbal supplements. Past surgical history included a cholecystectomy nine years ago. On presentation, vital signs were Unremarkable. Physical examination was notable for scleral icterus, jaundice, multiple excoriations over the forearms and shins, and tenderness to palpation over the right upper abdominal quadrant.

Initial laboratory workup was notable for elevated conjugated bilirubin, alkaline phosphatase, gamma glutamyltransferase, and prothrombin time (Table 1). Aspartate aminotransferase, alanine aminotransferase, blood urea nitrogen, serum creatinine, hemoglobin, and platelet count were all within normal limits. Neutrophilia, lymphopenia, and monocytosis were also noted although the absolute total white blood cell count was normal. Urinalysis showed a positive urobilinogen and glycosuria. Workup for liver chemistry abnormalities was unremarkable (Table 2).

Computed tomography and magnetic resonance imaging of the abdomen showed no abnormalities of the liver or biliary tree; however, a 2.5-cm enhancing exophytic solid and cystic mass arising from the lower pole of the left kidney was incidentally noted (Figure 1). Due to persistent liver chemistry abnormalities without an identified etiology, he underwent a percutaneous liver biopsy which revealed portal and periportal neutrophilic inflammatory infiltrate with bile duct and ductular proliferation as well as centrilobular hepatocellular cholestasis consistent with cholestatic hepatitis (Figure 2).

Due to the appearance of the renal cystic mass with Bosniak 4 classification, the patient underwent surgical resection of the renal mass. The perioperative course was uncomplicated, notably without any decompensation of liver or renal function. Histologic examination of the tumor revealed clear cell renal cell carcinoma with no vascular or capsular invasion. Liver chemistry abnormalities had normalized three months post-operatively (Figure 3).

DISCUSSION

Cholestasis in the setting of malignancies is usually due to metastatic disease with widespread hepatic infiltration or compression of the hepatobiliary tree. Less frequently, cholestasis may be due to a paraneoplastic syndrome rather than metastatic disease. In addition to renal cell carcinoma (RCC), hepatic dysfunction in the absence

of liver metastasis has been described in patients with prostate cancer^[3,4], bronchogenic carcinoma^[5], soft tissue sarcoma^[6,7], bladder cancer^[8], thymoma^[9], and lymphoproliferative malignancies^[10,11].

Non-metastatic hepatic dysfunction (NMHD) in the setting of RCC is a rare paraneoplastic phenomenon that was first described by Stauffer in 1961 in a case series of five patients and was referred to as “nephrogenic hepatomegaly”^[1]. Although the term “Stauffer’s syndrome” has been typically used to refer to NMHD secondary to renal tumors, other reports have also used this term to describe NMHD secondary to non-renal tumors^[3-8]. The hallmark features described by Stauffer included: 1. liver dysfunction in presence of RCC, 2. absence of liver metastasis, 3. absence of other causes of liver disease, and 4. resolution of hepatic dysfunction after resection of the primary.

Table 1 Laboratory results upon patient presentation.

Lab Test	Result	Reference Range
Total bilirubin	20.9 mg/dL	0.2 - 1.2 mg/dL
Conjugated bilirubin	12.5 mg/dL	0.0 - 0.5 mg/dL
Alkaline phosphatase	327 Units/L	40 - 150 Units/L
Gamma glutamyltransferase	185 Units/L	9 - 64 Units/L
Alanine aminotransferase (ALT)	34 Units/L	0-55 Units/L
Aspartate aminotransferase (AST)	29 Units/L	5-34 Units/L
Prothrombin time	18.7 seconds	12.1 - 14.8 seconds
International normalized ratio (INR)	1.6	0.9-1.1
Albumin	2.5 g/dL	3.4 - 5.0 g/dL
White blood cell count with differential	8.9 × 10 ³ /uL	3.5-10.5 × 10 ³ /uL
Neutrophils	81%	35-70%
Lymphocytes	11.30%	20-50%
Monocytes	18%	3-15%

Table 2 Work up for abnormal liver enzymes.

Lab Test	Result	Reference Range
Antinuclear antibodies	Negative	Negative
Anti smooth muscle antibodies	Negative	Negative
Anti mitochondrial antibodies	Negative	Negative
Urine ceruloplasmin	35 mg/dL	< 20 mg/dL
Herpes Simplex PCR and IgM	Negative	Negative
Epstein Barr virus PCR	Negative	Negative
Cytomegalovirus PCR	Negative	Negative

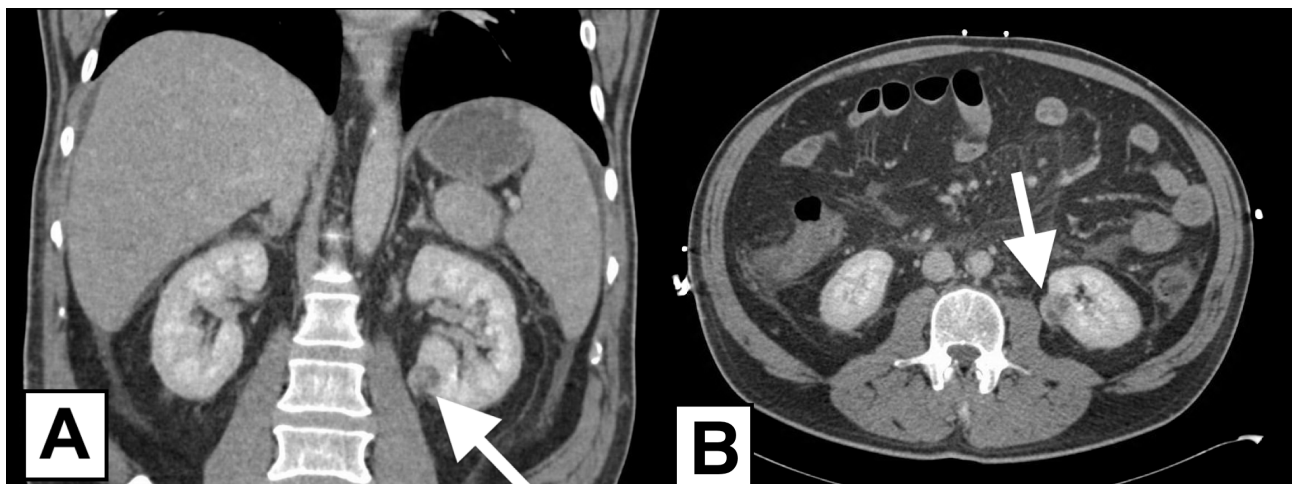


Figure 1 Coronal (A) and axial (B) sections of the computed tomography of the abdomen revealing an enhancing exophytic mass (white arrows) arising from the lower pole of the left kidney which was later confirmed to be clear cell renal cell carcinoma.

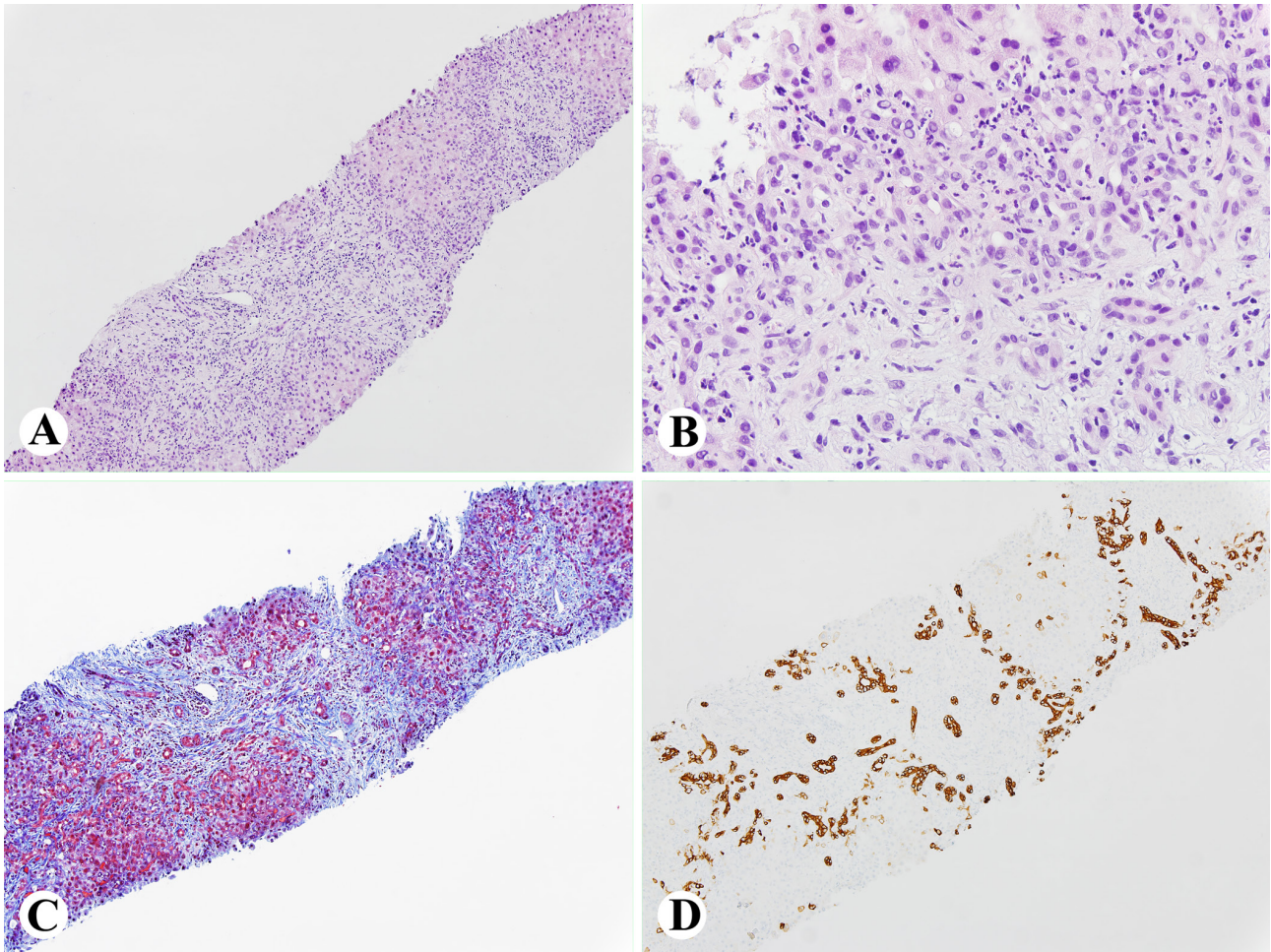


Figure 2 A-D, Liver biopsy showing portal ductular proliferation, mild edema, periductal and periductular neutrophils infiltrate (H&E stain, A, 100X; B, 400X); Trichrome stain showing portal edema and periportal fibrosis (C, 100X); and CK19 immunostain showing extensive periportal ductular proliferation (D, 100X).

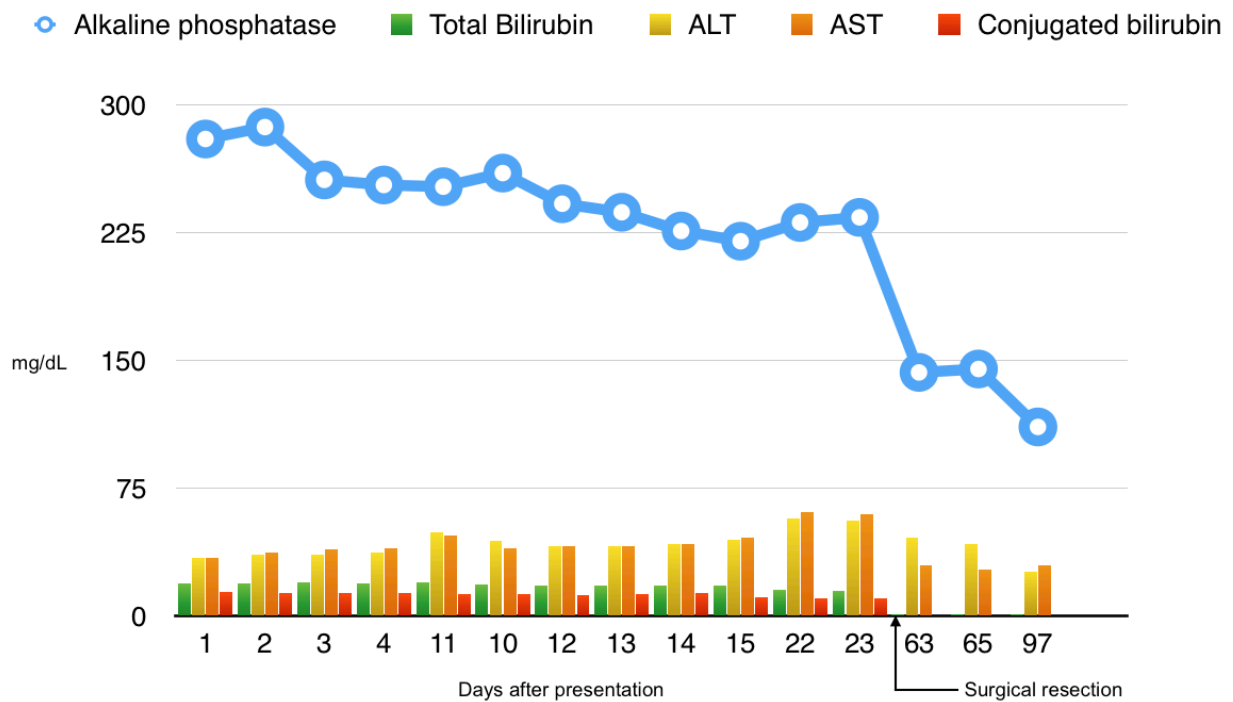


Figure 3 The trend of liver chemistry abnormalities before and after resection of the left renal mass. Liver enzymes normalized about a month after surgical resection of the renal mass.

Although the pathophysiology of Stauffer's syndrome has not been fully elucidated, several mechanisms have been proposed. Interleukin-6 has been suggested as a major contributor, as its plasma levels were found to be elevated in up to 80% of patients with RCC-related paraneoplastic syndromes^[12]. More recently, there has been a growing interest in exploring autoimmune mechanisms in patients with paraneoplastic syndromes and solid tumors^[13,14]. Further investigating the pathophysiology of Stauffer's syndrome would be challenging as it is rarely encountered in clinical practice. This raises the need to establish a national registry that provides means to report cases and collect blood samples for further analysis.

Data on the outcome, prognosis, and significance of Stauffer's syndrome is limited. Previous anecdotal reports suggested that RCC patients with hepatic dysfunction had significantly worse prognosis than those without hepatic dysfunction^[2,15]. It has also been suggested that the occurrence of Stauffer's syndrome may be an early indicator of recurrence after surgical resection or tumor metastases^[15,16].

The initial reports by Stauffer and others have described the classic, or anicteric, form of the NMHD in the setting of renal tumors^[1,17]. In comparison, the first case of the cholestatic, or icteric, variant of Stauffer's syndrome was reported by Dourakis *et al* in 1997^[18]. Since then, a total of 7 case reports describing the icteric variant of Stauffer's syndrome were found on our review of the literature^[19-25]. Direct hyperbilirubinemia was also noted in the patient described above. This adds to the growing body of literature on the icteric variant of Stauffer's syndrome. Moreover, our patient had evidence of hepatic dysfunction in the form of coagulopathy. However, histologic examination of the liver revealed intact hepatic parenchyma with inflammatory cellular infiltrate and periportal fibrosis. This confirms the lack of correlation between the severity of hepatic dysfunction and the liver biopsy findings in patients with Stauffer's syndrome.

Non-metastatic hepatic dysfunction in the setting of renal cell carcinoma is a diagnosis of exclusion that is made after an extensive non-revealing abnormal liver chemistry workup. The variable and non-specific presenting symptoms and signs as well as the need for extensive evaluation for abnormal liver chemistry usually results in delay in the diagnosis and management of the primary tumor. Therefore, physicians need to be familiar with this clinical entity as a possible reversible etiology of liver chemistry abnormalities in patients with renal and other solid tumors as this may guide further investigations, lead to earlier diagnosis and treatment of the primary tumor, and ultimately improve outcomes.

REFERENCES

1. Stauffer M. Nephrogenic hepatosplenomegaly. *Gastroenterology*. 1961; **40**: 694.
2. Fletcher MS, Packham DA, Pryor JP, Yates-Bell AJ. Hepatic dysfunction in renal carcinoma. *Br J Urol*. 1981; **53**(6): 533-6. [PMID: 7317737]
3. Hinostroza-Yanahuaya J, Mon-Mon C, Ortega-Marcos O, Herrero-Berron JC, Ortiz-Libreros M, Vigil-Medina A. Stauffer syndrome and prostate carcinoma, two cases in chronic haemodialysis patients. *Nefrologia*. 2013; **33**(5): 749-50. [DOI: 10.3265/Nefrologia.pre2013.May.10953]; [PMID: 24089176]
4. Kato D, Okwara C, Moreland C, Parker A. Hepatic Dysfunction as a Paraneoplastic Manifestation of Metastatic Prostate Adenocarcinoma. *J Invest Med High Impact Case Rep*. 2014; **2**(2): 2324709614539927. [DOI: 10.1177/2324709614539927]; [PMID: 26425613]; [PMCID: PMC4528893]
5. Saintigny P, Spano JP, Tcherakian F, Pailler MC, Breau JL. Non-metastatic intrahepatic cholestasis associated with bronchial adenocarcinoma. *Ann Med Interne (Paris)*. 2003; **154**(3): 171-5. [PMID: 12910044]
6. Sharara AI, Panella TJ, Fitz JG. Paraneoplastic hepatopathy associated with soft tissue sarcoma. *Gastroenterology*. 1992; **103**(1): 330-2. [PMID: 1612341]
7. Fraisse TC, Damigny A, di Castri A, de Wazieres B, Fourcade J. Leiomyosarcoma and Stauffer syndrome. *Rev Med Interne*. 2001; **22**(11): 1116-8. [PMID: 11817123]; [PMCID: PMC11817123]
8. Moreno-Palacios J, Wingartz-Plata H, Pardo-Belasteguigoitia P, Moreno-Aranda J. Stauffer syndrome in transitional cell carcinoma of the bladder. *Arch Esp Urol*. 2011; **64**(9): 911-3. [PMID: 22155881]
9. Mendogni P, Rosso L, Tosi D, Palleschi A, Righi I, Minonzio F, Fusco N, Nosotti M. Autoimmune hepatitis: an uncommon presentation of thymoma. *Tumori*. 2016; 102(Suppl. 2). [DOI: 10.5301/tj.5000505]; [PMID: 27079907]
10. Watterson J, Priest JR. Jaundice as a paraneoplastic phenomenon in a T-cell lymphoma. *Gastroenterology*. 1989; **97**(5): 1319-22. [PMID: 2676684]
11. Yalcin S, Kars A, Sokmensuer C, Atahan L. Extrahepatic Hodgkin's disease with intrahepatic cholestasis: report of two cases. *Oncology*. 1999; **57**(1): 83-5. [PMID: 10394130]
12. Blay JY, Rossi JF, Wijdenes J, Menetrier-Caux C, Schemann S, Négrier S, Philip T, Favrot M. Role of interleukin-6 in the paraneoplastic inflammatory syndrome associated with renal-cell carcinoma. *Int J Cancer*. 1997; **72**(3): 424-30. [PMID: 9247285]; [PMCID: PMC9247285]
13. Tsou P, Katayama H, Ostrin EJ, Hanash SM. The Emerging Role of B Cells in Tumor Immunity. *Cancer Res*. 2016; **76**(19): 5597-601. [DOI: 10.1158/0008-5472.CAN-16-0431]; [PMID: 27634765]
14. Nenova IS, Valcheva MY, Beleva EA, Tumbeva DY, Yaneva MP, Rancheva EL, Grudeva-Popova ZG. Autoimmune Phenomena in Patients with Solid Tumors. *Folia Med (Plovdiv)*. 2016; **58**(3): 195-9. [DOI: 10.1515/folmed-2016-0026]; [PMID: 27760006]
15. Chuang YC, Lin AT, Chen KK, Chang YH, Chen MT, Chang LS. Paraneoplastic elevation of serum alkaline phosphatase in renal cell carcinoma: incidence and implication on prognosis. *J Urol*. 1997; **158**(5): 1684-7. [DOI: 10.1016/S0022-5347(01)64095-3]; [PMID: 9334578]; [PMCID: PMC9334578]
16. Girotra M, Abraham RR, Pahwa M, Arora M. Is Stauffer's syndrome an early indicator of RCC recurrence? *ANZ J Surg*. 2010; **80**(12): 949-50. [DOI: 10.1111/j.1445-2197.2010.05563.x]; [PMID: 21114744]
17. Strickland RC, Schenker S. The nephrogenic hepatic dysfunction syndrome: a review. *Am J Dig Dis*. 1977; **22**(1): 49-55. [PMID: 319656]
18. Dourakis SP, Sinani C, Deutsch M, Dimitriadou E, Hadziyannis SJ. Cholestatic jaundice as a paraneoplastic manifestation of renal cell carcinoma. *Eur J Gastroenterol Hepatol*. 1997; **9**(3): 311-4. [PMID: 9096437]; [PMCID: PMC9096437]
19. Morla D, Alazemi S, Lichtstein D. Stauffer's syndrome variant with cholestatic jaundice: a case report. *J Gen Intern Med*. 2006; **21**(7): C11-3. [DOI: 10.1111/j.1525-1497.2006.00448.x]; [PMID: 16808761]; [PMCID: PMC924715]
20. Giannakos G, Papanicolaou X, Trafalis D, Michaelidis I, Margaritis G, Christofilakis C. Stauffer's syndrome variant associated with renal cell carcinoma. *Int J Urol*. 2005; **12**(8): 757-9. [DOI: 10.1111/j.1442-2042.2005.01149.x]; [PMID: 16174051]
21. Woldie I, Manickam P, Choi M, Shi D, Burks F, Vaishampayan U. An infrequent variant of Stauffer's syndrome. *Acta Gastroenterol Belg*. 2012; **75**(3): 379-80. [PMID: 23082719]
22. Fernandez AB, de Avila AS. Prothrombin complex concentrate (Octaplex(R)) for postsurgical bleeding control in a Stauffer's syndrome. *Ann Hematol*. 2012; **91**(8): 1325-6. [DOI: 10.1007/s00277-011-1396-8]; [PMID: 22258327]
23. Akbulut S, Baysal A, Topal F. Paraneoplastic presentation of cholestatic jaundice in renal cell carcinoma. *Turk J Gastroenterol*.

2014; **25**(3): 340-1. [DOI: 10.5152/tjg.2014.6048]; [PMID: 25141330].

24. Jangouk P, Hashash JG. An unusual cause of painless jaundice. Renal cell carcinoma (Stauffer syndrome). *Gastroenterology*. 2014; **146**(4): 913, 1138. [DOI: 10.1053/j.gastro.2013.12.038]; [PMID: 24560853]
25. Puga M, Gonzalez-Ballina E, Rivas-Moral L. Stauffer's Syndrome

Variant as an Unusual Case of Painless Jaundice. *Clinical gastroenterology and hepatology: the official clinical practice journal of the American Gastroenterological Association*. 2015; **13**(9): A25-6. [DOI: 10.1016/j.cgh.2015.05.011]; [PMID: 25979213]

Peer reviewer: Hany Shabana