

A Review Of Inflammatory Bowel Disease Unclassified --Indeterminate Colitis

Batool Mutar Mahdi

Batool Mutar Mahdi, Department Of Microbiology, Al-Kindi College Of Medicine, Baghdad University, AL-Nahda Square, Baghdad, Iraq

Correspondence: Batool Mutar Mahdi, Department Of Microbiology, Al-Kindi College Of Medicine, Baghdad University, AL-Nahda Square, Baghdad, Iraq. batool1966@yahoo.com

Telephone: +096417702553215

Received: June 11, 2012

Revised: July 6, 2012

Accepted: July 8, 2012

Published online: November 21, 2012

ABSTRACT

The precise diagnosis of colitis cannot always be established with the available diagnostic tools. A diagnosis of Crohn's disease (CD) and ulcerative colitis (UC) is based on a mixture of clinical, histologic, endoscopic, and radiologic results. The difference between UC and CD can be difficult because of the lack of a differentiating single gold standard. Indeterminate colitis (IC) or inflammatory bowel disease unclassified (IBDU) was introduced by pathologists for the diagnosis of surgical colectomy specimens showing an overlap between the features of UC and CD. The term indeterminate colitis is more widely applied to include all cases with endoscopic, radiographic, and histologic evidence of chronic inflammatory bowel disease confined to the colon, but without fulfillment of diagnostic criteria for UC and CD. IC is generally considered to be a temporary diagnosis. Furthermore, serologic markers such as perinuclear antineutrophil cytoplasmic antibody and anti-Saccharomyces cerevisiae, which are strongly linked with UC and CD and other autoantibodies may be of value in the diagnosis. The possibility that IC could be a separate entity must be investigated and the diagnosis of IC or inflammatory bowel disease unclassified was based on macroscopic and microscopic features, serologic, radiologic, endoscopic presentation. The definition of IBDU is valuable in clinical practice for those who had no clear clinical, endoscopic, histological, or other features affording a diagnosis of either UC or CD, IBDU could be used incidentally. The abnormality in the immune system will favor the use of biologic therapy that neutralize the pro-inflammatory cytokines and use of anti-inflammatory cytokines instead of corticosteroid and immunosuppressive drugs.

© 2012 Thomson research. All rights reserved.

Key words: Ulcerative colitis; Crohn's disease; Indeterminate colitis; Inflammatory bowel disease unclassified

Mahdi BM. A Review Of Inflammatory Bowel Disease Unclassified --Indeterminate Colitis. *Journal of Gastroenterology and Hepatology Research* 2012; 1(10): 241-246 Available from: URL: <http://www.ghrnet.org/index./joghr/>

INTRODUCTION

Indeterminate colitis (IC) is a vague term that requires qualification to identify the criteria that are applied when it is used as a diagnosis. Indeterminate colitis is not currently recognized as a diagnosis in the International Classification of Diseases, 9th revision, Clinical Modification (ICD-9-CM), or in the International Statistical Classification of Disease and Related Health Problem, 10th revision, version of 2006 (ICD-10). World Health Organization approved revisions at a meeting in Tokyo in October 2005, and the diagnosis; indeterminate colitis will be added to the ICD-10 2009^[1]. The term indeterminate colitis is controversial. Pathologist Price originally used this term in 1978 to describe colectomy specimens in which no specific features for either Crohn's disease (CD) or ulcerative colitis (UC) were seen^[2]. Kent *et al* 1979^[3] used the term indeterminate colitis when evaluation rendered a diagnosis of UC or Crohn's indefinite. Burakoff supported the basis that IC may be a separate entity in 2004^[4]. This term used by clinician in whom a diagnosis of UC or CD cannot be made based on standard clinical testing, including colonoscopy, imaging, laboratory tests, and biopsy. The pathologist Geboes K *et al* 2009^[5] used the term inflammatory bowel disease unclassified and the surgeons used the term indeterminate colitis for the same condition.

Epidemiology

Indeterminate colitis remains a mysterious inflammatory bowel disease (IBD) phenotype. A small number of statistics are available on the incidence and prevalence of IC in the general population. Several studies have consistently shown that such a diagnosis could be made in 5%-15% of inflammatory bowel disease cases. This figure has not been changed over the past 30 years, despite the introduction of newer diagnostic modalities^[6]. In adults, an incidence of about 1/100 000/year and a prevalence of 3-7/100 000 were found in some European countries (Denmark, Hungary, Spain, Holland) but a higher

incidence (about 2.5/100 000/year) has been reported in Scandinavia and Canada^[7]. Many population-based studies and hospital-based surveys have consistently found that, in adults, IC accounts for 3%-6% of all initial IBD diagnoses in Europe, as well as in Australia, Japan, Lebanon, Saudi Arabia, and South Africa; slightly lower figures have been occasionally reported from some south-European areas, and much higher figures (10%-18%) in a single study from Canada^[8]. By contrast, the frequency of IC appears to be higher (up to 29%) among children, especially in northern Europe. The incidence of IC in children has been assessed in Sweden, France, and Wales, ranging from 0.12-0.7/100 000/year^[7]. A meta-analysis study showed that frequency of IC is higher in children 12.7% than in adults 6%. In both children and adults IC was more frequent in prospective studies compared to retrospective studies^[9]. From the literature, IC cases show an equal sex distribution and the mean age at onset is 36-39 years^[10,11,12]. IC is diagnosed in between 9% and 20% of colectomy specimens^[13]. Thus, we conclude from above that epidemiology of this disease will become more obvious once a diagnostic test will be available to diagnose IC because this disease still in between UC and CD.

Etiology

The causes of IC remains unknown. Thus, we revise the different aspects of this disease in order to reach some possible causes.

Histopathological Aspect

Inflammatory bowel disease represents a spectrum of disease, both macroscopically and microscopically, with classical UC and classical CD at either end but numerous cases liberally distributed in the spectrum between. Some of these cases, especially those in the middle ground, represent ‘indeterminate colitis’. Pathologists consider macroscopic assessment of colorectal resection specimens is important as microscopic assessment. The characteristic features of UC are a continuous mucosocentric pathology, with the rectum bearing the brunt of the disease and a variable extension of disease proximally. Ulcerative appendicitis (UA), the appendiceal counterpart of ulcerative colitis (UC), is frequently present in colectomy specimens from patients with universal UC and is regarded as part of the continuous inflammatory process that is a hallmark of this disease. On the other hand, CD shows a fibro-stricturing pathology and the other primarily inflammatory and associated with deep fissures and fistulation^[14].

It is no surprise that IC cases show overlap of these two disease processes (Table 1)^[15].

Table 1 Morphological macroscopic features seen in indeterminate.

Morphological macroscopic features seen in indeterminate	
1	colitis
2	Extensive ulceration
3	Involvement of transverse and right colon (more severely than distal colon)
4	Involvement of >50% of the mucosal surface
5	Usually diffuse disease, but may show rectal sparing
6	Toxic dilation may be present

The affected colorectum in IC demonstrates an extensive colitis, which itself can take two main patterns. The first pattern is that of severe continuous disease throughout the colon, often with relative rectal sparing, more than 50% of the mucosal surface of the colon is involved and the disease process tends to affect the right and transverse colon more severely than the left (Figure 1). While in CD, there is an inflammation involves the full thickness of the wall from the mucosa to the serosa with granuloma formation.

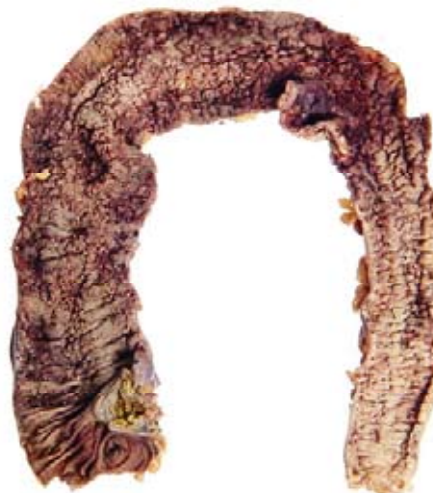

Figure 1 A total colectomy specimen showing indeterminate colitis. There is continuous disease more proximally with relative rectal sparing. The transverse colon is dilated with early ‘toxic megacolon’. The involved areas show widespread ulceration^[15].

The second is that of extensive intermittent ulceration that can give the false impression of skip lesions (Figures 2 and 3). The mucosa between these ulcers may appear normal. Fissures may also be seen macroscopically. Some of the cases may be diagnosed radiologically as ‘toxic megacolon’ and show dilation accordingly^[16,17]. In UC the inflammation involves the superficial mucosal layer with infiltration of lymphocytes, granulocytes and loss of goblet cells. In addition to that presence of ulceration and crypt abscesses.




Figure 2 A total colectomy specimen showing indeterminate colitis. The transverse colon is notably dilated and there is extensive ulceration with the appearance of ‘skip lesions’. The depth of the ulceration is evidenced by the fact that muscularis propria is discernible in the bed of the more extensive areas of ulceration, especially in the transverse colon^[15].

Microscopically: The picture is dominated by severe and extensive ulceration (Figure 4) (Table 2) seen in in areas of the colon that are maximally dilated very severe cases will show very extensive ulceration almost throughout the colon and rectum. Because of the fulminant disease, IC also shows myocytolysis, telangiectasia and some fissuring.

This Scanty deep penetrating slit-like fissures, described more recently by some authors as ‘knife-like’, spreading into the superficial half of the muscularis propria^[18,19].

The quality of the fissuring ulcers is different from that seen in CD. The fissures may take the form of either squat V-shaped clefts or knife-like breaks, both of which may extend into the submucosa and may extend into the superficial muscularis propria (Figures 4

, Sand 6). The V-shaped clefts of IC tend to be sparsely lined by inflammatory cells the adjacent bowel shows myocytolysis and capillary engorgement^[18]. These ulcers are associated with marked chronic inflammation in the adjacent mucosa. They may be relatively deep and extend into the superficial muscularis propria.

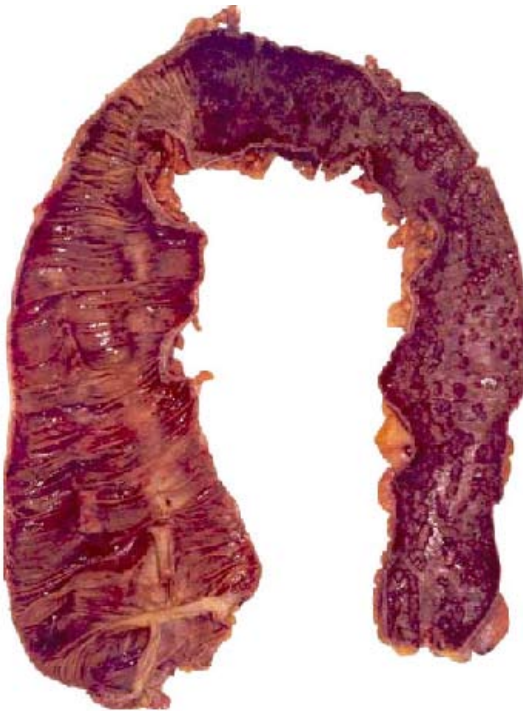

Figure 3 A total colectomy specimen showing indeterminate colitis (IC). Perhaps the features here might seem to favour ulcerative colitis (UC), as there is continuous distal disease, but there is focal inflammation and ulceration in the proximal colon, producing skip lesions. There are few stigmata of chronic UC microscopically and this serves to sustain the designation of IC^[15].

Table 2 Morphological microscopic features seen in indeterminate colitis.

Morphological microscopic features seen in indeterminate	
1	Extensive ulceration with a sharp transition to normal adjacent mucosa
2	Transmural lymphoid inflammation, with an absence of lymphoid aggregates
3	Absence of well-defined, epithelioid granulomas distant from crypts
4	Multiple squat V-shaped ulcers, lacking surrounding inflammation
5	Scanty deep penetrating slit-like fissures

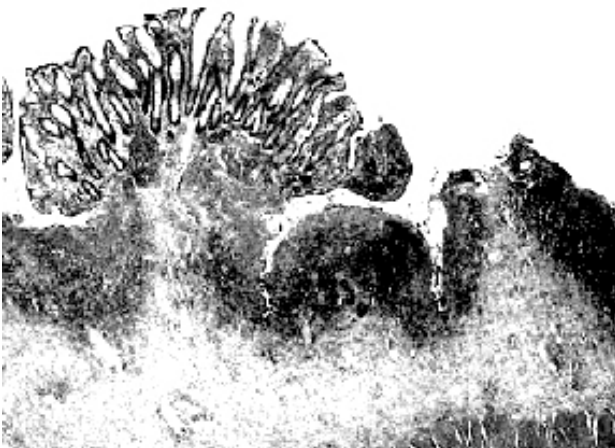


Figure 4 The microscopy of indeterminate colitis. There is extensive ulceration with typical superficial V-shaped fissures, parallel to each other. The surviving mucosal islands show modest stigmata of chronic inflammatory bowel disease^[15].

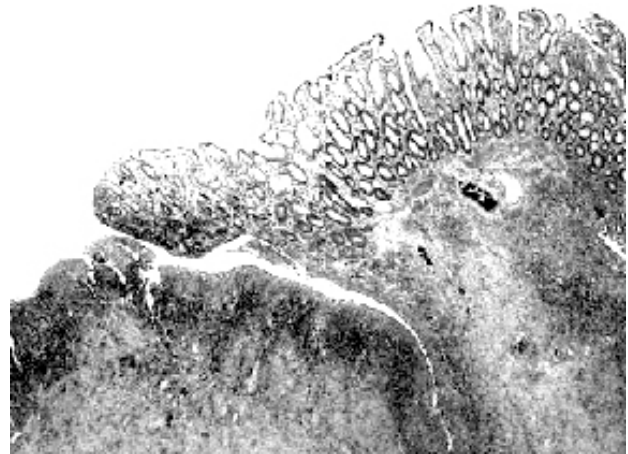


Figure 5 This case of indeterminate colitis shows undermining ulceration with fissuring beneath intact mucosa. The latter shows chronic inflammation but little crypt architectural change^[15].

SEROLOGICAL MARKERS

This disease results from an aberrant immune response and loss of tolerance to many self-antigens, leading to chronic inflammation of the gut. This idea is supported by the occurrence of antibodies directed to microbial and self antigens and increased levels of various autoantibodies directed against bacterial components and cross-reactive antigens^[20]. Peeters *et al* 2001^[21] evaluated patients with IC prospectively to determine if the serological autoantibody tests might be helpful in improving the diagnostic accuracy of categorizing IC. Autoimmune disorders form part of a broad spectrum of diseases which are often associated with impaired Treg production or maintenance^[22]. Joosens *et al* 2002 in a multicenter prospective study, had found that ASCA + /pANCA- predicts CD in 80% of patients with IC and ASCA- /pANCA + predicts UC in 63.6%. Patients who remain IC do not show antibodies against ASCA or pANCA^[23]. Other study done in 2011 demonstrated that sera of patients suffering from inflammatory bowel disease unclassified contain Auto-antibodies reacting with one or more antigens (pANCA 66.6%, ASCA 58.3%, exocrine part of pancreatic acinar cells 53.3% and intestinal goblet cells 3.33%) and significantly different from others UC and control groups. The Auto-antibodies were of mixed isotypes (IgG, IgM and IgA)^[24]. ASCA develops due to an increased permeability of yeast antigens in the small bowel which activates immune cells^[25]. In case of pANCAs, they are directed against antigens in the nuclei, the granules and the cytosol^[26]. Other Auto-antibodies such as exocrine pancreas which is found in 30% of CD patients^[27] is directed against normal pancreatic juice^[28]. There is a variations in the development of Auto-antibodies may be due to genetic factors^[29], geographical^[30], and ethnic factors^[31], socioeconomic status^[32] and human leukocyte antigen (HLA) typing^[33]. These serological markers are important in the diagnosis, management, disease monitoring, severity and prognosis of disease in UC and CD or inflammatory bowel disease unclassified. Other authors found that serology might not be helpful in diagnosis of IC and both of perinuclear antinutrophil cytoplasmic antibodies and anti *Saccharomyces cerevisiae* antibodies are negative in patients with indeterminate colitis^[34,35] while Tremaine 2007^[36] demonstrated that diagnosis of inflammatory bowel disease unclassified by exclusion and serological studies would not be diagnostic for indeterminate colitis until (if) there exists at least one test that positively identifies the subgroup. In addition to that, Tremaine 2011^[37] reported that the most reliable technique for evaluating patients with indeterminate colitis is serology. The serologic markers that have proven most useful

for diagnosing indeterminate colitis are anti-Saccharomyces cerevisiae antibody (ASCA) and perinuclear antineutrophil cytoplasmic antibody (pANCA), also known as nuclear-specific antigen. Most patients with indeterminate colitis are negative for both of these markers. Thus, testing for these markers can help clinicians predict whether patients will maintain a long-term diagnosis of indeterminate colitis. Typically, patients who lack these markers continue to have indeterminate colitis, whereas patients who have one or both of these markers will likely manifest with CD or UC over time. Other study concluded the auto-immune nature of this disease and there are some antigens originating from gastrointestinal tract or the bile system that may be involved in the initiation of this disease^[24].

Genetic study

In 2001, CD was shown to be associated with variants of the gene CARD15/NOD2 on chromosome 16, the gene product of which is involved in controlling the gut inflammatory response to bacteria^[38]. Mutations in this gene are almost always associated with CD. The contribution of the HLA region, which has been widely studied, shows low sensitivity and specificity for CD and UC. Although it is very early days, such genetic analyses have considerable potential so that, in the future, we may have much more rigorous^[39]. Genomic surveys have identified IL23R and IL12B as susceptibility loci for inflammatory bowel disease and there is an association of IL23R and IL12B with IBD in the Spanish population^[40]. It had been found that IL12B SNP rs6887695 modulates the susceptibility and the phenotype of IBD^[41]. Other study found a highly significant association between Crohn's disease and the IL23R gene on chromosome 1p31, which encodes a subunit of the receptor for the proinflammatory cytokine interleukin-23. An uncommon coding variant (rs11209026, c.1142G>A, p.Arg381Gln) confers strong protection against Crohn's disease^[42].

Immunological features in intestinal mucosa

Mucosal inflammation is almost always mediated by one of two pathways: either an excessive Th1 response that is associated with increased secretion of IL-12, gamma interferon and TNF or an excessive Th2 response that is associated with increased secretion of IL-4, IL-5 and IL-13^[43]. Crohn's disease is due to stimulation of Th1 and ulcerative colitis is due to stimulation of Th2^[44]. Mucosal T cells from indeterminate colitis exhibit an intrinsic hyperreactivity to IL-2 and grew similarly to those of CD mucosa. This may represent a primary pathogenic abnormality in this condition^[45]. Other study demonstrated that there is an increase in IL-10 and INF-gamma levels and decrease in TNF-alfa levels in patients with IC^[46]. The abnormality in the immune system will favor the use of biologic therapy that neutralize the pro-inflammatory cytokines and use of anti-inflammatory cytokines instead of corticosteroid and immunosuppressive drugs.

Diagnosis

It is generally believed that in most cases IC merely represents a provisional diagnosis; indeed, follow-up studies have shown that a vast proportion (up to 80%) of patients are eventually reclassified as being affected by either CD or UC, and up to 20% as not affected by IBD. However, a small subset of patients exists in which IC still remains the most accurate diagnosis a long time after disease onset (more than 10 years). It is likely that in such cases IC really represents a separate clinical entity^[8]. In more recent years, Capsule Endoscopy (CE) has been emerging as a promising tool to identify subtle small bowel abnormalities in patients with IC, thus allowing a change in

diagnosis to CD or UC^[47]. Patients with longstanding IBDU/IC and negative serology, CE can detect small-bowel lesions which lead to a CD diagnosis in a significant proportion of patients^[48]. Thus, authors hope that progress being made in genetic, serological, colonoscopic and radiologic imaging studies leads to more reliable phenotyping and easily diagnosis of indeterminate colitis^[49]. The definition of IBDU is valuable in clinical practice for those who had no clear clinical, endoscopic, histological, or other features affording a diagnosis of either UC or CD, IBDU could be used incidentally^[50].

Treatment of indeterminate colitis

Patients with indeterminate colitis are often managed the same as patients who have UC; clinicians usually use the same drug regimen and surgical approach for both groups and patients with indeterminate colitis have more complications following colectomy than patients with UC, but they do better than patients with CD^[37]. Others use biologic therapy that neutralize the pro-inflammatory cytokines and use of anti-inflammatory cytokines instead of corticosteroid and immunosuppressive drugs^[51].

CONCLUSIONS

The term indeterminate colitis is more widely applied to include all cases with endoscopic, radiographic, and histologic evidence of chronic inflammatory bowel disease confined to the colon, but without fulfillment of diagnostic criteria for UC and CD. Capsule endoscopy, genetic and serology will be added to confirm the diagnosis. Immunologic abnormalities in patients with IC will favor the use of biologic immune therapy as an alternative tool to treat IC.

REFERENCES

- 1 International Classifications of Diseases (ICD). World Health Organization [Website]. 2006. Available at: <http://www3.who.int/icd/currentversion/fr-icd.htm>, accessed on 29 August 2006.
- 2 Price AB. Overlap in the spectrum of non-specific inflammatory bowel disease--colitis indeterminate'. *J Clin Pathol* 1978; **31**: 567-577
- 3 Kent TH, Ammon RK, DenBesten L. Differentiation of ulcerative colitis and regional enteritis. *Arch Pathol* 1979; **89**: 20-29
- 4 Burakoff R. Indeterminate colitis: clinical spectrum of disease. *J Clin Gastroenterol* 2004; **38**: S41-S43
- 5 Geboes K, Van Eyken P. Inflammatory bowel disease unclassified and indeterminate colitis: the role of the pathologist. *J Clin Pathol* 2009; **62**: 201-205
- 6 Tremaine WJ. Diagnosis and treatment of indeterminate colitis. *Gastroenterol Hepatol (N Y)* 2011; **7**: 826-828
- 7 Nicholls RJ, Wells AD. Indeterminate colitis. *Baillieres Clin Gastroenterol* 1992; **6**: 105-112
- 8 Meucci G. What is the incidence, prevalence, and natural history of indeterminate colitis? *Inflamm Bowel Dis* 2008; **14** Suppl 2: S159-S160
- 9 Prenzel F, Uhlig HH. Frequency of indeterminate colitis in children and adults with IBD - a metaanalysis. *J Crohns Colitis* 2009; **3**: 277-281
- 10 Wells AD, McMillan I, Price AB, Ritchie JK, Nicholls RJ. Natural history of indeterminate colitis. *Br J Surg* 1991; **78**: 179-181
- 11 Meucci G, Bortoli A, Riccioli FA, Girelli CM, Radaelli F, Rivolta R, Tatarella M. Frequency and clinical evolution of indeterminate colitis: a retrospective multi-centre study in northern Italy. GSMII (Gruppo di Studio per le Malattie Infiammatorie Intestinali). *Eur J Gastroenterol Hepatol* 1999; **11**:

- 909-913
- 12 Dayton MT, Larsen KR, Christiansen DD. Similar functional results and complications after ileal pouch-anal anastomosis in patients with indeterminate vs ulcerative colitis. *Arch Surg* 2002; **137**: 690-694
 - 13 Rudolph WG, Uthoff SM, McAuliffe TL, Goode ET, Petras RE, Galandiuk S. Indeterminate colitis: the real story. *Dis Colon Rectum* 2002; **45**: 1528-1534
 - 14 Borley NR, Mortensen NJ, Chaudry MA, Mohammed S, Clarke T, Jewell DP. Evidence for separate disease phenotypes in intestinal Crohn's disease. *Br J Surg* 2002; **89**: 201-205
 - 15 Martland GT, Shepherd NA. Indeterminate colitis: definition, diagnosis, implications and a plea for nosological sanity. *Histopathology* 2007; **50**: 83-96
 - 16 Guindi M, Riddell RH. Indeterminate colitis. *J Clin Pathol* 2004; **57**: 1233-1244
 - 17 Lee KS, Medline A, Shockey S. Indeterminate colitis in the spectrum of inflammatory bowel disease. *Arch Pathol Lab Med* 1979; **103**: 173-176
 - 18 Yantiss RK, Farraye FA, O'Brien MJ, Fruin AB, Stucchi AF, Becker JM, Reddy SI, Odze RD. Prognostic significance of superficial fissuring ulceration in patients with severe "indeterminate" colitis. *Am J Surg Pathol* 2006; **30**: 165-170
 - 19 Yantiss RK, Odze RD. Diagnostic difficulties in inflammatory bowel disease pathology. *Histopathology* 2006; **48**: 116-132
 - 20 Plevy S. Do serological markers and cytokines determine the indeterminate? *J Clin Gastroenterol* 2004; **38**: S51-S56
 - 21 Peeters M, Joossens S, Vermeire S, Vlietinck R, Bossuyt X, Rutgeerts P. Diagnostic value of anti-Saccharomyces cerevisiae and antineutrophil cytoplasmic autoantibodies in inflammatory bowel disease. *Am J Gastroenterol* 2001; **96**: 730-734
 - 22 Barreto M, Ferreira RC, Lourenço L, Moraes-Fontes MF, Santos E, Alves M, Carvalho C, Martins B, Andreia R, Viana JF, Vasconcelos C, Mota-Vieira L, Ferreira C, Demengeot J, Vicente AM. Low frequency of CD4+CD25+ Treg in SLE patients: a heritable trait associated with CTLA4 and TGFbeta gene variants. *BMC Immunol* 2009; **10**: 5
 - 23 Joossens S, Reinisch W, Vermeire S, Sendid B, Poulain D, Peeters M, Geboes K, Bossuyt X, Vandewalle P, Oberhuber G, Vogelsang H, Rutgeerts P, Colombel JF. The value of serologic markers in indeterminate colitis: a prospective follow-up study. *Gastroenterology* 2002; **122**: 1242-1247
 - 24 Mahdi BM. Auto-antibodies in Patients with Inflammatory Bowel Disease Unclassified. *Iran J Immunol* 2011; **8**: 189-194
 - 25 Vermeire S, Peeters M, Vlietinck R, Joossens S, Den Hond E, Bulteel V, Bossuyt X, Geypens B, Rutgeerts P. Anti-Saccharomyces cerevisiae antibodies (ASCA), phenotypes of IBD, and intestinal permeability: a study in IBD families. *Inflamm Bowel Dis* 2001; **7**: 8-15
 - 26 Wiik A. Neutrophil-specific autoantibodies in chronic inflammatory bowel diseases. *Autoimmun Rev* 2002; **1**: 67-72
 - 27 Stöcker W, Otte M, Ulrich S, Normann D, Finkbeiner H, Stöcker K, Jantschek G, Scriba PC. Autoimmunity to pancreatic juice in Crohn's disease. Results of an autoantibody screening in patients with chronic inflammatory bowel disease. *Scand J Gastroenterol Suppl* 1987; **139**: 41-52
 - 28 Joossens S, Vermeire S, Van Steen K, Godefroid G, Claessens G, Pierik M, Vlietinck R, Aerts R, Rutgeerts P, Bossuyt X. Pancreatic autoantibodies in inflammatory bowel disease. *Inflamm Bowel Dis* 2004; **10**: 771-777
 - 29 Hugot JP, Chamaillard M, Zouali H, Lesage S, Cézard JP, Belaiche J, Almer S, Tysk C, O'Morain CA, Gassull M, Binder V, Finkel Y, Cortot A, Modigliani R, Laurent-Puig P, Gower-Rousseau C, Macry J, Colombel JF, Sahbatou M, Thomas G. Association of NOD2 leucine-rich repeat variants with susceptibility to Crohn's disease. *Nature* 2001; **411**: 599-603
 - 30 Hiatt RA, Kaufman L. Epidemiology of inflammatory bowel disease in a defined northern California population. *West J Med* 1988; **149**: 541-546
 - 31 Wright JP, Froggatt J, O'Keefe EA, Ackerman S, Watermeyer S, Louw J, Adams G, Girdwood AH, Burns DG, Marks IN. The epidemiology of inflammatory bowel disease in Cape Town 1980-1984. *S Afr Med J* 1986; **70**: 10-15
 - 32 Blanchard JF, Bernstein CN, Wajda A, Rawsthorne P. Small-area variations and sociodemographic correlates for the incidence of Crohn's disease and ulcerative colitis. *Am J Epidemiol* 2001; **154**: 328-335
 - 33 van Heel DA, Fisher SA, Kirby A, Daly MJ, Rioux JD, Lewis CM. Inflammatory bowel disease susceptibility loci defined by genome scan meta-analysis of 1952 affected relative pairs. *Hum Mol Genet* 2004; **13**: 763-770
 - 34 Matsui T, Yao T, Sakurai T, Yao K, Hirai F, Mataka H, Tsuda S, Wada Y, Iwashita A, Kamachi S. Clinical features and pattern of indeterminate colitis: Crohn's disease with ulcerative colitis-like clinical presentation. *J Gastroenterol* 2003; **38**: 647-655
 - 35 Geboes K, De Hertogh G. Indeterminate colitis. *Inflamm Bowel Dis* 2003; **9**: 324-331
 - 36 Tremaine WJ. Review article: Indeterminate colitis—definition, diagnosis and management. *Aliment Pharmacol Ther* 2007; **25**: 13-17
 - 37 Tremaine WJ. Diagnosis and treatment of indeterminate colitis. *Gastroenterology & Hepatology* 2011; **7**: 826-828
 - 38 Ogura Y, Bonen DK, Inohara N, Nicolae DL, Chen FF, Ramos R, Britton H, Moran T, Karaliuskas R, Duerr RH, Achkar JP, Brant SR, Bayless TM, Kirschner BS, Hanauer SB, Nuñez G, Cho JH. A frameshift mutation in NOD2 associated with susceptibility to Crohn's disease. *Nature* 2001; **411**: 603-606
 - 39 Satsangi J, Silverberg MS, Vermeire S, Colombel JF. The Montreal classification of inflammatory bowel disease: controversies, consensus, and implications. *Gut* 2006; **55**: 749-753
 - 40 Márquez A, Mendoza JL, Taxonera C, Díaz-Rubio M, De La Concha EG, Urcelay E, Martínez A. IL23R and IL12B polymorphisms in Spanish IBD patients: no evidence of interaction. *Inflamm Bowel Dis* 2008; **14**: 1192-1196
 - 41 Glas J, Seiderer J, Wagner J, Olszak T, Fries C, Tillack C, Friedrich M, Beigel F, Stallhofer J, Steib C, Wetzke M, Göke B, Ochsenkühn T, Diegelmann J, Czamara D, Brand S. Analysis of IL12B gene variants in inflammatory bowel disease. *PLoS One* 2012; **7**: e34349
 - 42 Duerr RH, Taylor KD, Brant SR, Rioux JD, Silverberg MS, Daly MJ, Steinhart AH, Abraham C, Regueiro M, Griffiths A, Dassopoulos T, Bitton A, Yang H, Targan S, Datta LW, Kistner EO, Schumm LP, Lee AT, Gregersen PK, Barmada MM, Rotter JI, Nicolae DL, Cho JH. A genome-wide association study identifies IL23R as an inflammatory bowel disease gene. *Science* 2006; **314**: 1461-1463
 - 43 Strober W, Fuss IJ, Blumberg RS. The immunology of mucosal models of inflammation. *Annu Rev Immunol* 2002; **20**: 495-549
 - 44 Bouma G, Strober W. The immunological and genetic basis of inflammatory bowel disease. *Nat Rev Immunol* 2003; **3**: 521-533
 - 45 Kugathasan S, Willis J, Dahms BB, O'Riordan MA, Hupertz V, Binion DG, Boyle JT, Focchi C. Intrinsic hyperreactivity of mucosal T cells to interleukin-2 in pediatric Crohn's disease. *J Pediatr* 1998; **133**: 675-681
 - 46 Mahdi BM. The relationship between helicobacter pylori infection and gastro-esophageal reflux disease. *N Am J Med Sci* 2011; **3**: 142-145
 - 47 Lopes S, Figueiredo P, Portela F, Freire P, Almeida N, Lérias C, Gouveia H, Leitão MC. Capsule endoscopy in inflammatory bowel disease type unclassified and indeterminate colitis serologically negative. *Inflamm Bowel Dis* 2010; **16**: 1663-1668
 - 48 Maunoury V, Savoye G, Bourreille A, Bouhnik Y, Jarry M,

- Sacher-Huvelin S, Ben Soussan E, Lerebours E, Galmiche JP, Colombel JF. Value of wireless capsule endoscopy in patients with indeterminate colitis (inflammatory bowel disease type unclassified). *Inflamm Bowel Dis* 2007; **13**: 152-155
- 49 Bousvaros A, Antonioli DA, Colletti RB, Dubinsky MC, Glickman JN, Gold BD, Griffiths AM, Jevon GP, Higuchi LM, Hyams JS, Kirschner BS, Kugathasan S, Baldassano RN, Russo PA. Differentiating ulcerative colitis from Crohn disease in children and young adults: report of a working group of the North American Society for Pediatric Gastroenterology, Hepatology, and Nutrition and the Crohn's and Colitis Foundation of America. *J Pediatr Gastroenterol Nutr* 2007; **44**: 653-674
- 50 Zhou N, Chen WX, Chen SH, Xu CF, Li YM. Inflammatory bowel disease unclassified. *J Zhejiang Univ Sci B* 2011; **12**: 280-286
- 51 Owczarek D, Cibor D, Szczepanek M, Mach T. Biological therapy of inflammatory bowel disease. *Pol Arch Med Wewn* 2009; **119**: 84-88
- peer reviewers:** Ole Haagen Nielsen, Department of Gastroenterology DM 112, Herlev Hospital, University of Copenhagen, Herlev Ringvej 75, DK-2730 Herlev, Denmark; Takayuki Yamamoto, Inflammatory Bowel Disease Center, Yokkaichi Social Insurance Hospital, 10-8 Hazuyamacho, Yokkaichi, Mie 510-0016, Japan; Zhan-ju Liu, department of Gastroenterology, Shanghai Tenth People's Hospital, Tongji University, No. 301 Yanchang Road, Shanghai 200072, China.