

Acute Liver Injury Associated with Anorexia Nervosa

Omar I. Massoud, D. Ralph Crowe

Omar I. Massoud, Liver Center, Division of Gastroenterology and Hepatology, School of Medicine, University of Alabama at Birmingham, Birmingham, Alabama, the Unites States

D. Ralph Crowe, Department of Pathology, School of Medicine, University of Alabama at Birmingham, Birmingham, Alabama, the Unites States

Conflict-of-interest statement: The authors declare that there is no conflict of interest regarding the publication of this paper.

Open-Access: This article is an open-access article which was selected by an in-house editor and fully peer-reviewed by external reviewers. It is distributed in accordance with the Creative Commons Attribution Non Commercial (CC BY-NC 4.0) license, which permits others to distribute, remix, adapt, build upon this work non-commercially, and license their derivative works on different terms, provided the original work is properly cited and the use is non-commercial. See: <http://creativecommons.org/licenses/by-nc/4.0/>

Correspondence to: Omar Massoud, MD, PhD, Liver Center, University of Alabama at Birmingham, 1808 7th Avenue South, Birmingham, AL 35294, the Unites States.

Email: omassoud@uab.edu

Telephone: +1-205-975-5676

Fax: +1-205-975-97775683

Received: October 12, 2016

Revised: November 20, 2017

Accepted: November 23, 2017

Published online: December 21, 2017

ABSTRACT

While mild to moderate elevation of liver transaminases is common with anorexia nervosa, acute hepatic injury with severe elevation of transaminases and coagulopathy is rare. We report a 24-year male with anorexia nervosa who was presented with acute liver injury. Alanine transferase and aspartate transferase peaked at 2033 IU/mL and 1410 IU/mL respectively. More common causes of acute liver injury were ruled out. Liver biopsy did not show centrilobular necrosis or congestion which are the hallmarks of ischemic liver injury. The patient has improved on re-institution of proper nutrition. In conclusion, acute liver injury can occasionally be caused by anorexia ner-

vosa. The pathophysiologic mechanism involved, on contrary to what previously reported, is unlikely tissue hypoperfusion.

Key words: Acute liver injury; Anorexia nervosa; Elevated liver enzymes

© 2017 The Author(s). Published by ACT Publishing Group Ltd. All rights reserved.

Massoud OI, Crowe DR. Acute Liver Injury Associated with Anorexia Nervosa. *Journal of Gastroenterology and Hepatology Research* 2017; **6(6)**: 2498-2501 Available from: URL: <http://www.ghrnet.org/index.php/joghr/article/view/2158>

INTRODUCTION

Anorexia nervosa is a common eating disorder characterized by refusal to maintain body weight at or above a minimally normal weight for age and height and intense fear of gaining weight^[1-2]. While mild to moderate elevation of liver transaminases is common^[3-7], acute hepatic injury with severe elevation of transaminases and coagulopathy is rare. Few case reports and one small series have been described^[8-12].

The mild to moderate elevation of transaminases likely reflects hepatic steatosis as a consequence of imbalance between hepatic triglyceride synthesis and secretion with decreased in lipoprotein synthesis, due to decreased aminoacid availability^[13]. The mechanism of acute hepatic injury in anorexia nervosa is unclear. Impaired hepatic perfusion as a result of hypotension, bradycardia and dehydration has been suggested^[10-11]. A recent study described increased starvation-induced autophagy in the hepatocytes as a possible mechanism for acute alteration of hepatic function^[14-15].

In this report, we describe an unusual case of a male with anorexia nervosa, who presented with acute hepatic injury with jaundice and coagulopathy.

CASE REPORT

A 24-year old man with anorexia nervosa was transferred from a local hospital for evaluation of marked elevation of hepatic transaminases. He was diagnosed with anorexia nervosa one year earlier according to the Diagnostic and Statistical Manual of Mental Disorders, Fourth Edition (DSM-V)^[1]. The patient presented to his local Emergency Room (ER) for increased weakness, fatigue and 20 pound weight

loss over the last month. In the ER, he was found to have bradycardia (heart rate 37 beat per minute) and hypotension (systolic blood pressure 70 mmHg). His alanine transferase (ALT) and aspartate transferase (AST) were 473 IU/mL and 449 IU/mL respectively. Initial workup including serologic markers for hepatitis A, B and C, autoimmune markers, liver ultrasound and abdominal CT were all unremarkable. On the third hospital day, transaminases increased to more than one thousand IU/mL each, total bilirubin was 3 mg/dL and INR was 1.3. At this point, he was transferred to our center for further evaluation and management of his liver dysfunction.

The patient denied any history of alcohol or drug abuse. There was no history of previous liver disease, diabetes or hyperlipidemia. He was not on any medications prior to hospitalization. In the local hospital he had started on multivitamins, folic acid, thiamin and calcium. There was no family history of liver disease.

On admission his heart rate was 43 beat per minute, blood pressure was 108/73 mmHg, he was afebrile, respiratory rate was 20/minute oxygen saturation was 100% on room air, his weight was 42 Kilograms and his body mass index (BMI) was 16 kg/m². He appeared cachectic with marked temporal wasting. He had mild jaundice. The rest of his physical examination was unremarkable. Laboratory values on admission, as well as liver function tests peak values and values on discharge are shown in table 1 and 2.

Serology for hepatitis A, B, C, CMV and EBV, and autoimmune markers including antinuclear antibody (ANA), antimitochondrial antibody (AMA), antismooth muscle antibody (ASMA) and total IgG were all negative or normal. Serum ceruloplasmin and μ -1 antitrypsin phenotype were normal. Iron studies were abnormal and showed serum ferritin level of 3442 ng/mL and iron saturation of 105%. Hemochromatosis gene testing showed heterozygosity for C282Y gene mutation. Slit-lamp examination was negative for Kayser-Fleischer ring. Serum copper level was normal. Twenty four hour urine copper was slightly elevated at 48 (normal 3-30) mcg/

L. Liver biopsy showed no inflammation, periportal fibrosis, or steatosis. It showed increased stainable iron, but no stainable copper was identified (Figure 1).

During his hospitalization, the patient was followed closely by our nutrition and psychiatric teams. His liver transaminases reached a peak on hospital day 8, with ALT and AST values of 2033 IU/mL and 1410 IU/mL respectively. Following day 8, the patient's transaminases, bilirubin and INR gradually decreased. The patient was discharged on day 11 to complete treatment in an inpatient psychiatric facility. Discharge labs showed significant improvement in liver enzymes, bilirubin and INR (Table 1).

In summary, this is a patient with anorexia nervosa and significant

Table 1 Liver Function Tests on Admission, Peak Values and on Discharge.

	Admission day	Peak day (#8)	Discharge day (#11)
ALT	1620	2033	1236
AST	1486	1410	523
AP	215	279	189
Bili t.	3.3	3.3	2.5
Bili D.	0.4	0.5	0.3
Bili I.	2.9	2.9	2.2
Albumin	3.7	3.7	3.4
INR	1.35	1.48	1.38

Table 2 Complete Blood Count (CBC) and Basic Metabolic Panel (BMP) on Admission.

WBC	3.63
Hb	11.9
Hct%	31
Plat	114
Na	131
K	5.2
Chl.	99
Bicarb	29
Glu	50
BUN	55
Creat	0.9

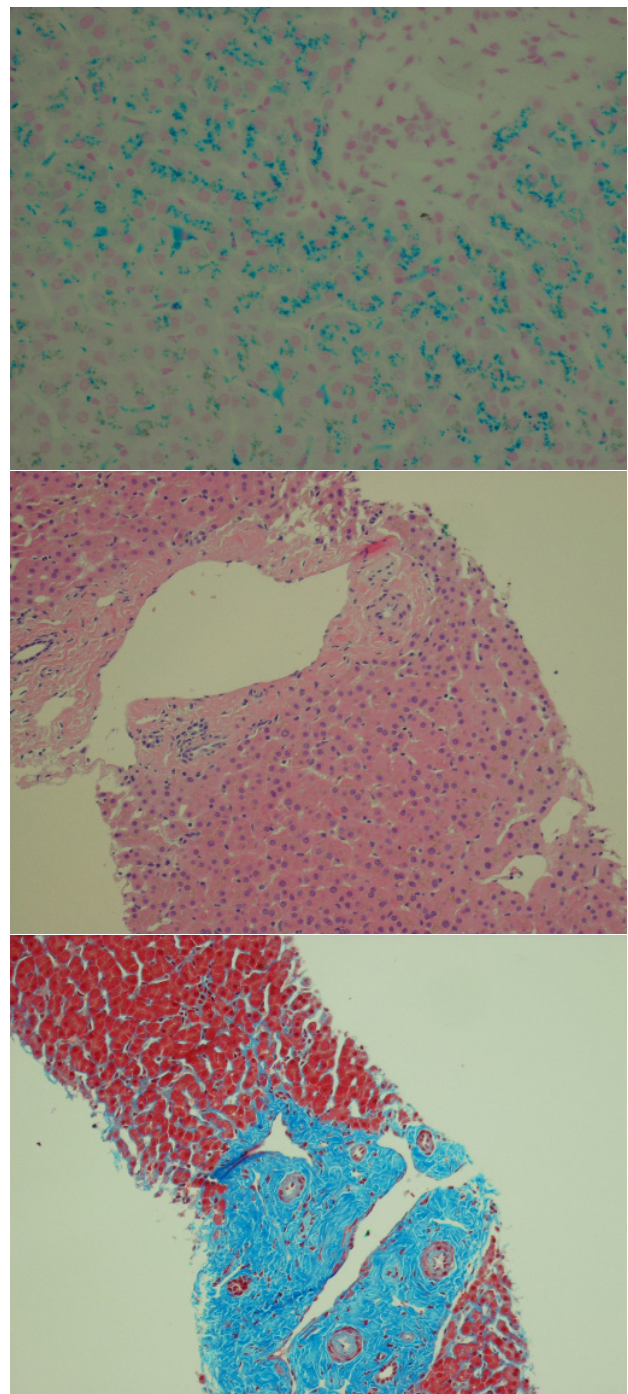


Figure 1 Liver Biopsy Findings.

weight loss who presented with an acute hepatic injury. Common causes of acute hepatic injury were excluded. His condition has improved with the improvement in his nutritional status.

DISCUSSION

It is not unusual to find mild to moderate elevation of liver enzymes, especially transaminases, in patients with anorexia nervosa^[4-7]. This resolves with nutritional improvements in most cases^[8-9]. However, acute hepatic injury with marked elevation of transaminases, jaundice and coagulopathy is rare. Very few cases of acute hepatic injury in anorexia nervosa have been reported^[8-13, 16], with occasional fatal outcome^[16].

In this report, we described a male patient with anorexia nervosa, which is unusual, who presented with acute hepatic injury. More common causes of acute hepatic injury were considered and excluded, including acute viral hepatitis (A, B, C, CMV, EBV), autoimmune hepatitis, drug or alcohol- induced hepatitis and Wilson's disease. Our patient recovered and was discharged to complete psychiatric treatment and rehabilitation. All cases reported in English literature recovered or improved with the exception of one patient who died^[16]. This emphasizes the fact that although recovery is to be expected in most cases, mortality can occasionally occur.

The pathophysiologic mechanism involved in acute liver injury associated with anorexia nervosa is poorly understood. Early reports suggested that hepatic hypoperfusion (ischemic hepatitis) is the main mechanism involved^[10-11]. Bradycardia, hypotension, hypovolemia and low cardiac output are all common findings in anorexia nervosa; all of which can contribute to the development of tissue and organ hypoperfusion including the liver. Pre-renal azotemia is commonly reported with this condition which can also be a manifestation of tissue hypoperfusion. The rapid improvement seen with re-institution of nutrition and hydration supports the hypoperfusion hypothesis.

A recent case series, however, has challenged this concept^[13]. In the largest published case series of acute hepatic injury due to anorexia nervosa, Rautou and his colleagues, examined liver biopsies from 12 patients with acute hepatic injury due to anorexia nervosa. Surprisingly none of the liver biopsies showed centrilobular hepatocellular necrosis or congestion, which are the hallmarks of ischemic hepatitis. The liver biopsy from our patient did not show any evidence of ischemia either. In fact the changes on this liver biopsy were minimal in contrast to the marked elevation of transaminases. These observations indicate that hepatic hypoperfusion may not be the principal mechanism in acute liver injury associated with anorexia nervosa. In Rautou's study, numerous autophagosomes, the hallmark of autophagy, were seen in hepatocytes of 4 patients whom their biopsies were examined by electron microscopy and no autophagosomes were seen in any of the controls^[17]. The results of this study suggest that autophagy may be an important mechanism in acute hepatic injury associated with anorexia nervosa.

In conclusion, acute hepatic injury due to anorexia nervosa may be more common than initially thought. We believe that it is appropriate to include anorexia nervosa in the conditions that can cause acute hepatic injury. Although hepatic hypoperfusion, glycogen depletion and autophagy may play role, more studies are needed to understand the underlying mechanisms of acute hepatic injury associated with anorexia nervosa.

Compliance with Ethical Standard

The authors declare no conflict of interest. All procedures performed in studies involving human participants were in accordance with

the ethical standards of the institutional and/or national research committee and with the 1964 Helsinki declaration and its later amendments or comparable ethical standards.

REFERENCES

- 1 American Psychiatric Association. Diagnostic and statistical manual of mental disorders, 5th ed. text revision. Washington, DC: American Psychiatric Association; 2013. ISBN: 978-0-89042-554-1
- 2 Singhal V, Misra M, Klibanski A. Endocrinology of anorexia nervosa in young people: recent insights. *Curr Opin Endocrinol Diabetes Obes.* 2014; **21(1)**:64-70. [PMID: 24275621]; [DOI: 10.1097/MED.000000000000026]
- 3 Rosen E, Bakshi N, Watters A, Rosen HR, Mehler PS. Hepatic complications of anorexia nervosa. *Dig Dis Sci.* 2017 Nov; **62(11)**: 2977-2981 [PMID: 28932925]; [DOI: 10.1007/s10620-017-4766-9]
- 4 Milner MR, McAnarney ER, Klish WJ. Metabolic abnormalities in adolescent patients with anorexia nervosa. *Journal of Adolescent Health* 1985; **6**: 191-195. [PMID: 3988577]
- 5 Ozawa Y, Shimizu T, Shishiba Y. Elevation of serum aminotransferase as a sign of multiorgan-disorders in severely emaciated anorexia nervosa. *Internal Medicine* 1998; **37**: 32-39. [PMID: 9510397]
- 6 Sherman P, Leslie K, Goldberg E, Rybczynski J, St Louis P. Hypercartenemia and transaminitis in female adolescents with eating disorders: A prospective, controlled study. *Journal of Adolescent Health* 1994; **15**: 205-209. [PMID: 8075090]
- 7 Umeki S. Biochemical abnormalities of the serum in anorexia nervosa. *Journal of Nervous and Mental Disease* 1998; **176**: 503-506. [PMID: 2457069]
- 8 Furuta S, Ozawa Y, Maejima K, Tashiro H, Kitahora T, Hasegawa K, Kuroda S, Ikuta N. Anorexia nervosa with severe liver dysfunction and subsequent critical complications. *Intern Med* 1999; **38**: 575-579. [PMID: 10435364]
- 9 Rivera-Nieves J, Kozaiwa K, Rees Parrish C, Iezzoni J, Berg CL. Marked transaminase elevation in anorexia nervosa. *Dig Dis Sci* 2000; **45**: 1959-63. [PMID: 11117567]
- 10 Di Pascoli L, Lion A, Milazzo D, Caregato L. Acute liver damage in anorexia nervosa. *Int J Eat Disord* 2004; **36**: 114-7. [PMID: 15185281]
- 11 De Caprio C, Alfano A, Senatore I, Zarrella L, Pasanisi F, Contaldo F. Severe acute liver damage in anorexia nervosa: two case reports. *Nutrition* 22 (2006) 572-575. [PMID: 16600819]
- 12 Bridet L, Martin JJ, Nuno JL. Acute liver damage and anorexia nervosa: a case report. *Turk J Gastroenterol.* 2014 Apr; **25(2)**: 205-8. [PMID: 25003683]; [DOI: 10.5152/tjg.2014.2531]
- 13 Rautou PE, Cazals-Hatem D, Moreau R, Francoz C, Feldmann G, Lebrec D, Ogier-Denis E, Bedossa P, Valla D, Durand F. Acute liver cell damage in patients with anorexia nervosa : A possible role of starvation-induced hepatocyte autophagy. *Gastroenterology* 2008; **135(No. 3)**: 840-848. [PMID: 18644371]; [DOI: 10.1053/j.gastro.2008.05.055]
- 14 Kheloufi M, Boulanger CM, Durand F, Rautou PE. Liver autophagy in anorexia nervosa and acute liver injury. *Biomed Res Int.* 2014; **2014**: 701064. [PMID: 25250330]; [DOI: 10.1155/2014/701064]
- 15 Rautou PE, Cazals-Hatem D, Moreau R, Francoz C, Feldmann G, Lebrec D, Ogier-Denis E, Bedossa P, Valla D, Durand F. Acute liver cell damage in patients with anorexia nervosa : A possible role of starvation-induced hepatocyte autophagy. *Gastroenterology* 2008; **135(No. 3)**: 840-848. [PMID: 18644371]; [DOI: 10.1053/j.gastro.2008.05.055]
- 16 Sakada M, Tanaka A, Ohta D, Takayanagi M, Kodama T, Suzuki K, Inoue K, Fujita Y, Maruyama M. Severe steatosis resulted from

anorexia nervosa leading to fatal hepatic failure. *J Gastroenterol* 2006; 714-715. [PMID: 16933013]; [DOI: 10.1007/s00535-006-1845-7]

Cell Biol 2004; **36**: 2491-2502. [PMID: 19200873]; [DOI: 10.1016/S0076-6879(08)03602-1]

17 Mizushima N. Methods for monitoring autophagy. *Int J Biochem*

Peer Reviewers: Jingmin Zhao; Hartmut Jaeschke